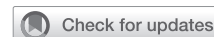

# Simultaneous hybrid maze procedure for long-standing persistent atrial fibrillation with dilated atrium



Zhe Zheng, MD, PhD,<sup>a,b</sup> Yan Yao, MD, PhD,<sup>a,c</sup> Haojie Li, MD,<sup>a,b</sup> Lihui Zheng, MD,<sup>a,c</sup> Sheng Liu, MD,<sup>a,b</sup> Hengqiang Lin, MD,<sup>a,b</sup> and Fujian Duan, MD<sup>a,d</sup>

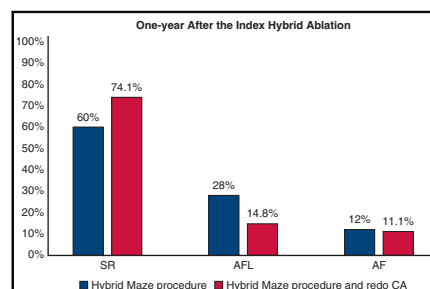
## ABSTRACT

**Background:** The efficacy of catheter-based or thoracoscopic ablation for treating long-standing persistent atrial fibrillation (AF) with a dilated atrium remains suboptimal. This study aimed to assess the feasibility and initial results of simultaneous hybrid ablation with a new biatrial lesion set in these patients.

**Methods:** Twenty-seven consecutive patients with long-standing persistent AF and dilated atrium underwent simultaneous hybrid ablation with a new biatrial lesion set consistent with the principle of the Cox maze procedure at our institution. Patients were followed up at 3, 6, and 12 months after the procedure and annually thereafter.

**Results:** After thoracoscopic epicardial ablation, endocardial mapping confirmed complete bilateral pulmonary vein isolation in 25 patients (96.2%). All patients were followed for a mean of  $18.7 \pm 8.9$  months. Freedom from atrial tachyarrhythmia at 1 year after the single hybrid procedure was 64% with antiarrhythmic drugs and 60% without antiarrhythmic drugs. Freedom from atrial tachyarrhythmia at latest follow-up after the hybrid procedure and redo catheter ablation was 77.8% with antiarrhythmic drugs and 74.1% without antiarrhythmic drugs. In patients with sinus rhythm restoration, mean left atrial diameter decreased from  $54.4 \pm 4.3$  mm to  $45.2 \pm 4.1$  mm ( $P < .001$ ), and mean right atrial diameter decreased from  $59.4 \pm 3.9$  mm to  $54.9 \pm 4.4$  mm ( $P < .001$ ). Postoperative pleural effusion was observed in 3 patients (11.1%), and no adverse events occurred during follow-up.

**Conclusions:** In patients with long-standing persistent AF and a dilated atrium, simultaneous hybrid ablation with the new biatrial lesion set, in combination with touch-up catheter ablation when necessary, can achieve promising results. More studies are needed to confirm these findings. (JTCVS Techniques 2021;5:34-42)



**Results of the simultaneous hybrid maze procedure for long-standing persistent atrial fibrillation and dilated atrium.**

## CENTRAL MESSAGE

The simultaneous hybrid maze procedure is a safe and effective treatment for long-standing persistent atrial fibrillation with a dilated atrium, in combination with touch-up catheter ablation when needed.

## PERSPECTIVE

Simultaneous hybrid ablation with a lesion set consistent with the principle of the Cox maze procedure can be performed safely with encouraging results on a beating heart. With further technologic advances, the hybrid maze procedure may be a minimally invasive method for advanced atrial fibrillation with efficacy equal to that of the Cox maze procedure.

See Commentaries on pages 43 and 45.

From the <sup>a</sup>National Clinical Research Center for Cardiovascular Diseases, State Key Laboratory of Cardiovascular Disease, and Departments of <sup>b</sup>Cardiovascular Surgery, <sup>c</sup>Arrhythmia, and <sup>d</sup>Medical Imaging, Fuwai Hospital, National Center for Cardiovascular Diseases, Chinese Academy of Medical Sciences and Peking Union Medical College, Beijing, China.

Supported by grants from the Ministry of Science and Technology of People's Republic of China (2016YFC1302001). The funder had no role in study design, data collection, data analysis, data interpretation, or manuscript preparation.

Received for publication Oct 15, 2020; accepted for publication Oct 15, 2020; available ahead of print Oct 27, 2020.

Address for reprints: Zhe Zheng, MD, PhD and Yan Yao, MD, PhD, 167 Beilishi Rd, Xicheng District, Beijing 100037, China (E-mail: zhengzhe@fuwai.com or ianyao@263.net.cn).


2666-2507

Copyright © 2020 The Authors. Published by Elsevier Inc. on behalf of The American Association for Thoracic Surgery. This is an open access article under the CC BY-NC-ND license (<http://creativecommons.org/licenses/by-nc-nd/4.0/>).

<https://doi.org/10.1016/j.xjtc.2020.10.015>

**Abbreviations and Acronyms**

AAD	= antiarrhythmic drug
AF	= atrial fibrillation
AFL	= atrial flutter
CA	= catheter ablation
ECG	= electrocardiography
IVC	= inferior vena cava
LA	= left atrium
LAA	= left atrial appendage
LAD	= left atrial diameter
LSPAF	= long-standing persistent atrial fibrillation
NT-proBNP	= N-terminal pro B-type natriuretic peptide
PV	= pulmonary vein
RA	= right atrium
RAD	= right atrial diameter
SR	= sinus rhythm
SVC	= superior vena cava

 Video clip is available online.

The Cox maze procedure has proven to be the best strategy for treating atrial fibrillation (AF); however, it has been less widely applied in the management of nonvalvular AF owing to invasiveness and fears of associated increased morbidity.<sup>1</sup> When applying catheter ablation (CA) as the first-line invasive therapy for persistent AF, the 5-year sinus rhythm (SR) maintenance was <50%.<sup>2-4</sup> Previous studies have reported a success rate of thoracoscopic epicardial ablation on beating heart for patients with persistent AF was about 60%.<sup>5</sup> Hybrid ablation combining thoracoscopic epicardial ablation with electrophysiological mapping and CA was introduced to improve the results of thoracoscopic epicardial ablation; however, one study reported a wide variation in freedom from AF, from 19% to 94%, associated with the type of AF, left atrial size, and type of lesion sets.<sup>6</sup>

The duration of AF and dilation of the left atrium (LA) have been identified as risk factors for recurrent AF.<sup>4,7-10</sup> The efficacy of hybrid ablation for patients with long-standing persistent AF (LSPAF) and a dilated atrium has been unclear. In our center, we performed hybrid ablation with a new biatrial lesion set that is consistent with the principles of the Cox maze procedure. In this study, we examined the initial results of simultaneous hybrid ablation with the new lesion set in patients with LSPAF and marked atrial dilation.

**METHODS****Patient Population**

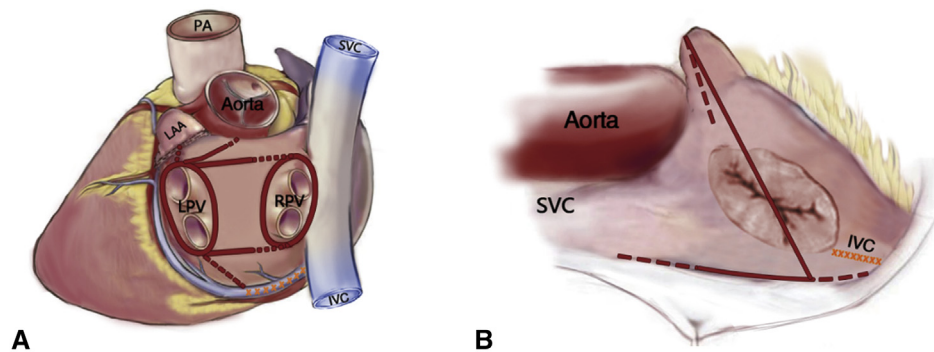
Twenty-seven consecutive patients with LSPAF and a markedly dilated atrium underwent simultaneous hybrid ablation between December 2016 and August 2019. Selection criteria included the following: LSPAF, anteroposterior left atrial diameter (LAD)  $\geq 50$  mm (measured at the left parasternal axis plane by transthoracic echocardiography), use of at least 1 antiarrhythmic drug (AAD) in standard dosage that failed or was not tolerated, patient preference for a hybrid procedure instead of CA after awareness of efficacy and safety, and absence of organic valvular disease. This study was approved by and the need for informed consent waived by the Institutional Review Board of Fuwai Hospital (date of review, October 24, 2019; approval 2017-880).

**Thoracoscopic Epicardial Ablation Technique**

Surgery was performed under general anesthesia and on a beating heart. A double-lumen endotracheal tube for selective lung ventilation was placed. A 10-mm, 30° scope was introduced into the thoracic cavity through a camera port located in the third intercostal space anterior axillary line. One 15-mm working port was located in the fourth intercostal space midaxillary line, and a 10-mm working port was located in the second intercostal space midclavicular line. Access to the right side was more forward than on the left side.

**Left-sided ablation.** The left atrial appendage (LAA) was exposed and excised by linear stapler (ECR 60G; Ethicon Endo-Surgery, Cincinnati, Ohio). Division of the ligament of Marshall was performed with an ultrasonic scalpel. A bipolar radiofrequency clamp (Isolator; AtriCure, Mason, Ohio) was applied to ablate the antrum of left pulmonary veins (PVs) using 3 or 4 applications of energy to create durable linear and transmural lesions. The clamp was redirected with one jaw into the oblique sinus and the other jaw into the transverse sinus horizontally and then used to create left-sided roof and inferior linear lesions on the epicardium. In this application, a double-layer atrial tissue was clamped between the jaws. The line connecting the left PV isolation loop to the mitral annulus was directed to the roof of the aorta at the junction of the left coronary and noncoronary cusp (left fibrous trigone lesion).<sup>11,12</sup> This line was made with bipolar radiofrequency clamp application similar to left-sided roof and inferior linear lesions and complemented with ablation from the Isolator bipolar radiofrequency pen (Figure 1). Finally, coumadin ridge linear lesion connecting the left superior PV to the LAA was created, and linear lesion connecting the left inferior PV to the great cardiac vein, aiming to interrupt the reentrant circuits located in the dilated mitral isthmus, was performed with bipolar radiofrequency pen for 80 seconds in each application.

**Right-sided ablation.** Right PVs were also ablated using the bipolar radiofrequency clamp. The Waterston groove fat pad and part of the crista terminalis were ablated by clamping. With the aid of a suction handle, the inferior wall of the LA was revealed, and the roof of the LA was revealed by hanging the superior vena cava. The left-sided box lesion through the transverse sinus and oblique sinus from the right was clearly visible. The right-sided roof and inferior linear lesions were created with the bipolar radiofrequency pen to connect the right PV isolation loop to the left-sided roof and inferior linear lesions. Next, the linear lesion on the crista terminalis was extended to the superior vena cava (SVC) and inferior vena cava (IVC) using the bipolar radiofrequency pen. The linear lesion connecting the tip of the right atrial appendage (RAA) to the SVC-IVC line on the free wall of the right atrium (RA) was made. To eliminate the reentrant circuits locating at the RAA, the linear lesion was extended from the tip to the base of the RAA. These 2 linear lesions were created with the bipolar radiofrequency pen. The epicardial ablation lesions are depicted in Figure 1. If AF persisted after thoracoscopic epicardial ablation, cardioversion was performed.

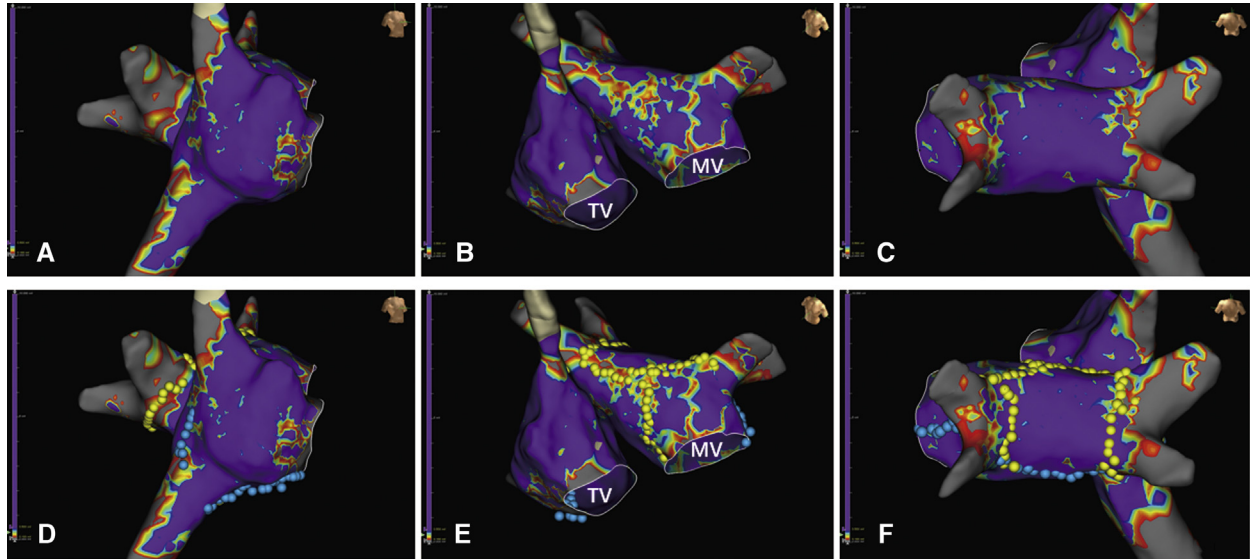


**FIGURE 1.** A schematic drawing of biatrial lesion sets in simultaneous hybrid ablation. A, Posterior view of the left atrium, with linear lesions including bilateral pulmonary vein isolation, the roof line, the inferior line, left fibrous trigone lesion, the linear lesion connecting the left upper pulmonary vein to the left atrial appendage (LAA), the linear lesion connecting the left inferior pulmonary vein to the great cardiac vein (GCV), and GCV linear ablation. B, Lateral view of the right atrium, with linear lesions including the superior vena cava–inferior vena cava (SVC-IVC) line, the linear lesion connecting the right atrial appendage (RAA) to the SVC-IVC line, and the linear lesion connecting the tip to the base of the RAA on the inner wall of the RAA and cavotricuspid isthmus line. The *solid red lines* represent epicardial ablation sites with a bipolar radiofrequency clamp, and the *dotted red lines* represent epicardial ablation sites with a bipolar radiofrequency pen during thoracoscopic ablation. The *yellow line* with crosses represents ablation sites other than touch-up or reinforced sites during catheter ablation. PA, Pulmonary artery; LPV, left pulmonary vein; RPV, right pulmonary vein.

**Three-Dimensional Voltage Mapping and Catheter Ablation**

Endocardial electrophysiological mapping and CA were performed immediately after initial thoracoscopic epicardial ablation. Two multiple-polar catheters were positioned within the coronary sinus (IBI; St Jude Medical,

St Paul, Minn) and at the right ventricle (Daig, St Jude Medical). After transseptal puncture, 70 to 100 IU/kg heparin was administered i.v., and the activated clotting time was maintained at 200 to 300 seconds. A long Swartz sheath (8F, SR0; St Jude Medical) was introduced into the LA, and a circular mapping catheter (PV12; APT, Shenzhen, China) was subsequently navigated into the LA for electroanatomic and voltage mapping



**FIGURE 2.** Endocardial 3-dimensional voltage mapping and catheter ablation after initial thoracoscopic epicardial ablation. A, Right atrial mapping (right atrial free wall view) showing a persistent normal potentials area and a low-voltage area located at the superior vena cava–inferior vena cava (SVC-IVC) linear lesion and almost entire linear lesion connecting the right atrial appendage (RAA) to the SVC-IVC lesion was composed of a persisting normal potentials area. B, Bi-atrial mapping (anteroposterior view) showing the roof line and the left fibrous trigone line. C, Biatrial mapping (posteroanterior view) showing gray areas located in bilateral pulmonary veins, implying complete bilateral pulmonary vein isolation and persistent normal potentials at the posterior wall of the left atrium and without an obvious inferior line. D, Based on the electrophysiological mapping in A, touch-up endocardial catheter ablation (*blue spots*) was performed at the SVC-IVC line, and a cavotricuspid isthmus line was also created. E, Based on the electrophysiological mapping in B, reinforced endocardial catheter ablation (*yellow spots*) was performed at the roof line and left fibrous trigone line. F, Based on the electrophysiological mapping in C, reinforced endocardial catheter ablation (*blue and yellow spots*) with a box lesion was performed. Endocardial voltage mapping displayed atrial models containing *gray areas* (no voltage), *colored areas* (low voltage), and *purple areas* (normal voltage). Catheter ablation was marked with *blue and yellow dots*. TV, Tricuspid valve; MV, mitral valve.

with the EnSite NavX mapping system (Abbott, Indianapolis, Ind). The normal voltage areas (purple areas) were defined as voltage  $>0.5$  mV, transmural areas (gray areas) were defined as  $<0.1$  mV, and low-voltage areas were defined as 0.1 to 0.5 mV. The full length of the surgical linear lesion and the length of the normal voltage areas were tagged and measured, and the ratio of the two was calculated. A 4.0-mm TactiCath quartz ablation catheter (Abbott) was used to confirm whether the surgical lesion was completed and to ablate the residual conduction gaps along the previous surgical lesion. Irrigated radiofrequency ablation was applied with an upper temperature limit of 43 °C, power of 30 to 40 W, and flow rate of 17 mL/min. Linear lesions of the coronary sinus, tricuspid isthmus, and mitral isthmus were delivered routinely after the foregoing steps (Figure 2). Durable PV isolation, conduction block over the mitral isthmus, and tricuspid isthmus lesions were confirmed. Finally, protamine was used to abrogate the effect of heparin and maintain the activated clotting time at  $<180$  seconds before removing all catheters. Patients were transferred to the intensive care unit for continuous monitoring and treatment.

### Postoperative Drug Treatment

Oral class III AADs with preference to sotalol was routinely administered after the procedure and continued for 3 months after the procedure. At 3 months after the index procedure, continuous AAD treatment or redo catheter ablation was recommended for patients with AF recurrence. Low molecular weight heparin and warfarin were started as soon as bleeding risk allowed. Patients preference to taking novel oral anticoagulants continued to be used low molecular weight heparin until the thoracic drainage tube removal, then they were given novel oral anticoagulants. Oral anticoagulation was continued for at least 3 months. If the 3-month monitoring visit confirmed the absence of atrial arrhythmia, oral anticoagulants were stopped. If atrial arrhythmia persisted, oral anticoagulants were continued when the CHA<sub>2</sub>DS<sub>2</sub>-VASc score was  $\geq 2$ .

### Follow-up

The patients were followed-up at 3, 6, and 12 months after the procedure and annually thereafter with 24-hour Holter or 7-day ECG monitoring. At 3 months after the procedure, 24-hour Holter or 7-day ECG monitoring was undertaken after confirmation of the absence of atrial arrhythmia with 12-lead ECG and the withdrawal of AADs. Freedom from atrial tachyarrhythmia was defined as the absence of episodes of AF, atrial flutter (AFL), or atrial tachycardia lasting  $\geq 30$  seconds on any surface ECG or 24-hour Holter or 7-day ECG monitoring after the 3-month blanking period.

### Endpoints

The primary endpoint was freedom from atrial tachyarrhythmia with or without AADs at 12 months after the single hybrid procedure. The secondary endpoint was freedom from atrial tachyarrhythmia with or without AADs at latest follow-up after the hybrid procedure and redo CA.

### Statistical Analysis

Categorical data are presented as frequency and percentage, and continuous variables are presented as mean  $\pm$  SD or median with interquartile range as appropriate. Preoperative and postoperative comparisons of continuous variables was performed with the paired Student *t* test.

## RESULTS

### Patient Characteristics

A total of 27 patients with LSPAF who underwent simultaneous hybrid ablation with the new biatrial lesion set were included in the analysis. Patient characteristics are

**TABLE 1. Characteristics of 27 patients who underwent simultaneous hybrid ablation for long-standing persistent atrial fibrillation**

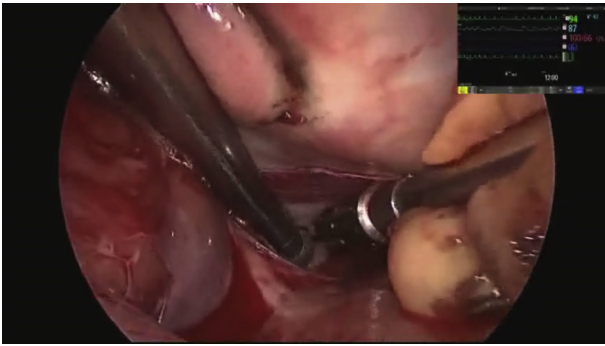
Characteristic	Value
Age, y, mean $\pm$ SD	58.8 $\pm$ 6.6
Male sex, n (%)	21 (77.8)
BMI, kg/m <sup>2</sup> , mean $\pm$ SD	27.3 $\pm$ 3.5
AF duration, y, mean $\pm$ SD	4.3 $\pm$ 3.8
Hypertension, n (%)	21 (77.8)
Hyperlipemia, n (%)	5 (18.5)
Diabetes mellitus, n (%)	7 (25.9)
Previous stroke, n (%)	7 (25.9)
Previous PCI, n (%)	1 (3.7)
Hypertrophic cardiomyopathy, n (%)	2 (7.4)
Dilated cardiomyopathy, n (%)	1 (3.7)
AAD treatment, n (%)	
IC	3 (12)
II	18 (66.7)
III	9 (33.3)
CHA <sub>2</sub> DS <sub>2</sub> -VASc score, mean $\pm$ SD	2.1 $\pm$ 1.4
LAD, mm, mean $\pm$ SD	54.2 $\pm$ 4.1
RAD, mm, mean $\pm$ SD	59.1 $\pm$ 5.5
LVEDD, mm, mean $\pm$ SD, mm	49.0 $\pm$ 4.5
LVEF, %, mean $\pm$ SD	61.3 $\pm$ 5.6
NT-proBNP, pg/mL, mean $\pm$ SD	1057.1 $\pm$ 992.9

BMI, Body mass index; AF, atrial fibrillation; PCI, percutaneous coronary intervention; AAD, antiarrhythmic drug; LAD, left atrial anteroposterior diameter; RAD, right atrial superior-inferior diameter; LVEDD, left ventricular end-diastolic diameter; LVEF, left ventricular ejection fraction; NT-proBNP, N-terminal pro B-type natriuretic peptide.

summarized in Table 1. The mean patient age was 58.8  $\pm$  6.6 years, and 21 (77.8%) were male. The average duration of AF was 4.3  $\pm$  3.8 years. The mean LAD was 54.2  $\pm$  4.1 mm, and the mean superior-inferior right atrial diameter (RAD) was 59.1  $\pm$  5.5 mm.

### Procedural Characteristics

**Initial thoracoscopic epicardial ablation.** All patients underwent a complete biatrial lesion set. Three patients (11.1%) were restored to SR when thoracoscopic epicardial ablation was performed at the RA (Video 1). In addition, AF converted to AFL in 2 patients (7.4%) during thoracoscopic epicardial ablation, and electric cardioversion was performed in the other 22 patients (81.5%) (Figure 3). Twenty-five patients underwent a postoperative computed tomography scan, which showed a 100% success rate of LAA exclusion and a mean stump length was 2.6  $\pm$  3.0 mm. **Electrophysiological mapping findings and jointed catheter ablation.** After initial thoracoscopic epicardial



**VIDEO 1.** In this patient with long-standing persistent atrial fibrillation (3 years), the left atrium was significantly enlarged, with a diameter of 50 mm. The operation was performed under general anesthesia, with double-lumen endotracheal intubation and a beating heart. At the beginning, thoracoscopic surgical ablation was performed on both sides. The operating hole was located in the second intercostal midclavicular line and the fourth or fifth intercostal axillary line. The laparoscopic lens was entered into left pleural cavity from the third intercostal axillary line. The pericardium was cut by an ultrasonic knife, the left atrial appendage was removed by a stapler, and the Marshall ligament was cut off. Next, the left pulmonary vein was dissected with a soft tissue dissector and isolated by a bipolar radiofrequency clamp, making sure that the clamp was beyond the pulmonary veins. Then atrial tissues from the upper left pulmonary vein to the aortic root and left side of the roof line was ablated by the bipolar clamp. The next step was ablation from the left atrial appendage root to the upper left pulmonary vein. Atrial tissues from the lower left pulmonary vein to the great cardiac vein were ablated with a bipolar pen. After the procedures on the left side were completed, the procedures on the right side were performed. Access to the right side was more forward than on the left side. A lobular adhesion was released. After the pericardium was cut and 3 traction lines were placed, the right pulmonary vein was isolated by a bipolar clamp, and ganglionated plexi in the Waterstone groove were also ablated by the clamp. Next, the left atrial roof beneath the superior vena cava and the space between the inferior vena cava and the lower right pulmonary vein were dissected, and a box lesion of the left atrial posterior wall was finished by the bipolar pen. Finally, lesion sets of the right atrium were completed by the bipolar pen, including the line from the superior vena cava to the inferior vena cava, the line from the RAA to the aortic root, and the connected line between the RAA and the line from superior vena cava to the inferior vena cava. At the start of ablation of the connected line, AF converted to AFL; at the completion of ablation of the connected line, sinus rhythm was restored. After surgical ablation, the reference electrode was placed in the coronary sinus under X-ray guidance, and a circle electrode was placed in the left atrium through the atrial septal puncture. Voltage mapping was performed when left atrial modeling was completed. The results showed residual potentials in the left pulmonary vein and mitral isthmus and gaps in the ablation line on the roof. An endocardial catheter ablation was performed at these sites. Finally, isolation or entrance and exit blocks in the pulmonary veins, left atrial posterior wall, and mitral isthmus were verified. Video available at: [https://www.jtcvs.org/article/S2666-2507\(20\)30588-5/fulltext](https://www.jtcvs.org/article/S2666-2507(20)30588-5/fulltext).

ablation, endocardial electrophysiological mapping and checking at the LA and RA were analyzed in 26 and 8 patients, respectively. In 2 patients who presented with AFL, electrical activation sequence mapping displayed a

counterclockwise macro-reentry rotating mitral valve annulus, and SR was restored after endocardial CA was performed at mitral isthmus. Complete low-voltage or transmural areas were seen on left atrial linear lesions in 6 patients (23.1%); in contrast, in other patients, different percentages of areas of persisting normal potentials were seen in surgical linear lesions (Table 2).

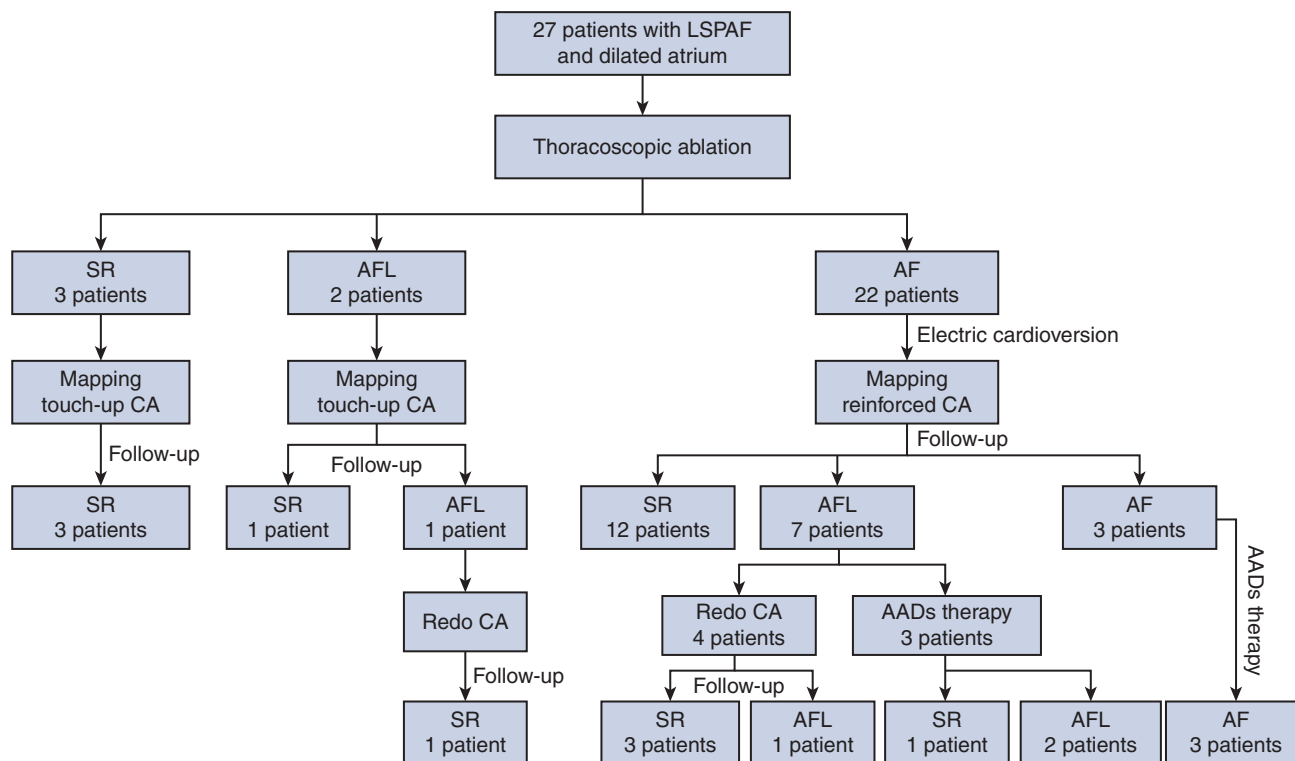
Left and right PV entrance-exit block was confirmed in 25 patients (96.2%) and in all patients (100%), respectively. In all the ablation lines at the LA, a linear lesion connecting the left inferior PV to the great cardiac vein had the highest percentage of areas of persisting normal potentials (22.4%). In all the ablation lines at the RA, the linear lesion connecting the IVC to the tip of the RAA displayed the highest percentage of areas of persisting normal potentials (28.4%). Lesions of reinforced and touch-up ablation during the jointed CA are described in Table 2. Endocardial 3-dimensional voltage mapping and CA after initial thoracoscopic epicardial ablation in a patient is shown in Figure 2.

#### Follow-up

**Efficacy after the index procedure.** All patients were followed up to a mean of 18.7 months (median, 12 months; range, 6 to 36 months). Recurrent AF occurred in 3 patients. Eight patients were diagnosed with new-onset AFL, and 1 of those patients restored SR after AAD therapy. Freedom from atrial tachyarrhythmia after the single hybrid procedure was 70.4% at 6 months, 64.0% at 12 months, and 53.8% at 24 months in patients with AAD therapy and 70.4% at 6 months, 60% at 12 months, and 46.2% at 24 months in patients without AAD therapy (Figure 4).

**Efficacy after redo catheter ablation.** Five out of 8 patients with postoperative new-onset AFL underwent redo CA. Electrophysiological mapping displayed complete PV isolation in 5 patients and the gaps related to AFL located on the mitral isthmus and coumadin ridge in 2 patients, on the mitral isthmus and roof linear lesion in 1 patient, on the cavotricuspid isthmus and roof linear lesion in 1 patient, and on the mitral isthmus alone in 1 patient. During redo CA, AFL terminated to SR in 3 patients, and persisted in 2 patients and terminated to SR by overdrive pacing. At latest follow-up, SR restoration was observed in 4 out of 5 patients who underwent redo CA, and AFL persisted in 1 patient (Figure 3). Freedom from atrial tachyarrhythmia after the hybrid ablation and redo CA was 77.8% at 6 months and 76.9% at 12 months in all patients with AAD therapy and 74.1% at 6 months and 73.1% at 12 months in all patients without AAD therapy (Figure 4).

**Atrial reversed remodeling and cardiac function improvement.** Compared with baseline, in patients with SR, LAD, RAD, and N-terminal pro B-type natriuretic peptide (NT-proBNP) all decreased and left ventricular ejection



**FIGURE 3.** Flow diagram of the simultaneous hybrid maze procedure and the results at latest follow-up. *LSPAF*, Long-standing persistent atrial fibrillation; *SR*, sinus rhythm; *AFL*, atrial flutter; *AF*, atrial fibrillation; *CA*, catheter ablation; *AADs*, antiarrhythmic drugs.

fraction increased. In patients with recurrent AF or new-onset AFL, only LAD decreased significantly (Table 3).

**Adverse Events**

No in-hospital deaths occurred. Three patients (11.1%) had postoperative pleural effusion that was drained 2 weeks after surgery. No patient required permanent pacemaker

implantation. No thromboembolic complications or heart failure readmission or deaths occurred.

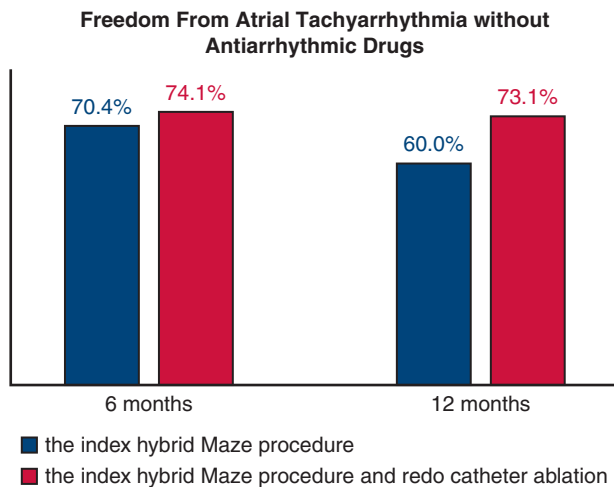
**DISCUSSION**

Our data show that in patients with LSPAF with a markedly dilated atrium (LAD ≥50 mm), freedom from atrial tachyarrhythmia without AAD therapy was 60% at

**TABLE 2.** Electrophysiological voltage mapping results in 26 patients and procedural characteristics of jointed catheter ablation in all patients after initial thoracoscopic epicardial ablation

Parameter	Persisting normal potentials, n (%)	Ratio of normal voltage, %, mean ± SD	Reinforced or touch-up CA, n (%)
<b>Left atrial lesions (n = 26)</b>			
Left PV isolation loop	1 (3.8)	—	16 (59.3)
Right PV isolation loop	0	—	15 (55.6)
Roof line	7 (26.9)	8.6 ± 21.0	26 (96.3)
Inferior line	9 (34.6)	7.8 ± 13.6	6 (22.2)
Left fibrous trigone line	11 (42.3)	11.2 ± 13.7	17 (63.0)
Left inferior PV to GCV/MI	15 (57.7)	22.4 ± 23.2	26 (96.3)
<b>Right atrial lesions (n = 8)</b>			
SVC-IVC line	1 (12.5)	3.2 ± 9.1	1 (3.7)
IVC-RAA tip line	6 (75)	28.4 ± 25.5	0 (0)
Line from the tip to the base of RAA	2 (25)	12.4 ± 23.5	0 (0)
Coronary sinus lesion	—	—	13 (48.1)
Cavotricuspid isthmus line	—	—	27 (100)

CA, Catheter ablation; PV, pulmonary vein; GCV, great cardiac vein; MI, mitral isthmus; SVC, superior vena cava; IVC, inferior vena cava; RAA, right atrial appendage.



**FIGURE 4.** Freedom from atrial tachyarrhythmia without antiarrhythmic drugs (AADs) after the single hybrid procedure was 70.4% at 6 months and 60% at 12 months. Freedom from atrial tachyarrhythmia without AADs in all patients was 74.1% at 6 months and 73.1% at 12 months after the hybrid ablation and redo catheter ablation.

12 months after single simultaneous hybrid ablation with the new biatrial lesion set and 74.1% after the index procedure and redo CA at latest follow-up (Figure 5).

**Ablation Efficacy in AF Patients With Dilated Atrium**

Atrial enlargement is a predictor of AF recurrence following radiofrequency CA or surgical ablation,<sup>7,9,13</sup> which always indicates longer AF duration and more complicated mechanism in AF. In the present study, the cohorts were characterized by a markedly dilated biatrium and would face challenges when treated with CA or thoracoscopic epicardial ablation. We performed a simultaneous hybrid ablation in these patients to achieve a better result. Asmundis and colleagues<sup>14</sup> reported a 65.1% rate of

freedom from atrial arrhythmias without AADs in patient with LSPAF with a dilated LA at a nearly 2-year follow-up. Recurrences were characterized by AF in 13 patients (20.3%) and atrial tachycardia in 8 patients (12.5%).<sup>14</sup> Population characteristics and atrial arrhythmia recurrence in that study were similar to those in our study. The incidence of recurrent AF was lower in our study, at 11%. Pison and colleagues<sup>15</sup> reported a success rate of 90% for persistent AF with smaller LA (mean LAD, 43.1 ± 5.6 mm) without AAD therapy. In our study, LA size is larger, which may be the reason for a lower success rate.

**Advantages of the Hybrid Technique With the New Biatrial Lesion Set**

Lesion sets with box lesions or a left-sided Cox maze and cavotricuspid isthmus are generally applied in the present hybrid procedures.<sup>16,17</sup> However, the substrate of potential AF drivers might lay on the dilated RA in patients with LSPAF.<sup>18</sup> The new biatrial lesion set, which is analogous to that of standard Cox maze, is an easily applied ablation strategy that can interrupt all drivers in both atria and are especially useful for patients with LSPAF and a dilated atrium. In our cohort, AF terminated to SR in 11.1% of patients when RA ablation was performed. An additional left trigone lesion is incorporated in the left-sided lesion set compared with the left-sided Cox maze procedure to prevent perimitral flutter.<sup>11,12</sup> Electrophysiological mapping after thoracoscopic epicardial ablation revealed that the bipolar pen created a suboptimal transmural effect on linear lesions at the atrium. Therefore, the hybrid technique combining thoracoscopic epicardial ablation and endocardial CA on beating heart has the potential to create transmural tissue lesions equivalent to the cut-and-sew technique on an arrested heart.

**New-Onset AFL**

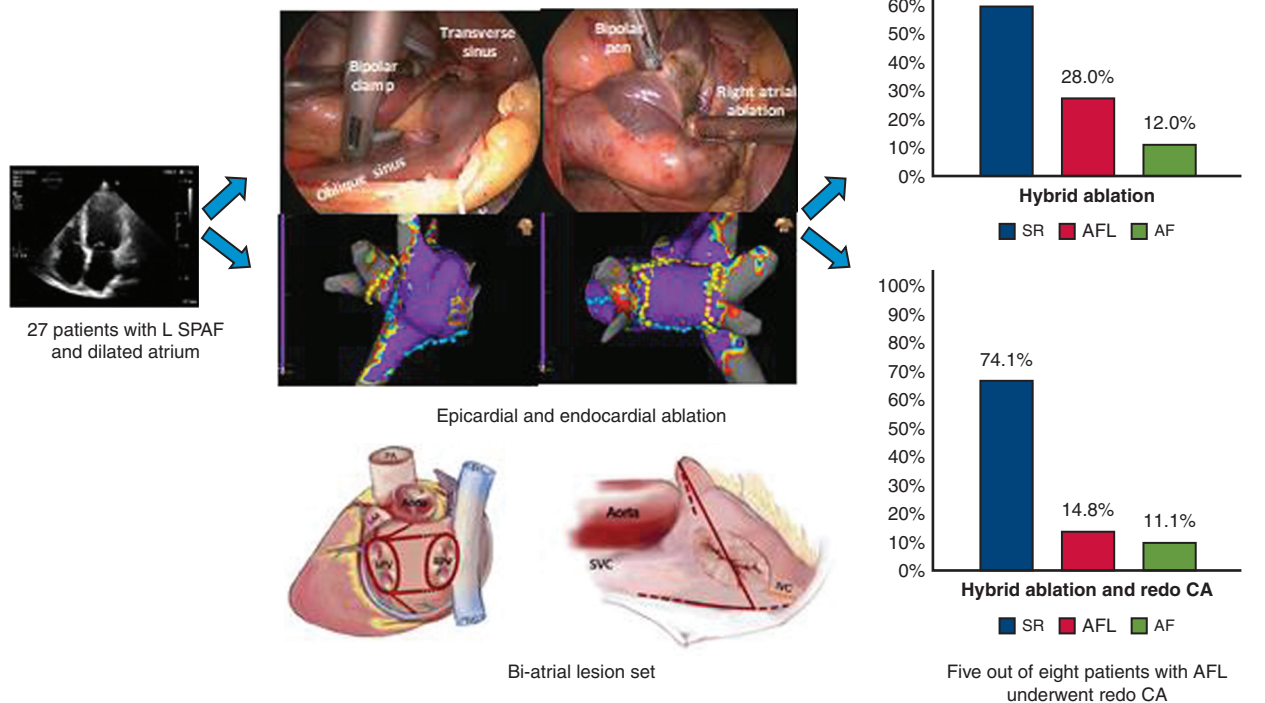
Although the hybrid technique was applied to eliminate the gaps after thoracoscopic epicardial ablation, some studies have shown a noteworthy incidence of new-onset AFL after simultaneous or staged hybrid ablation.<sup>10,14,19,20</sup> Our study found a higher incidence of postoperative atrial tachycardia. Several factors may be responsible for this. First, immediate endocardial voltage mapping after thoracoscopic epicardial ablation can result in false low-voltage lesions due to acute edema, inflammation, and myocardial ischemia,<sup>10</sup> which might be overlooked by joint touch-up CA, and late conductance reconnection may occur. The staged hybrid procedure is beneficial to the full inspection to mature tissue lesion at two or three months after thoracoscopic epicardial ablation. The potential advantage of staged hybrid ablation to decrease postoperative AFL needs further clarification. Second, based on joint CA with spot ablations, the larger the atrium, the greater the risk of gaps. Third, to avoid damage to the esophagus,

**TABLE 3. Atrial reversed remodeling during follow-up**

Parameter	Baseline, mean ± SD	Follow-up, mean ± SD	P value
<b>Patients with SR (n = 17)</b>			
LAD, mm	54.4 ± 4.3	45.2 ± 4.1	<.001
RAD, mm	59.4 ± 3.9	54.9 ± 4.4	<.001
LVEF, %	61.2 ± 4.4	64.1 ± 3.8	.028
NT-proBNP, pg/mL	960.9 ± 769.7	271.6 ± 314.9	.001
<b>Patients with AF or AFL (n = 10)</b>			
LAD, mm	53.9 ± 4.1	47.6 ± 5.2	.001
RAD, mm	58.3 ± 8.7	57.5 ± 4.5	.772
LVEF, %	61.4 ± 7.6	60.5 ± 8.8	.723
NT-proBNP, pg/mL	669.4 ± 560.1	530.1 ± 288.2	.501

SR, Sinus rhythm; LAD, left atrial anterior-posterior diameter; RAD, right atrial superior-inferior diameter; LVEF, left ventricular ejection fraction; NT-proBNP, N-terminal pro B-type natriuretic peptide; AF, atrial fibrillation; AFL, atrial flutter.

The efficacy of simultaneous hybrid procedure with bi-atrial lesion set for long-standing persistent atrial fibrillation with dilated atrium



**FIGURE 5.** Twenty-seven patients with long-standing persistent atrial fibrillation (LSPAF) with markedly dilated atrium underwent simultaneous hybrid ablation with a biatrial lesion set consistent with the principle of the Cox maze procedure. The upper part of the middle portion in the picture shows epicardial left-sided box lesion ablation by a bipolar clamp through the transverse and oblique sinus, epicardial ablation with a bipolar pen at the free wall of the right atrium, and endocardial ablation at the right atrium (blue spots) and the posterior wall of the left atrium (blue spots and yellow spots). The inferior part of the middle portion in the picture show the complete lesion set during the simultaneous hybrid ablation. At 12 months after the single simultaneous hybrid ablation, without antiarrhythmic drugs, 60% patients restored sinus rhythm (SR), 28% patients had new-onset atrial flutter (AFL), and 12% patients had recurrent atrial fibrillation (AF). At last follow-up after the simultaneous hybrid procedure and redo catheter ablation (CA) (4 of 5 patients who underwent redo CA were followed for 12 months, and 1 patient was followed for 6 months), 74.1% restored SR, 14.8% had new-onset AFL and 11.1% had recurrent AF. The hybrid maze procedure for treatment of a more challenging clinical problem of chronic persistent AF in patients with dilated atria was introduced. The initial results were promising. More studies including the staged hybrid maze procedure in these patients are needed to confirm its effectiveness. PA, Pulmonary artery; SVC, superior vena cava; LAA, left atrial appendage; LPV, left pulmonary vein; RPV, right pulmonary vein; IVC, inferior vena cava.

endocardial ablation at the mitral isthmus was not done in line with the epicardial lesion at the mitral isthmus, which may be responsible for the new-onset AFL related to mitral isthmus in this study. The incidence of new-onset AFL should be given sufficient attention when simultaneous hybrid ablation is performed. The appearance of nontransmural lesions is common after thoracoscopic epicardial ablation, therefore, higher requirements are proposed for jointed endocardial ablation, especially in linear lesions at the atrium. On the other hand, we believe that new-onset AFL is the bridge through which AF converts to SR, and that the hybrid maze procedure is a promising technique to treat LSPAF with a dilated atrium.

**Safety**

The previous report showed that the severe complication rate after a simultaneous procedure was 5%,<sup>17</sup> the safety of this study cohort was relatively good. There were no major complications, such as death, stroke, procedural bleeding, or conversion to median sternotomy with cardiopulmonary bypass, which was attributed to the extensive experience of the surgeon and interventionist in this study. We are not sure that the safety of the simultaneous hybrid maze procedure in this study can be generalized. Considering the results of our study, we suggest that the procedure be carried out by experienced heart rhythm team for patients at low risk, and that the safety outcome be strictly monitored.



## Limitations

One important limitation of this study is related to the inadequacy of a small pilot study for drawing definite conclusions with a limited sample. Determining the safety and effectiveness of the hybrid maze procedure for treating patients with LSPAF and a dilated atrium needs further powerful studies with larger sample. Given this early experience, we did not perform the endocardium mapping and ablation at the right atrium in all patients, which might have a negative influence on our results. For patients who converted to sinus rhythm during thoracoscopic epicardial ablation, whether the planned endocardial portion is beneficial requires further confirmation. Extensive unidirectional radiofrequency pen application was used to create most of linear lesions at biatrium and without performing endocardial catheter ablation, in line with the surgical lesion at the right atrium in most patients, which might contribute to postoperative recurrence. Considering the side effects of AADs and patient preference, not all patients were treated with oral class I or III AADs before the procedure, which did not likely influence the postoperative results because of the limited efficacy of AADs in the treatment of LSPAF. The small size of our study in patients with a preserved ejection fraction may limit its applicability to larger and more diverse groups of patients. In addition, in this study, all procedures were performed by one team in a single center, and the results should not be generalized.

## CONCLUSIONS

In this pilot study, in patients with LSPAF with markedly dilated atrium, simultaneous hybrid ablation with a new biatrial lesion set was shown to be a feasible and safe procedure. More studies including the staged hybrid maze procedure in these patients are needed to confirm the effectiveness of the hybrid maze procedure.

## Conflict of Interest Statement

The authors reported no conflicts of interest.

The *Journal* policy requires editors and reviewers to disclose conflicts of interest and to decline handling or reviewing manuscripts for which they may have a conflict of interest. The editors and reviewers of this article have no conflicts of interest.

We thank Shujie Wang for the electrophysiological mapping and CA image acquisition and Lexue Wu for the picture of the lesion sets. We also thank James R. Edgerton for revising this manuscript.

## References

1. Badhwar V, Rankin JS, Damiano RJ Jr, Gillinov AM, Bakaeen FG, Edgerton JR, et al. The Society of Thoracic Surgeons 2017 clinical practice guidelines for the surgical treatment of atrial fibrillation. *Ann Thorac Surg.* 2017;103:329-41.

2. Schreiber D, Rostock T, Fröhlich M, Sultan A, Servatius H, Hoffmann BA, et al. Five-year follow-up after catheter ablation of persistent atrial fibrillation using the stepwise approach and prognostic factors for success. *Circ Arrhythm Electrophysiol.* 2015;8:308-17.
3. Scherr D, Khairy P, Miyazaki S, Aurillac-Lavignolle V, Pascale P, Wilton SB, et al. Five-year outcome of catheter ablation of persistent atrial fibrillation using termination of atrial fibrillation as a procedural endpoint. *Circ Arrhythm Electrophysiol.* 2015;8:18-24.
4. Kawaji T, Shizuta S, Morimoto T, Aizawa T, Yamagami S, Yoshizawa T, et al. Very long-term clinical outcomes after radiofrequency catheter ablation for atrial fibrillation: a large single-center experience. *Int J Cardiol.* 2017;249:204-13.
5. van Laar C, Kelder J, van Putte BP. The totally thoracoscopic maze procedure for the treatment of atrial fibrillation. *Interact Cardiovasc Thorac Surg.* 2017;24:102-11.
6. Khojenezhad A, Ellenbogen KA, Al-Atassi T, Wang PJ, Kasirajan V, Wang X, et al. Hybrid atrial fibrillation ablation: current status and a look ahead. *Circ Arrhythm Electrophysiol.* 2017;10:e005263.
7. Njoku A, Kannabhiran M, Arora R, Reddy P, Gopinathannair R, Lakkireddy D, et al. Left atrial volume predicts atrial fibrillation recurrence after radiofrequency ablation: a meta-analysis. *Europace.* 2018;20:33-42.
8. Richardson TD, Shoemaker MB, Whalen SP, Hoff SJ, Ellis CR. Staged versus simultaneous thoracoscopic hybrid ablation for persistent atrial fibrillation does not affect time to recurrence of atrial arrhythmia. *J Cardiovasc Electrophysiol.* 2016;27:428-34.
9. Sunderland N, Maruthappu M, Nagendran M. What size of left atrium significantly impairs the success of maze surgery for atrial fibrillation? *Interact Cardiovasc Thorac Surg.* 2011;13:332-8.
10. Bulava A, Mokracek A, Hanis J, Eisenberger M, Kurfirst V, Dusek L. Correlates of arrhythmia recurrence after hybrid epi- and endocardial radiofrequency ablation for persistent atrial fibrillation. *Circ Arrhythm Electrophysiol.* 2017;10:e005273.
11. Edgerton JR, Jackman WM, Mahoney C, Mack MJ. Totally thoracoscopic surgical ablation of persistent AF and long-standing persistent atrial fibrillation using the "Dallas" lesion set. *Heart Rhythm.* 2009;6(12 Suppl):S64-70.
12. Edgerton JR, Jackman WM, Mack MJ. A new epicardial lesion set for minimal access left atrial maze: the Dallas lesion set. *Ann Thorac Surg.* 2009;88:1655-7.
13. Wen SN, Liu N, Bai R, Tang RB, Yu RH, Long DY, et al. Right atrial diameter and outcome of catheter ablation of atrial fibrillation. *J Interv Card Electrophysiol.* 2017;49:157-64.
14. de Asmundis C, Chierchia GB, Mugnai G, Van Loo I, Nijs J, Czaplá J, et al. Midterm clinical outcomes of concomitant thoracoscopic epicardial and transcatheter endocardial ablation for persistent and long-standing persistent atrial fibrillation: a single-centre experience. *Europace.* 2017;19:58-65.
15. Pison L, La Meir M, van Opstal J, Blaauw Y, Maessen J, Crijns HJ. Hybrid thoracoscopic surgical and transvenous catheter ablation of atrial fibrillation. *J Am Coll Cardiol.* 2012;60:54-61.
16. Kumar P, Kiser AC, Gehi AK. Hybrid treatment of atrial fibrillation. *Prog Cardiovasc Dis.* 2015;58:213-20.
17. Jiang YQ, Tian Y, Zeng LJ, He SN, Zheng ZT, Shi L, et al. The safety and efficacy of hybrid ablation for the treatment of atrial fibrillation: a meta-analysis. *PLoS One.* 2018;13:e0190170.
18. Miller JM, Kalra V, Das MK, Jain R, Garlie JB, Brewster JA, et al. Clinical benefit of ablating localized sources for human atrial fibrillation: the Indiana University FIRM registry. *J Am Coll Cardiol.* 2017;69:1247-56.
19. Velagic V, Asmundis CDE, Mugnai G, Irfan G, Hunuk B, Stroker E, et al. Repeat procedures after hybrid thoracoscopic ablation in the setting of longstanding persistent atrial fibrillation: electrophysiological findings and 2-year clinical outcome. *J Cardiovasc Electrophysiol.* 2016;27:41-50.
20. Maesen B, Pison L, Vroomen M, Luermans JG, Vernoooy K, Maessen JG, et al. Three-year follow-up of hybrid ablation for atrial fibrillation. *Eur J Cardiothorac Surg.* 2018;53(Suppl\_1):i26-32.

**Key Words:** hybrid ablation, maze, long-standing persistent atrial fibrillation, dilated atrium