

Microsurgical Complications after Finger Reimplantation Treated with Negative Pressure Wound Therapy: A Case Report

Jorge I. Quintero, MD*†

Constanza Moreno-Serrano, MD*†

Julio C. Bermúdez, MD*†

Hand and Microsurgery Research
Group

Summary: Venous congestion is the most critical complication following microsurgical finger replantation and can present within the first postoperative days or even in the immediate postoperative period. This is a case series of three patients who underwent digit replantation. The postoperative complication was venous congestion, and immediately, negative pressure wound therapy (NPWT) was applied to reduce the risk of failure. Three patients with a range of 35 years of age were included. One index finger, one thumb, and one ring finger were the fingers amputated; the surgical technique was described; our anticoagulant protocol was demonstrated; and finally, standardization of the NPWT was established. At the end of the therapy, all fingers survived. We concluded that NPWT is an excellent treatment option following the identification of venous congestion in digit replantation. (*Plast Reconstr Surg Glob Open* 2022;10:e4517; doi: [10.1097/GOX.0000000000004517](https://doi.org/10.1097/GOX.0000000000004517); Published online 20 September 2022.)

Venous congestion is the most critical complication following microsurgical finger replantation and can present within the first postoperative days or even in the immediate postoperative period.¹ Several treatment options for this complication have been described, including leech therapy,² active bleeding of the fingertip or nail bed,³ and systemic anticoagulation with a high risk of anemia and blood transfusion requirements.⁴ Recently, negative pressure wound therapy (NPWT) has been identified as a novel method to treat venous congestion in free flaps.⁵ These favorable results have allowed for exploration of the use of NPWT in venous congestion following finger replantation. We report three cases of finger replantation that developed venous congestion and were treated with NPWT as a salvage procedure.

MATERIALS AND METHODS

This is a case series of three patients who underwent digit replantation. The postoperative course was complicated by venous congestion. NPWT was applied after the

diagnosis of venous congestion since venous reconstruction was very challenging due to the amputation zone. All patients followed the same anticoagulation protocol previously described.⁵ Settings and duration of NPWT of all three digits were recorded.

RESULTS

The first patient is a 33-year-old woman with an amputation of the index finger at the level of the distal interphalangeal joint secondary to a table saw injury. Microsurgical anastomosis of one artery and one vein was performed 33 hours after her admission. Venous congestion and probable arterial insufficiency were identified 44 hours after the finger replantation and NPWT was initiated. Five days after continuous NPWT the finger was no longer congested and viable.

The second patient is a 46-year-old man with an amputation of the left thumb at interphalangeal joint secondary to a table saw injury. Microsurgical anastomosis of one artery and one vein was performed after 8 hours of cold ischemia. Venous congestion was identified 96 hours later, and NPWT was applied. Three days after continuous NPWT, the thumb was less congested and was viable.

The third patient is a 28-year-old man with an avulsion amputation of the right ring finger at mid-third of the proximal phalanx. Microsurgical anastomosis of one artery and two veins was performed after 2 hours of cold ischemia. Fracture of the head of the middle phalanx with avulsion of the flexor digitorum profundus and complete laceration of the extensor mechanism was the initial injury. The radial and ulnar nerves were sutured, and the

From the *Hand and Microsurgery Division, Department of Orthopedics and Traumatology, Hospital Universitario Fundación Santa Fe de Bogotá, Bogotá, Colombia; and †School of Medicine, Universidad de los Andes, Bogotá, Colombia.

Received for publication May 20, 2022; accepted July 19, 2022.

Copyright © 2022 The Authors. Published by Wolters Kluwer Health, Inc. on behalf of The American Society of Plastic Surgeons. This is an open-access article distributed under the terms of the [Creative Commons Attribution-Non Commercial-No Derivatives License 4.0 \(CCBY-NC-ND\)](https://creativecommons.org/licenses/by-nc-nd/4.0/), where it is permissible to download and share the work provided it is properly cited. The work cannot be changed in any way or used commercially without permission from the journal.

DOI: [10.1097/GOX.0000000000004517](https://doi.org/10.1097/GOX.0000000000004517)

Disclosure: The authors have no financial interest to declare in relation to the content of this article.

fracture was fixed with K-wires. A fish mouth incision was created at the fingertip. Venous congestion was identified 24 hours later. Five days after continuous NPWT, the finger remained congestive but viable (Fig. 1).

All patients were started on anticoagulation treatment.⁵ No complications, other than venous congestion, were identified during the hospitalization or follow-up period. At the time of the last follow-up, none of the patients needed a blood transfusion, no complications were seen secondary to the anticoagulation therapy, and all three fingers healed with normal function.

NPWT was used for an average of 4.3 (3–5) days, the average pressure was 83.3 (–75, –100) mm Hg, and intensity was low in all three cases. We followed our prior setting.⁵ NPWT was applied around the injured finger and the next one. NPWT foam was used in the volar and dorsal aspects of the finger, leaving the fingertip uncovered to allow the surgeon to evaluate the graft. Case number 3

had a fish mouth incision to promote active bleeding. In all cases, reservoirs had less than 50 mL.

DISCUSSION

Microsurgical skills have been established as the most important aspect of a successful replantation. Also important is the ratio of arteries and veins repaired to avoid major complications such as venous congestion, as described by Lee et al.⁶ In this retrospective study of 162 patients, the authors conclude that for every artery repaired, two veins need to be repaired for successful finger replantation.

Venous congestion is one of the strongest predictors of digit loss after replantation. Several treatment options for this complication have been described, including leech therapy. Arami et al.² reported the use of leech therapy in 25 patients, and 11 of the digits survived. However, complications such as active bleeding requiring blood transfusion and local infection can place limitations on their use.

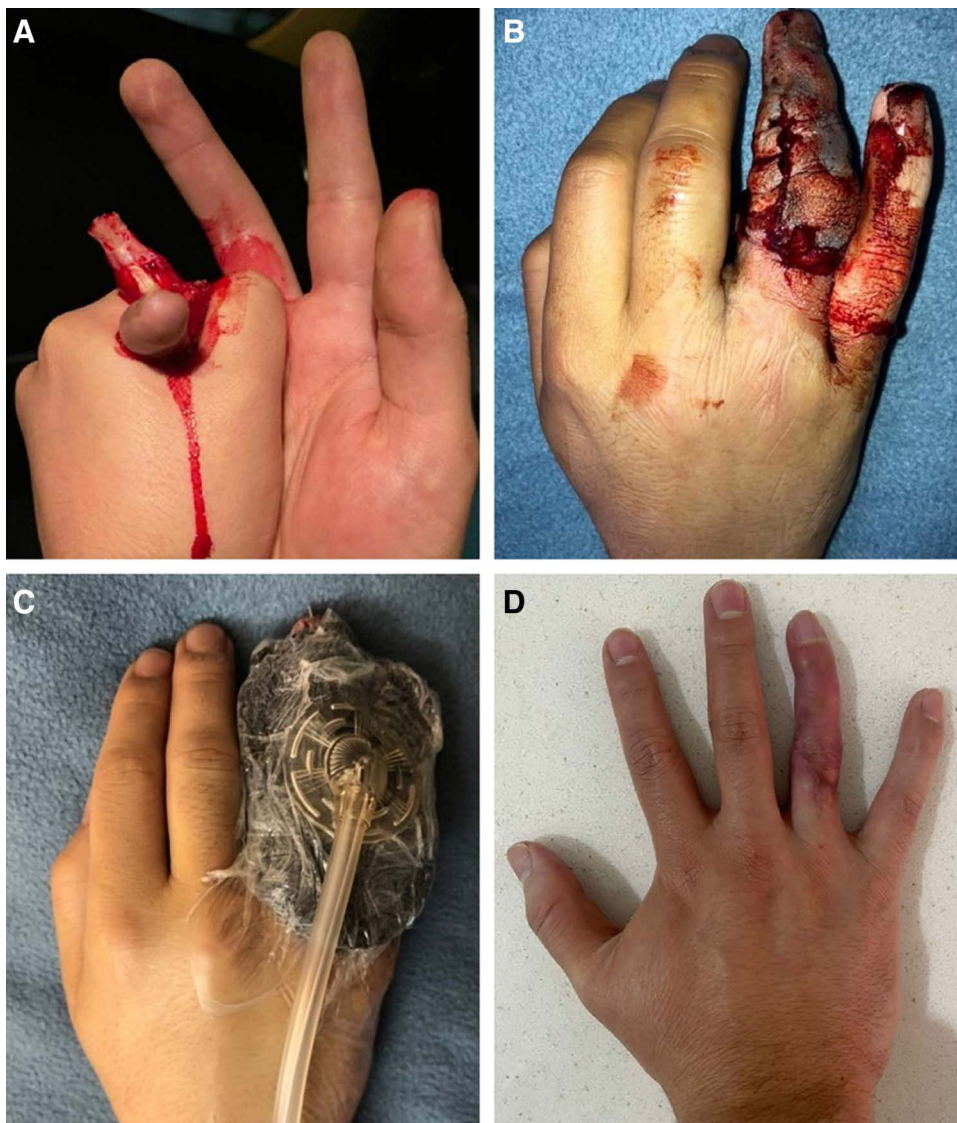


Fig. 1. Ring avulsion. A, Initial presentation. B, Postoperative with venous congestion. C, Negative pressure wound therapy (NPWT) was applied. D, 1-year follow-up.

Digital “milking technique” leading to active bleeding of the pulp has also shown favorable results as described by Etoz et al.⁷

The use of NPWT in venous congestion following finger replantation was first described by Aydin et al.⁸ A custom-made subatmospheric device was created within a fingertip amputation of the index finger using this device. The patient had a full recovery. Matsushita et al.⁹ described the use of NPWT with a device specifically designed to treat pressure ulcers. A thumb pulp amputation was treated with -50 to -200 mm Hg for a period of 7 days with evidence of granulation tissue at the wound base. Fok and Fung¹⁰ reported the use of NPWT in two patients with venous congestion following finger replantation of a thumb and index finger. Wall suction was continuous and set at -120 mm Hg for 7 days with favorable results.

There is a big gap between applied NPWT and reexploration of a congestive finger; in our cases, NPWT was applied when the venous congestion was identified and followed by direct visualization of the fingertip, temperature control every 2 hours for the first 24 hours, every 6 hours for the first 2 days, and every 12 hours for the remaining 3 days. With the improvement of the aspect of the fingertip, we maintained the use of NPWT, and at the end of our observation, all the fingers had integration of the amputated graft, but further studies should be done to answer this question.

The strength of this case series is the standardization of NPWT. Three patients diagnosed with venous congestion following replantation showed excellent results after the use of a standardized NPWT protocol despite the variability in ischemia times and types of injury. NPWT is a low-cost solution that is easy to apply, less logistically burdensome than leech therapy, and easy to monitor. These data show that standardized NPWT can be used in venous congestion after finger replantation after a clean cut or after a ring finger avulsion with excellent results.

A notable limitation of this series is the variability in the types of injuries seen in our three patients. All digits were amputated at different levels with variable ischemia times as well as variable mechanisms of injury. Usually, our microsurgical technique is one artery and two veins. Unfortunately, in cases one and two, just one vein was repaired, which could have led to venous congestion. However, the standardization of NPWT was the one thing they all had in common, which highlights the benefit of NPWT. It is reasonable to think that regardless of the size of a cohort, it would be challenging to gather sufficient

replantation data to control for these variables, and it would require a heroic multicenter effort to determine how these factors can impact venous congestion following replantation. Another limitation is that we lack information about the cost of the NPWT compared with other types of treatment for venous congestion.

CONCLUSIONS

Vascular complications following finger replantation can be secondary to arterial congestion or venous congestion. Adequate surgical technique is the most important factor to avoid any complications. NPWT is an excellent treatment option following the identification of venous congestion in digit replantation.

Jorge I. Quintero, MD

Fundación Santa Fe de Bogotá

Carrera 7n 123-35 piso 10

Bogotá 110111, Colombia

E-mail: jorge.quintero@fsfb.org.co

REFERENCES

1. Shaterian A, Sayadi LR, Anderson A, et al. Etiology and survival of secondary revascularizations after hand and digit replantations. *J Hand Microsurg.* 2020;12:111–115.
2. Arami A, Gurevitz S, Palti R, et al. The use of medicinal leeches for the treatment of venous congestion in replanted or revascularized digits. *J Hand Surg Am.* 2018;43:949.e1–949.e5.
3. Iglesias M, Butrón P. Local subcutaneous heparin as treatment for venous insufficiency in replanted digits. *Plast Reconstr Surg.* 1999;103:1719–1724.
4. Askari M, Fisher C, Weniger FG, et al. Anticoagulation therapy in microsurgery: a review. *J Hand Surg Am.* 2006;31:836–846.
5. Quintero JI, Cárdenas LL, Achury AC, et al; FSFB Hand and Microsurgery Research Group. Negative pressure wound therapy as a salvage procedure in venous congestion of microsurgical procedures. *Plast Reconstr Surg Glob Open.* 2021;9:e3725.
6. Lee BI, Chung HY, Kim WK, et al. The effects of the number and ratio of repaired arteries and veins on the survival rate in digital replantation. *Ann Plast Surg.* 2000;44:288–294.
7. Etöz A, Karaca K, Ozgenel Y. Milking technique for reimplanted digits with insufficient venous drainage. *Tech Hand Up Extrem Surg.* 2005;9:122–123.
8. Aydin U, Ozbek S, Akin S, et al. Custom subatmospheric dressing for fingertip injuries. *Tech Hand Up Extrem Surg.* 2011;15:104–105.
9. Matsushita Y, Fujiwara M, Nagata T, et al. Negative pressure therapy with irrigation for digits and hands: pressure measurement and clinical application. *Hand Surg.* 2012;17:71–75.
10. Fok MWM, Fung BKK. A novel technique: subatmospheric pressure wound therapy for treating venous congestion of replanted digits. *JPRAS Open.* 2015;6:44–48.