

Modified Gott shunt to avoid left ventricular overload and cerebral hypoperfusion during distal aortic arch surgery

Sandro Gelsomino, MD, PhD, FESC,^a Elham Bidar, MD,^a Jayant S. Jainandunsing, MD, PhD,^b Ignace F. J. Tielliu, MD, PhD,^c Roberto Lorusso, MD, PhD,^a Daniel Johnson, PhD,^a Jos G. Maessen, MD, PhD,^a and Ehsan Natour, MD, PhD,^a *Maastricht and Groningen, The Netherlands*

ABSTRACT

We present a simple solution to address—at the same time—the issue of spinal perfusion, overload on the left ventricle, and brain perfusion during complex distal arch and descending aortic surgery. It is a modification of a passive Gott shunt that includes an extra 10-mm tube interposed between the side port of the ascending aorta cannula and the left subclavian artery. This technique may represent an extra option for surgeons during complex aortic surgery to maintain satisfactory distal perfusion, to reduce the cardiac load, and to provide adequate perfusion to the brain. (*J Vasc Surg Cases and Innovative Techniques* 2019;5:65-7.)

Keywords: Aorta; Aortic arch; Aneurysm; Shunt; Perfusion

Spinal cord injury, overload on the left ventricle, and increased cerebral blood flow pressure above the aortic clamp are well-known challenges in thoracoabdominal aortic surgery.¹ We present a successful repair of a pseudoaneurysm of the distal arch in a patient who had previously undergone coarctation surgery and in whom a modified Gott shunt was used to ensure, at the same time, spine and brain perfusion during the beating heart procedure as well as to gain effective decompression of the left side of the heart. Institutional Review Board approval was waived, and informed consent of the patient was obtained.

CASE REPORT

A 57-year-old woman was referred to our hospital with complaints of dyspnea. Her prior history included a coarctation repair (interposition technique) during childhood through lateral left thoracotomy. A computed tomography scan revealed a large aortic arch pseudoaneurysm at the site of the proximal anastomosis (Fig 1) with extravasation of contrast material at the base of the left subclavian artery at the anastomosis site. The case was discussed by a multidisciplinary team including a cardiac surgeon, a vascular surgeon, and one interventional radiologist, who agreed in judging the anatomy not suitable

for endovascular repair. Conventional repair using cardiopulmonary bypass under circulatory arrest was at first planned as a primary treatment of choice. Nonetheless, because of the excellent exposure of both ascending and descending aorta through left anterolateral thoracotomy, we switched to off-pump distal aortic arch “clamp and sew” repair.² For monitoring of cerebral function, multimodal physiologic monitoring and near-infrared spectroscopy were employed.

A single dose of heparin (5000 units) was administered. The ascending aorta was cannulated with a 22F cannula (Edwards Lifesciences, Irvine, Calif); a second aortic cannula (22F; Edwards Lifesciences) was similarly used to cannulate the descending aorta, and it was connected to the other by a 9.5-mm tube (length, 400 mm). The side port of the ascending cannula was then connected to a 10-mm shunt placed into the left subclavian artery, making a small incision within a double 6-0 Prolene purse-string suture (Fig 2).

Flow was measured by incorporating a flow meter probe between the cut halves of the shunt. The flow ranged from 180 to 230 mL/min; proximal aortic pressure varied from 110 to 140 mm Hg. No difference was detected between right and left radial pressures (systolic, 110-120 mm Hg; diastolic, 70-72 mm Hg). Systolic and diastolic femoral pressures ranged between 110 to 125 mm Hg and 70 to 75 mm Hg, respectively.

The aorta was cross-clamped between the left subclavian artery and the carotid artery to ensure an optimal landing zone for the new prosthesis. A second clamp was placed proximal to the descending cannula. After aneurysm resection, a 24-mm straight woven Dacron prosthesis (Vascutek Gelweave Valsalva; Terumo CVS, Inchinnan, United Kingdom) was used. It was anastomosed to the distal aortic arch at the base of the left subclavian artery (end to end). Subsequently, the clamp on the aortic arch was released and placed on the prosthesis to restore the physiologic flow into the left subclavian artery. Finally, the distal anastomosis was performed. The aorta was deaired and unclamped. The prosthesis was covered with the remaining tissue. Throughout the procedure, the patient remained hemodynamically stable. Cross-clamp time was 43 minutes.

From the Department of Cardiothoracic Surgery, Maastricht University Hospital, Maastricht^a; and the Department of Anesthesiology,^b and Division of Vascular Surgery,^c University Medical Center Groningen, Groningen.

Author conflict of interest: none.

Correspondence: Sandro Gelsomino, MD, PhD, FESC, Department of Cardiothoracic Surgery, Cardiovascular Research Institute Maastricht-CARIM, Universiteitssingel 50, 6229 ER Maastricht, The Netherlands (e-mail: sandro.gelsomino@maastrichtuniversity.nl).

The editors and reviewers of this article have no relevant financial relationships to disclose per the Journal policy that requires reviewers to decline review of any manuscript for which they may have a conflict of interest.

2468-4287

© 2018 The Authors. Published by Elsevier Inc. on behalf of Society for Vascular Surgery. This is an open access article under the CC BY-NC-ND license (<http://creativecommons.org/licenses/by-nc-nd/4.0/>).

<https://doi.org/10.1016/j.jvscit.2018.11.005>

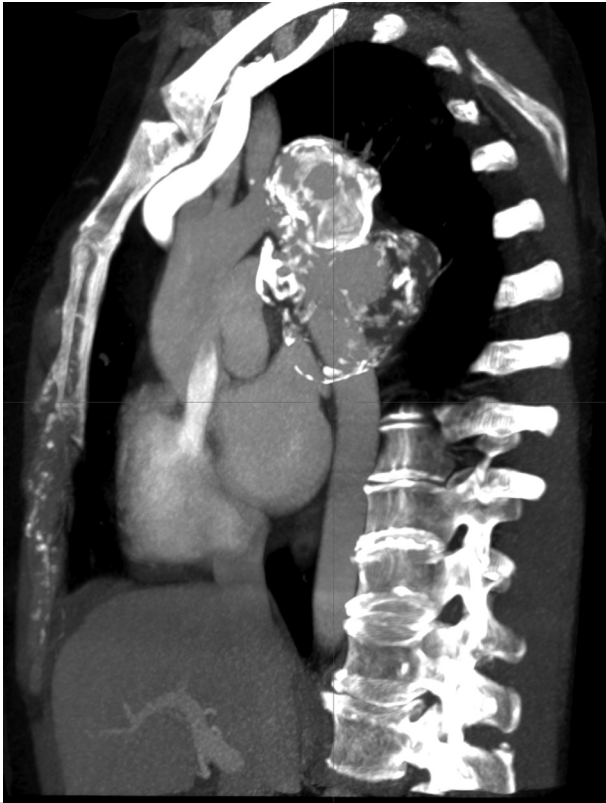

Fig 1. Computed tomography angiogram depicts the aneurysm preoperatively.

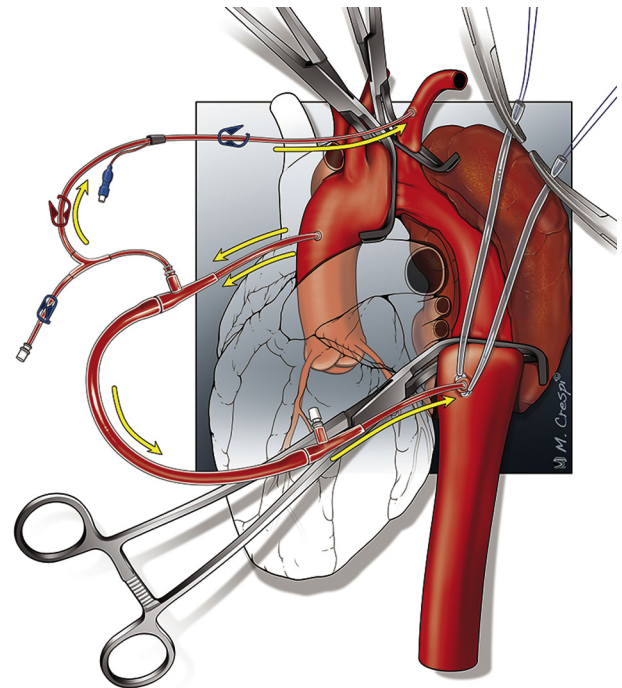


Fig 2. Scheme of the modified Gott shunt through an anterolateral thoracotomy. The *yellow arrows* show the direction of the flow.

The postoperative course was uneventful. **Fig 3** shows the control computed tomography image before discharge on postoperative day 10.

DISCUSSION

Surgical repair of aneurysms of the distal arch and thoracoabdominal aorta still represents a great challenge for the surgeon. Spinal cord injury, which remains the most devastating complication despite advances in spinal cord protection, occurs with an incidence ranging between 8% and 28%.³ Several distal perfusion techniques have been developed to limit this complication, including passive shunt (Gott shunt), left-sided heart bypass, and partial cardiopulmonary bypass,^{4,5} all presenting advantages and drawbacks.⁶

Another serious concern is the rise of pressure above the cross-clamp, leading to an increase in cerebral blood flow and cerebrospinal fluid pressure during aortic cross-clamping.⁷ For this reason, a left subclavian shunt is employed to protect the brain during distal aortic surgery, although some authors cast doubt on its actual effectiveness.⁸

We present a simple solution to address, at the same time, either the spinal perfusion or the increase of pressure above the aortic clamp during a complex aortic aneurysm repair. It is a simple modification of a passive

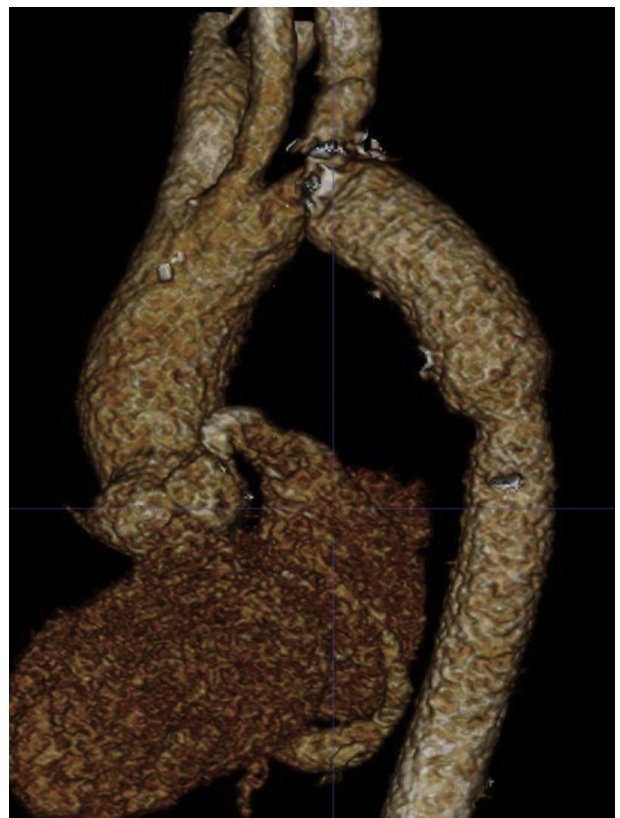

Fig 3. Predischarge three-dimensional computed tomography image shows complete repair of the aneurysm with no extravascular leakage.

Gott shunt that includes an extra 10-mm shunt interposed between the side port of the ascending cannula and the left subclavian artery. The favorable aortic exposure through the left thoracotomy made us prefer this approach to a passive axillofemoral shunt that would have required extra incisions for vessel exposure.

The passive shunt flow was able to maintain a satisfactory distal perfusion and to reduce the cardiac load that may lead to progressive deterioration of cardiac function in accordance with previous studies.⁹ In addition, the extra small shunt provided adequate antegrade brain perfusion through the left subclavian artery.

Furthermore, we might also postulate that keeping the pressure in the subclavian artery low could also have helped enhance spinal perfusion by increasing flow in the anterior spinal artery (which is a branch of the vertebral artery) and in the internal mammary artery (which contributes to spinal cord blood supply through its anastomoses with the intercostal arteries). Furthermore, the flow into the subclavian artery ensures, through the vertebral and basilar branches, the perfusion of the cerebellum that is not monitored by multimodal physiologic monitoring and near-infrared spectroscopy.

This modified shunt might be an extra technical option for aortic surgeons. The technique can be especially helpful in the case of patients who are likely to undergo prolonged (>30 minutes) aortic clamping, which significantly increases the risk of spinal cord hypoperfusion and ischemia.¹⁰

Great care must be taken in hemodynamically unstable patients, those with a diseased aorta, and the elderly with a more friable aortic wall. Moreover, it is mandatory to check the shunt function during surgery to assess the adequacy of the distal flow and to carefully monitor the distal aortic pressure and the adequacy of distal aortic perfusion.

In addition, the size of the cannula must be carefully chosen, balancing the goals of preventing paraplegia and end-organ dysfunction with potential risks linked to this procedure: technical difficulty with cannulation, vessel damage, bleeding from the cannulation site, aortic calcification, and risk of embolic stroke.

CONCLUSIONS

The suggested modified shunt is a simple, effective, and inexpensive technique. It requires only partial anticoagulation and does not need specific perfusion personnel. It might represent a valid extra aid for aortic surgeons.

REFERENCES

1. Cooley DA, Golino A, Frazier OH. Single-clamp technique for aneurysms of the descending thoracic aorta: report of 132 consecutive cases. *Eur J Cardiothorac Surg* 2000;18:162-7.
2. Acher C, Wynn M. Paraplegia after thoracoabdominal aortic surgery: not just assisted circulation, hypothermic arrest, clamp and sew, or TEVAR. *Ann Cardiothorac Surg* 2012;1:365-72.
3. Greenberg RK, Lu Q, Roselli EE, Svensson LG, Moon MC, Hernandez AV, et al. Contemporary analysis of descending thoracic and thoracoabdominal aneurysm repair: a comparison of endovascular and open techniques. *Circulation* 2008;118:808-17.
4. Gott VL, Whiffen JD, Dutton RC. Heparin bonding on colloidal graphite surfaces. *Science* 1963;142:1297-8.
5. Svensson LG, Hess KR, Coselli JS, Safi HJ. Influence of segmental arteries, extent, and aortofemoral bypass on postoperative paraplegia after thoracoabdominal aortic operations. *J Vasc Surg* 1994;20:255-62.
6. Kawaharada N, Ito T, Higami T. Spinal cord protection for descending or thoracoabdominal aortic aneurysm repair. In: Grundmann RT, editor. *Diagnosis, screening and treatment of abdominal, thoracoabdominal and thoracic aortic aneurysms*. Rijeka: InTech; 2011.
7. Saether OD, Juul R, Aadahl P, Stromholm T, Myhre HO. Cerebral haemodynamics during thoracic- and thoracoabdominal aortic aneurysm repair. *Eur J Vasc Endovasc Surg* 1996;12:81-5.
8. Girardi LN, Krieger KH, Mack CA, Lee LY, Tortolani AJ, Isom OW. Does cross-clamping the arch increase the risk of descending thoracic and thoracoabdominal aneurysm repair? *Ann Thorac Surg* 2005;79:133-7; discussion: 137-8.
9. Verdant A, Cossette R, Page A, Baillot R, Dontigny L, Page P. Aneurysms of the descending thoracic aorta: three hundred sixty-six consecutive cases resected without paraplegia. *J Vasc Surg* 1995;21:385-90; discussion: 390-1.
10. Backer CL, Stewart RD, Kelle AM, Mavroudis C. Use of partial cardiopulmonary bypass for coarctation repair through a left thoracotomy in children without collaterals. *Ann Thorac Surg* 2006;82:964-72.

Submitted Sep 5, 2018; accepted Nov 10, 2018.