



CLINICAL CASE

Refractory Celiac Disease Type II: A Case Report that Demonstrates the Diagnostic and Therapeutic Challenges



Alexandra Fernandes^{a,*}, Ana Margarida Ferreira^a, Rosa Ferreira^{a,1},
Sofia Mendes^a, Cláudia Agostinho^a, Nuno Almeida^a, Pedro Figueiredo^a,
Manuela Ferreira^a, Pedro Amaro^a, Lígia Prado e Castro^b, Carlos Sofia^a

^a Gastroenterology Department, Centro Hospitalar e Universitário de Coimbra, Coimbra, Portugal

^b Pathology Department, Centro Hospitalar e Universitário de Coimbra, Coimbra, Portugal

Received 13 July 2015; accepted 18 August 2015

Available online 26 September 2015

KEYWORDS

Celiac Disease;
Cladribine;
Enteropathy-
Associated T-Cell
Lymphoma;
Hematopoietic Stem
Cell Transplantation

Abstract Refractory celiac disease is an uncommon but serious complication of celiac disease. We describe a case of a severe refractory celiac disease type II, complicated with ulcerative jejunoileitis, in a 68 years old female, unresponsive to consecutive treatments with budesonide, prednisolone, cladribine and autologous stem cell transplantation. The patient maintained severe malnutrition, advanced osteoporosis, anaemia, vitamin deficiencies and hydro-electrolytic imbalances, necessitating consecutive hospitalizations for total parenteral nutrition. The patient also developed life-threatening complications, namely respiratory and urinary septic shock and also episodes of haemorrhagic shock secondary to ulcerative jejunoileitis. The progression to enteropathy associated T-cell lymphoma was never demonstrated, but the patient died 7 years after the diagnosis due to a septic shock secondary to a nosocomial pneumonia and osteomyelitis related to a spontaneous hip fracture. This case highlights the difficulties in the diagnostic process, therapeutic management and surveillance of this rare condition associated with very poor prognosis.

© 2015 Sociedade Portuguesa de Gastreenterologia. Published by Elsevier España, S.L.U. This is an open access article under the CC BY-NC-ND license (<http://creativecommons.org/licenses/by-nc-nd/4.0/>).

* Corresponding author.

E-mail address: xanafmuc@hotmail.com (A. Fernandes).

¹ Present address: Gastroenterology Department, Hospital Beatriz Ângelo, Loures, Portugal.

PALAVRAS-CHAVE

Cladribina;
Doença Celíaca;
Transplante de
Células Estaminais
Hematopoiéticas;
Linfoma de Células T
Associado a
Enteropatia

Doença Celíaca Refratária Tipo II: Um Caso Clínico que Ilustra os Desafios Diagnósticos e Terapêuticos

Resumo A doença celíaca refratária é uma complicação rara mas muito severa da doença celíaca. Apresentamos o caso de uma doente de 68 anos, com doença celíaca refratária tipo II complicada de jejunoileíte ulcerativa, que não respondeu a tratamentos sucessivos com budesonido, prednisolona, cladribina e transplante autólogo de medula óssea. A doente manteve desnutrição e osteoporose severas, deficiências vitamínicas e desequilíbrios hidro-eletrolíticos, necessitando de múltiplas hospitalizações para receber nutrição parentérica total. Também desenvolveu diversas complicações potencialmente fatais nomeadamente sépsis com origem respiratória e urinária e choque hemorrágico secundário à jejunoileíte ulcerativa. Contudo, nunca se demonstrou a presença de um linfoma de células T. A doente faleceu 7 anos após o diagnóstico devido a choque séptico secundário a pneumonia nosocomial e osteomielite relacionada com fratura espontânea da anca. Este caso ilustra as dificuldades sentidas no decurso do diagnóstico, terapêutica e vigilância desta entidade clínica rara, a qual está associada a um péssimo prognóstico.

© 2015 Sociedade Portuguesa de Gastreenterologia. Publicado por Elsevier España, S.L.U. Este é um artigo Open Access sob a licença de CC BY-NC-ND (<http://creativecommons.org/licenses/by-nc-nd/4.0/>).

1. Introduction

Celiac disease (CD) is a chronic immune-mediated enteropathy precipitated by exposure to dietary gluten in genetically predisposed individuals. It is a common autoimmune disease affecting around 1% of the general population.¹ The diagnosis is often easy in the presence of classic symptoms of malabsorption, positive celiac-specific antibodies and villous atrophy in duodenal biopsies. However, some patients, mainly those diagnosed in the adulthood, can only present atypical or extra intestinal manifestations (e.g. iron deficiency, fatigue, abnormal liver function tests, bone disease, skin disorders, peripheral neuropathy, depression), and the specific serology can be negative.^{2,3} Strict life-long gluten free diet (GFD) is the only treatment available, leading to clinical and mucosal recovery in most patients, but a small minority does not show clinical improvement upon GFD.^{1,4} Refractory CD (RCD) is a rare and severe condition, developing in 1–5% of the adult-onset CD patients, and is defined as persistent or recurrent symptoms and signs of malabsorption with small intestinal villous atrophy despite a strict GFD for more than 12 months in the absence of other causes of villous atrophy.^{5,6} RCD is divided in two types based on the absence (Type I) or presence (Type II) of abnormal intraepithelial lymphocytes (IEL).⁷ Type II RCD (RCD-II) has limited therapeutic options, often complicates with severe malnutrition, ulcerative jejunoileitis and enteropathy associated T-cell lymphoma (EATL).^{7,8}

We report an unfavourable case of RCD-II, describing the difficulties in the initial diagnosis, the consecutive failures of distinct therapeutic options, and the multiple complications that finally led to the death of the patient.

2. Case report

We present the case of a 68 years old white female, diagnosed with CD in 2008, when she was 61 years old, and whom

never become asymptomatic despite strict GFD. The diagnosis was made considering characteristic histologic features, despite negative specific-CD serology. She had no other comorbidities apart from chronic depression and there was no family history of CD or other autoimmune diseases. The patient presented to our department for the first time in February 2010 complaining of chronic diarrhoea, vomiting, anorexia, asthenia and weight loss, despite 2 years of GFD. She showed severe malnutrition (body mass index – BMI: 12 kg/m², extreme hypoalbuminemia), threatening hydro-electrolytic imbalances (hypomagnesaemia, hypokalaemia, hypophosphatemia, hypocalcaemia), normocytic anaemia (haemoglobin of 8.1 g/dL), coagulopathy (INR of 8.2), vitamin deficiencies and severe osteoporosis. The adherence to GFD was revised and ensured. Upper gastrointestinal (UGI) endoscopy with duodenal biopsies was repeated, showing endoscopic aspects compatible with CD (Fig. 1). A marked villous atrophy, with villous to crypt ratio of <1/1 and increased IEL were observed – Marsh-Oberhuber stage 3b (Fig. 2). These biopsies also allowed the diagnosis of giardiasis that was successfully treated with metronidazole (confirmed with repeated biopsies after treatment). Ileocolonoscopy was performed, and despite absence of mucosal changes random biopsies demonstrated the presence of lymphocytic colitis. Apart from these two parallel diagnoses that could contribute to the refractory symptoms, careful investigation and exclusion of other entities that could be the cause of symptoms and villous atrophy was made (Table 1). Specific-CD serology was repeated and it was negative once again. HLA typing was determined and revealed a DQ2/DQ8 compound heterozygote. Immunohistochemical analysis was performed in duodenal biopsies and revealed more than 50% of aberrant IELs, which were CD3+, but mostly CD8- and CD30- (Fig. 3), being compatible with a RCD-II, with no evidence of EATL. The aberrant pattern was confirmed by detection of T-cell receptor chains clonal rearrangement, performed at the Celiac Centre Amsterdam, VU University Medical Centre. A CT scan

Table 1 Other causes of non-responsive celiac disease (NRCD) and villous atrophy in adults that were investigated/excluded.

Differential diagnosis	Investigation/Evidence
<i>Other causes of NRCD</i>	
Gluten contamination	Exclusion by extensive nutritional revision (expert dietician); hospitalization
Microscopic colitis	Successfully treated with resolution on repeated colonic biopsies
Bacterial overgrowth	Unresponsive to multiple antibiotic courses
Lactose intolerance	Unresponsive to lactose eviction
Pancreatic insufficiency	Normal faecal elastase
Irritable bowel syndrome	Clinical course and severity not compatible
<i>Other causes of duodenal villous atrophy</i>	
Giardiasis	Successfully treated; resolution on repeated duodenal biopsies
Crohn's disease	Negative ASCA and ANCA; Histology not compatible
Infectious enteritis	Consecutive negative serologies and faecal cultures
Parasitic infestation	Consecutive negative stool parasitic analysis
AIDS enteropathy	Negative HIV 1 + 2
Eosinophilic gastroenteritis	Histology not compatible
Whipple disease	Histology not compatible
Intestinal tuberculosis	Absence of <i>Micobacterium tuberculosis</i> in duodenal biopsies; Negative QuantiFERON
Collagenous sprue	Absence of subepithelial collagen deposition band
Tropical sprue	Absence of travel history to endemic areas and no improvement with folic acid and antibiotics
Intestinal lymphoma	Normal $\beta 2$ microglobulin; Exclusion on intraoperative enteroscopy and jejunal biopsies
Adult-onset autoimmune enteropathy ^a	Significant intraepithelial lymphocytosis is against this diagnosis (it would be expected reduced number of IEL); positive HLA DQ2/DQ8 is not typical of this condition
Hypogammaglobulinemia	Normal serum immunoglobulin and protein electrophoresis; no major changes in thoracic CT scan; no history of recurrent infections
Small-bowel ischaemia	Histology not compatible
Drug-associated enteropathy	No history of suspicious medication

^a Determination of anti-enterocyte or anti-goblet cell antibodies was not possible in our institution.

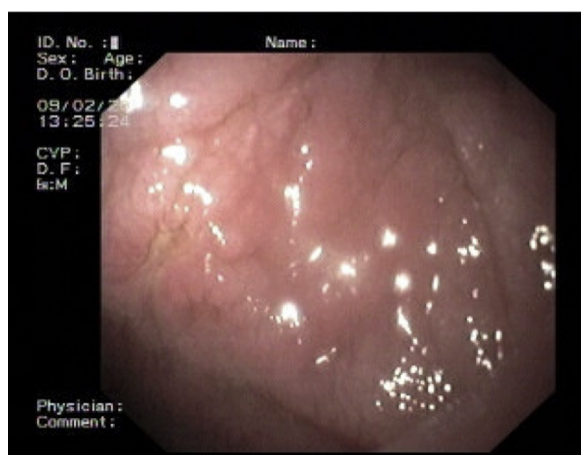

Figure 1 Upper gastrointestinal endoscopy, showing classic endoscopic signs of villous atrophy such as loss of Kerckring's folds in the duodenum, fissuring with a mosaic pattern, and also a small ulcer.

enteroclysis identified bowel-wall thickening in the jejunum and ileum, mesenteric lymphadenopathy and prominent mesenteric vessels resembling the comb sign (Fig. 4). Unfortunately, the double balloon enteroscopy performed was not

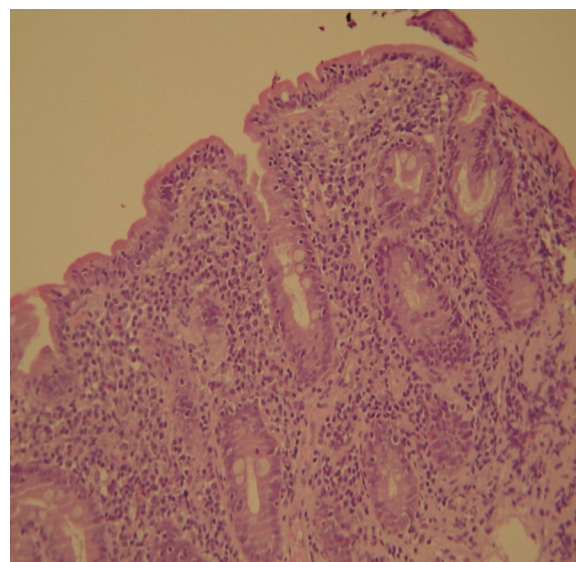


Figure 2 Biopsies from the distal duodenum (H&E) showing severe villous atrophy together with intraepithelial lymphocytosis (>40 IELs/100 enterocytes) and crypt hyperplasia - Marsh-Oberhuber type 3b.

satisfactory and could not find these abnormalities. Additionally, the videocapsule enteroscopy revealed flat mucosa, scalloping effect and multiple small ulcers, particularly in the jejunum (Fig. 5). Apart from total parenteral nutrition (TPN) with correction of ionic and vitamin deficiencies, and after antibiotic therapy to treat the giardiasis, the patient started budesonide (9 mg/i.d.) that was adequate not only for the RCD but also for the lymphocytic colitis treatment, yet due to insufficient improvement prednisolone was initiated (1 mg/kg weight). The clinical response was unsatisfactory and consecutive hospitalizations were necessary to perform TPN and hydro-electrolytic corrections. Due to lack of response to budesonide and prednisolone an intraoperative enteroscopy was performed and an ulcerative jejunoileitis was identified, corroborating the diagnosis of RCD-II. The case was discussed and reviewed by experts in CD at Celiac Centre Amsterdam, VU University Medical Centre that agreed with the diagnosis of RCD-II and suggested treatment with cladribine, which was performed in October 2010 (single cycle, intravenous, 0.1 mg/kg/day for 5 days), with good clinical, analytical and nutritional response (BMI: 20 kg/m²), keeping, however, a Marsh-Oberhuber stage 3b. In April 2011, 6 months after cladribine, there was a new clinical deterioration and TPN was again initiated. The patient was then proposed for autologous stem cell transplantation (ASCT), performed in October 2011, with no histological improvement but with some clinical stability until December 2013. Since then the patient was consecutively hospitalised due to severe malnutrition (BMI < 14 kg/m²), vitamin deficiencies, hydro-electrolytic imbalances and anaemia, necessitating TPN and blood transfusions, and also respiratory and urinary infections complicated with septic shock, and episodes of haemorrhagic shock. There was also a spontaneous fracture of the femur neck, secondary to severe osteoporosis, treated with a dynamic hip screw (DHS) that infected subsequently and needed to be removed. The patient died 7 years after the diagnosis of CD, due to a respiratory septic shock, presenting with severe malnutrition (BMI 10 kg/m²), without evidence of EATL on CT scan enteroclysis and PET scan.

3. Discussion

Celiac disease is a common autoimmune condition that is generally associated with good prognosis as the compliance of a strict GFD leads to clinical and mucosal recovery.¹ When diagnosed in adults, particularly above the age of 50, the presentation is often atypical and lack of improvement under GFD is more likely.⁴ Iron deficiency and extraintestinal manifestations (like bone disease and depression) can be the only presenting signs of the disease, and definitive diagnosis is normally delayed.⁹ At this stage, the diagnostic workup is significantly more complex, especially in cases of seronegative CD. In our particular case, although the clinical suspicion and the first duodenal biopsies (taken while the patient was on normal diet) corroborated the diagnosis of CD, there were two major problems – negative celiac-specific antibodies performed while on a gluten-containing diet and unresponsiveness to GFD. In cases of non-responsive CD (NRCD), after ensuring strict adherence to GFD, the first

step is to confirm the initial diagnosis of CD and exclude other entities that mimic CD symptoms and other causes of villous atrophy. The positivity of celiac-specific antibodies is one of the parameters used to confirm the diagnosis, but serology may be negative in 5–16% of patients with biopsy-confirmed CD.^{2,3,5} This was the case of our patient that despite negative specific serology presented typical histology and high clinical suspicion. In these ambiguous seronegative CD cases HLA typing may help to rule out or confirm the diagnosis, as HLA-DQ2 (~95%) or HLA-DQ8 (~5%) are present in almost all patients with CD.^{10,11} So, CD is excluded for patients who are negative for HLA-DQ2 or HLA-DQ8, considering its high negative predictive value (>99%).^{12,13} In fact, our patient presented HLA DQ2/DQ8 compound heterozygosity, supporting the CD diagnosis.

NRCD is common, affecting from 7% to 30% of patients under GFD. There are many distinct aetiologies including inadvertent gluten ingestion (the most common cause), other food intolerances, small intestinal bacterial overgrowth, microscopic colitis, pancreatic insufficiency and RCD, that makes up a small subset (approximately 10%) of NRCD.^{14–16} In fact, during the extensive investigation to exclude other potential causes of chronic diarrhoea (Table 1), we identified two concomitant entities – microscopic colitis and giardiasis – that could be responsible for some persisting symptoms, but despite being successfully treated, the severe symptoms persisted. Moreover, these are two common conditions associated with CD, particularly microscopic colitis that develops in 4% of patients with CD.⁹

RCD is almost exclusive of patients diagnosed with CD above the age of 50, and two to three times more frequent in women.⁷ Our patient had all these epidemiological features. The immunohistochemical studies as well as a T-cell receptor gene rearrangement analysis showing clonal expansion were indicative of RCD-II.⁷ This diagnosis was further supported by the presence of severe and life threatening malnutrition, protein losing enteropathy, bowel-wall thickening in the jejunum/ileum and mesenteric lymphadenopathy at CT scan enteroclysis and, most important, evidence of ulcerative jejunoileitis, that should be considered synonym of RCD-II.^{8,17,18} When there are doubts about the diagnosis in immunohistochemical and/or T-cell receptor gene rearrangement, flow cytometry is a good option, since it is able to differentiate cytoplasmatic from membranous CD3 expression and to identify other aberrant IEL with preserved CD8 expression.⁷ EATL is a threatening complication and was a major concern in this patient, considering the clinical severity and lack of sustained response to medical treatment. However, its presence was systematically excluded in multiple histological analyses. Additionally, the aberrant IELs of our patient lack CD30 expression that is associated with worse prognosis, including the development of overt EATL.¹⁹

RCD-II has a poor prognosis, with a five-year survival between 44 and 58%. The higher mortality can be largely attributed to the high risk of developing EATL, which occurs between 33% and 52% within 5 years after diagnosis.⁷ Even in the absence of EATL RCD-II is often complicated with threatening haemorrhage due to ulcerative jejunoileitis, severe malabsorption with intestinal failure and severe sepsis, as occurred in our patient.^{5,9}

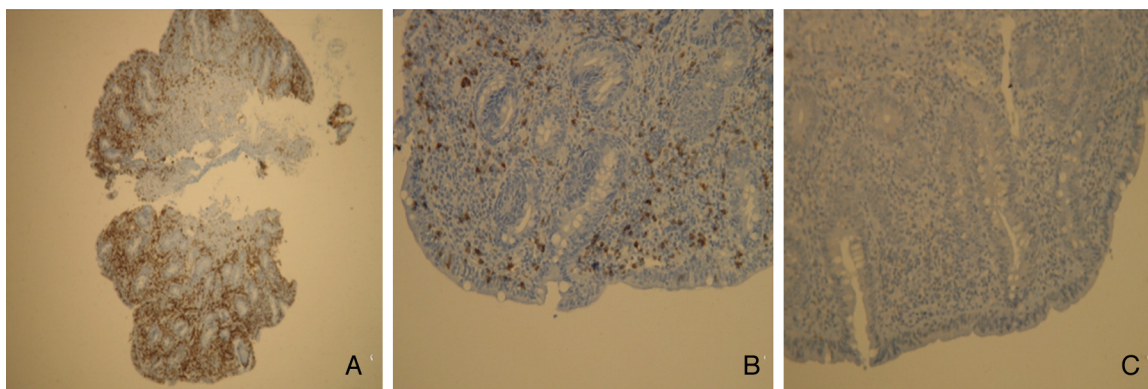


Figure 3 Immunohistochemistry images from the duodenal biopsies showing an abnormal population of IELs which are (A) CD3 positive, but (B) mostly CD8 negative and (C) CD30 negative.

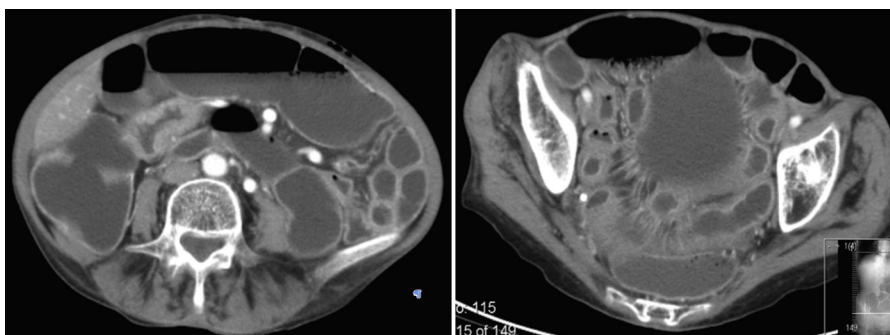


Figure 4 CT scan enteroclysis, showing bowel-wall thickening, mesenteric lymphadenopathy and prominent mesenteric vessels resembling the comb sign.

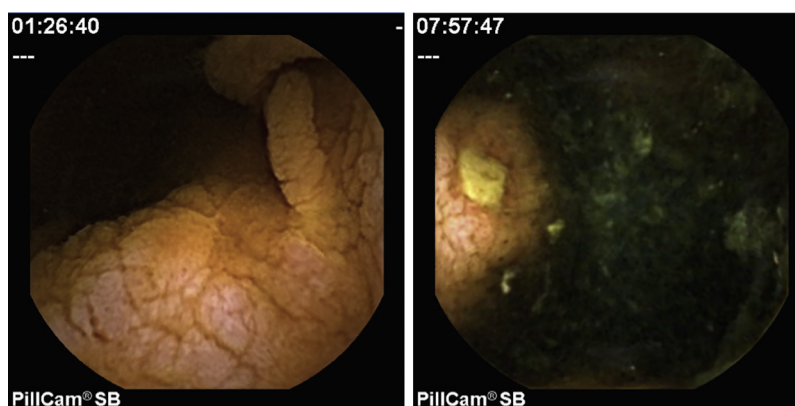


Figure 5 Videocapsule enteroscopy images showing grossly oedematous jejunum with flat mucosa, scalloping effect and a small ulcer.

As RCD-II is a rare disease, to date there is no standardised therapy, and the evidence for treatment is based on case reports, open-label observational or prospective experiences, and expert opinion.¹⁷ Apart from TPN and substitution of vitamins, that are consensual, pharmacological therapy is question of debate. Immunosuppressive drugs suggested for RCD-I include steroids, thiopurines, cyclosporine, infliximab and alemtuzumab.^{8,17} Steroids suppress clinical symptoms in RCD-I and clinical improvement is reported in up to 90% of patients.⁸ However, RCD-II is, at least in part, resistant to most therapies evaluated so far and there is

no place for immunosuppressive drugs such as azathioprine and infliximab, that could increase the risk of progression to EATL.^{4,8,17} Cladribine is equally toxic to proliferating as to nondividing lymphoid cells, and this feature is particularly interesting for the treatment of low-grade malignancies, as RCD-II is considered, and there are already some published cases with favourable results.^{7,20} We decided to use this strategy in our patient but it did not lead to sustained improvement. Finally, high-dose chemotherapy followed by ASCT has been explored for RCD-II in a pilot study from a single centre.²¹ This was our last alternative, but unfortunately

it did not bring sustained clinical or histological improvements. Interleukin-15 blockade could also be considered as an experimental therapy.²²

Surgery in RCD should be limited to the management of complications such as perforation, massive haemorrhage, high-grade obstruction, and cancer.^{8,23}

The present case also emphasises the uncertainties regarding the optimal follow-up strategy of patients with RCD-II. Regular follow-up, including UGI endoscopy with biopsies, CT scan or MR enteroclysis, and PET scan, is necessary to detect EATL as early as possible.⁷ However, the best tests for EATL surveillance and the appropriate interval between examinations are not currently established.⁸ Clinical supervision in RCD should not be limited to EATL surveillance but should also include monitoring for nutritional deficiencies and bone density measurements.

This RCD-II case demonstrates the difficulties in the diagnosis, management and surveillance of this rare condition. The therapeutic approach is complex, since there are few options, whose efficacy is not yet fully demonstrated, and which are not sufficiently validated.

In our opinion, due to rarity of RCD, these patients should be referred to specialised centres. International consensuses in these areas are urgently required in order to facilitate future therapeutic advances.

Ethical disclosures

Protection of human and animal subjects. The authors declare that the procedures followed were in accordance with the regulations of the relevant clinical research ethics committee and with those of the Code of Ethics of the World Medical Association (Declaration of Helsinki).

Confidentiality of data. The authors declare that they have followed the protocols of their work centre on the publication of patient data.

Right to privacy and informed consent. The authors declare that no patient data appear in this article.

Conflicts of interest

The authors have no conflicts of interest to declare.

Acknowledgments

Chris Mulder, MD, PhD (Department of Gastroenterology and Hepatology, Celiac Centre Amsterdam, VU University Medical Centre, Amsterdam, The Netherlands) for the complementary histological analysis and therapeutic guidance.

References

- Ludvigsson JF, Leffler DA, Bai JC, Biagi F, Fasano A, Green PH, et al. The Oslo definitions for coeliac disease and related terms. *Gut*. 2013;62:43–52.
- Lewis NR, Scott BB. Meta-analysis: deamidated gliadin peptide antibody and tissue transglutaminase antibody compared as screening tests for coeliac disease. *Aliment Pharmacol Ther*. 2010;31:73–81.
- Rashtak S, Ettore MW, Homburger HA, Murray JA. Comparative usefulness of deamidated gliadin antibodies in the diagnosis of celiac disease. *Clin Gastroenterol Hepatol*. 2008;6:426–32, quiz 370.
- Rubio-Tapia A, Kelly DG, Lahr BD, Dogan A, Wu TT, Murray JA. Clinical staging and survival in refractory celiac disease: a single center experience. *Gastroenterology*. 2009;136:99–107, quiz 352–353.
- Rubio-Tapia A, Hill ID, Kelly CP, Calderwood AH, Murray JA, American College of Gastroenterology, et al. ACG clinical guidelines: diagnosis and management of celiac disease. *Am J Gastroenterol*. 2013;108:656–76, quiz 77.
- Tack GJ, Verbeek WH, Al-Toma A, Kuik DJ, Schreurs MW, Visser O, et al. Evaluation of cladribine treatment in refractory celiac disease type II. *World J Gastroenterol*. 2011;17:506–13.
- Nijeboer P, van Wanrooij RL, Tack GJ, Mulder CJ, Bouma G. Update on the diagnosis and management of refractory coeliac disease. *Gastroenterol Res Pract*. 2013;2013:518483.
- Malamut G, Afchain P, Verkarre V, Lecomte T, Amiot A, Damotte D, et al. Presentation and long-term follow-up of refractory celiac disease: comparison of type I with type II. *Gastroenterology*. 2009;136:81–90.
- Kelly CP, Bai JC, Liu E, Leffler DA. Advances in diagnosis and management of celiac disease. *Gastroenterology*. 2015;148:1175–86.
- Rubio-Tapia A, Rahim MW, See JA, Lahr BD, Wu TT, Murray JA. Mucosal recovery and mortality in adults with celiac disease after treatment with a gluten-free diet. *Am J Gastroenterol*. 2010;105:1412–20.
- Kaukinen K, Partanen J, Maki M, Collin P. HLA-DQ typing in the diagnosis of celiac disease. *Am J Gastroenterol*. 2002;97:695–9.
- Ludvigsson JF, Bai JC, Biagi F, Card TR, Ciacci C, Ciclitira PJ, et al. Diagnosis and management of adult coeliac disease: guidelines from the British Society of Gastroenterology. *Gut*. 2014;63:1210–28.
- Hadithi M, von Blomberg BM, Crusius JB, Bloemena E, Kostense PJ, Meijer JW, et al. Accuracy of serologic tests and HLA-DQ typing for diagnosing celiac disease. *Ann Intern Med*. 2007;147:294–302.
- Leffler DA, Dennis M, Hyett B, Kelly E, Schuppan D, Kelly CP. Etiologies and predictors of diagnosis in nonresponsive celiac disease. *Clin Gastroenterol Hepatol*. 2007;5:445–50.
- Abdulkarim AS, Burgart LJ, See J, Murray JA. Etiology of non-responsive celiac disease: results of a systematic approach. *Am J Gastroenterol*. 2002;97:2016–21.
- O'Mahony S, Howdle PD, Losowsky MS. Review article: management of patients with non-responsive coeliac disease. *Aliment Pharmacol Ther*. 1996;10:671–80.
- Rubio-Tapia A, Murray JA. Classification and management of refractory coeliac disease. *Gut*. 2010;59:547–57.
- United European G. When is a coeliac a coeliac? Report of a working group of the United European Gastroenterology Week in Amsterdam, 2001. *Eur J Gastroenterol Hepatol*. 2001;13:1123–8.
- Farstad IN, Johansen FE, Vlatkovic L, Jahnsen J, Scott H, Fausa O, et al. Heterogeneity of intraepithelial lymphocytes in refractory sprue: potential implications of CD30 expression. *Gut*. 2002;51:372–8.
- Al-Toma A, Goerres MS, Meijer JW, von Blomberg BM, Wahab PJ, Kerckhaert JA, et al. Cladribine therapy in refractory celiac disease with aberrant T cells. *Clin Gastroenterol Hepatol*. 2006;4:1322–7, quiz 00.
- Al-toma A, Visser OJ, van Roessel HM, von Blomberg BM, Verbeek WH, Scholten PE, et al. Autologous hematopoietic stem cell transplantation in refractory celiac disease with aberrant T cells. *Blood*. 2007;109:2243–9.

22. Mention JJ, Ben Ahmed M, Begue B, Barbe U, Verkarre V, Asnafi V, et al. Interleukin 15: a key to disrupted intraepithelial lymphocyte homeostasis and lymphomagenesis in celiac disease. *Gastroenterology*. 2003;125:730–45.
23. Al-Toma A, Verbeek WH, Hadithi M, von Blomberg BM, Mulder CJ. Survival in refractory coeliac disease and enteropathy-associated T-cell lymphoma: retrospective evaluation of single-centre experience. *Gut*. 2007;56:1373–8.