

Pediatric metastatic odontogenic ghost cell carcinoma: a multimodal treatment approach

Safia K. Ahmed,¹ Masayo Watanabe,²
Daphne E. deMello,³ Thomas B. Daniels⁴

¹Department of Radiation Oncology, Mayo Clinic, Rochester, MN; ²Department of Cancer and Blood Disorders, Phoenix Children's Hospital, AZ; ³Department of Pathology and Laboratory Medicine, Phoenix Children's Hospital, AZ; ⁴Department of Radiation Oncology, Mayo Clinic, Phoenix, AZ, USA

Abstract

Odontogenic ghost cell carcinoma (OGCC) is a rare and aggressive tumor wherein optimal treatment remains uncertain. We report the first pediatric metastatic OGCC case treated with multimodal therapy: surgery, adjuvant chemoradiation, and adjuvant immunotherapy. Adjuvant therapy was utilized due to locally advanced disease with pathologic features indicative of high recurrence risk. This multimodal approach was modeled after management of primary head and neck cancer, where adjuvant chemoradiation and immunotherapy are associated with improved outcomes. Our patient is alive and disease free at 14 months indicating a potentially positive role for multimodal therapy in the management of OGCC.

Introduction

Odontogenic ghost cell carcinoma (OGCC) is a rare, aggressive tumor of the maxilla and mandible. With fewer than 35 cases reported, optimal treatment remains uncertain. Wide surgical resection is the standard with an indeterminate role for radiation therapy and chemotherapy.¹⁻⁷ Despite aggressive surgical resection, OGCC demonstrates high recurrence rates.^{1-3,6,8,9} Therefore, further investigation into multimodal therapy is needed. We report the first pediatric metastatic OGCC case treated with surgery, adjuvant chemoradiation, and adjuvant immunotherapy.

Case Report

A 10 year-old Hispanic male presented with a fluctuant mass in the right maxilla.

Computed tomography (CT) scan revealed a 3.3 cm soft tissue lesion with destruction of the adjacent maxillary bone and sinus, and displacement of several teeth. Biopsy demonstrated OGCC. Preoperative staging five weeks later revealed size progression and metastatic disease. The mass now measured 5.3 cm. A right submandibular node and several enlarged right cervical lymph nodes were noted corresponding to FDG avidity on PET. Right-sided modified radical maxillectomy and palatotomy, and right-sided modified radical neck dissection was performed one week later. Significant involvement of the buccal mucosa and submandibular gland were noted. After multiple attempts, final surgical margins were negative. Pathology confirmed OGCC (Figure 1). Seven of thirty-eight Level I and II lymph nodes were positive for metastases. The tumor was positive for EGF receptor indicating cellular expression of EGFR protein. One week after surgery, maxillary packing was removed in the operating room. No tumor recurrence was appreciated. Adjuvant therapy was recommended given the rapid pre-surgery growth, positive lymph nodes, and concern for microscopic residual disease. A lesion in the right buccal space was noted at the time of radiation simulation (19 days after surgery). Given these findings and prior history of rapid growth, this was presumed recurrent tumor. An intensity modulated radiation therapy (IMRT) plan was designed for the entire right-sided postoperative bed and bilateral neck. The patient received 44 Gray in 22 fractions (6 mega-Volt photons) prior to receiving a break for treatment-related toxicities. Imaging obtained then showed a 4.9 cm soft tissue mass in the right cheek and a 1.7 cm left gingivolabial soft tissue mass (Figure 2). Biopsy confirmed OGCC. Radiation volumes were expanded to include the new disease.

In summary, the postoperative bed received 60 Gray in 30 fractions over two plans (44 Gray in 22 fractions plus 16 Gray in eight fractions). The left gingivolabial disease received 39 Gray in 13 fractions in two plans (24 Gray in eight fractions plus 15 Gray in five fractions). Treatment was delivered over 63 days. The patient remained dependent on a feeding tube throughout radiation. He developed pain, nausea, oral candidiasis, dermatitis, and nasal mucosa irritation.

Carboplatin was given prior to each radiation fraction if blood counts were adequate. After completion of radiation, monthly cetuximab was initiated. The patient received nine doses prior to being lost to follow-up. When he returned 14 months after completion of radiation, restaging scans demonstrated no recurrent tumor.

Correspondence: Thomas B. Daniels, Department of Radiation Oncology, Mayo Clinic, 5777 E. Mayo Blvd, Phoenix, AZ 85054, USA.
Tel.: +1.480.342.1262 - Fax: +1.480.342.3972.
E-mail: daniels.thomas@mayo.edu

Key words: Odontogenic ghost cell carcinoma; pediatric; chemotherapy; radiation; immunotherapy.

Contributions: SA, MW, TBD, writing of manuscript; DdM, writing of manuscript and pathology review.

Conflicts of interest: the authors declare no potential conflict of interest.

Conference presentation: Poster presentation at the American Radium Society 97th Annual Meeting, May 2-5, 2015.

Received for publication: 7 February 2015.

Accepted for publication: 16 March 2015.

This work is licensed under a Creative Commons Attribution NonCommercial 3.0 License (CC BY-NC 3.0).

©Copyright S.K. Ahmed et al., 2015
Licensee PAGEPress, Italy
Rare Tumors 2015; 7:5855
doi:10.4081/rt.2015.5855

Discussion

With fewer than 35 OGCC cases reported, optimal management remains uncertain. Currently, wide surgical resection is the recommended treatment.^{2,6,7} Radiation and chemotherapy have inconclusive roles, with some reports stating multimodal therapy offers no benefit and others proposing a potential advantage.^{1,2,4} Moreover, immunotherapy in OGCC has never been reported. We report the first pediatric metastatic OGCC case treated with multimodal therapy: surgical resection, adjuvant chemoradiation, and adjuvant immunotherapy. Our case shares clinical similarities with other reports, including a male partiality and maxillary predominance.^{5,6,8,10} However, we report the youngest case in the literature and the first Hispanic case. Currently reported age range for OGCC is 13-86 years.^{7,8,10} Including our case, the age distribution is now 10-86 years indicating OGCC is also a pediatric malignancy. OGCC is more commonly reported in Asian patients.^{8,10} However, Caucasian and African American cases have also been reported.^{5,7,8} Given the patient diversity but overall small number of reports, it is impossible to draw any definitive conclusions between ethnicity and OGCC. Rapid progression and local recurrence are

well-documented characteristics of OGCC.^{1-3,6,8,9} Our case demonstrates particularly aggressive behavior with substantial tumor growth and lymph node metastases in just over a month between diagnosis and staging. Moreover, contralateral metastasis developed within two months of surgery, requiring expansion of radiation treatment fields. Although the final surgical resection margins were negative,

multiple attempts were necessary to achieve this and the inability to obtain a wide negative margin likely predisposed to recurrence.

Adjuvant radiation therapy was recommended in this case given features suggestive of high recurrence risk. To our knowledge, only seven prior published OGCC cases were treated with radiation therapy (Table 1).^{1,4,9,11-14} Three patients were known to be without evi-

dence of disease at last follow-up. Given the small number of reports and absence of rationale for radiation use in these cases, it is inaccurate to draw any association (favorable or unfavorable) between radiation and survival in OGCC. Of note, all radiation cases were published 15-29 years ago. Significant advances in radiation therapy have since been made, including development of IMRT. IMRT allows

Table 1. Summary of odontogenic ghost cell carcinoma cases treated with radiation.

First author (year)	Age/sex/ethnicity	Tumor site	Initial treatment	Progression, recurrence	Progression treatment	Follow-up
Ikemura (1985) ¹³	48/F?	L upper gingivae, hard palate	Enucleation	Ethmoidal and frontal sinus, 3 months	RT (30 Gy), 5-fluorouracil chemotherapy, total maxillary resection	Contralateral maxillary invasion, DOD by 20 months
Grodjesk (1987) ¹²	46/M/C	R Maxilla	R maxillectomy, RT (62 Gy R maxilla + 50 Gy neck)	Local recurrence and lung metastases, 6 months	N/A	DOD
Scott (1989) ¹⁴	33/M/AA	L maxilla	L maxillectomy ×3	Pterygoid residual tumor following third surgery, 6 weeks	RT (30 Gy, 3 wks)	Lost to follow-up at 3 years, NED?
Kao (1995) ⁹	40/F?	R maxilla	Modified partial maxillectomy (R maxillary cyst-like excision 7 yrs prior)	Local and distant recurrence ×3, 3 yrs, 6 yrs, 8 yrs	Resection for first 2 local and distant recurrences, resection and RT (50 Gy) for 3rd recurrence	Metastatic pulmonary disease, 13 yrs
Alcalde (1996) ¹	72/F/J	L maxilla	Enucleation; adjuvant RT (48 Gy)	N/A	N/A	NED at 10 years
Folpe (1998) ¹¹	20/M?	R maxilla	R maxillectomy	Local recurrence ×3, 10 months, 13 months, unknown	Resection for first 2 recurrences, RT for 3 rd recurrence (60 Gy)	Local recurrence at 6 years, NED 1 ½ years later
Kamijo (1999) ⁴	38/M/J	R maxilla	Enucleation; adjuvant RT (50 Gy)	N/A	N/A	NED at 1 year
Current case	10/M/H	R maxilla, lymph nodes	R maxillectomy, palatotomy, neck dissection; adjuvant RT	Residual tumor and contralateral metastasis, 2 months	RT field expansion: 60 Gy/30 fx to postoperative bed and 39 Gy/13 fx to new left sided disease	Alive at 14 months, NED

M, male; F, female; L, left; R, right; C, Caucasian; AA, African American; J, Japanese; H, Hispanic; RT, radiation therapy; Gy, Gray; Fx, fraction; NED, no evidence of disease; DOD, dead of disease.

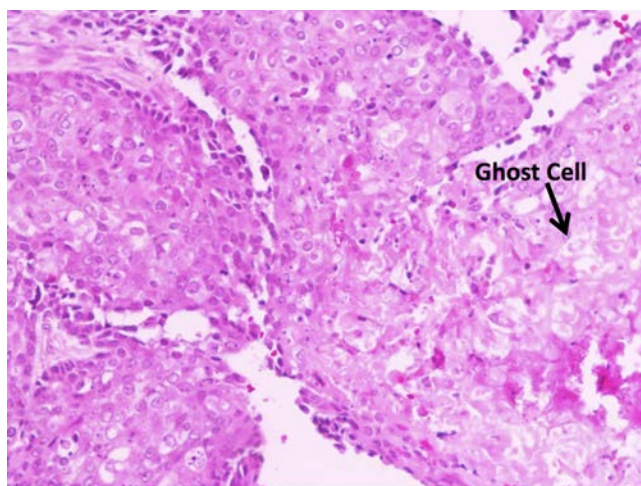


Figure 1. Islands of squamous epithelial cells with foci of ghost cells and calcification (Hematoxylin & Eosin, 400×).

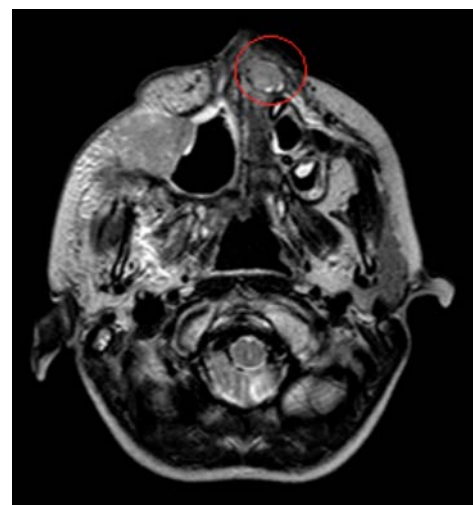

Figure 2. Magnetic resonance imaging demonstrating known right-sided disease and progression during treatment (red circle).

for high doses of radiation to be delivered to the tumor while minimizing dose to adjacent structures. Prior to IMRT, the intended therapeutic dose to the primary site was limited due to toxicities from irradiating surrounding healthy tissues. The modern era adjuvant radiation dose for primary head and neck cancer is 60-66 Gray with concurrent chemotherapy.^{15,16} In the seven OGCC cases treated with radiation, we see a dose range of 30-60 Gray. Again, associations are impossible to make due to absence of radiation therapy details; however, it is reasonable to question whether these tumors were adequately dosed. As such, modern era radiotherapy investigations are warranted.

Ikemura *et al.* reported use of 5-fluorouracil in 1985 for recurrent OGCC.¹³ As no response was noted, chemotherapy was deemed unsuitable. It may also be argued that chemotherapy is irrelevant since OGCC does not have a propensity for distant metastases.^{3,17} Again, it is difficult to draw definite conclusions from a few cases. Platinum-based chemotherapy as a synergistic modality with radiation in head and neck cancer is clearly associated with improved disease-free outcomes in the modern era.^{15,18}

To our knowledge, this is the first case to utilize immunotherapy for EGFR overexpression in OGCC. Molecular analyses indicate EGFR expression occurs in odontogenic epithelial cells and is involved in odontogenic tumor genesis.¹⁹ Adjuvant cetuximab was recommended in this case as cetuximab plus radiotherapy is associated with improved survival in head and neck squamous-cell carcinoma.²⁰ With newer literature geared at molecular and immunohistochemical analyses in odontogenic tumors, immunotherapy may develop a niche in OGCC management.

Conclusions

In summary, treatment modality outcomes in OGCC are indeterminate due to the small number of cases with each modality in the current literature. Our patient's treatment was modeled after the management of primary head and neck cancer due to clinical and pathologic features predisposing to a high

recurrence risk after surgery alone. As adjuvant chemoradiation and immunotherapy is associated with improved outcomes in primary head and neck cancer, a similar application in OGCC may help better delineate ideal treatment for this rare and aggressive tumor.

References

- Alcalde RE, Sasaki A, Misaki M, Matsumura T. Odontogenic ghost cell carcinoma: report of a case and review of the literature. *J Oral Maxillofac Surg* 1996;54:108-11.
- Goldenberg D, Sciubba J, Koch W, et al. Malignant odontogenic tumors: a 22-year experience. *Laryngoscope* 2004;114:1770-4.
- Goldenberg D, Sciubba J, Tufano RP. Odontogenic ghost cell carcinoma. *Head Neck* 2004;26:378-81.
- Kamijo R, Miyaoka K, Tachikawa T, et al. Odontogenic ghost cell carcinoma: report of a case. *J Oral Maxillofac Surg* 1999;57:1266-70.
- Lu Y, Mock D, Takata T, et al. Odontogenic ghost cell carcinoma: report of four new cases and review of the literature. *J Oral Maxillofac Surg* 1999;28:323-9.
- Zhu ZY, Chu ZG, Chen Y, et al. Ghost cell odontogenic carcinoma arising from calcifying cystic odontogenic tumor: a case report. *Korean J Pathol* 2012;46:478-82.
- Del Corso G, Tardio ML, Gissi DB, et al. Ki-67 and p53 expression in ghost cell odontogenic carcinoma: a case report and literature review. *Oral maxillofac surg* 2015;19:85-9.
- Cheng Y, Long X, Li X, et al. Clinical and radiological features of odontogenic ghost cell carcinoma: review of the literature and report of four new cases. *Dentomaxillofac Radiol* 2004;33:152-7.
- Kao SY, Pong BY, Li WY, et al. Maxillary odontogenic carcinoma with distant metastasis to axillary skin, brain, and lung: case report. *Int J Oral Maxillofac Surg* 1995;24:229-32.
- Arashiyama T, Kodama Y, Kobayashi T, et al. Ghost cell odontogenic carcinoma arising in the background of a benign calcifying cystic odontogenic tumor of the mandible. *Oral Surg Oral Med Oral Pathol Oral Radiol* 2012;114:e35-40.
- Folpe AL, Tsue T, Rogerson L, et al. Odontogenic ghost cell carcinoma: a case report with immunohistochemical and ultrastructural characterization. *J Oral Pathol Med* 1998;27:185-9.
- Grodjesk JE, Dolinsky HB, Schneider LC, et al. Odontogenic ghost cell carcinoma. *Oral Surg Oral Med Oral Pathol* 1987;63:576-81.
- Ikemura K, Horie A, Tashiro H, et al. Simultaneous occurrence of a calcifying odontogenic cyst and its malignant transformation. *Cancer* 1985;56:2861-4.
- Scott J, Wood GD. Aggressive calcifying odontogenic cyst—a possible variant of ameloblastoma. *Br J Oral Maxillofac Surg* 1989;27:53-9.
- Bernier J, Domenge C, Ozsahin M, et al. Postoperative irradiation with or without concomitant chemotherapy for locally advanced head and neck cancer. *New Eng J Med* 2004;350:1945-52.
- Cooper JS, Pajak TF, Forastiere AA, et al. Postoperative concurrent radiotherapy and chemotherapy for high-risk squamous-cell carcinoma of the head and neck. *New Eng J Med* 2004;350:1937-44.
- Roh GS, Jeon BT, Park BW, et al. Ghost cell odontogenic carcinoma of the mandible: a case report demonstrating expression of tartrate-resistant acid phosphatase (TRAP) and vitronectin receptor. *J Craniomaxillofac Surg* 2008;36:419-23.
- Forastiere AA, Goepfert H, Maor M, et al. Concurrent chemotherapy and radiotherapy for organ preservation in advanced laryngeal cancer. *New Eng J Med* 2003;349:2091-8.
- Kumamoto H. Molecular pathology of odontogenic tumors. *J Oral Pathol Med* 2006;35:65-74.
- Bonner JA, Harari PM, Giralt J, et al. Radiotherapy plus cetuximab for locoregionally advanced head and neck cancer: 5-year survival data from a phase 3 randomised trial, and relation between cetuximab-induced rash and survival. *Lancet Oncol* 2010;11:21-8.