

# Wells Syndrome – An Odyssey

Birgit Heinig<sup>1</sup>, Aleksandra Vojvodic<sup>2</sup>, Torello Lotti<sup>3</sup>, Michael Tirant<sup>3</sup>, Uwe Wollina<sup>4\*</sup>

<sup>1</sup>Center of Physical and Rehabilitative Medicine, Städtisches Klinikum Dresden, Academic Teaching Hospital, Dresden, Germany; <sup>2</sup>Military Medical Academy of Belgrade, Belgrade, Serbia; <sup>3</sup>Department of Dermatology, University of Rome “G. Marconi”, Rome, Italy; <sup>4</sup>Department of Dermatology and Allergology, Städtisches Klinikum Dresden, Academic Teaching Hospital, Dresden, Germany

## Abstract

**Citation:** Heinig B, Vojvodic A, Lotti T, Tirant M, Wollina U. Wells Syndrome – An Odyssey. *Open Access Maced J Med Sci.* 2019 Sep 30; 7(18):3002-3005. <https://doi.org/10.3889/oamjms.2019.572>

**Keywords:** Eosinophilic skin diseases; Wells syndrome; Flame figure; Eosinophilia; Treatment; Interleukin-5

**\*Correspondence:** Uwe Wollina, Department of Dermatology and Allergology, Städtisches Klinikum Dresden, Academic Teaching Hospital, Dresden, Germany. E-mail: [uwollina@gmail.com](mailto:uwollina@gmail.com)

**Received:** 30-Apr-2019; **Revised:** 22-Jun-2019; **Accepted:** 23-Jun-2019; **Online first:** 30-Jun-2019

**Copyright:** © 2019 Birgit Heinig, Aleksandra Vojvodic, Torello Lotti, Michael Tirant, Uwe Wollina. This is an open-access article distributed under the terms of the Creative Commons Attribution-NonCommercial 4.0 International License (CC BY-NC 4.0)

**Funding:** This research did not receive any financial support

**Competing Interests:** The authors have declared that no competing interests exist

**BACKGROUND:** Wells syndrome is a rare idiopathic dermatosis of the eosinophilic spectrum. Diagnostic criteria include cutaneous eruptions of variable morphology with eosinophilic infiltrates, peripheral blood eosinophilia, a relapsing, remitting course, and exclusion of systemic disease. Diagnosis is often delayed.

**CASE PRESENTATION:** We present a 28-year older man with recently developed pruritic and sometimes painful erythema. His medical history was positive for coughing in the evening that started in November 2012. Later, a pansinusitis developed. Early diagnosis improves the outcome.

**CONCLUSION:** Standardized treatment has yet to be developed. In our case, systemic corticosteroids were of limited value only.

## Introduction

Eosinophilic skin diseases are characterised by eosinophil infiltration and/or degranulation in skin lesions, with or without blood eosinophilia. Eosinophils can defend against microbes, to regulate inflammation, cause tissue damage, promote remodelling and fibrosis, and initiate pruritus. Tissue eosinophilia can be caused by cytokine-mediated increased differentiation and survival of eosinophils (extrinsic eosinophilic disorders), and mutation-mediated clonal expansion of eosinophils (intrinsic eosinophilic disorders). Increased generation of interleukin (IL)-5 producing T-lymphocytes is often involved [1].

Eosinophilic skin diseases are heterogeneous. Pruritus is a common symptom. These disorders can be classified in:

- allergy-related (allergic drug eruption, urticaria, allergic contact dermatitis, atopic dermatitis),
- parasitic infestations and arthropod bites,
- infection-related (chronic pulmonary aspergillosis, HIV, *Toxocara canis*),
- autoimmune blistering (bullous pemphigoid, dermatitis herpetiformis), and
- those of unknown origin (idiopathic).

The latter group, which is extremely heterogeneous and rare, includes Wells syndrome

(eosinophilic cellulitis), granuloma faciale, eosinophilic pustular folliculitis, recurrent cutaneous eosinophilic vasculitis, Job syndrome, angiolymphoid hyperplasia with eosinophilia, and eosinophilic fasciitis [2]. Here we present a case of Wells syndrome with a remarkable delay of diagnosis.

## Case Report

A 28-year older man presented with recently developed pruritic and sometimes painful erythema (Figure 1). His medical history was positive for coughing in the evening that started in November 2012. In January 2018, he contacted his GP because of fever. He got a prescription for codeine and oral antibiotic.

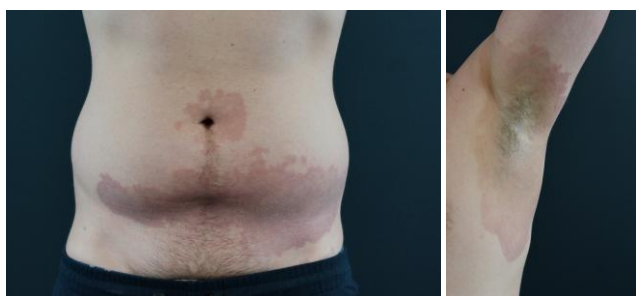


Figure 1: Clinical presentation of Wells syndrome (eosinophilic cellulitis) with large erythematous and brownish macules with slightly elevated borders: abdominal (left); axillary (right)

Because of a feeling of pressure and fullness of the paranasal sinuses, he went to an ENT specialist. The allergy tests remained negative, and he got a prescription for 200 mg-cineole capsules.

In April 2018 he experienced a short breath in addition to coughing and greenish sputum. The pulmonologist diagnosed infection-triggered asthma. A corticoid asthma spray improved coughing temporarily.

He presented himself again to the ENT specialist in July 2018 because of persistent coughing and nasal speech. He got a prescription for an oral antibiotic, prednisolone tablets and a corticoid-containing nasal-spray. In August 2018 he suffered an allergic shock after novaminsulfon intake. A respiratory insufficiency was treated in the intensive care unit. Oral prednisolone medication was continued. A computerised tomography (CT) of paranasal sinuses demonstrated a massive polypoid pansinusitis with congestion of the cavities. At this point, the erythematous skin lesions appeared.

On examination, we observed larger erythematous to brownish macules with a slightly elevated border of the armpits, peri- and infra-umbilical, on fingers and thighs. There was no scaling,

no blistering (Figure 1).

A diagnostic skin biopsy revealed eosinophilic and neutrophilic infiltrate with dominance of eosinophils of the whole corium with presence of so-called flame figures, i.e. degranulated eosinophils around collagen fibres.

Eosinophilia of the cutis is suggestive of the following three differential diagnoses: Wells syndrome (Eosinophilic cellulitis - EC), Churg-Strauss syndrome (Eosinophilic granulomatosis with polyangiitis - EGPA), and hyper-eosinophilic syndrome (HES).

Imaging: Echocardiography remained unremarkable. Dual X-ray energy of the chest was suggestive of atypical pneumonia treated with oral clindamycin (Figure 2).

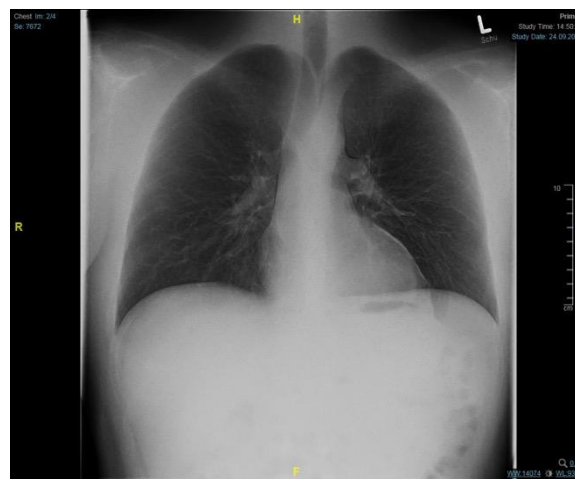

Figure 2: Chest X-ray with atypical pneumonia-like features

Body plethysmography excluded obstructive or restrictive ventilation conditions. There was no hint for a diffusion abnormality either.

Abdominal ultrasound demonstrated no pathological findings.

The ENT council confirmed a chronic pansinusitis with an indication for functional endoscopic sinus surgery. Histology of the surgical specimen did not show tissue eosinophilia. After surgery, prednisolone was omitted. The exanthema re-appeared but was less severe. Dyspnea continued.

Laboratory investigation: Eosinophil blood count 23.7 % (normal range: 0.8 – 7.0) or 2.03 G/L (0.04 – 0.54), total IgE 416.0 kU/L (< 100), lymphopenia of 20.0 % (25-45), creatine kinase 3.74  $\mu\text{mol/s} \cdot \text{L}$  (0.00-2.90), total protein 62.4 g/L (66-87), 25-OH-vitamine D 15.5 ng/L (20.0-80.0), C-reactive protein, ANA, c-ANCA, p-ANCA, myeloperoxidase, C3 and C4 complement, antibodies to SSA/Ro, SSB/La, Scl-70, Jo-1, Sm, and RNP70 were normal or negative.

In summary of our findings, we confirmed the diagnosis of Wells syndrome.

The medication at the end of hospital stay consisted of the following medical drugs: Cetirizine 10 mg/d, methyl-prednisolone 8 mg/d, cortisone nasal spray; tiotropium bromide pulmonary spray and salmeterol xinafoate/fluticasone spray, cholecalciferol 20.000 I.U. on day 1 and 15 of each month, and fluocinolone acetonide ointment for a maximum of 4 weeks.

## Discussion

Our patient underwent an odyssey to the final diagnosis of EC. Eventually, EGPA could be excluded by the normal finding of chest X-ray, body plethysmography, absence of tissue eosinophilia in surgical specimen from pansinusitis surgery, and absence of ANCA in peripheral blood. In skin histology there was no vasculitis, granulomas were missing [3].

HES has been recently redefined as: (1) Blood eosinophilia of greater than 1500/mm<sup>3</sup> on at least two occasions or evidence of prominent tissue eosinophilia associated with symptoms and marked blood eosinophilia. (2) Exclusion of secondary causes of eosinophilia, such as parasitic or viral infections, allergic diseases, drug-induced or chemical-induced eosinophilia, hypoadrenalism, and neoplasms [4].

EC or Wells syndrome was described in 1971 by G. C. Wells as recurrent granulomatous dermatitis with eosinophilia [5]. EC has a sudden onset. During the course of the disease, patients present with recurrent episodes of acute pruritic dermatitis and / or painful edematous swellings or persistent urticarial eruptions. This was a leading symptom in the present patient.

**Table 1: Diagnostic criteria for eosinophilic cellulitis (Wells syndrome)**

Major criteria (2 of 4 required)
Any of the previously reported clinical variants
Plaque-type
Annular-granuloma-like
Urticaria-like
Papulovesicular
Bullous
Papulonodular
Fixed-Drug Eruption-like
Relapsing, remitting course
No systemic evidence disease
Histology: eosinophilic infiltrates, no vasculitis
Minor (at least 1 required)
Histology: Flame figures
Histology: Granulomatous change
Laboratory: Peripheral eosinophilia not persistent and not greater than > 1500/ $\mu$ l
Triggering factor (e.g. drug)

Histopathology is useful in diagnostics. The findings vary with the disease stage, of course. Initially, oedema and a dermal infiltrate of eosinophils are seen. The sub-acute stage, as in our patient, is characterised by fibrinoid flame-figures of mid to deep dermis. Later on, eosinophils tend to disappear and are replaced by histiocytic granulomas. The absence

of vasculitis is an important negative sign [6].

Diagnostic criteria have been proposed by Heelan et al., in 2013 [7] (Table 1).

The cause of the disease is unknown, but other disorders may be associated with EC such as infections or hematologic disorders or medical drugs. Cases of EC arising in patients receiving biologics are increasingly reported [8], [9].

Systemic corticosteroids are usually helpful in EC, but the response may vary about associated pathologies. In our case, the previous corticosteroid treatments were too short, or the dosage was insufficient, leading to recurrences. Standard doses are 1 mg prednisolone per kg body weight. Sometimes higher dosages and repeated course are necessary. Cyclosporin A has been used at doses between 100 and 200 mg/d. Alternatives to systemic corticosteroids are dapsone with a dosage of up to 200 mg/d if there is no glucose-6-phosphate dehydrogenase deficiency, antihistamines (with limited success), colchicine, chloroquine, and azathioprine among others. The combination of prednisolone 50 to 10 mg/d with dapsone 50 mg/d seems to induce a more rapid response. Randomised controlled trials are missing [10].

New treatment modalities are on the horizon. Case reports on successful treatment of EC with monoclonal anti-IgE antibody omalizumab have been published [11]. Increased expression of IL-5 has been reported in several cases. Therefore, antibodies directed against IL-5 (e.g. mepolizumab), IL-5-receptor, and Siglec-8 could be a choice. Reduction of tissue eosinophilia can be achieved by dexpramipexole, tyrosine kinase inhibitors, Janus kinase inhibitors, or cytokine inhibitors to IL-13, IL-31, and others [12].

In conclusion, EC or Wells syndrome is a rare disorder of the spectrum of eosinophilic skin diseases. Diagnosis may be significantly delayed if this rare syndrome is not considered during a chronic relapsing course of variable complaints. Other eosinophilic disorders need to be excluded. Underlying or associated diseases of autoimmune, infectious or malignant nature need careful consideration. Treatment of choice is systemic corticosteroids, but more specific treatment options are on the horizon.

## References

1. Simon D, Wardlaw A, Rothenberg ME. Organ-specific eosinophilic disorders of the skin, lung, and gastrointestinal tract. *J Allergy Clin Immunol*. 2010; 126(1):3-13; quiz 14-5. <https://doi.org/10.1016/j.jaci.2010.01.055> PMID:20392477 PMCID:PMC2902687
2. Long H, Zhang G, Wang L, Lu Q. Eosinophilic Skin Diseases: A Comprehensive Review. *Clin Rev Allergy Immunol*. 2016;

- 50(2):189-213. <https://doi.org/10.1007/s12016-015-8485-8> PMID:25876839
3. Cottin V, Bel E, Bottero P, Dalhoff K, Humbert M, Lazor R, Sinico RA, Sivasothy P, Wechsler ME, Groh M, Marchand-Adam S, Khouatra C, Wallaert B, Taillé C, Delaval P, Cadranet J, Bonniaud P, Prévot G, Hirschi S, Gondouin A, Dunogué B, Chatté G, Briault C, Pagnoux C, Jayne D, Guillevin L, Cordier JF; Groupe d'Etudes et de Recherche sur les Maladies Orphelines Pulmonaires (GERM"O"P). Revisiting the systemic vasculitis in eosinophilic granulomatosis with polyangiitis (Churg-Strauss): A study of 157 patients by the Groupe d'Etudes et de Recherche sur les Maladies Orphelines Pulmonaires and the European Respiratory Society Taskforce on eosinophilic granulomatosis with polyangiitis (Churg-Strauss). *Autoimmun Rev*. 2017; 16(1):1-9. <https://doi.org/10.1016/j.autrev.2016.09.018> PMID:27671089
4. Simon HU, Rothenberg ME, Bochner BS, Weller PF, Wardlaw AJ, Wechsler ME, Rosenwasser LJ, Roufosse F, Gleich GJ, Klion AD. Refining the definition of hypereosinophilic syndrome. *J Allergy Clin Immunol*. 2010; 126(1):45-9. <https://doi.org/10.1016/j.jaci.2010.03.042> PMID:20639008 PMID:PMC3400024
5. Wells GC. Recurrent granulomatous dermatitis with eosinophilia. *Trans St Johns Hosp Dermatol Soc*. 1971; 57(1):46-56.
6. Peckruhn M, Tittelbach J, Schliemann S, Elsner P. Life of lesions in eosinophilic cellulitis (Wells' syndrome)-a condition that may be missed at first sight. *Am J Dermatopathol*. 2015; 37(2):e15-7. <https://doi.org/10.1097/DAD.0000000000000051> PMID:25238447
7. Heelan K, Ryan JF, Shear NH, Egan CA. Wells syndrome (eosinophilic cellulitis): Proposed diagnostic criteria and a literature review of the drug-induced variant. *J Dermatol Case Rep*. 2013; 7(4):113-20. <https://doi.org/10.3315/jdcr.2013.1157> PMID:24421864 PMID:PMC3888780
8. Rozenblat M, Cohen-Barak E, Dodiuk-Gad R, Ziv M. Wells' Syndrome Induced by Ustekinumab. *Isr Med Assoc J*. 2019; 21(1):65.
9. Dabas G, De D, Handa S, Chatterjee D, Radotra BD. Wells syndrome in a patient receiving adalimumab biosimilar: A case report and review of literature. *Indian J Dermatol Venereol Leprol*. 2018; 84(5):594-599. [https://doi.org/10.4103/ijdv.IJDVL\\_636\\_17](https://doi.org/10.4103/ijdv.IJDVL_636_17) PMID:30058563
10. Rășler F, Lukács J, Elsner P. Treatment of eosinophilic cellulitis (Wells syndrome) - a systematic review. *J Eur Acad Dermatol Venereol*. 2016; 30(9):1465-79. <https://doi.org/10.1111/jdv.13706> PMID:27357601
11. Egeland Ø, Balieva F, Undersrud E. Wells syndrome: a case of successful treatment with omalizumab. *Int J Dermatol*. 2018; 57(8):994-995. <https://doi.org/10.1111/ijd.14006> PMID:29707773
12. Simon D, Simon HU. Therapeutic strategies for eosinophilic dermatoses. *Curr Opin Pharmacol*. 2019; 46:29-33. <https://doi.org/10.1016/j.coph.2019.01.002> PMID:30743138