

RESEARCH ARTICLE

Interrelationships in the Variability of Root Canal Anatomy among the Permanent Teeth: A Full-Mouth Approach by Cone-Beam CT

Paul Monsarrat^{1,2}, Bertrand Arcaute^{3,4}, Ove A. Peters⁵, Elisabeth Maury³, Norbert Telmon^{4,6}, Marie Georgelin-Gurgel³, Delphine Maret^{3,4*}

1 Department of Anatomical Sciences and Radiology, Dental Faculty, Paul Sabatier University, Toulouse University Hospital, Toulouse, France, **2** STROMALab, Université de Toulouse, CNRS ERL 5311, EFS, INP-ENVT, Inserm U1031, UPS, Toulouse, France, **3** Department of Department of Conservative Dentistry and Endodontics, Dental Faculty, Paul Sabatier University, Toulouse University Hospital, Toulouse, France, **4** AMIS Laboratory - Laboratoire Anthropologie Moléculaire et Imagerie de Synthèse, Université de Toulouse, UMR 5288 CNRS, UPS, Toulouse, France, **5** Department of Endodontics, Arthur A. Dugoni School of Dentistry University of the Pacific, San Francisco, California, United States of America, **6** Service de Médecine Légale, Centre Hospitalier Universitaire Rangueil, avenue du Professeur Jean Poulhès, 31059, Toulouse Cedex 9, France

☞ These authors contributed equally to this work.

* delphine_maret@yahoo.fr



CrossMark
click for updates

OPEN ACCESS

Citation: Monsarrat P, Arcaute B, Peters OA, Maury E, Telmon N, Georgelin-Gurgel M, et al. (2016) Interrelationships in the Variability of Root Canal Anatomy among the Permanent Teeth: A Full-Mouth Approach by Cone-Beam CT. PLoS ONE 11(10): e0165329. doi:10.1371/journal.pone.0165329

Editor: James Cray, Medical University of South Carolina, UNITED STATES

Received: July 1, 2016

Accepted: October 10, 2016

Published: October 20, 2016

Copyright: © 2016 Monsarrat et al. This is an open access article distributed under the terms of the [Creative Commons Attribution License](https://creativecommons.org/licenses/by/4.0/), which permits unrestricted use, distribution, and reproduction in any medium, provided the original author and source are credited.

Data Availability Statement: All relevant data are within the paper and its Supporting Information files.

Funding: The authors received no specific funding for this work.

Competing Interests: The authors have declared that no competing interests exist.

Abstract

Objectives

In endodontic practice, clinicians should be aware of possible root canal anatomic variations. The aim of this study was to assess using CBCT acquisitions regarding whether one root canal anatomy of a tooth is associated with a specific anatomy of another tooth.

Methods

A total of 106 CBCT acquisitions were obtained using a CBCT scanner with 200µm voxel size. Numbers of roots and canals of the entire dentition were described. Bivariate analyses and logistic regressions were conducted to explore root canal anatomy on one tooth according to age, gender, jaw, side and the others teeth. Multiple correspondence analysis (MCA) was performed to correlate the different numbers of canals profiles.

Results

A total of 2424 teeth were analyzed. Independently from the other variables, the presence of an additional root canal on a mandibular incisor increases the risk of having an additional root canal on a mandibular premolar (OR_[95%] 3.7 [1.0;13.2]). The mandibular molar variability increases in women compared to men (OR_[95%] 0.4 [0.1; 0.9]). MCA showed correspondence between 2-canals maxillary incisor and canines and 5-canals maxillary molars, and some correlation between additional canal on maxillary and mandibular premolars.

Conclusions

Although CBCT examinations are conducted in the first intention of making a diagnosis or prognostic evaluation, medium FOV acquisitions could be used as an initial database thus furnishing preliminary evaluations and information. In endodontic practice, clinicians should be aware of possible root canal anatomic variations. The visualization of all canals is considered essential in endodontic therapy. The use of multi-correspondence analysis for statistics in endodontic research is a new approach as a prognostic tool.

Introduction

Root canal systems have been described as complex anatomical structures with significant implication on root canal preparation. In the literature, various factors such as genetics and ethnic differences, have been reported to influence root canal anatomy [1,2]. Visualization of root canal anatomy is, therefore, of major interest in the practice of dentistry and considered essential in endodontic therapy. Successful root canal treatment is dependent on a detailed understanding of the morphology of the root canal system. Adequate debridement, shaping, and complete obturation in three dimensions are based on knowledge of normal anatomy and variations from the norm. Clinicians should be aware of common root canal configurations and possible anatomic variations [2,3].

Several studies have investigated root canal anatomy with different *ex vivo* methods such as root sectioning, electron microscopy, staining and clearing techniques and micro-computed tomography [4]. Nevertheless, these techniques may lead to a selection bias with a higher proportion of sound teeth or undamaged during extraction [4], and cannot be applied in clinical practice, which generally relies on the use periapical radiographs and more recently on the operating microscope [5].

Conventional radiography yields limited information due to the projection in two dimensions (2D) of a 3-dimensional (3D) anatomical structure, which can lead to failure to recognize a root canal because another structure is superimposed upon it [6]. Cone-beam computed tomography (CBCT) is a considerable technological advancement, providing a three-dimensional view with no overlapping of complex anatomic structures. CBCT scanning can help clinicians view morphological features from a 3-dimensional perspective and to provide the researchers opportunities to study root canal anatomy nondestructively. In endodontic practice, CBCT is a diagnostic tool offering a better understanding of root canal anatomy in axial, sagittal, and coronal sections [7]. Clinical applications differ according to the size of the field of view (FOV) of the CBCT unit.

Considering that the incidence of missed roots or canals in teeth that needed retreatment may be as high as 42% [8], the visualization of all canals is essential. Especially, multi-rooted teeth are described as a complex anatomical structure. In general, maxillary first molars present with 3 roots and 4 canals [9,10]. In the mesiobuccal (MB) root, the incidence of a second canal (MB2) is over 50%, according to the literature [1,6,7,10–12]. However, variations of root canal anatomy concern all teeth. A clinical question is then the capacity to predict the complexity of root canal morphology.

Therefore, the aim of this pilot study was to assess using CBCT acquisitions regarding whether one root canal anatomy of a tooth is associated with a specific anatomy of another tooth.

Materials and Methods

Sample

We examined 106 CBCT acquisitions obtained from 2012 to 2013 in a private practice of Oral and Maxillo-Facial Radiology (E. Coudrais EC) in Toulouse, France; all scans were de-identified before being transmitted for analysis (EC). These acquisitions were randomly selected. Authors were not the treating dentists of these patients. Exclusion criteria were patients who were minors, edentulous patients and presence of metallic artifacts. In accordance with ethical and local radiation protection guidelines and the local board, no CBCT examinations were prescribed especially for the study; they were part of routine care. According to French law, the results of medical imaging examinations may be used retrospectively without the patient's consent when these examinations have been carried out for clinical purposes and when they have been recorded anonymously (article 40–1, law 94–548 of 1 July 1994)[13].

CBCT scans

The CBCT images were obtained using a CBCT scanner (CS 9500 3D[®], Carestream, Marne-la-Vallée, France) with tube voltage of 90kV and tube current of 10mA. The voxel size was 200 μ m and the FOV was 90 x 150mm. The exposure time was 10.8s with a dose—area product of 605 mGy.cm². The scans were acquired by an experienced radiologist (EC) according to the manufacturer's recommended protocol with the minimum exposure necessary for adequate image quality.

Image evaluation and study variables

CBCT scans were analyzed using CS Dental Imaging Software 3D Module v3.2.9 (Carestream, Marne-la-Vallée, France). Two dental practitioners independently (B. Arcaute BA and E. Maury EM) evaluated the images twice at an interval of 2 weeks. A preview of the three planes was conducted and followed by a visualization of all slices in the axial plan (coronal to apical and apical to coronal directions). The following variables were recorded: age, sex, type of tooth and number of teeth, jaw (maxillary/mandibular) or side (left/right). For each tooth, the number of roots and canals were noted. When reading the scans, third molars and root fragments were excluded. Have also not been considered teeth with orthodontic appliances, stirred images or presence of metallic artifacts preventing the adequate visualization of endodontic structures.

Statistical analysis

Statistical analysis was performed using the STATA 13.1 software (StataCorp, TX, USA). Inter and intra-examiner agreement was evaluated by the Kappa test. A random sample of 30 CBCT examinations was re-examined one week after the initial examination to test intra-examiner agreement with the Kappa test. The Kappa test was also used to assess inter-examiner agreement, again using a random sample of 30 CBCT examinations. The scans were read by 2 trained observers (BA and EM). The data were analyzed using descriptive statistics. A Stuart-Maxwell test was performed to compare left/right pairs of teeth (paired samples). When a 2x2 comparison was performed, this test acted as the McNemar test. The level of significance was set at 5% ($p < 0.05$).

The effects of age, gender, jaw (maxillary/mandibular) or side (left/right) on the number of roots and canals were analyzed. To achieve this goal, teeth were grouped (maxillary incisors or canines, mandibular incisors or canines, maxillary premolars, mandibular premolars, maxillary molars, mandibular molars); for each patient, a tooth group was considered with a difference

compared to the reference group if at least one tooth of the group had a difference from the average dental anatomy.

Non-parametric and unmatched test (Mann-Whitney) was used to determine the effect of age, non-parametric and matched test (Wilcoxon) for the effect of jaw and side, and chi square test for the effect of gender, on variability. The dependent variable of a root anatomical variation for a specific tooth group was analyzed using a logistic regression model, taking into account the other tooth groups, age and gender. Multiple correspondence analysis (MCA) was performed to correlate different numbers of canals profiles.

Results

Study sample

From the initial sample of 106 CBCT scans, 102 scans were selected. Four scans were excluded because of presence of a metallic artifact. Patient age ranged from 20 to 88 years, with a mean age of 46.8 years. The study sample included 53 women and 49 men. The inter-examiner agreement of 30 CBCT scans was very high with a Kappa coefficient of 0.86 for root numbers and 0.82 for canal numbers. The intra-examiner agreement of 30 CBCT scans was also very high with a Kappa coefficient of 0.97 for both root and canal numbers.

Descriptive data

A total of 2424 teeth were analyzed (1199 maxillary teeth and 1225 mandibular teeth). There was no significant difference between men and women regarding their age or the number of teeth in each dental arch (Table 1).

Number of roots and canals

Table 2 summarizes the details regarding the number of teeth, canals and roots.

Incisors and canines. Morphological examination of the maxillary and mandibular incisor-canine group showed that these teeth generally had one root for one canal (Fig 1). Anatomical variations were more frequent in the mandibular central and lateral incisors, where 2 canals for one root were identified in 11% of left central incisors, 13% of right central incisors, 12% of left lateral incisors, and 13% of right lateral incisors (Fig 1).

Premolars. The first maxillary premolar generally had 2 canals for 2 roots but 3 canals for 3 roots were also found (Table 2). The second maxillary premolar generally showed 1 canal for 1 root. In the mandible, the majority of premolars had a single root with a single canal. However, the first premolar showed more variations, with 2 canals for one root or 2 canals for 2 roots.

Molars. The most common morphology for maxillary molars was 3 roots for both first and second molars (Table 2). Maxillary first molars presented with 4 canals in about half of the

Table 1. Description of study population.

	Number of patients	Number of teeth	Age
	N (%)	Mean ± SD	Mean ± SD (min–max)
Total	102	25.2 ± 4.3	46.8 ± 15.9 (20–88)
Men	49 (48%)	25.5 ± 4.6	45.5 ± 15.9 (20–81)
Women	53 (52%)	24.9 ± 4.0	48.0 ± 15.9 (23–88)

We detected no significant difference between men and women regarding the age or the number of teeth on dental arch.

doi:10.1371/journal.pone.0165329.t001

Table 2. Details about the number of canals and roots observed in the medium field of view cone-beam CT acquisitions.

ISO	UNS	n	1 canal 1 root	2 canals 1 root	2 canals 2 roots	3 canals 1 root	3 canals 2 roots	3 canals 3 roots	3 canals 4 roots	4 canals 2 roots	4 canals 3 roots	4 canals 4 roots	5 canals 3 roots	5 canals 4 roots
11	8	97	<u>96 (99%)</u>	-	1 (1%)	-	-	-	-	-	-	-	-	-
21	9	95	<u>94 (99%)</u>	-	1 (1%)	-	-	-	-	-	-	-	-	-
31	24	96	<u>84 (88%)</u>	11 (11%)	1 (1%)	-	-	-	-	-	-	-	-	-
41	25	96	<u>83 (86%)</u>	12 (13%)	1 (1%)	-	-	-	-	-	-	-	-	-
12	7	96	<u>95 (99%)</u>	-	1 (1%)	-	-	-	-	-	-	-	-	-
22	10	95	<u>94 (99%)</u>	-	1 (1%)	-	-	-	-	-	-	-	-	-
32	23	100	<u>87 (87%)</u>	12 (12%)	1 (1%)	-	-	-	-	-	-	-	-	-
42	26	99	<u>85 (86%)</u>	13 (13%)	1 (1%)	-	-	-	-	-	-	-	-	-
13	6	94	<u>93 (99%)</u>	-	1 (1%)	-	-	-	-	-	-	-	-	-
23	11	94	<u>93 (99%)</u>	-	1 (1%)	-	-	-	-	-	-	-	-	-
33	22	101	<u>96 (95%)</u>	3 (3%)	2 (2%)	-	-	-	-	-	-	-	-	-
43	27	101	<u>95 (94%)</u>	1 (1%)	5 (5%)	-	-	-	-	-	-	-	-	-
14	5	81	9 (11%)	2 (3%)	<u>66 (81%)</u>	-	1 (1%)	3 (4%)	-	-	-	-	-	-
24	12	84	14 (17%)	1 (1%)	<u>64 (84%)</u>	-	1 (1%)	4 (5%)	-	-	-	-	-	-
34	21	95	<u>82 (87%)</u>	7 (7%)	6 (6%)	-	-	-	-	-	-	-	-	-
44	28	92	<u>81 (88%)</u>	6 (7%)	5 (5%)	-	-	-	-	-	-	-	-	-
15	4	73	<u>49 (67%)</u>	4 (6%)	19 (26%)	-	-	1 (1%)	-	-	-	-	-	-
25	13	74	<u>49 (66%)</u>	3 (4%)	20 (27%)	-	-	2 (3%)	-	-	-	-	-	-
35	20	79	<u>75 (95%)</u>	3 (4%)	1 (1%)	-	-	-	-	-	-	-	-	-
45	29	80	<u>78 (98%)</u>	1 (1%)	1 (1%)	-	-	-	-	-	-	-	-	-
16	3	78	-	-	1 (1%)	-	1 (1%)	37 (48%)	-	1 (1%)	<u>37 (48%)</u>	-	-	1 (1%)
26	14	71	-	-	-	-	-	30 (42%)	-	-	<u>40 (56%)</u>	-	-	1 (2%)
36	19	67	-	2 (3%)	-	-	<u>42 (62%)</u>	1 (2%)	1 (2%)	19 (28%)	2 (3%)	-	-	-
46	30	63	-	-	-	-	<u>46 (73%)</u>	3 (5%)	-	10 (16%)	4 (6%)	-	-	-
17	2	84	1 (1%)	-	-	3 (4%)	3 (4%)	<u>55 (65%)</u>	-	1 (1%)	19 (23%)	2 (2%)	-	-
27	15	83	1 (1%)	-	-	5 (6%)	2 (3%)	<u>48 (58%)</u>	-	-	25 (30%)	1 (1%)	-	1 (1%)
37	18	75	-	-	1 (1%)	-	<u>66 (88%)</u>	5 (7%)	-	1 (1%)	2 (3%)	-	-	-
47	31	81	2 (2%)	-	3 (4%)	-	<u>62 (77%)</u>	8 (10%)	-	3 (4%)	2 (2%)	-	1 (1%)	-

The group in underline italics represented the group taken as a reference. We used the ISO and Universal Numbering System (UNS).

doi:10.1371/journal.pone.0165329.t002

cases, while second molars in general had 3 roots and 3 canals; however, 4-canal, 3-root and 3-canal as well as 1-root morphologies were also present. The mandibular first molar generally had 3 canals and 2 roots or 4 canals and 2 roots (Table 2). The second molar more generally had 3 canals and 2 roots (Table 2). However, the presence of 3 canals and 3 roots was less frequent (left 7%, right 10%).

Table 3 presents the proportion of tooth groups, which have at least one difference from the typical dental anatomy presented in Table 2. For example, a difference compared to reference group in “the mandibular incisors or canines” was attributed to patient if all these teeth didn’t have 1 canal 1 root (Table 2); these differences constituted the variability group. The greatest variability was demonstrated for maxillary molars; 80% of these teeth didn’t have 4 canals 3

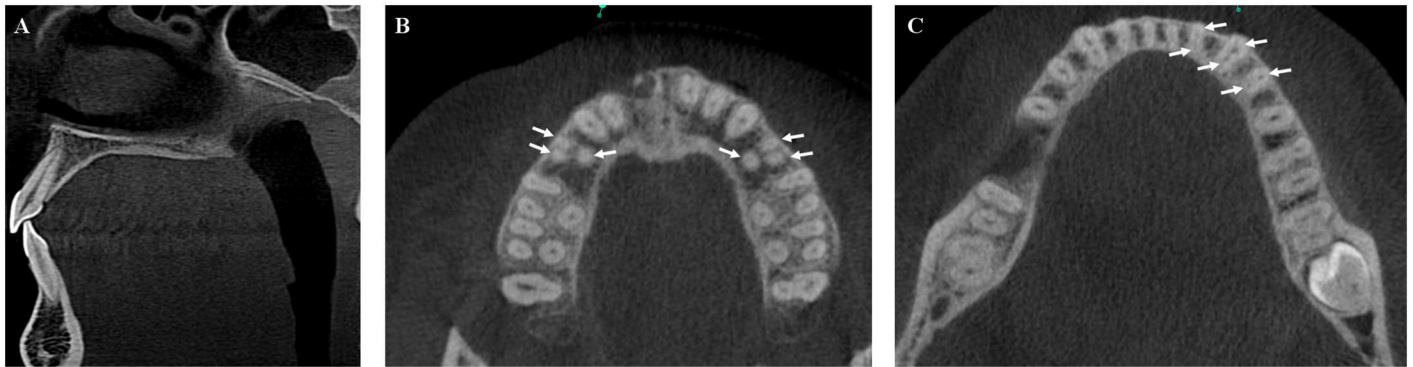

Fig 1. CBCT acquisitions to illustrate the presence of additional canals. (A) Sagittal CBCT image of a mandibular central incisor with one root and two canals. (B) Presence of an additional canal bilaterally in first maxillary premolars (white arrows). (C) Additional canal (white arrows) concomitantly on mandibular incisors, canines and first mandibular premolars, together with no variability on mandibular molars (3 canals, 2 roots).

doi:10.1371/journal.pone.0165329.g001

roots for first maxillary molars and 3 canals 3 roots for second maxillary molars (Table 3). Maxillary premolars and mandibular molars had 54% and 41% variability, respectively. The lower variability was observed for mandibular and maxillary incisors or canines, and mandibular premolars groups (Table 3). Both the number of canals and the number of roots for these teeth were lower in the reference group compared to the variability group (S1 Table).

Bivariate analysis between each predictive factor

Age. An age difference was observed for mandibular premolars: reference group was significantly more aged (48.4 ± 1.7 versus 39.5 ± 3.2 years, $p = 0.04$).

Gender. The proportion of women was lower in the variability group compared to the reference group for maxillary premolars (43% versus 62%, $p = 0.05$), whereas higher for mandibular molars (62% versus 42%, $p = 0.05$). Globally, both the mean number of roots and canals were lower for maxillary premolars and greater for mandibular molars, when women were compared to men (S2 Table).

Jaw factor. An increased variability was observed for mandibular incisors and canines compared to maxillary ($p < 0.001$). The number of canals for incisors, and the number of roots

Table 3. Proportion of tooth groups which have at least a difference from the average dental anatomy presented in Table 2.

	Variability group (difference compared to reference group)	Reference group
Maxillary incisors or canines	1 (1%)	100 (99%)
Mandibular incisors or canines	25 (25%)	77 (75%)
Maxillary premolars	53 (54%)	45 (46%)
<i>Maxillary first premolar</i>	24 (26%)	68 (74%)
<i>Maxillary second premolar</i>	33 (39%)	52 (61%)
Mandibular premolars	18 (18%)	83 (82%)
Maxillary molars	77 (80%)	19 (20%)
<i>Maxillary first molar</i>	48 (55%)	40 (45%)
<i>Maxillary second molar</i>	44 (48%)	48 (52%)
Mandibular molars	39 (41%)	57 (59%)

doi:10.1371/journal.pone.0165329.t003

and canals for canines were increased (Table 2). An increased variability was detected for maxillary premolars compared to mandibular ($p < 0.001$); the proportion of second premolars with 2 canals/2 roots (26–27%) was much higher in maxillary compared to mandibular (1%) (Table 2). Except for 5 and 12, premolar variability involved more canals and more roots. For molars, the greatest variability concerned maxillary ($p < 0.001$); it was found that about half first maxillary molars were concerned by 3 canals/4 roots and half by 3 canals/3 roots, whereas two third mandibular molars were concerned by 3 canals/2 roots and one third by 4 canals/2 roots (Table 2). Finally, we observed that mandibular molar variability implied more canals and more roots, whereas it was not the case for maxillary: first molar variability implied less canals and less roots, second molar variability implied more canals and less roots (S1 Table).

Side factor. The Stuart-Maxwell test did not reveal any significant difference between the right and left side in the present study. However, there appeared to be a trend to more first mandibular molars with 2 roots and 4 canals on the right side ($p = 0.06$).

Multifactorial analysis of presence of additional root canals in specific tooth groups (Table 4)

Taking into account the other tooth groups, age and gender, having variability on a mandibular premolar increased 4 times the risk to have variability on mandibular incisors or canines (OR_[95%] 4.3 [1.2; 15.4]). Conversely, having variability on mandibular incisors or canines increased 4 times the risk to have variability on mandibular premolars (OR_[95%] 3.7 [1.0; 13.2]). Having variability on mandibular premolars decreased the risk to discover variability on mandibular molars (OR_[95%] 0.2 [0.1; 0.9]). Finally, being a male decreased about twice the risk to have a variability on mandibular molars compared to being a female (OR_[95%] 0.4 [0.1; 0.9]). While on some occasions significant, the factor “age” overall contributed minimally to models.

The first dimension of MCA always explained at least 67% of the principal inertia, while the second dimension explained only 12%, and the following dimensions less than 3% (Fig 2). This tended to validate the one-dimensionality. Group A showed correspondence between 2-canals maxillary incisor and canines and 5-canals maxillary molars. Group B and C revealed some

Table 4. Results from logistic regression analysis (90 observations).

OR _[95%]	Dependent variable					
	Maxillary incisors/ canines	Mandibular incisors/ canines	Maxillary premolars	Mandibular premolars	Maxillary molars	Mandibular molars
Explanatory variables						
Maxillary incisors/ canines	-	-	-	-	-	-
Mandibular incisors/ canines	-	-	0.7 [0.2;1.9]	<u>3.7 [1.1;13.2]</u>	1.8 [0.4;7.8]	1.7 [0.5;4.8]
Maxillary premolars	-	0.6 [0.2;1.8]	-	2.2 [0.6;7.8]	0.5 [0.1;1.5]	1.4 [0.5;3.6]
Mandibular premolars	-	<u>4.3 [1.2;15.4]</u>	2 [0.6;6.8]	-	4.3 [0.5;38.8]	<u>0.2 [0.1;0.9]</u>
Maxillary molars	-	2 [0.5;8.7]	0.5 [0.1;1.5]	4 [0.5;42.9]	-	0.7 [0.2;2.1]
Mandibular molars	-	1.7 [0.6;4.9]	1.4 [0.5;3.6]	0.3 [0.1;1.1]	0.7 [0.2;2.2]	-
Age	-	<u>1.1 [1;1.1]</u>	1 [0.9;1.1]	<u>0.9 [0.8;0.9]</u>	1 [0.9;1.1]	<u>0.9 [0.8;0.9]</u>
Sex	-	2.6 [0.8;7.6]	2.2 [0.8;5.4]	0.6 [0.2;2.3]	0.7 [0.2;2.1]	<u>0.4 [0.1;0.9]</u>

The odds ratio (OR = e^β) for each covariate in underline italics represented significant results at 95% confidence interval (OR_[95%]).

doi:10.1371/journal.pone.0165329.t004

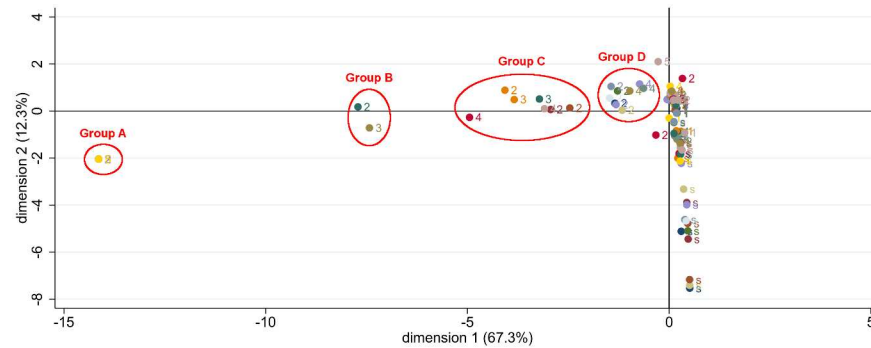


Fig 2. Multiple correspondence analysis MCA. When the tooth was absent, the number of canals was considered as a new category “s” to be included in the 102 observations analysis of the MCA.

doi:10.1371/journal.pone.0165329.g002

correspondence between additional canal on maxillary and mandibular premolars. Group C and D identified some correspondence between additional canal on mandibular incisors or canines and molars (Table 5).

Discussion

The visualization of all canals is considered essential in endodontic therapy. CBCT images are known to provide three-dimensional information about the presence of additional canals (Fig 1). The use of CBCT imaging with a resolution of 200µm is a limitation of the present study. For example the coarser resolution creates uncertainty when describing canal anatomy according to Vertucci’s classification [3,14]. Also, studies using an operating microscope, sectioning methodology or clearing technique revealed a higher canal detection rate than CBCT examinations [6]. In fact, due to the discrete grid of a CBCT reconstruction matrix, any canal with a maximum cross-sectional dimension of less than 400µm could, in a worst-case scenario, escaped detection in this data set.

Using CBCT acquisitions of 90x150mm FOV, entire upper and lower dental arches can be visualized. Consequently, intra-individual dental variability, the relationship between the additional canals found among the different groups of teeth, may be analyzed.

Consequently, this study will bring elements for the clinician, allowing it to anticipate the degree of technical difficulty and any radiological investigation based on anatomical variations already discovered on other teeth. For example, discovering two canals in a mandibular incisor multiplied by 4 the risk to discover two canals in a mandibular premolar, and conversely.

In the maxillary incisor-canine group, only slightly over 1% of teeth had more than one root or canal. These results are consistent with the literature [14]. Observation of mandibular incisor-canine teeth highlighted the variable canal anatomy of the incisors. They had 2 canals in one root in 11% to 13%. The presence of 2 canals was found in previous studies but in variable proportions ranging from 0.3% to 45.3% depending on the techniques used [15,16]. The maxillary first premolars showed a large incidence of teeth with 2 roots and 2 canals, observed in between 81% to 84%. These results were consistent with previous studies [17]. A third root and a third canal were present in our study in less than 5% of cases. The maxillary second premolars frequently had a single root and a single canal per root. Others studies differed, with either a higher [18] or a lower incidence of 2 canals per root [19]. The presence of 3 canals and 3 roots was rare in our study, at less than 3%. Mandibular premolars frequently had a single root in between 94% to 99% of the cases, which is similar to findings by Cleghorn *et al.* [20,21]. In our study, we mainly found a single canal between 87% to 98%. However, the mandibular first

Table 5. Details about each group according to MCA analysis (ISO system).

Group A	11: 2-canals
	12: 2-canals
	13: 2-canals
	21: 2-canals
	22: 2-canals
	23: 2-canals
	15: 3-canals
	16: 5-canals
	26: 5-canals
	27: 5-canals
Group B	25: 3-canals
	45: 2-canals
Group C	14: 3-canals
	24: 3-canals
	33: 2-canals
	43: 2-canals
	35: 2-canals
	37: 4-canals
	47: 4-canals
Group D	17: 4-canals
	31: 2-canals
	32: 2-canals
	34: 2-canals
	41: 2-canals
	42: 2-canals
	44: 2-canals
	36: 4-canals
	46: 4-canals

doi:10.1371/journal.pone.0165329.t005

premolar had 2 canals in 12% (right) to 13% of cases (left). The prevalence appears to be lower than that observed by Cleghorn *et al.* [20], who found that 24.2% of first premolars had two or more canals.

Several authors have studied maxillary molar anatomy. The presence of 3 separate roots was the most common configuration of the maxillary first and second molars [3]. In addition, the first molar had 3 canals for 3 roots in 42% (left) to 48% (right) and 4 canals for 3 roots in 48% (right) to 56% (left). The results showed that around 5% of maxillary first molars did not have three roots. These results were consistent with previous studies of Chinese, Korean, Brazilian and Indian populations [7,10,12]. However, other studies of Burmese or Thai populations [22,23] showed 3 separate roots for all maxillary first molars. These differences suggested the potential role of ethnicity [10]. Nevertheless, the relationship of ethnic background to anatomic variants was not explored in current sample; it is a potential limitation for the current study since majority of the population studied is expected to be Caucasian.

The morphology most commonly observed for maxillary second molars was 3 roots, with one canal in each root (left 58%, right 65%). The presence of a fourth canal was recorded in 23% (right) to 30% (left), which was similar to previous studies [10,22,23]. Mandibular molars have also been studied in the literature [2,10,12,24]. The mandibular first molar had two roots

in 89% (right) to 91% (left) of cases. The most common finding was 3 canals and 2 roots (62% on the left and 73% on the right), according to previous studies [10,25]. The role of ethnicity in the morphology of the mandibular first molar has been stressed in studies, with a higher prevalence of teeth with 3 roots in East Asian populations [25]. With regard to the mandibular second molar, the most frequent morphology was 2 separate roots and 3 canals. Although the literature concluded that this was the most common configuration, significant differences were observed between different populations [5,10,24].

The second part of our study objectives was to conduct logistic regression analyses to obtain the risk to discover additional canal on a group of teeth when a variability was found on another group of teeth. To the best of our knowledge, few investigations have looked for left-right symmetry in pairs of opposite teeth, and when such studies have been performed, they have only considered one type of tooth and not the entire dentition [26,27]. In our study, the Stuart-Maxwell test did reveal a trend of a difference between the left and right mandibular molars ($p = 0.06$). First left mandibular molars in this study have a tendency to more canals and less roots compared to the first right mandibular molars. Such results were consistent with Kim *et al.* which found side asymmetry, with a right-sided predominance for extra distal roots and a left-sided predominance for extra distal canals [25].

Root canal anatomy studies with CBCT have described a single type of tooth [18,25] or a group of teeth [28], but not all teeth present on the maxillary and mandibular arches. These studies often used a small FOV with a small voxel size (e.g. $76\mu\text{m}$), which makes it possible to see the root canal anatomy in detail. Such acquisitions were mainly performed during clinical endodontic practice, more precisely in the presence of clinical signs and symptoms (2015 AAE and AAOMR Joint Position Statement). Accordingly, there was an increased risk to discover more complex root canal anatomies (risk of teeth selection bias). However, studies to predict additional canals need the visualization of all the teeth in one examination (*i.e.* with medium FOV). Independently from the other variables (*i.e.* age, gender, other teeth), the presence of an additional root canal on a mandibular incisor increases the risk of having an additional root canal on a mandibular premolar. The variability on mandibular premolars and molars appears to decrease with age. This can be explained by the root canal mineralization and highlights the difficulty to visualize small additional canals. Bivariate and multivariate analyses identified some association between gender and the presence of an additional canal. The increased variability of second maxillary premolars in men compared to women was reported in some studies [29,30]. Mandibular molar root variability is more contrasted: many studies have found male predominance [31], but some studies have also reported an increased anatomical variation in women compared to men, as we pointed-out [32].

Even if a probabilistic model has been reported in endodontic research to obtain probability of an additional root in mandibular molars, the use of MCA in statistical analyses is a new and original approach. This correspondence analysis model enabled us to form four groups with different number of canals.

Conclusions

The visualization of all canals is considered relevant in endodontic therapy. Can the presence of an additional canal on one tooth predict the chance to discover an additional canal on another tooth in the same patient? Although CBCT examinations are conducted in the first intention of making a diagnosis or prognostic evaluation, medium FOV acquisitions could be used as an initial database thus furnishing preliminary evaluations and information. Multi-institutional studies may be undertaken to collect more CBCT images and perform additional statistical analyses.

Supporting Information

S1 Table. Considering the presence or absence of variability in each tooth group, the mean number \pm standard deviation of canals and roots for each tooth were provided.

(DOCX)

S2 Table. For each tooth, the mean number \pm standard deviation of canals and roots was presented, for men and women.

(DOCX)

Acknowledgments

We thank E. Coudrais for the CBCT database and N. Crowte for language revision. We acknowledge the statistical advice provided by J.N. Vergnes and G. Fernandez de Grado. We also acknowledge the research platform of the Toulouse Dental Faculty.

Author Contributions

Conceptualization: BA NT MG DM.

Data curation: PM BA EM DM.

Formal analysis: PM BA DM.

Funding acquisition: DM.

Investigation: PM BA EM DM.

Methodology: PM BA EM MG DM.

Project administration: NT DM.

Resources: NT DM.

Supervision: NT MG DM.

Validation: OP EM NT DM.

Visualization: PM BA DM.

Writing – original draft: PM BA OP DM.

Writing – review & editing: PM BA OP NT MG DM.

References

1. Sert S, Bayirli GS. Evaluation of the root canal configurations of the mandibular and maxillary permanent teeth by gender in the Turkish population. *J Endod.* 2004; 30: 391–398. PMID: [15167464](#)
2. Celikten B, Tufenkci P, Aksoy U, Kalender A, Kermeoglu F, Dabaj P, et al. Cone beam CT evaluation of mandibular molar root canal morphology in a Turkish Cypriot population. *Clin Oral Investig.* 2016; doi: [10.1007/s00784-016-1742-2](#) PMID: [26850623](#)
3. Vertucci FJ. Root canal morphology and its relationship to endodontic procedures. *Endod Top.* 2005; 10: 3–29. doi: [10.1111/j.1601-1546.2005.00129.x](#)
4. Kottoor J, Albuquerque D, Velmurugan N, Kuruvilla J. Root anatomy and root canal configuration of human permanent mandibular premolars: a systematic review. *Anat Res Int.* 2013; 2013: 254250. doi: [10.1155/2013/254250](#) PMID: [24455268](#)
5. Neelakantan P, Subbarao C, Subbarao CV. Comparative evaluation of modified canal staining and clearing technique, cone-beam computed tomography, peripheral quantitative computed tomography, spiral computed tomography, and plain and contrast medium-enhanced digital radiography in studying

- root canal morphology. *J Endod.* 2010; 36: 1547–1551. doi: [10.1016/j.joen.2010.05.008](https://doi.org/10.1016/j.joen.2010.05.008) PMID: [20728725](https://pubmed.ncbi.nlm.nih.gov/20728725/)
6. Baratto Filho F, Zaitter S, Haragushiku GA, de Campos EA, Abuabara A, Correr GM. Analysis of the internal anatomy of maxillary first molars by using different methods. *J Endod.* 2009; 35: 337–342. doi: [10.1016/j.joen.2008.11.022](https://doi.org/10.1016/j.joen.2008.11.022) PMID: [19249591](https://pubmed.ncbi.nlm.nih.gov/19249591/)
 7. Zheng Q, Wang Y, Zhou X, Wang Q, Zheng G, Huang D. A cone-beam computed tomography study of maxillary first permanent molar root and canal morphology in a Chinese population. *J Endod.* 2010; 36: 1480–1484. doi: [10.1016/j.joen.2010.06.018](https://doi.org/10.1016/j.joen.2010.06.018) PMID: [20728713](https://pubmed.ncbi.nlm.nih.gov/20728713/)
 8. Hoen MM, Pink FE. Contemporary endodontic retreatments: an analysis based on clinical treatment findings. *J Endod.* 2002; 28: 834–836. doi: [10.1097/00004770-200212000-00010](https://doi.org/10.1097/00004770-200212000-00010) PMID: [12489654](https://pubmed.ncbi.nlm.nih.gov/12489654/)
 9. Weine FS, Healey HJ, Gerstein H, Evanson L. Canal configuration in the mesiobuccal root of the maxillary first molar and its endodontic significance. 1969. *J Endod.* 2012; 38: 1305–1308. doi: [10.1016/j.joen.2012.08.005](https://doi.org/10.1016/j.joen.2012.08.005) PMID: [22980167](https://pubmed.ncbi.nlm.nih.gov/22980167/)
 10. Silva EJNL, Nejaim Y, Silva AIV, Haiter-Neto F, Zaia AA, Cohenca N. Evaluation of root canal configuration of maxillary molars in a Brazilian population using cone-beam computed tomographic imaging: an in vivo study. *J Endod.* 2014; 40: 173–176. doi: [10.1016/j.joen.2013.10.002](https://doi.org/10.1016/j.joen.2013.10.002) PMID: [24461399](https://pubmed.ncbi.nlm.nih.gov/24461399/)
 11. Lee J-H, Kim K-D, Lee J-K, Park W, Jeong JS, Lee Y, et al. Mesiobuccal root canal anatomy of Korean maxillary first and second molars by cone-beam computed tomography. *Oral Surg Oral Med Oral Pathol Oral Radiol Endod.* 2011; 111: 785–791. doi: [10.1016/j.tripleo.2010.11.026](https://doi.org/10.1016/j.tripleo.2010.11.026) PMID: [21439860](https://pubmed.ncbi.nlm.nih.gov/21439860/)
 12. Neelakantan P, Subbarao C, Ahuja R, Subbarao CV, Gutmann JL. Cone-beam computed tomography study of root and canal morphology of maxillary first and second molars in an Indian population. *J Endod.* 2010; 36: 1622–1627. doi: [10.1016/j.joen.2010.07.006](https://doi.org/10.1016/j.joen.2010.07.006) PMID: [20850665](https://pubmed.ncbi.nlm.nih.gov/20850665/)
 13. Bilfeld MF, Dedouit F, Sans N, Rousseau H, Rougé D, Telmon N. Ontogeny of Size and Shape Sexual Dimorphism in the Pubis: A Multislice Computed Tomography Study by Geometric Morphometry. *J Forensic Sci.* 2015; 60: 1121–1128. doi: [10.1111/1556-4029.12761](https://doi.org/10.1111/1556-4029.12761) PMID: [25782723](https://pubmed.ncbi.nlm.nih.gov/25782723/)
 14. Vertucci FJ. Root canal anatomy of the human permanent teeth. *Oral Surg Oral Med Oral Pathol.* 1984; 58: 589–599. PMID: [6595621](https://pubmed.ncbi.nlm.nih.gov/6595621/)
 15. Madeira MC, Hetem S. Incidence of bifurcations in mandibular incisors. *Oral Surg Oral Med Oral Pathol.* 1973; 36: 589–591. PMID: [4517109](https://pubmed.ncbi.nlm.nih.gov/4517109/)
 16. Leoni GB, Versiani MA, Pécora JD, Damião de Sousa-Neto M. Micro-computed tomographic analysis of the root canal morphology of mandibular incisors. *J Endod.* 2014; 40: 710–716. doi: [10.1016/j.joen.2013.09.003](https://doi.org/10.1016/j.joen.2013.09.003) PMID: [24767569](https://pubmed.ncbi.nlm.nih.gov/24767569/)
 17. Atieh MA. Root and canal morphology of maxillary first premolars in a Saudi population. *J Contemp Dent Pract.* 2008; 9: 46–53. PMID: [18176648](https://pubmed.ncbi.nlm.nih.gov/18176648/)
 18. Yang L, Chen X, Tian C, Han T, Wang Y. Use of cone-beam computed tomography to evaluate root canal morphology and locate root canal orifices of maxillary second premolars in a Chinese subpopulation. *J Endod.* 2014; 40: 630–634. doi: [10.1016/j.joen.2014.01.007](https://doi.org/10.1016/j.joen.2014.01.007) PMID: [24767555](https://pubmed.ncbi.nlm.nih.gov/24767555/)
 19. Kartal N, Özçelik B, Cimilli H. Root canal morphology of maxillary premolars. *J Endod.* 1998; 24: 417–419. doi: [10.1016/S0099-2399\(98\)80024-1](https://doi.org/10.1016/S0099-2399(98)80024-1) PMID: [9693586](https://pubmed.ncbi.nlm.nih.gov/9693586/)
 20. Cleghorn BM, Christie WH, Dong CCS. The root and root canal morphology of the human mandibular second premolar: a literature review. *J Endod.* 2007; 33: 1031–1037. doi: [10.1016/j.joen.2007.03.020](https://doi.org/10.1016/j.joen.2007.03.020) PMID: [17931927](https://pubmed.ncbi.nlm.nih.gov/17931927/)
 21. Cleghorn BM, Christie WH, Dong CCS. The root and root canal morphology of the human mandibular first premolar: a literature review. *J Endod.* 2007; 33: 509–516. doi: [10.1016/j.joen.2006.12.004](https://doi.org/10.1016/j.joen.2006.12.004) PMID: [17437863](https://pubmed.ncbi.nlm.nih.gov/17437863/)
 22. Ng YL, Aung TH, Alavi A, Gulabivala K. Root and canal morphology of Burmese maxillary molars. *Int Endod J.* 2001; 34: 620–630. PMID: [11762499](https://pubmed.ncbi.nlm.nih.gov/11762499/)
 23. Pattanshetti N, Gaidhane M, Al Kandari AM. Root and canal morphology of the mesiobuccal and distal roots of permanent first molars in a Kuwait population—a clinical study. *Int Endod J.* 2008; 41: 755–762. doi: [10.1111/j.1365-2591.2008.01427.x](https://doi.org/10.1111/j.1365-2591.2008.01427.x) PMID: [18637850](https://pubmed.ncbi.nlm.nih.gov/18637850/)
 24. Gulabivala K, Aung TH, Alavi A, Ng YL. Root and canal morphology of Burmese mandibular molars. *Int Endod J.* 2001; 34: 359–370. PMID: [11482719](https://pubmed.ncbi.nlm.nih.gov/11482719/)
 25. Kim S-Y, Kim BS, Woo J, Kim Y. Morphology of mandibular first molars analyzed by cone-beam computed tomography in a Korean population: variations in the number of roots and canals. *J Endod.* 2013; 39: 1516–1521. doi: [10.1016/j.joen.2013.08.015](https://doi.org/10.1016/j.joen.2013.08.015) PMID: [24238439](https://pubmed.ncbi.nlm.nih.gov/24238439/)
 26. Plotino G, Tocci L, Grande NM, Testarelli L, Messineo D, Ciotti M, et al. Symmetry of root and root canal morphology of maxillary and mandibular molars in a white population: a cone-beam computed tomography study in vivo. *J Endod.* 2013; 39: 1545–1548. doi: [10.1016/j.joen.2013.09.012](https://doi.org/10.1016/j.joen.2013.09.012) PMID: [24238444](https://pubmed.ncbi.nlm.nih.gov/24238444/)

27. Guo J, Vahidnia A, Sedghizadeh P, Enciso R. Evaluation of root and canal morphology of maxillary permanent first molars in a North American population by cone-beam computed tomography. *J Endod.* 2014; 40: 635–639. doi: [10.1016/j.joen.2014.02.002](https://doi.org/10.1016/j.joen.2014.02.002) PMID: [24767556](https://pubmed.ncbi.nlm.nih.gov/24767556/)
28. Kim Y, Lee S-J, Woo J. Morphology of maxillary first and second molars analyzed by cone-beam computed tomography in a Korean population: variations in the number of roots and canals and the incidence of fusion. *J Endod.* 2012; 38: 1063–1068. doi: [10.1016/j.joen.2012.04.025](https://doi.org/10.1016/j.joen.2012.04.025) PMID: [22794206](https://pubmed.ncbi.nlm.nih.gov/22794206/)
29. Al-Ghananeem MMF, Haddadin K, Al-Khreisat AS, Al-Weshah M, Al-Habahbeh N. The number of roots and canals in the maxillary second premolars in a group of Jordanian population. *Int J Dent.* 2014; 2014: 797692. doi: [10.1155/2014/797692](https://doi.org/10.1155/2014/797692) PMID: [25530761](https://pubmed.ncbi.nlm.nih.gov/25530761/)
30. Bulut DG, Kose E, Ozcan G, Sekerci AE, Canger EM, Sisman Y. Evaluation of root morphology and root canal configuration of premolars in the Turkish individuals using cone beam computed tomography. *Eur J Dent.* 2015; 9: 551–557. doi: [10.4103/1305-7456.172624](https://doi.org/10.4103/1305-7456.172624) PMID: [26929695](https://pubmed.ncbi.nlm.nih.gov/26929695/)
31. Song JS, Kim S-O, Choi B-J, Choi H-J, Son H-K, Lee J-H. Incidence and relationship of an additional root in the mandibular first permanent molar and primary molars. *Oral Surg Oral Med Oral Pathol Oral Radiol Endod.* 2009; 107: e56–60. doi: [10.1016/j.tripleo.2008.09.004](https://doi.org/10.1016/j.tripleo.2008.09.004) PMID: [19101484](https://pubmed.ncbi.nlm.nih.gov/19101484/)
32. Park J-B, Kim N, Park S, Kim Y, Ko Y. Evaluation of root anatomy of permanent mandibular premolars and molars in a Korean population with cone-beam computed tomography. *Eur J Dent.* 2013; 7: 94–101. PMID: [23407684](https://pubmed.ncbi.nlm.nih.gov/23407684/)