

## Case Report

# Hydrocephalus due to Membranous Obstruction of Magendie's Foramen

Konstantinos Kasapas, M.D., Dimitrios Varthalitis, M.D., Nikolaos Georgakoulis, M.D., Ph.D., Georgios Orphanidis, M.D.

Department of Neurosurgery, Athens General Hospital "G. Gennimatas", Athens, Greece

We report a case of non communicating hydrocephalus due to membranous obstruction of Magendie's foramen. A 37-year-old woman presented with intracranial hypertension symptoms caused by the occlusion of Magendie's foramen by a membrane probably due to arachnoiditis. As far as the patient's past medical history is concerned, an Epstein-Barr virus infectious mononucleosis was described. Fundoscopic examination revealed bilateral papilledema. Brain magnetic resonance imaging demonstrated a significant ventricular dilatation of all ventricles and turbulent flow of cerebrospinal fluid (CSF) in the fourth ventricle as well as back flow of CSF through the Monro's foramen to the lateral ventricles. The patient underwent a suboccipital craniotomy with C1 laminectomy. An occlusion of Magendie's foramen by a thickened membrane was recognized and it was incised and removed. We confirm the existence of hydrocephalus caused by fourth ventricle outflow obstruction by a membrane. The nature of this rare entity is difficult to demonstrate because of the complex morphology of the fourth ventricle. Treatment with surgical exploration and incision of the thickened membrane proved to be a reliable method of treatment without the necessity of endoscopic third ventriculostomy or catheter placement.

**Key Words :** Hydrocephalus · Magendie's foramen · Arachnoiditis · Obstruction.

## INTRODUCTION

In children obstruction of Magendie's foramen is mainly congenital while in adults it is mostly acquired. In this paper we present a rare case of hydrocephalus caused by the occlusion of Magendie's foramen by a membrane due to arachnoiditis.

## CASE REPORT

### History and examination

A 37-year-old woman was admitted to our emergency department with the chief complaint of headache that has gradually been deteriorating in the last month and was accompanied by blurred vision. The headache was worst in the morning and was localized in the frontal and occipital region. The patient also mentioned two episodes of vomiting and phonophobia along with the headache the last week. Physical examination was normal, however the patient complained for mild unsteadiness and recent memory loss. No loss of bladder control or urgency to urination was mentioned. As far as the patient's past medical history is concerned, an Epstein-Barr virus (EBV) infectious mononucleosis was described. The rest medical history was unremarkable.

For evaluation of her symptoms the initial workup included a brain magnetic resonance imaging (MRI) which revealed significant ventricular dilatation of lateral, third and fourth ventricles with subependymal edema, without any gadolinium enhancement of the ventricular system or obvious obstruction. A T2W TSE study was also performed and demonstrated a turbulent flow of cerebrospinal fluid (CSF) in the fourth ventricle and back flow of CSF through the Monro's foramen to the lateral ventricles (Fig. 1). The patient had also undergone fundoscopic examination that showed bilateral papilledema.

### Operation

Based on the above findings a decompression on the foramen magnum was decided having established an obstruction at that level. The patient underwent a suboccipital craniotomy with C1 laminectomy. An occlusion of Magendie's foramen by a thickened membrane was recognized and the membrane was incised and removed, thus restoring the normal flow of cerebrospinal fluid between the fourth ventricle and the cerebellomedullary cistern (Fig. 2).

### Postoperative course

The postoperative course was uneventful. The new fundoscop-

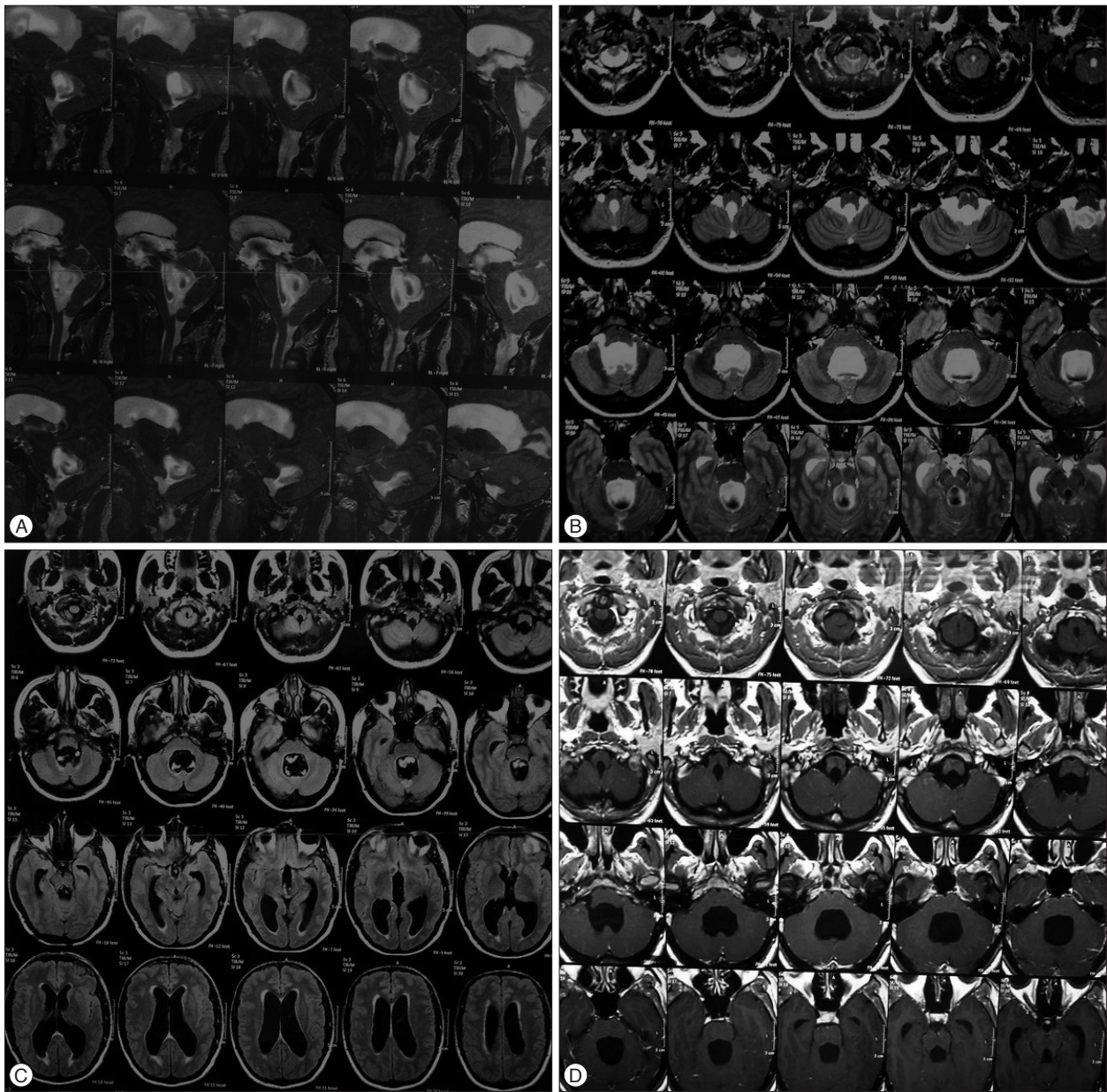
• Received : February 9, 2014 • Revised : February 9, 2014 • Accepted : April 26, 2014

• Address for reprints : Konstantinos Kasapas, M.D.

Department of Neurosurgery, Athens General Hospital "G. Gennimatas", 154 Mesogeion St. Athens, Athens 11527, Greece

Tel : +30-2107768365, Fax : +30-2107768364, E-mail : kostaskasapas@gmail.com

• This is an Open Access article distributed under the terms of the Creative Commons Attribution Non-Commercial License (<http://creativecommons.org/licenses/by-nc/3.0>) which permits unrestricted non-commercial use, distribution, and reproduction in any medium, provided the original work is properly cited.

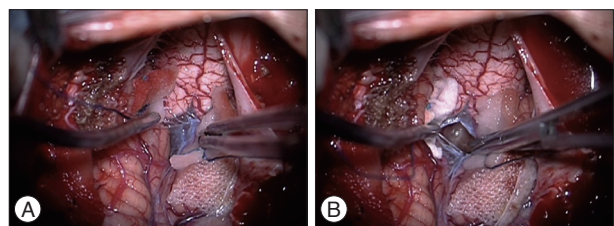


**Fig. 1.** A : Preoperative sagittal T2W TSE MRI showing turbulent flow of CSF in the fourth ventricle and back flow of CSF through the Monro's foramen to the lateral ventricles. B : Preoperative axial T2 MRI showing significant dilatation of fourth ventricle with turbulent flow of CSF. C : Preoperative axial T1 MRI showing dilatation of third, fourth and lateral ventricles. D : Preoperative axial T1 MRI showing significant dilatation of fourth ventricle. CSF : cerebrospinal fluid.

ic examination in two weeks revealed a reduction in papilledema and the second MRI scan showed a marked decrease in the size of the ventricles, showing therefore that cerebrospinal fluid flow through the ventricular system and subarachnoid space was restored (Fig. 3).

**DISCUSSION**

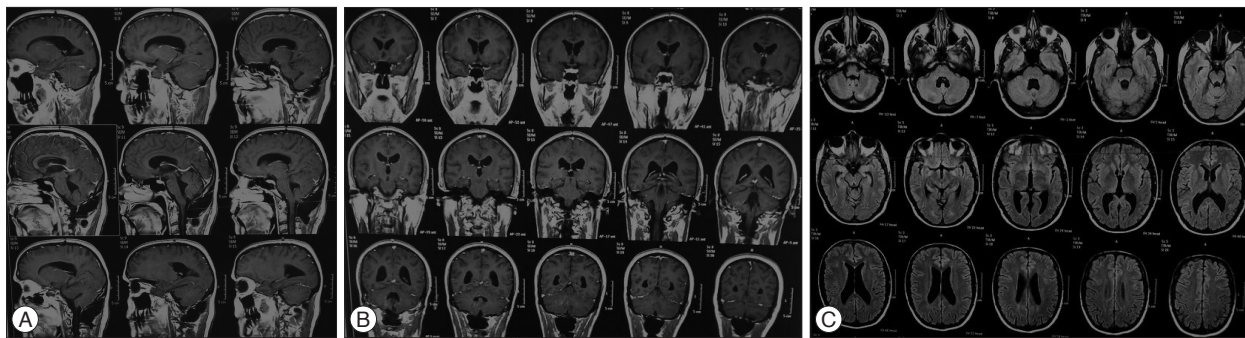
Membranous obstruction of the Magendie's foramen is a rare case of non communicating quadrivertricular hydrocephalus. In children is usually congenital and related with Dandy-Walker Syndrome, Arnold-Chiari malformation, tuberous sclerosis, spi-



**Fig. 2.** A : Perioperative photo showing the occlusion of Magendie's foramen by the membrane. B : Perioperative photo showing Magendie's foramen after the incision and removal of the membrane.

na bifida, platybasia, achondroplasia, basilar impression and atlanto-occipital fusion<sup>9)</sup>. In adults it is mostly acquired rather than





**Fig. 3.** A : Postoperative sagittal T1 MRI showing marked decrease in the size of the ventricles. B : Postoperative coronal T1 MRI showing marked decrease in the size of the ventricles. C : Postoperative axial T1 MRI showing marked decrease in the size of the ventricles.

congenital<sup>9)</sup>. Acquired ventricular outlet obstructions are reported in adults as well as children and generally occur in infection (meningoencephalitis, prenatal infection, shunting procedures, granulomatosis, venereal disease, influenza, ear-ocular-nasopharyngeal infection, Toxoplasmosis, Cysticercosis), head trauma, intraventricular hemorrhage, tumors or Arnold-Chiari malformation<sup>9,10)</sup>.

Review of the literature regarding adults revealed only few cases of congenital membranous obstruction of the foramen of Magendie in which the obstruction was not associated with systemic illness or trauma<sup>2,3,6,7,9)</sup>. Also only few cases related to idiopathic stenosis of the foramina of Magendie have been described<sup>1,4,5,8,10,12)</sup>. The rare published cases of hydrocephalus caused by stenosis of the foramina of Magendie are usually associated with another disease, mainly Chiari Type I malformation<sup>5)</sup>. In our case we present the occlusion of Magendie's foramen by a membrane due to arachnoiditis with the high suspicion of an EBV infectious mononucleosis<sup>11)</sup>.

In the past the diagnosis was based on indirect data resulting from invasive methods such as ventriculography while in recent years it mainly results from brain MRI, MRI CSF flow and direct surgical exploration. However direct visualization of the membrane on MRI has been described in two cases<sup>10)</sup>. Although MRI CSF flow study is more sensitive for the cerebral aqueduct, which is of smaller diameter and with an identifiable flow in the cephalocaudal axis than the fourth ventricle which is a larger structure and also has three outlets, this study is also very helpful in demonstrating Magendie's foramen obstructions. In our case, brain MRI with T2 weighted turbo spin-echo study was critical for the patient's management, as it demonstrated a turbulent flow of CSF in the third and fourth ventricle and back flow of CSF through the Monro's foramen to the lateral ventricles.

Preoperative radiological findings are very useful in deciding the appropriate surgical approach which includes the incision and removal of membrane with or without endoscopic third ventriculostomy (EVT) and CSF shunting<sup>5,10)</sup>. The efficacy of ETV in the treatment of obstructive hydrocephalus and the absence of complications related to the presence of a CSF shunt, have encouraged the use of this method for treating obstructive hydrocephalus, including obstacles situated to the cerebral aqueduct

and, in the fourth ventricle and the foramen of Magendie and Luschka as well<sup>5)</sup>. Regarding our case a suboccipital craniotomy with C1 laminectomy was performed and the thickened arachnoid was incised and removed at the foramen of Magendie. This procedure restored the normal flow of cerebrospinal fluid between the fourth ventricle and the cisterna magna and was considered as curative because the patient remained free of symptoms thereafter. Nevertheless, a ventriculo-cisternal shunting and EVT have been proposed in case of a possible restenosis but taking the risk of catheter infection in the first case<sup>1,10)</sup>.

## CONCLUSION

In this study we confirm the existence of hydrocephalus caused by fourth ventricle outflow obstruction (Magendie's foramen) by a membrane probably on the basis of arachnoiditis. The obstructive nature of this rare entity is difficult to demonstrate, even on MRI images, because of the complex morphology of the fourth ventricle. Treatment with surgical exploration and incision of the thickened membrane proved to be a reliable method of treatment without the necessity of EVT or catheter placement.

## References

- Amacher AL, Page LK : Hydrocephalus due to membranous obstruction of the fourth ventricle. *J Neurosurg* 35 : 672-676, 1971
- Hashish H, Guenot M, Mertens P, Sindou M : [Chronic hydrocephalus in an adult due to congenital membranous occlusion of the apertura mediana ventriculi quarti (foramen of Magendie). Report of two cases and review of the literature]. *Neurochirurgie* 45 : 232-236, 1999
- Holland HC, Graham WL : Congenital atresia of the foramina of Luschka and Magendie with hydrocephalus: report of a case in an adult. *J Neurosurg* 15 : 688-694, 1958
- Huang YC, Chang CN, Chuang HL, Scott RM : Membranous obstruction of the fourth ventricle outlet. A case report. *Pediatr Neurosurg* 35 : 43-47, 2001
- Karachi C, Le Guérinel C, Brugières P, Melon E, Decq P : Hydrocephalus due to idiopathic stenosis of the foramina of Magendie and Luschka. Report of three cases. *J Neurosurg* 98 : 897-902, 2003
- Kim JH, Chung YG, Lee NJ, Kim SH, Lee HK, Lee KC, et al : Unilateral hydrocephalus in congenital atresia of the foramen of Monro. *J Korean Neurosurg Soc* 29 : 434-437, 2000
- Maloney AF : Two cases of congenital atresia of the foramina of Magendie

- and Luschka. *J Neurol Neurosurg Psychiatry* 17 : 134-138, 1954
8. Osaka Y, Shin H, Sugawa N, Yoshino E, Horikawa Y, Yamaki T, et al. : ["Disproportionately large, communicating fourth ventricle" due to membranous obstruction of Magendie's foramen]. *No Shinkei Geka* 23 : 429-433, 1995
  9. Rifkinson-Mann S, Sachdev VP, Huang YP : Congenital fourth ventricular midline outlet obstruction. Report of two cases. *J Neurosurg* 67 : 595-599, 1987
  10. Rougier A, Ménégon P : MRI evidence of membranous occlusion of the foramen of Magendie. *Acta Neurochir (Wien)* 151 : 693-694, 2009
  11. van der Klooster JM, van Saase JL, Grootendorst AF, Sinnige HA : [Meningo-encephalitis and hydrocephalus caused by Epstein-Barr virus]. *Ned Tijdschr Geneesk* 142 : 650-654, 1998
  12. Yoshioka S, Matsukado Y, Uemura S, Nagahiro S, Ootsuka T, Yadomi C : [Hydrocephalus due to membranous obstruction of the fourth ventricle aperture]. *No Shinkei Geka* 13 : 1135-1139, 1985