

Laparoscopic Ablative and Reconstructive Surgeries in Genitourinary Tuberculosis

Rahul Gupta, MCh Urology, Lalgudi N Dorairajan, MCh Urology,
K Muruganandham, MCh Urology, Ramanitharan Manikandan, MCh Urology,
Avijit Kumar MCh Urology, Santosh Kumar, MCh Urology

ABSTRACT

Background and Objectives: Laparoscopy is the present standard of care for urologic diseases. Laparoscopy in renal tuberculosis (genitourinary tuberculosis) is difficult because of inflammation and fibrosis associated with the disease. We present the outcome of our experience of laparoscopy in genitourinary tuberculosis, both ablative and reconstructive.

Methods: The detailed data of patients with genitourinary tuberculosis who underwent laparoscopic surgeries between January 2011 and September 2012 were reviewed. Indications, type of surgery, duration, blood loss, intraoperative problems, postoperative outcomes, and follow-up details were noted.

Results: Overall, 7 laparoscopic procedures were performed: 5 nephrectomies, 1 ureteric reimplantation with psoas hitch, and 1 combined nephrectomy and laparoscopy-assisted Mainz II pouch reconstruction. The mean operative time was 192 minutes for nephrectomy, 210 minutes for ureteric reimplantation, and 480 minutes for nephrectomy with Mainz II pouch reconstruction. There were no conversions to open surgery. The mean amount of blood loss was 70 mL for the nephrectomies, 100 mL for ureteric reimplantation, and 200 mL for nephrectomy with Mainz II pouch reconstruction. In 5 of 6 patients who underwent nephrectomy, there was severe perinephric and peripelvic fibrosis posing difficulty in dissection. However, the renal vessels could be controlled individually. The mean postoperative hospital stay was 3 days for the nephrectomies, 5 days for the ureteric reimplantation, and 10 days for the nephrectomy with Mainz II pouch reconstruction. In all cases the recovery was uneventful.

Conclusions: Laparoscopy, though technically more de-

manding, is a feasible and safe option for ablative and complex reconstructive procedures in genitourinary tuberculosis. It offers the benefits of minimally invasive surgery. The difficulty with this procedure is mostly because of peripelvic and perinephric fibrosis, whereas the lower ureter and bladder are relatively easier to dissect.

Key Words: Genitourinary tuberculosis, laparoscopy, nephrectomy, ureteric reimplantation, MAINZ II

INTRODUCTION

Laparoscopy has been expanding in technical expertise, instrumentation, and surgical stature since its inception.¹ Most of the ablative and reconstructive surgeries in urology can be accomplished with advanced laparoscopy skills. The procedure is minimally invasive, with less morbidity, a more rapid postoperative recovery, and uncompromised surgical endpoints as substantiated by follow-up outcome data. Since the first clinical report in 1991, laparoscopic nephrectomy has been embraced by urologists worldwide. At many medical centers, including ours, laparoscopic nephrectomy has replaced open nephrectomy as the treatment of choice for many benign and malignant diseases with excellent results. Advanced renal or urinary tract tuberculosis (genitourinary tuberculosis [GUTB]) is known to cause multiple pathologies in the urinary tract, such as the ureteral strictures, hydronephrosis, small-capacity bladder because of associated tuberculous cystitis and nonfunctioning hydronephrotic kidneys with caseation, and calcification. Simple nephrectomy is recommended for the management of nonfunctioning or severely diseased tuberculous kidneys, which potentially harbor tuberculous bacilli.¹ However, when laparoscopic nephrectomy is attempted in such patients who have dense perinephric adhesions, there is a high conversion rate. Hence laparoscopic nephrectomy remained a relative contraindication for a very long time.²⁻⁴ Similarly, laparoscopic surgery for ureteral strictures is challenging because of the severe periureteral fibrosis caused by tuberculosis. Thus laparoscopic surgery in the management of urinary tract tuberculosis continues to be a technical

Department of Urology, JIPMER (Jawaharlal Institute of Postgraduate Medical Education and Research), Pondicherry, India (all authors).

Disclosure: no financial or personal disclosures.

Address correspondence to: L. N. Dorairajan, MCh Urology, Department of Urology, JIPMER, Pondicherry, India. Telephone: +91-413-2297332, E-mail: dorairajan_ln@hotmail.com

DOI: 10.4293/JSLS.2014.00203

© 2014 by JSLS, Journal of the Society of Laparoendoscopic Surgeons. Published by the Society of Laparoendoscopic Surgeons, Inc.

challenge.⁵ We analyzed our data for 7 patients who underwent laparoscopic procedures for various indications.

MATERIALS AND METHODS

The details of all 7 patients with GUTB who underwent laparoscopic surgical treatment for various indications between January 2011 and September 2012 were reviewed. We reviewed all the patients' data from the hospital records, and data pertaining to baseline characteristics, indication for surgery, type of surgery, operative duration, blood loss, intraoperative problems, postoperative outcome, and follow-up details were noted (**Table 1**). All patients received anti-tuberculosis treatment (ATT) before surgery. The standard regimen consisted of 4 drugs in the initial 2 months: isoniazid, 5 mg/kg orally once daily; rifampin, 10 mg/kg orally once daily; pyrazinamide, 25 mg/kg orally in 2 divided doses daily; and ethambutol, 15 mg/kg orally once daily. In the remaining 4 to 7 months, isoniazid and rifampin were administered daily in the same doses.

All laparoscopic procedures were performed by experienced faculty members. All laparoscopic procedures were carried out using a standard 3- or 4-port technique, with the primary port being inserted by the Hassan open technique; an additional port was required in only 1 case, in which laparoscopic-assisted Mainz pouch reconstruction was performed. The operative duration was taken as the time from the primary port insertion until the primary port closure. In all nephrectomies the specimen was extracted through a 6- to 7-cm incision in the lower abdomen (Pfannenstiel). Blood loss was measured as the amount present in the suction container minus the irrigation used. Recorded videos of the procedures were also reviewed for further assessment. Finally, postoperative recovery, wound infection, and the need for additional procedures, as well as the time to discharge from the hospital, were noted.

RESULTS

The mean age of the 7 patients was 43 years, and there were 4 men and 3 women. The symptoms were present for at least 6 months in all the patients before surgery. All patients received ATT for at least 6 months, with 2 patients receiving ATT for 9 months. Two patients received ATT because their urine tests were positive for acid-fast bacilli, and in 1 patient a bladder biopsy specimen was positive for acid-fast bacilli. The remaining 4 patients received ATT on the basis of radiologic findings being suggestive of

GUTB. Five patients had sterile pyuria, and the remaining 2 patients had contaminated specimens. The clinical details of all the cases are given in **Table 1**.

Laparoscopic Nephrectomy

Three patients had nonfunctioning kidneys with pyonephrosis with preplaced percutaneous nephrostomies (PCNs). All PCNs were placed in the department of urology on an inpatient basis at least 6 months before definitive surgery was undertaken. In 2 patients the primary indication for nephrectomy was nonfunctioning kidneys with recurrent episodes of pain not responding to medical management. The mean operative duration for the nephrectomies was 192 minutes (range, 180–210 minutes). There was no conversion to an open procedure. The mean amount of blood loss was 70 mL (range, 50–100 mL). Intraoperative difficulty in hilar dissection was encountered in 4 of 5 nephrectomies. Mass control of the hilar vessels by use of multiple Hem-o-lok clips (Weck Closure Systems, Research Triangle Park, NC, USA) was necessary in 1 patient. It was found that lower ureteric dissections were easier than peripelvic and hilar dissections when dense adhesions were present (**Figure 1**). All patients were managed with a 12-French suction drain, which was removed on the first or second postoperative day (POD); Per urethral catheters were removed on the first POD. The mean postoperative hospital stay was 3 days (range, 2–5 days). There was no wound dehiscence either from the port or from the lower Pfannenstiel incision used for specimen extraction.

Laparoscopic Ureteric Reimplantation With Psoas Hitch

One patient had a left lower ureteric stricture with well-preserved renal function. A PCN was inserted in the department of urology 6 months before treatment to preserve function. The patient received ATT for 6 months. He had biopsy (bladder)–proven GUTB. On the nephrostogram, there was a complete block at the lower ureteric level. The bladder capacity was 400 mL on the cystogram. The operative duration in this patient was 210 minutes, and the amount of blood loss was 100 mL. No difficulty was encountered in ureteral or bladder dissection or mobilization. The elasticity of the bladder was well maintained in this case, which helped in creation of the psoas hitch and the sub-detrusor tunnel (**Figure 2**). A 6-French, 26-cm double-pigtail stent was kept across the anastomosis to preserve the patency. A PCN was kept in situ to

Table 1.

Clinical Details of Cases and Procedures Performed

Case No.	Age (y)/Sex	Urine for AFB ^a	Sputum Culture	Clinical Presentation	Urine Culture	Blood Urea/ Serum Creatinine (mg/dL)	ATT Duration (mo)	Anatomic/Functional Studies	Procedure Performed
1	36/F ^a	Negative	Negative	Left pyonephrosis with preplaced PCN	Sterile pyuria	18/0.7	6	IVP ^a showed multiple infundibular stenosis; renal scan indicated PFK ^a	Left nephrectomy
2	47/F	Negative	Negative	Right pyonephrosis with preplaced PCN	Sterile pyuria	22/0.9	9	Nephrostogram showed right lower ureteric stricture with NFK ^a on DTPA scan	Right nephrectomy
3	45/F	Negative	Negative	Left loin pain for 5 mo	Contaminated	16/1.0	6	IVP showed non-visualized kidney with multiple calcifications	Left nephrectomy
4	41/M ^a	Positive	Negative	Left pyonephrosis with preplaced PCN	Sterile pyuria	19/0.7	6	Nephrostogram showed left lower ureteric stricture; PFK on DTPA scan	Left nephrectomy
5	41/M	Positive	Positive	Right loin pain	Sterile pyuria	25/1.1	9	Enlarged NFK	Right nephrectomy
6	46/M	Negative (biopsy proven)	Negative	Left PCN for hydronephrosis and loin pain	Sterile pyuria	16/0.7	6	Nephrostogram showed left ureteric dilation until lower end; bladder capacity, 400 mL; no vesicoureteral reflux	Left ureteric reimplantation
7	45/M	Negative	Negative	Bilateral hydronephrosis with urethral stricture disease	Contaminated	24/1.4; GFR ^a , 50 mL; left kidney, 6%	6	IVP showed right hydronephrosis and thimble bladder; urethrography showed pan-urethral stricture	Left nephrectomy with Mainz II pouch reconstruction

^aAFB = acid-fast bacilli; F = female; GFR = glomerular filtration rate; IVP = intravenous pyelogram; M = male; NFK = nonfunctioning kidney; PFK = poorly functioning kidney. DTPA = Tc 99m Diethylene triamine pentaacetic acid

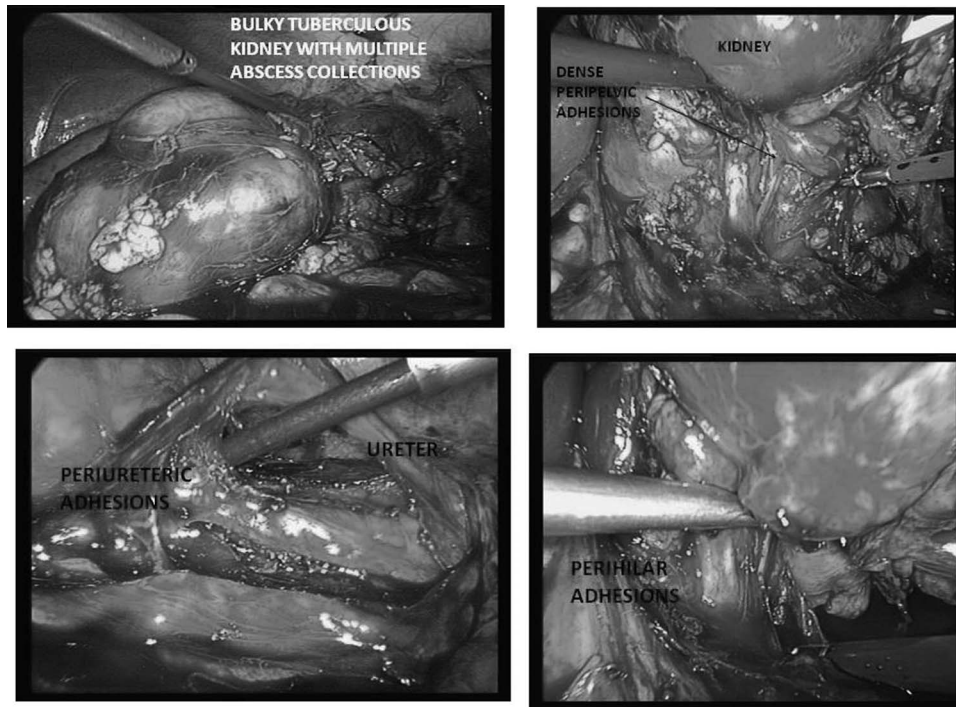


Figure 1. Intraoperative photographs of case 5 showing dense adhesions around kidney and perihilar area.

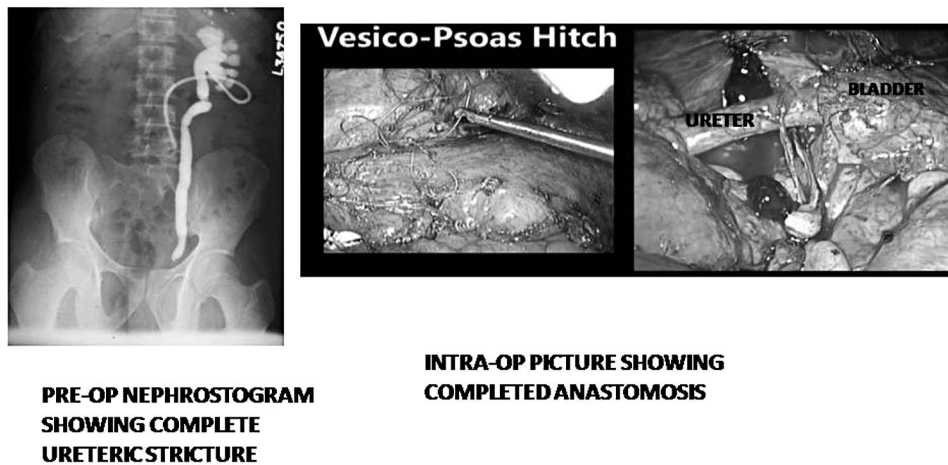


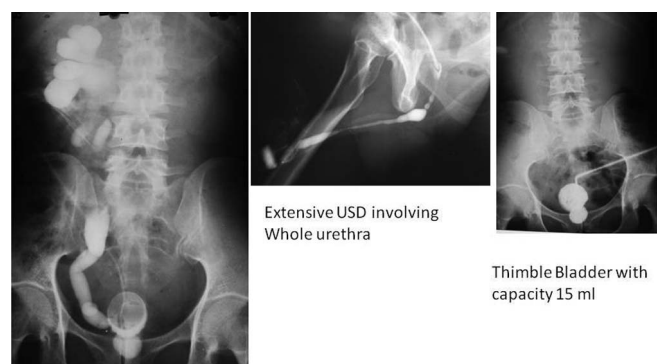
Figure 2. A, Preoperative nephrostogram showing complete stricture of distal ureter. B and C, Intraoperative pictures of completed anastomosis.

allow a postoperative contrast study to be performed; this also served as a precautionary measure for any urine leak. The postoperative recovery was uneventful. The patient was discharged on the fifth POD. The perurethral catheter and the drain were removed on the seventh POD and eighth POD, respectively, on an outpatient basis. There was no urinary leak after removal of the perurethral catheter.

Laparoscopic Nephrectomy With Laparoscopy-Assisted Mainz II Pouch Reconstruction

One patient had a left pyonephrotic kidney with a pre-placed right PCN for ureteric stricture in the department of urology. He had a thimble bladder with a capacity of 10 to 20 mL. He also had an extensive urethral stricture involving the entire anterior and posterior urethra with a fixed

and open bladder neck (**Figure 3**). He had normal renal function, and the glomerular filtration rate of the right kidney was 50 mL/min. He opted for an internal continent diversion. Laparoscopic nephrectomy and laparoscopic-assisted Mainz II pouch reconstruction were performed (**Figure 4**). The operative duration for the combined procedure was 480 minutes, with blood loss of 200 mL.



IVP Showing Rt Preserved function with Lower ureteric stricture with Lt NFK

Figure 3. Images of case 7. A, Intravenous pyelogram (IVP) showing well-preserved right (Rt) kidney with hydronephrosis. Lt = left; NFK = nonfunctioning kidney. B, Ascending urethrogram showing extensive anterior urethral stricture disease (USD). C, Cystogram showing small-capacity bladder.

Postoperatively, a rectal tube was used for 3 days. The ureteric splint was removed on the eighth POD, and oral alkali treatment was started on the third POD. The postoperative recovery was uneventful with a hospital stay of 10 days. The patient is being seen on regular follow-up visits and passes semisolid stools 5 to 6 times per day.

DISCUSSION

There are a number of problems in patients with GUTB that require surgical management, paramount among them are the presence of nonfunctioning moieties, caseation, calcification, complex fistula formation, and dense perirenal fibrotic reaction.¹ Many of these problems requiring surgical intervention can now be managed by present-day laparoscopic techniques, providing the well-known benefits of minimally invasive surgery to the patient. These problems lead to difficulty in dissection because of poor anatomic landmarks.³ As a result, there is more intraoperative blood loss, a higher incidence of conversion to open surgery,³ and a frustratingly longer operative duration, putting stress on the surgical team and the anesthetist because of difficult decision making and keeping a balance between the patient's safety and benefit. Nevertheless, our study shows that difficulty is often

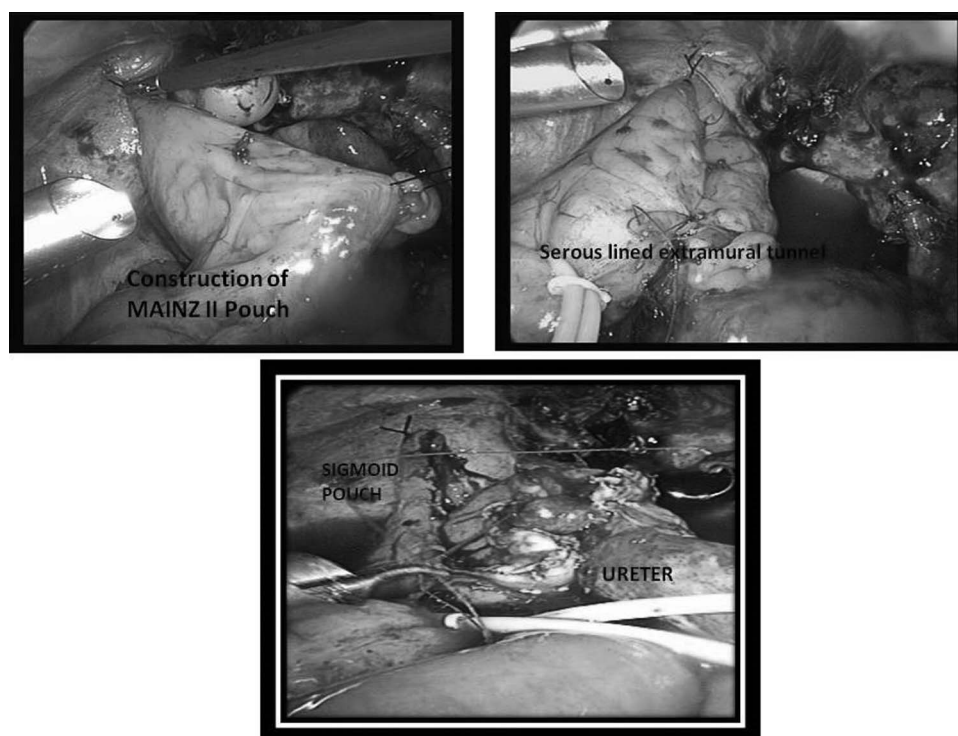


Figure 4. Steps in laparoscopic reconstruction of Mainz II pouch in case 7.

encountered during laparoscopic nephrectomy in the peripelvic and perihilar areas in which dense adhesions are usually found. Laparoscopic mobilization of the ureter in our experience, however, has been found to be easier, as is the dissection around the perivesical area, in which the adhesions were less often encountered and were less dense.

In addition, GUTB patients may also have problems as a result of the disease affecting the respiratory system that may decrease the lung capacity; therefore the laparoscopic surgery time has to be limited. Preoperative assessment of respiratory function is thus important, and chest physiotherapy along with cessation of smoking may improve the respiratory reserve. However, if the respiratory system is significantly affected, the risks associated with laparoscopic surgery are usually on the higher side. Although none of our patients had significant respiratory disease, our study shows that the operative times were within reasonable limits, and we believe that the minimally invasive technique helped in reducing the risk of pulmonary complications. None of our patients had a significant respiratory problem either intraoperatively or during the postoperative period.

There are other challenges in managing GUTB patients. These patients may have decreased renal function, which also restricts the reconstructive options available to the deciding physician. In patients with compromised renal function, use of the bowel for urinary tract reconstruction must be performed judiciously to avoid serious metabolic complications. In suitable selected cases, as shown in our study in the seventh case, minimally invasive surgery can be combined with open surgical techniques in innovative ways to perform complex urinary tract reconstruction efficaciously and efficiently to give the benefits of laparoscopic surgery to the patient without compromising outcome or safety.

GUTB was once considered a relative contraindication for laparoscopic surgery because of reported higher operative times, more blood loss, and a higher incidence of conversion to open surgery.² There was also a higher incidence of a portion of the kidney being left, leading to fistula formation. Our study, as well as other similar studies, indicate that with growing experience in laparoscopy, it is considered to have become the standard of care for these patients for all forms of reconstructive and ablative procedures. Laparoscopy is safe and effective in the hands of experienced surgeons. It should be considered, therefore, in the present day in every case of GUTB requiring surgical management in view of the good outcomes, less blood loss, and the reduced postoperative stay, as well as less morbidity.

References:

1. Chibber PL, Shah HN, Jain P. Laparoscopic nephroureterectomy for tuberculous nonfunctioning kidneys compared with laparoscopic nephroureterectomy for other diseases. *J Laparoendosc Adv Surg Tech*. 2005;15:308–312.
2. Gupta NP, Agrawal AK, Sood S. Tubercular pyelonephritic nonfunctioning kidney—another relative contraindication for laparoscopic nephrectomy: a case report. *J Laparoendosc Adv Surg Tech A*. 1997;7:131–134.
3. Kim HH, Lee KS, Park K, Ahn H. Laparoscopic nephrectomy for nonfunctioning tuberculous kidney. *J Endourol*. 2000;14:433–437.
4. Lee KS, Kim HH, Byun SS, Kwak C, Park K, Ahn H. Laparoscopic nephrectomy for tuberculous nonfunctioning kidney: comparison with laparoscopic simple nephrectomy for other diseases. *Urology*. 2002;60:411–414.
5. Hemal AK, Gupta NP, Rajeev K. Comparison of retroperitoneoscopic nephrectomy with open surgery for tuberculous nonfunctioning kidneys. *J Urol*. 2000;164:32–35.