



Axillary nerve injury associated with glenohumeral dislocation: a review and algorithm for management

Duncan Avis¹
Dominic Power²

- Axillary nerve injury is a well-recognized complication of glenohumeral dislocation. It is often a low-grade injury which progresses to full recovery without intervention. There is, however, a small number of patients who have received a higher-grade injury and are less likely to achieve a functional recovery without surgical exploration and reconstruction.
- Following a review of the literature and consideration of local practice in a regional peripheral nerve injury unit, an algorithm has been developed to help identification of those patients with more severe nerve injuries.
- Early identification of patients with high-grade injuries allows rapid referral to peripheral nerve injury centres, allowing specialist observation or intervention at an early stage in their injury, thus aiming to maximize potential for recovery.

Keywords: axillary nerve; peripheral nerve injury; glenohumeral dislocation

Cite this article: *EFORT Open Rev* 2018;3:70-77.
DOI:10.1302/2058-5241.3.170003.

Introduction

Glenohumeral dislocation is a common injury associated with both low- and high-energy trauma. There are age-related peaks of incidence in the young adult playing sports and in elderly patients sustaining falls. A dislocation is considered simple if not accompanied by any other lesion of bone, nerve, vessel or rotator cuff. It is considered complex if associated injury to any of these tissues is also encountered.

Nerve injuries are a well-recognized complication of glenohumeral dislocation with a wide-ranging frequency reported in the range of 15.8% to 48%.¹⁻³ The axillary nerve is the most commonly and often most severely injured,^{2,3} with isolated axillary nerve injury rates reported in the range of 3.3% to 40%.^{1,2} and an increasing predisposition in those aged over 60 years.⁴ While most axillary

nerve injuries associated with glenohumeral dislocation resolve without intervention,^{2,5-8} there remains a group of patients who have a higher-grade nerve injury, who will fail to progress to a satisfactory recovery with ongoing functional deficit.^{9,10}

The classifications of nerve injuries provided by Seddon and Sunderland define the pathophysiology and pathoanatomy of the injury, which aids understanding of injury severity and potential for recovery.¹¹ At the lower end of the spectrum of injury lies the neurapraxic injury. This represents a temporary block to conduction as a consequence of transient neural ischaemia, oedema and focal demyelination. These injuries will generally have an excellent prognosis with complete recovery by 12 weeks. If there is further injury, a low-grade injury may fail to heal should the insult continue, such as in ongoing ischaemia secondary to persistent dislocation, pressure from fracture fragments or extraneural scar tissue. A higher-grade injury is characterized by axonal disruption and subsequent Wallerian degeneration. Further along this spectrum, there will be progressive injury to the neural architecture which can allow categorization of such injuries as intermediate-grade axonopathy, or as high-grade injuries with axonopathy in the presence of severe neural connective tissue disruption or rupture. The intermediate grades retain some semblance of neural architecture and thus have more capacity to heal, generally within four months. The high-grade injuries have little or no capacity to recover without surgical intervention.

While these classifications provide a guide, the clinical reality represents nerves with mixed-depth lesions representing a spectrum between low and high grades. Those nerves with a greater proportion of low-grade injury can be expected to have a better outcome than those with predominantly high-grade injuries. The extrapolation of injury depth in mixed-depth lesions represents a diagnostic challenge.

In recent years, there has been a paradigm shift in the management of peripheral nerve injuries with the

increasing use of surgical neurolysis, nerve grafting and nerve transfers in the management of severe nerve injuries which will not otherwise recover. However, it is also well-recognized that delay in surgical intervention for peripheral nerve injuries is an independent variable for prediction of poor outcome, as a consequence of time-related decreased axonal regenerative capacity and increasing motor end plate degeneration and muscle degradation.¹²⁻¹⁴

The diagnostic and management challenges are to identify those patients with high-grade axillary nerve injuries that have no recovery potential and to intervene early. Equally important is the recognition of non-recovering lesions, which can be referred to specialist centres for intervention.

Anatomy of the axillary nerve

The axillary nerve arises from fascicles in the posterior division of the fifth cervical spinal nerve root. These combine with the posterior divisions of the C6-T1 roots to form the posterior cord. The axillary nerve arises as a branch from the posterior cord distal to the subscapular and thoracodorsal nerves, and just before the formation of the branches to triceps. It passes with the posterior circumflex humeral vessels through the quadrilateral space from the anterior to posterior aspect of the shoulder. In the quadrilateral space, it is intimately related to the inferior shoulder joint capsule and to the surgical neck of the humerus. There are two terminal branches. The anterior branch passes deep to deltoid around the humeral neck. This branch innervates the anterior and medial portions of the deltoid and almost always contributes to innervation of the posterior portion as well.¹⁵ It has no cutaneous sensory branch. The posterior branch has a branch innervating the posterior deltoid and teres minor. The posterior branch also gives rise to the superior lateral brachial cutaneous nerve, innervating the skin of the proximal lateral arm.

Whilst all nerves of the brachial plexus are at risk of injury during glenohumeral dislocation, the most commonly injured is the axillary nerve.^{2,3,7,16,17} The axillary nerve in particular is predisposed to injury due to its constrained anatomical relationship with the humeral neck and quadrilateral space and distal soft tissue attachments via multiple branches. Traction injury occurs with humeral head dislocation and shaft displacement with further potential for compressive nerve injury. This anatomical relationship may further threaten the nerve during subsequent reduction manoeuvres, causing nerve injury.¹⁸ The site of injury to the axillary nerve may occur in the quadrilateral space, but frequently there is either a continuity lesion or avulsion from the posterior cord distal to the thoracodorsal origin.^{19,20}

Table 1. Variables associated with high-grade axillary nerve injury following glenohumeral dislocation

Associated fracture - proximal humerus or scapula
Vascular injury
Delay in reduction >2 hours
Neurological deficit in axillary nerve and other plexus palsies
Neuropathic pain associated with axillary nerve

Prediction and detection of axillary nerve injury

There are certain factors which are associated with a higher incidence of nerve injury for glenohumeral dislocation. Key points in the assessment of axillary nerve injury in association with shoulder dislocation include the patient's age and mechanism of injury, time to reduction and the method of reduction, associated musculoskeletal injuries and any abnormality in the remainder of the brachial plexus (Table 1).

Patient age

Risk of nerve injury increases with age, with each additional decade representing 1.3 times increased odds of associated nerve injury. In those aged over 40 years sustaining a glenohumeral fracture-dislocation, there has been a series documenting a 65% incidence of nerve injury with EMG diagnosis suggesting deltoid denervation.²² Of these, only 23% had a 'mild' denervation, with the remainder having 'moderate', 'pronounced' or 'total' denervation – the important point being that 42% of these remained symptomatic at 38-month follow-up.

Associated injuries

Fractures occur in 18% of glenohumeral dislocations³ and the presence of a fracture doubles the risk of nerve injury.² Of nerve injury cases, 64% will have a fracture.²¹ Blunt trauma to the shoulder with associated axillary nerve injury is an independent predictor of poor neurological recovery, even in the absence of glenohumeral dislocation. In the simple dislocation, the rate of neurotmesis of the axillary nerve is low (1%) but significantly increases in the presence of blunt trauma without dislocation.⁷

Vascular injuries are frequently associated with nerve injury.² Arterial injury can, surprisingly, go undetected due to the excellent collateral circulation of the arm, but absence of peripheral pulses or the need for Doppler to detect them is very strongly associated with axillary artery occlusion or disruption.¹⁶ The presence of a large haematoma may be indicative of an underlying arterial injury.¹⁷

Of isolated axillary injuries from dislocation, 41% will have concurrent rotator cuff tears.²⁷ Rotator cuff injury or associated fracture may hamper examination as a consequence of impaired range of movement and pain

associated with these injuries. It is very unlikely that deltoid paralysis in isolation will render abduction of the arm impossible.⁷ In this scenario, either a more significant nerve injury may be the reason (for example, associated supra-scapular nerve injury) or a significant rotator cuff tear. Equally important is the continued suspicion of an associated rotator cuff tear in the presence of a recognized nerve injury, the finding of the latter detracting from investigation of the former.⁷

With more extensive plexus injuries, the incidence of cuff tears decreases but the incidence of scapular fracture significantly increases – a likely proxy marker of increased injury energy and severity.²⁷

Reduction

There is a higher rate of axillary nerve injury with shoulder dislocations not reduced within 12 hours;²² with some evidence to suggest those that are reduced more than 2 hours following injury, with an associated nerve lesion, are less likely to recover within six months than those with nerve injuries that are reduced promptly.²³

There is no one technique of reduction manoeuvre which is demonstrated to be superior to others;²⁴ neither does there appear to be any evidence suggesting contraindication of closed reduction in the presence of nerve injury. It is apparent, however, that nerve injury can be caused or exacerbated by the reduction manoeuvre; hence, this needs to be performed in an atraumatic manner. Although rare, a locked dislocation with block to reduction being caused by the noose-like effect of the terminal branches of the brachial plexus has been reported.⁴ This would obviously be an indication for open reduction.

Associated neural injuries

Most axillary nerve injuries are low-grade lesions which will recover rapidly and often completely. The detection of associated injuries to the median or ulnar nerve suggests an infraclavicular brachial plexus injury which has a poorer prognosis.^{7,22} The detection of associated nerve deficits should prompt early referral to a specialist centre for further evaluation. Associated nerve injuries need to be identified and documented at the time of initial examination and after any intervention.²⁵ Failure to do so not only makes recognition of injury and duration difficult but also exposes the treating doctor to litigation.

Neuropathic pain is associated with intermediate- and high-grade injuries but can also highlight deterioration in low-grade injuries due to pressure from a haematoma or perineural scar formation. Neuropathic pain from the axillary nerve is often reported as a burning or deep aching sensation in the upper lateral cutaneous nerve of arm territory. In a series of brachial plexus palsies associated with arterial injury, nerve-related pain was demonstrated in 20% of all cases either representing neurostenalgia, or

less commonly causalgia, as a consequence of nerve traction and ischaemia.¹⁷ In all cases, this resolved in this acutely explored cohort.

Preservation of sensation in the regimental patch area of the upper arm, supplied by the cutaneous branch of the axillary nerve, cannot rule out motor palsy due to the trifurcated nature of the axillary nerve at the level of the humeral neck. This may be preserved between 15% and 50% of the time, even in multiple nerve injuries.^{2,16,23}

The best indicator of axillary motor impairment is deltoid paresis at one week post-injury.² In one series, all axillary nerve injuries were diagnosed clinically by deltoid paresis, with 100% concurrence with neurophysiological findings.¹⁶ Even in the presence of post-injury discomfort, with or without associated injuries, palpation of the deltoid anterior, middle or posterior fibres will be sufficient to detect the presence or absence of voluntary muscle contraction.

Several clinical examination techniques have been described to identify the presence and degree of axillary nerve motor palsy with deltoid weakness or paralysis. The ‘Extension lag’ test²⁴ and the ‘Swallowtail sign’²⁵ have been more recently advanced by Bertelli, who has proposed testing shoulder abduction in internal rotation, thus aiming to test the deltoid in isolation, with no compensation from the periscapular musculature.²⁶ This test has been correlated with both intraoperative observational and neurophysiological findings confirming deltoid paralysis, and the two aforementioned tests, both of which demonstrated false-positive results. In the acute setting, such tests may be impossible as a consequence of patient discomfort. They should not be performed in injuries with associated fractures, thus avoiding displacement.

Electrophysiological analysis

The incidence of nerve injuries is often much higher if the diagnosis is made by neurophysiology rather than by clinical findings alone, illustrating an underlying nerve injury with apparent lack of clinical dysfunction.^{2,27} This raises the question, however, of the relevance of electrophysiological injury without clinical deficit.

Once an axillary nerve injury has been detected, the differential needs to be made between neural demyelination, axonal disruption and neural discontinuity (whether physical or electrophysiological), thus differentiating between the low-, intermediate- and high-grade injuries. Electromyography (EMG) and Nerve Conduction Studies (NCS) are capable of this, even in the early weeks following an injury. At less than two weeks post-injury, compound muscle action potential (CMAP) may demonstrate decreased amplitude consistent with axonal injury and resultant Wallerian degeneration. Similarly, decreased or absent motor unit (MU) recruitment may help to differentiate between a conduction block or axonal disruption, i.e.

grade 1 or 2 Sunderland injury compared with higher grades associated with more significant axonotmetic or neurotmetic features.^{2,14,16,28} A low-grade injury will be represented by the presence of decreased but normal motor units, compared with absence of MU recruitment in the higher-grade injuries. Early axonal loss will also be represented by the appearance of fibrillation potentials and positive sharp waves.

Electrophysiological markers of poor outcome are suggested to be CMAP < 10% of the contralateral side, absent motor units on needle EMG and a significant reduction in motor unit action potential (MUAP).^{7,29} After several weeks have passed, differentiation is by the development of fibrillation and presence of Sharp waves in axonal injuries in contrast to their absence in lower-grade, demyelinating injury. This difference again would be aided by the decrease in the conduction amplitude and conduction velocity on NCS, further helping differentiation from axonal interruption. Despite this, neurophysiology cannot differentiate between a severe lesion in continuity, i.e. the higher-grade axonotmetic injuries and a neurotmesis. Similarly, differentiation between those injuries which may undergo reinnervation and those which do not can only be determined with serial testing, i.e. demonstrating any evidence of reinnervation. Absence of evidence of reinnervation or delay in reinnervation may be the hallmark of a higher-grade lesion, thus warranting surgical exploration.

Prognosis for recovery

Most axillary nerve injuries associated with shoulder dislocation will improve and demonstrate a good functional recovery. Neurapraxia should demonstrate full recovery by three months and low-grade axonal injuries can expect to be reinnervating by three months with established recovery by six to seven months.^{7,22,30} These injuries should progress to full functional recovery. Deep muscle tenderness will often precede any electrophysiological evidence of muscle reinnervation, but its presence has a very high sensitivity and positive predictive value of early muscle reinnervation which will recover to at least grade M3 (MRC scale).³⁶

A Tinel's test may be elicited associated with axillary nerve injuries. This can be performed on either the anterior or posterior aspects of the quadrilateral space. A non-progressive anterior Tinel's test is more likely representative of a high-grade injury compared with a progressive Tinel's elicited in the posterior quadrangular space, which is likely to represent neural regeneration.

Recovery can be subsequently monitored by serial NCS and EMG studies, noting the reappearance of motor unit potentials. Over time and with progressive recovery, the amplitude of these and CMAP will be expected to increase.

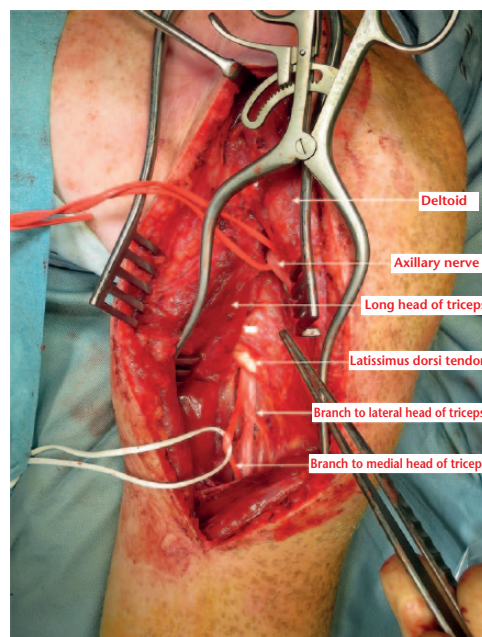


Fig. 1 Clinical photograph demonstrating the anatomical relationships of the axillary nerve and branches of the radial nerve to the triceps.

Injuries which are not recovering, or only partially recovering, by three months and show poor recovery of muscle strength need to be monitored. These represent intermediate-grade injuries which may not progress adequately. These lesions may benefit from early exploration and neurolysis. If, on examination at nine months, there is still poor recovery (MRC grade 3 or lower), then recovery is unlikely and nerve transfer may then be a good option.

High-grade injuries and ruptures need early identification, early surgical exploration and consideration of grafting; this allows normal anatomical restitution and can always be followed by a salvage nerve transfer should this fail. Nerve transfer is a good option for late referrals of a high-grade injury (more than four months post-injury), those with no graftable option or those injuries which have failed to progress to functional recovery by nine months.

Surgical options

For those injuries that do not recover (i.e. ongoing deltoid paralysis), surgical exploration is mandatory. Upon exploration, the injured nerve can be identified and neurolysis performed, dissecting the nerve from surrounding scar tissue. Occasionally interfascicular neurolysis will be required. Neurolysis removes potential constrictive tissue which in isolation can improve conduction in non-recovering lower-grade injuries. For those high-grade injuries unlikely to recover, the options are either nerve grafting or nerve transfer surgery.

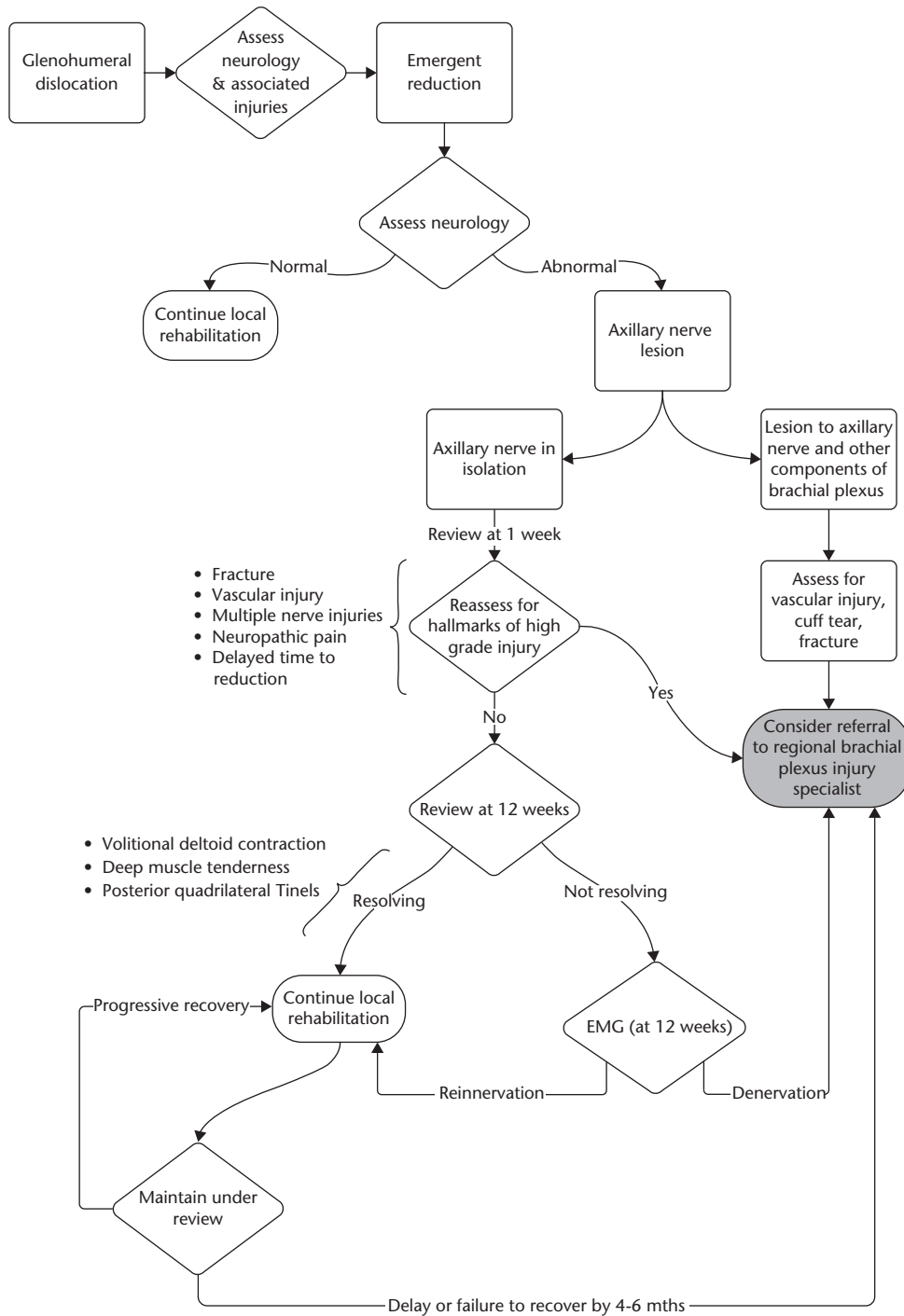


Fig. 2 An algorithm for the detection of higher-grade axillary nerve injuries.

Grafting with suitable donor nerves, for example the sural, aims for restitution of neural continuity following resection of the non-viable segment. The nerve distal to the injury has to have capacity to regenerate following grafting. Nerve transfers aim to reinnervate the nerve distal to the lesion directly from a donor nerve which remains in continuity proximally. For the axillary nerve, options

have been described with good results using medial and lateral triceps branches of the radial nerve (Fig. 1) and the thoracodorsal nerve.^{31,32}

Exploration of the axillary nerve will allow direct assessment of lesions to the nerve and neural continuity. Intraoperative stimulation of the axillary nerve will demonstrate those lesions in continuity and is an accurate

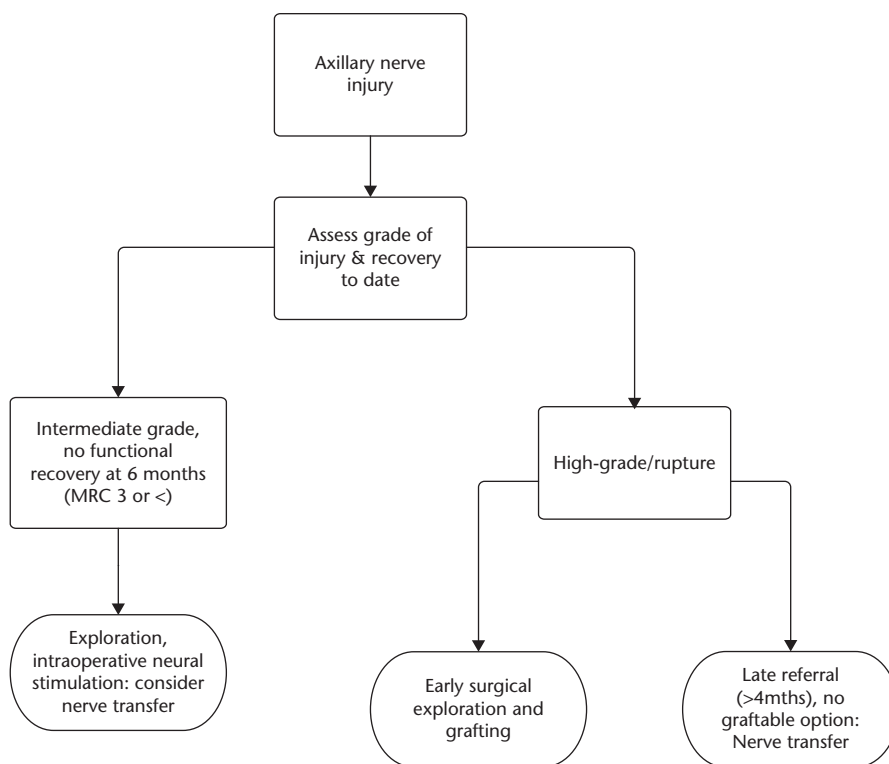


Fig. 3 Options for management of nerve injury at peripheral nerve injury centre.

assessment of the injury to the architecture of the nerve and degree of neurophysiological disruption. Those lesions which are in continuity and can demonstrate deltoid contraction on neural electrical stimulation will predictably do well and recover with either no further surgical input or neurolysis alone.^{7,19} Those lesions which demonstrate no capacity for conduction require further thought. If exploration is being performed within a timeframe when further recovery may be possible, then a further period of observation could be allowed following neurolysis. This runs the risk, however, of the development of a neuroma in continuity which may need excision and grafting at a later date. If the exploration and neurolysis is being performed after a reasonable window for recovery has already passed, then excision and grafting could be performed at that stage. Similarly, should the exploration be performed late, with no evidence of neuroma in continuity (thus assuming no attempt at regeneration as a proxy marker of a non-viable nerve distally), then nerve transfer could be performed, assuming the nerve distal to the injury is, to all intents, dead.

Predictors of surgical outcome

Irrespective of the procedure, better results will be achieved with earlier intervention. There is a trend towards better outcomes with intervention at less than 4–6 months

following injury,^{20,23,33} with more substantial evidence suggesting significantly poorer results after 9–12 months.^{9,34}

There are several factors which will determine the success of grafting or transfer surgery, unfortunately not all under the control of the surgeon:

- Increasing patient age results in worse outcomes. Results of grafting and nerve transfer deteriorate after the age of 30 years, with potential for no recovery after the age of 50 years.^{9,34}
- Increasing patient body mass index (BMI) is associated with a worse result.⁹
- The patient with multiple nerve injuries or associated rotator cuff tears will do less well than those with isolated axillary nerve injuries, whatever the intervention.^{19,20,34}
- Perhaps unsurprisingly, those patients who can be managed with neurolysis alone have a better outcome than those who undergo graft or transfer, though this reflects the severity of the injury rather than choice of surgical modality.³⁵
- Graft length has an unclear bearing on outcome. While some studies have historically suggested there is a worse outcome with respect to abduction with grafts > 6 cm^{36,37} and others have shown trends to support this,³⁸ others have demonstrated good results with longer grafts, with results being comparable with both shorter grafts and nerve transfer.^{20,34,39}

Conclusions

Nerve injuries associated with glenohumeral dislocation need first to be recognized and subsequently understood. This allows categorization of the injury and formulation of a plan of management. The algorithm proposed (Fig. 2) aims to guide this process with the hope of capture of those patients with significant injuries who can be directed to specialist peripheral nerve injury centres for further assessment and treatment (Fig. 3).

We appreciate that a wide spectrum of injuries will be encountered and suggest the algorithm as an aid to management. It is not, for example, expected that all axillary nerve injuries associated with a tuberosity fracture are referred to a specialist centre. Similarly, those patients with associated risks for, or who have evidence of, a potentially higher-grade injury may be those that warrant closer follow-up and repeat assessment rather than immediate referral.

We aim for the clinician to use the algorithm as an aid to identifying injuries that have a higher chance of associated significant nerve injury, which may warrant close observational follow-up or referral to a specialist centre in an appropriate timescale.

AUTHOR INFORMATION

¹Basingstoke & North Hampshire Hospital, UK.

²Queen Elizabeth Hospital, UK.

Correspondence should be sent to: D. Avis, Basingstoke & North Hampshire Hospital, Aldermaston Rd, Basingstoke RG24 9NA, UK.
Email: duncanavis@hotmail.com

ICMJE CONFLICT OF INTEREST STATEMENT

None declared.

FUNDING STATEMENT

No benefits in any form have been received or will be received from a commercial party related directly or indirectly to the subject of this article.

LICENCE

© 2018 The author(s)

This article is distributed under the terms of the Creative Commons Attribution-Non Commercial 4.0 International (CC BY-NC 4.0) licence (<https://creativecommons.org/licenses/by-nc/4.0/>) which permits non-commercial use, reproduction and distribution of the work without further permission provided the original work is attributed.

REFERENCES

- Atef A, El-Tantawy A, Gad H, Hefeda M.** Prevalence of associated injuries after anterior shoulder dislocation: a prospective study. *Int Orthop* 2016;40:519–24.
- Visser CP, Coene LN, Brand R, Tavy DL.** The incidence of nerve injury in anterior dislocation of the shoulder and its influence on functional recovery. A prospective clinical and EMG study. *J Bone Joint Surg [Br]* 1999;81:679–85.
- Te Slaa RL, Wijffels MP, Brand R, Marti RK.** The prognosis following acute primary glenohumeral dislocation. *J Bone Joint Surg [Br]* 2004;86:58–64.
- Gumina S, Postacchini F.** Anterior dislocation of the shoulder in elderly patients. *J Bone Joint Surg [Br]* 1997;79:540–3.
- Blom S, Dahlbäck LO.** Nerve injuries in dislocations of the shoulder joint and fractures of the neck of the humerus. A clinical and electromyographical study. *Acta Chir Scand* 1970;136:461–6.
- Berry H, Bril V.** Axillary nerve palsy following blunt trauma to the shoulder region: a clinical and electrophysiological review. *J Neurol Neurosurg Psychiatry* 1982;45:1027–32.
- Hems TE, Mahmood F.** Injuries of the terminal branches of the infraclavicular brachial plexus: patterns of injury, management and outcome. *J Bone Joint Surg [Br]* 2012;94:799–804.
- Sunderland S.** *Nerves and nerve injuries.* Edinburgh, London: E. and S. Livingstone, 1968.
- Lee JY, Kircher MF, Spinner RJ, Bishop AT, Shin AY.** Factors affecting outcome of triceps motor branch transfer for isolated axillary nerve injury. *J Hand Surg [Am]* 2012;37:2350–6.
- Leffert RD, Seddon H.** Infraclavicular brachial plexus injuries. *J Bone Joint Surg [Br]* 1965;47:9–22.
- Sunderland S.** A classification of peripheral nerve injuries producing loss of function. *Brain* 1951;74:491–516.
- Fu SY, Gordon T.** Contributing factors to poor functional recovery after delayed nerve repair: prolonged denervation. *J Neurosci* 1995;15:3886–95.
- Fu SY, Gordon T.** Contributing factors to poor functional recovery after delayed nerve repair: prolonged axotomy. *J Neurosci* 1995;15:3876–85.
- Korus L, Ross DC, Doherty CD, Miller TA.** Nerve transfers and neurotization in peripheral nerve injury, from surgery to rehabilitation. *J Neurol Neurosurg Psychiatry* 2016;87:188–97.
- Leechavengvongs S, Teerawutthichait T, Witoonchart K, et al.** Surgical anatomy of the axillary nerve branches to the deltoid muscle. *Clin Anat* 2015;28:118–22.
- Burge P, Rushworth G, Watson N.** Patterns of injury to the terminal branches of the brachial plexus. The place for early exploration. *J Bone Joint Surg [Br]* 1985;67:630–4.
- Stenning M, Drew S, Birch R.** Low-energy arterial injury at the shoulder with progressive or delayed nerve palsy. *J Bone Joint Surg [Br]* 2005;87:1102–6.
- Milton GW.** The mechanism of circumflex and other nerve injuries in dislocation of the shoulder and the possible mechanism of nerve injuries during reduction of dislocation. *Aust N Z J Surg* 1953;23:25–30.
- Kline DG, Kim DH.** Axillary nerve repair in 99 patients with 101 stretch injuries. *J Neurosurg* 2003;99:630–6.
- Mikami Y, Nagano A, Ochiai N, Yamamoto S.** Results of nerve grafting for injuries of the axillary and suprascapular nerves. *J Bone Joint Surg [Br]* 1997;79:527–31.
- Lam WL, Fufa D, Chang NJ, Chuang DC.** Management of infraclavicular (Chuang Level IV) brachial plexus injuries: A single surgeon experience with 75 cases. *J Hand Surg Eur Vol* 2015;40:573–82.
- Kosiyatrakul A, Jitprapaikularn S, Durand S, Oberlin C.** Recovery of brachial plexus injury after shoulder dislocation. *Injury* 2009;40:1327–9.
- Wehbe J, Maalouf G, Habanbo J, et al.** Surgical treatment of traumatic lesions of the axillary nerve. A retrospective study of 33 cases. *Acta Orthop Belg* 2004;70:11–18.

- 24. Hertel R, Lambert SM, Ballmer FT.** The deltoid extension lag sign for diagnosis and grading of axillary nerve palsy. *J Shoulder Elbow Surg* 1998;7:97-9.
- 25. Nishijima N, Yamamuro T, Fujio K, Ohba M.** The swallow-tail sign: a test of deltoid function. *J Bone Joint Surg [Br]* 1995;77:152-3.
- 26. Bertelli JA, Ghizoni MF.** Abduction in internal rotation: a test for the diagnosis of axillary nerve palsy. *J Hand Surg [Am]* 2011;36:2017-23.
- 27. Perlmutter GS.** Axillary nerve injury. *Clin Orthop Relat Res* 1999;(368):28-36.
- 28. Simon NG, Spinner RJ, Kline DG, Kliot M.** Advances in the neurological and neurosurgical management of peripheral nerve trauma. *J Neurol Neurosurg Psychiatry* 2016;87:198-208.
- 29. Malikowski T, Micklesen PJ, Robinson LR.** Prognostic values of electrodiagnostic studies in traumatic radial neuropathy. *Muscle Nerve* 2007;36:364-7.
- 30. Lee S, Saetia K, Saha S, Kline DG, Kim DH.** Axillary nerve injury associated with sports. *Neurosurg Focus* 2011;31:E10.
- 31. Leechavengvongs S, Witoonchart K, Uerpaiojkit C, Thuvasethakul P.** Nerve transfer to deltoid muscle using the nerve to the long head of the triceps, part II: a report of 7 cases. *J Hand Surg [Am]* 2003;28:633-8.
- 32. Samardzic MM, Grujicic DM, Rasulic LG, Milicic BR.** The use of thoracodorsal nerve transfer in restoration of irreparable C5 and C6 spinal nerve lesions. *Br J Plast Surg* 2005;58:541-6.
- 33. Terzis JK, Kokkalis ZT.** Shoulder function following primary axillary nerve reconstruction in obstetrical brachial plexus patients. *Plast Reconstr Surg* 2008;122:1457-69.
- 34. Degeorges R, Lebellec Y, Alnot JY.** Facteurs pronostiques de la chirurgie du nerf axillaire. *Rev Chir Orthop Reparatrice Appar Mot* 2004;90:103-10.
- 35. Domínguez-Páez M, Socolovsky M, Di Masi G, Arráez-Sánchez MÁ.** [Isolated traumatic injuries of the axillary nerve. Radial nerve transfer in four cases and literatura review]. *Neurocirugía (Astur)* 2012;23:226-33.
- 36. Terzis JK, Kostas I, Soucacos PN.** Restoration of shoulder function with nerve transfers in traumatic brachial plexus palsy patients. *Microsurgery* 2006;26:316-24.
- 37. Terzis JK, Barbisioti A.** Primary restoration of elbow flexion in adult post-traumatic plexopathy patients. *J Plast Reconstr Aesthet Surg* 2012;65:72-84.
- 38. Okazaki M, Al-Shawi A, Gschwind CR, Warwick DJ, Tonkin MA.** Outcome of axillary nerve injuries treated with nerve grafts. *J Hand Surg Eur Vol* 2011;36:535-40.
- 39. Wolfe SW, Johnsen PH, Lee SK, Feinberg JH.** Long-nerve grafts and nerve transfers demonstrate comparable outcomes for axillary nerve injuries. *J Hand Surg Am* 2014;39:1351-7.