

Fetal Kidneys Ultrasound Appearance in the First Trimester - Clinical Significance and Limits of Counseling

ȘTEFANIA TUDORACHE¹, MONICA CARA², D.G. ILIESCU¹, A. STOICA³,
CRISTIANA SIMIONESCU⁴, LILIANA VICTORIA NOVAC⁵, DANIELA CERNEA⁶

¹University of Medicine and Pharmacy of Craiova, Obstetrics and Gynecology, Prenatal Diagnostic Unit, University Emergency Hospital, Craiova, Romania

²University of Medicine and Pharmacy of Craiova, Public Health Department, Craiova, Romania

³University of Medicine and Pharmacy of Craiova, Pediatric Surgery, Craiova, Romania

⁴University of Medicine and Pharmacy of Craiova, Pathology Department, Craiova, Romania

⁵University of Medicine and Pharmacy of Craiova, Obstetrics and Gynecology, Craiova, Romania

⁶University of Medicine and Pharmacy of Craiova, Anaesthesiology and Intensive Care Department, Craiova, Romania

ABSTRACT: Objective. The objective of this study was to determine the visualizing rate of fetal kidneys at various gestational ages in late first trimester (FT) and to establish the clinical significance of their two-dimensional ultrasound (2DUS) appearance in the FT. Methods. In a prospective cross-sectional study, 1456 women from an unselected population underwent a detailed assessment of fetal anatomy at 11+0 -13+4 weeks of gestation with the use of transabdominal sonography. Information on the ultrasound findings, antenatal course and perinatal outcome was obtained in 1331 cases. Results. 44 cases in which a congenital kidney disease was detected by ultrasound in the prenatal period were identified. The renal pathology was suspected in the FT in 8 cases, and confirmed by a standard test (postmortem autopsy or second-trimester scan) in 4 cases. The standard detailed second-trimester scan at 18-22 weeks diagnosed another 23 cases but refuted suspicion in 4 FT positive cases. The third trimester added another 17, all confirmed by the postpartum scan. For FT presence or absence of congenital renal anomalies, sensitivity, specificity, +LRs and -LRs of 2DUS were 9.09%, 99.69%, 29.25, and 0.91. Conclusion. FT prenatal kidneys' visualization is critically dependent on the gestational age. FT diagnosis holds uncertainty. An early diagnosis carries a risk of providing a false-positive or a false-negative result, because the differentiation of the renal system is delayed or the diagnosis is not amenable yet to prenatal ultrasound. No FT findings can exclude the mid-trimester follow-up ultrasound scan. Second and third trimester scan are relevant for congenital kidney diseases.

KEYWORDS: first trimester ultrasound, first trimester anomaly scan, fetal kidneys, multicystic dysplastic kidney, polycystic kidney disease, prenatal counseling

Introduction

Due to recent improvements in ultrasound (US) technology the fetal anomaly screening in the late first trimester (FT) became a reality. Recent years have forced the diagnostic of all major cardiac and extracardiac anomalies towards the first trimester and today there is proof that most of them are accessible under 14 weeks[1,2].

Recent guidelines for scanning in the first trimester recommend fetal kidneys recognition [3]. Yet, like in many other systems, the prevalence of the congenital kidneys anomaly varies depending on the time of observation: fetal life less than 14 weeks, less than 24 weeks, more than 24 weeks, neonatal, infancy, or childhood [4]. Unlike other systems (e.g. the fetal heart, which is characterized by complex development process in early gestation, being fully developed at the end of 8th week [5]), the

fetal kidneys are evolving through the second and the third trimester, the most active phase of nephrogenesis being present between 26 and 34 weeks of amenorrhea (this process being complete after 34 weeks).

We performed a prospective study in order to determine the visualizing rate of fetal kidneys in the late FT (11, 12 and 13 weeks of amenorrhea), to characterize their FT US appearance and to establish if these features are related with the second and third trimester aspects and with the neonatal outcome.

Material and methods

This is a single center study performed between January 2011 and April 2014, in cases attending our Prenatal Diagnostic Unit (PDU), County Emergency University Hospital Craiova, Romania, for FT screening for aneuploidies (by nuchal translucency-NT and maternal serum

biochemistry). Inclusion criteria were: singleton pregnancies, with a fetal crown-rump length (CRL) of 44-74 mm, detailed anomaly FT genetic scan in PDU (using an extended examination protocol [2], ST and TT available, known pregnancy outcome. In continuing pregnancies we included only cases in which the second trimester screening scan was performed in our unit or the cases that finalized with birth in our hospital, making the postnatal clinical exam at discharge available. We recruited pregnancies consecutively, following the referral by primary or secondary centers or after self-referral. The exclusion criterion was the loss to follow-up.

US examinations were performed using an E8 (GE Medical Systems, Zipf, Austria) machine, equipped with 4-8-MHz curvilinear transducer. All scans were performed using speckle reduction imaging (SRI) and CrossXBeam CRI.

The scans were performed on a daily schedule basis, in the Prenatal Diagnostic Unit, by any of its members. They include two obstetrician sonographers and five trainees. The trainees have had, at the beginning of the study, various levels of skills, varying between 2 years and 4 years of experience in prenatal diagnostic US. They all had previously attended a 14 days training course on FT fetal scanning. The first line sonographer (the trainee or the senior obstetrician, upon the case) was informed upon the patient's history and personal data.

In the study it was recommended to store, for each case, at least: a transversal image of the fetal pelvis or at least two longitudinal parasagittal section of the fetus, with the spine in an anterior position, for attempting to visualize both kidneys. The ST fetal scans were performed by all unit members. Newborns data were retrieved from the clinical hard copies files of all cases, from the Neonatology Department. The neonatal clinic exams were performed by the attending neonatologist, also the ultrasound exam if indicated. The neonatal team already has a protocol for the timing and content of the postnatal examination and this study did not alter the clinical practice [6]. The clinical assessment is usually performed before discharge from hospital by a senior doctor, but may also be performed by a resident doctor.

Although the population was unselected, we do not consider our participants a low risk population, but a medium risk, as being a tertiary center, we examine referrals from primary or secondary centers (approximate 20%

of the study group). All participants were offered the FT unit anomaly protocol and the ST anomaly scan. We obtained approval from our institutional ethics committee (Ethical Committee of the University of Medicine and Pharmacy of Craiova) for the study. All women had provided verbal informed consent for the use of US images for research purposes.

In the PDU we offer invasive maneuvers (chorionic villus sampling and amniocentesis) on daily routine.

Throughout the study period, in cases with severe anomalies we advocated for medical TOP, regardless the gestational age (GA), as fetal conventional autopsy is still the gold standard in diagnosis of fetal abnormalities [7]. If medical TOP performed, a specimen autopsy was attempted. Autopsies were performed by trained perinatal pathologists and followed accepted protocols [8]. Direct communication with the pathologist was present. Information for the pathologist was provided and included the obstetrical and medical history, the invasive testing results, the US features, and the family history. We considered the standard pathology test obtained if autopsy photographic files were available. The autopsy photographic files were obtained using a Sony DSLR A200 camera (10.2 megapixels), and a Leica IC80HD digital microscope camera (3 megapixels). Sensitive instruments and strong illumination were used.

Statistical analysis - study design allowed us to construct a 2x2 table of true positive, false positive (FP), false negative (FN) and true negative values, in order to calculate sensitivity and specificity with 95% confidence intervals (CI). We calculated estimates of sensitivity and specificity with 95% confidence intervals (CI) by comparing antenatal findings with subsequent verification of diagnosis either by mid-trimester, third trimester scan, postnatal clinical and US examination or postmortem. We choose to report also positive and negative likelihood ratios (+LR and -LR). Statistical analyses were performed using the statistical software IBM SPSS Statistic 19.

Results

The flow diagram is presented in Fig.1 [9]. 1456 fetuses were examined during the study period. Follow-up was complete in 1331 cases. 44 cases in which a congenital kidney disease was detected by ultrasound in the prenatal period were identified. The lost to follow-up rate was 8.17%.

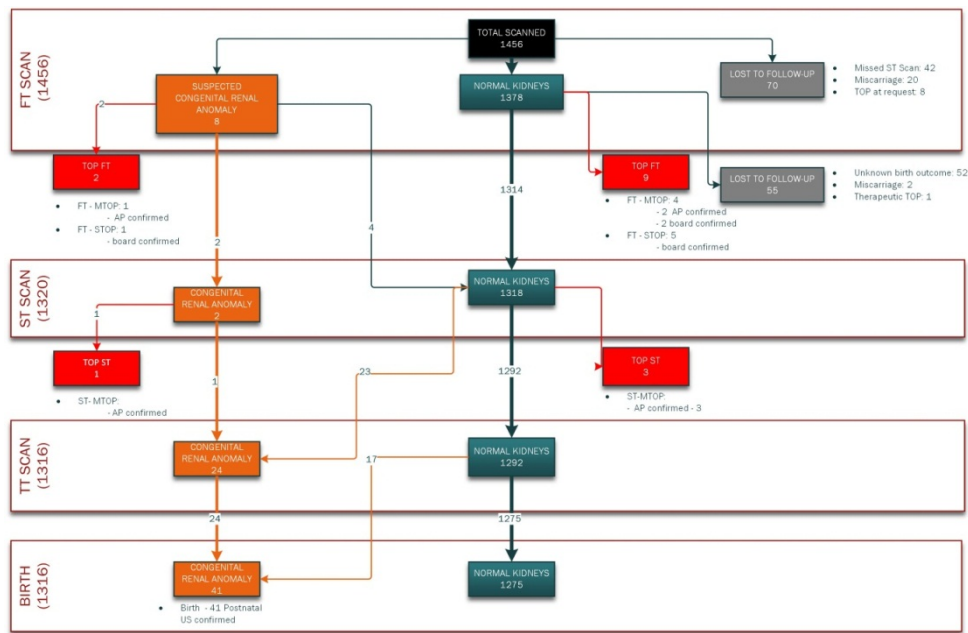


Fig.1. Flow diagram (recommended for accuracy studies)

The median maternal age was 32 (range 18-43) years, the median gestational age was 12.4 (range 11.4 - 15.5) weeks, the median maternal BMI was 21.24 (range 16.5 - 36) and the median CRL was 66 (range 44 - 74) mm. In our study population the prevalence of congenital renal anomalies was 3.31%.

From the 44 cases identified prenatally, the FT scan was positive in just 4 cases. We had another 4 cases false-positive in the FT, all

confirmed as normal kidney in the second trimester, third trimester and postpartum.

The visualization rate of fetal kidneys at 11 weeks (between 11+0 weeks and 11+6 weeks, CRL between 44 and 52 mm), 12 (between 12+0 weeks and 12+6 weeks, CRL between 52.6 and 66.6 mm) and 13 weeks (between 13+0 weeks and 13+6 weeks, CRL between 67 and 74 mm) is represented in Fig.2.

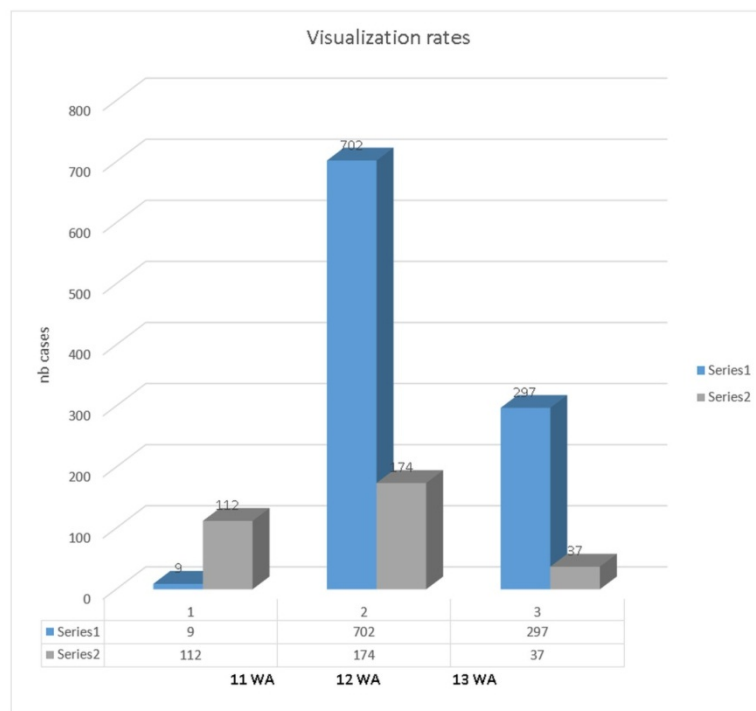


Fig.2. Visualization rates at different gestational age, in the late first trimester.

The renal pathology was suspected in the first trimester in 8 cases, confirmed by second-trimester scan at 18-22 weeks in 2 cases, when no associated anomalies were detected. The standard detailed second-trimester scan at 18-22 weeks diagnosed another 23 cases. The third

trimester added another 17. All cases diagnosed in the ST and third trimester were confirmed by the postpartum scan.

Our final results regarding the FT antenatal suspected diagnosis, the type of evolution and the pregnancy outcome are summarized in Fig.3.

Nb	Mother's age	FT prenatal dg	ST prenatal dg	TT prenatal dg	fam history	Postabortum /postnatal dg	Associated FT Struct Anom	genetics	autopsy	outcome
1	31	Unilateral increased echogenicity of the renal cortex, unilateral pyelectasis appearance	unilateral multicystic dysplastic kidney	-	none	Unilateral MCKD	none	Normal karyotype	Performed, confirmed MCKD	ST MTOP
2	34	Bilateral pyelectasis	-	-	none	Horseshoe kidney	Clenched hands, AVSD	Trisomy 18	Performed, confirmed horseshoe kidney	FT MTOP
3	31	unilateral pyelectasis appearance, with antero-posterior diameter of the right renal pelvis 4.4 mm, normal bilateral renal length and echogenicity of the renal cortex	pyeloureteral duplication and cortical renal cysts (right kidney), normal left kidney	pyeloureteral duplication and cortical renal cysts (right kidney), normal left kidney	none	-unilateral pyelectasis and two cortical cysts (right kidney) - normal left kidney	none	Normal karyotype	-	Birth, expectance, clinical and ultrasound follow-up
4	37	Bilateral pyelectasis	-	-	none	unknown	Hypoplastic nasal bone, large NT	Trisomy 21	Not performed	FT TOP
5	23	Bilateral pyelectasis	Normal kidneys	Normal kidneys	none	Normal kidneys	none	Normal karyotype	-	birth
6	26	unilateral pyelectasis	Mild unilateral pyelectasis	Mild intermittent unilateral pyelectasis	none	Normal kidneys	Hypoplastic nasal bone, large NT	Normal karyotype	-	birth
7	22	Unilateral increased echogenicity of the renal cortex	Normal kidneys	Normal kidneys	none	Normal kidneys	none	-	-	birth
8	30	Bilateral increased echogenicity of the renal cortex	Normal kidneys	Normal kidneys	none	Normal kidneys	Echogenic intracardiac foci	Normal kidneys	-	birth

Fig.3. Cases screened positive at first trimester detailed anomaly scan. Aspects in the follow-up program and outcome.

In 2 FT suspected cases additional structural or chromosomal anomalies were present.

In 2 cases diagnosed in early pregnancy with mild pyelectasis, the disease eventually regressed: in one case it resolved spontaneously and in one case the pyelectasis remained minor in the second trimester.

From the 6 cases early diagnosed with pyelectasis, two were associated with chromosomal anomalies.

We found 2 cases with FT increased echogenicity that had no clinical significance.

Contrary, FT normal findings did not exclude severe congenital anomalies, which were subsequently diagnosed in the follow-up second and third trimester scans.

None of the parents refused postmortem examination after the induced abortion. From the cohort that entered the study, the postmortem examination or autopsy workup was attempted in 14 cases. In 12 cases the pathology confirmed the prenatal diagnosis (2 cases of congenital anomaly and 10 cases of normal kidneys), and in 2 cases detailed pathologic examination was impossible because of severe autolysis or fragmentation of the fetus secondary to TOPs.

The sensitivity, specificity and positive and negative likelihood ratio values and diagnostic odds ratio with 95% CI for 2D FT ultrasound techniques are shown in Fig.4.

2DUS		
Se	19.05%	95% CI: 5.56 % - 41.92 %
Sp	99.69%	95% CI: 99.22 % - 99.91 %
PPV	50.00%	95% CI: 16.01 % - 83.99 %
NPV	98.72%	95% CI: 97.95 % - 99.25 %
LR+	62.38	95% CI: 16.71 - 232.86
LR-	0.81	95% CI: 0.66 - 0.99
DOR	76.82	95% CI: 17.73 - 332.85

Se=Sensitivity, Sp = Specificity, PPV= positive predictive value, NPV = negative predictive value, LR+=Positive likelihood ratio, LR-= Negative likelihood ratio, DOR = Diagnostic odds ratio,

	Real Dg +	Real Dg -
FTUS +	4	4
FTUS -	17	1306

Fig.4. Sensitivity, specificity, positive and negative likelihood ratio values and diagnostic odds ratio with 95% CI for 2DUS method in detecting congenital renal anomalies.

Positive 2DUS scans diagnose congenital renal anomalies with high accuracy (specificity 99.69%). When negative, 2DUS identify fetuses with normal kidneys with very low accuracy (sensitivity 9.09%).

Our results showed that, in first trimester, +LRs for 2DUS technique were 29.25 proving moderate to low evidence for ruling in congenital renal anomalies. -LRs were 0.91 showing poor evidence for ruling out kidney anomalies.

Discussions

As many other systems, the kidneys' visualization rates are linearly dependent on the gestational age at presentation.

Our population study is too small to draw conclusions. Still, we confirm that FT US holds for FP and FN results in terms of congenital kidney diseases [10, 11, 12,13]. Early FT scan cannot reliably diagnose any kidney pathology even if using high quality US systems. Our study results confirm that the diagnosis of normality or abnormality of the kidneys is difficult to assess in the FT, and that the long

time evolution of fetal kidney's diseases is virtually impossible to predict in early pregnancy. Most congenital kidney diseases are either not present in the FT, or not detectable, and the kidney FT appearance may be as well unremarkable.

Concerning long-term counseling after FT anomaly scan, reference to fetal kidneys evolution is unadvisable, both in cases with mild abnormal US appearance, and in cases with normal aspects.

In our study we demonstrate that FT scan has high specificity and could be useful for assessing normality of the kidney, yet -LR is almost 1, showing minimal decrease in likelihood of disease.

We consider that FT scan for kidneys abnormalities is not a very helpful test due to the low sensitivity that can lead to a large number of false negative results. Second and third trimester scan are more relevant for congenital kidney diseases.

Maternal anxiety is almost equally profound before invasive maneuvers and before non-invasive ones [14], like the ultrasound exam.

And there is no evidence that an earlier prenatal diagnosis has a less long-term emotional impact than later in gestation [15], the psychological side effects of prenatal diagnostic procedures being a reality of nowadays medicine.

An abnormal US finding, although minor, always leads to parental anxiety and emotional confusion. After identifying a FT marker of abnormality, we should be able to clarify whether there is an important feature or not. This attitude proved to be very difficult in cases of suspected kidneys anomalies. On the other hand, diagnostic of an abnormality must be correlated with the test's accuracy, and in terms of minor features in the FT, as pyelectasis and hyperechogenic kidneys, persists vagueness in definition and incidence [16,17].

To illustrate, we present two of the cases with mild pyelectasis in the FT (Fig.5A and 5B, and 6A and 6B, respectively). Although they presented very different outcome, both structural

anomalies showed similar findings at the FT anomaly scan: pyelectasis appearance and normal kidney size. In terms of antero-posterior diameter of the pelvis, the first was much less ultrasound symptomatic at the FT scan (see Fig.5A first row) than the other case (see Figure 4A first row), yet the ST scan showed a much more severe evolution (see Fig.3A second row and Fig.4B second row). The most important feature for the first case was the increased echogenicity of the renal cortex in the FT, yet with a pyelic diameter less than 2 mm. For the first case, pathology was instrumental in confirming postmortem features. To our knowledge this is the first report linking the FT increased echogenicity of kidney parenchyma to early ST development of multicystic dysplastic kidney (MCDK) by serial scans, and the published literature does not offer sufficient information in regards with FT appearance of MCDK.

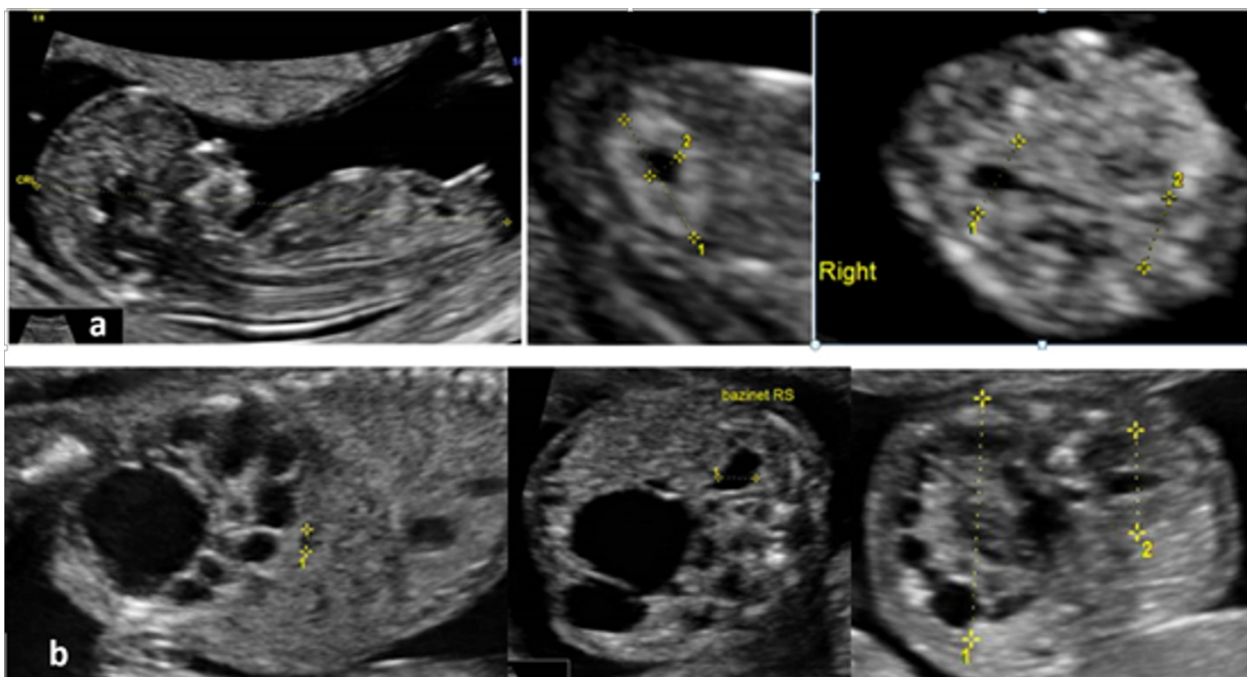


Fig.5A. Case 1, ultrasound features at 11+3 gestational weeks (first row) and at 16+2 gestational weeks (second row)

-11+3 weeks of amenorrhea scan: gray-scale 2D examination showed unilateral increased echogenicity of the renal cortex, with pyelectasis appearance, antero-posterior diameter of the right renal pelvis 1.7 mm, normal bilateral renal length. No other associated structural abnormalities were noted in terms of genetic markers and structural features. CRL (crown-rump length) was consistent with menstrual dates (59.4 mm). The mother's kidneys appeared normal.
-16+2 weeks of amenorrhea scan: unilateral multicystic dysplastic kidney (MCDK) (right kidney), contralateral borderline pyelectasis (left kidney).

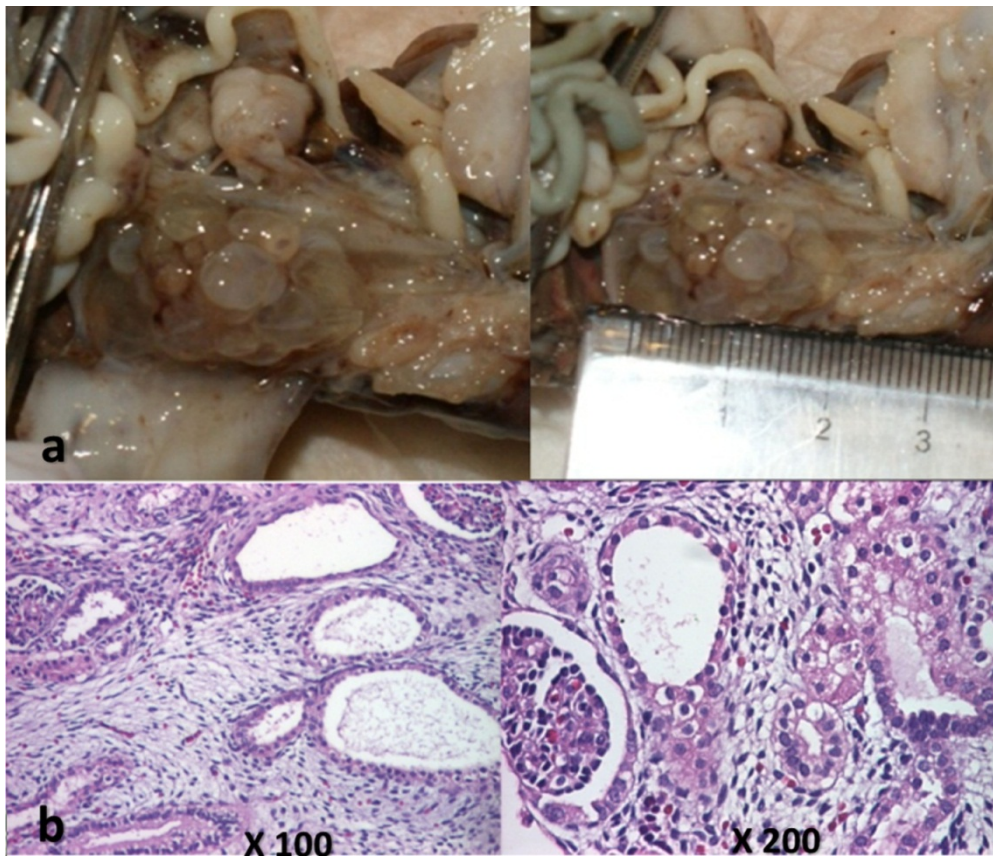


Fig.5B. Case 1, intact specimen obtained after medical termination of pregnancy, pathological examination. Macroscopic (first row) and microscopic (second row) aspects at autopsy. The diagnosis was confirmed.

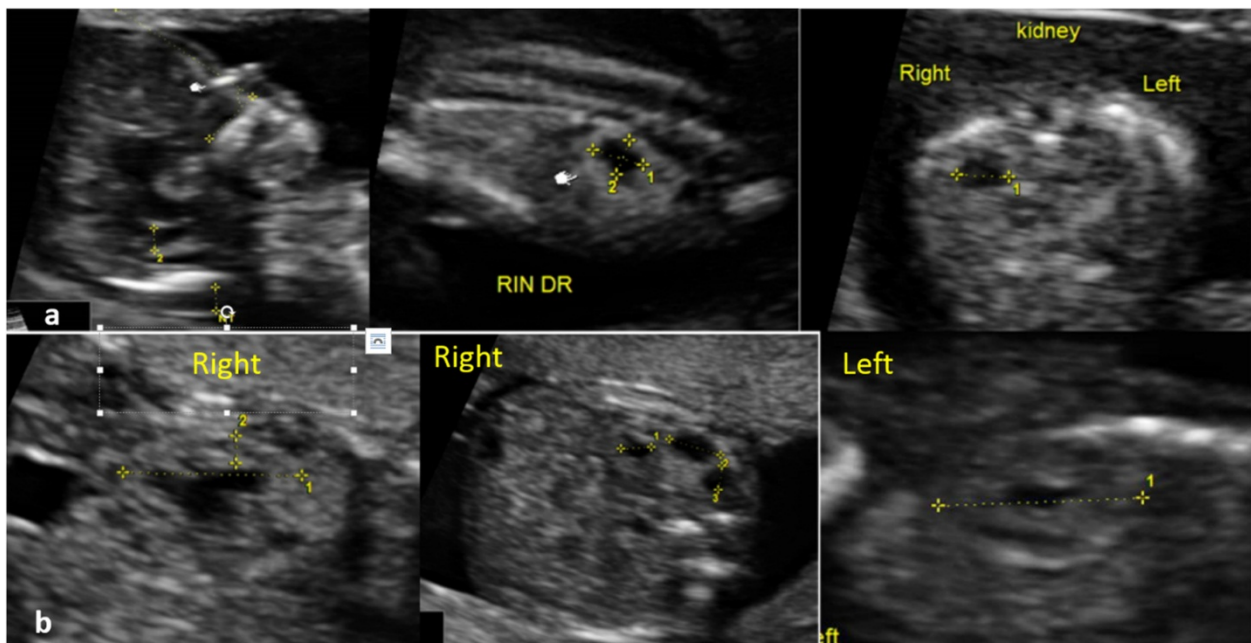


Fig.6A. Case 3, ultrasound features at 12+4 gestational weeks (first row) and at 16+5 gestational weeks (second row)
 - 12+4 weeks of amenorrhea. Gray-scale 2D examination showed unilateral pyelectasis appearance, antero-posterior diameter of the right renal pelvis 4.4 mm, normal bilateral renal length and echogenicity of the renal cortex. No other associated structural abnormalities were observed at the detailed anomaly FT scan. The mother's kidneys appeared normal.
 -early second trimester scan: the diagnostic was suspicion of unilateral pyeloureteral duplication and renal cyst (right kidney), normal left kidney.

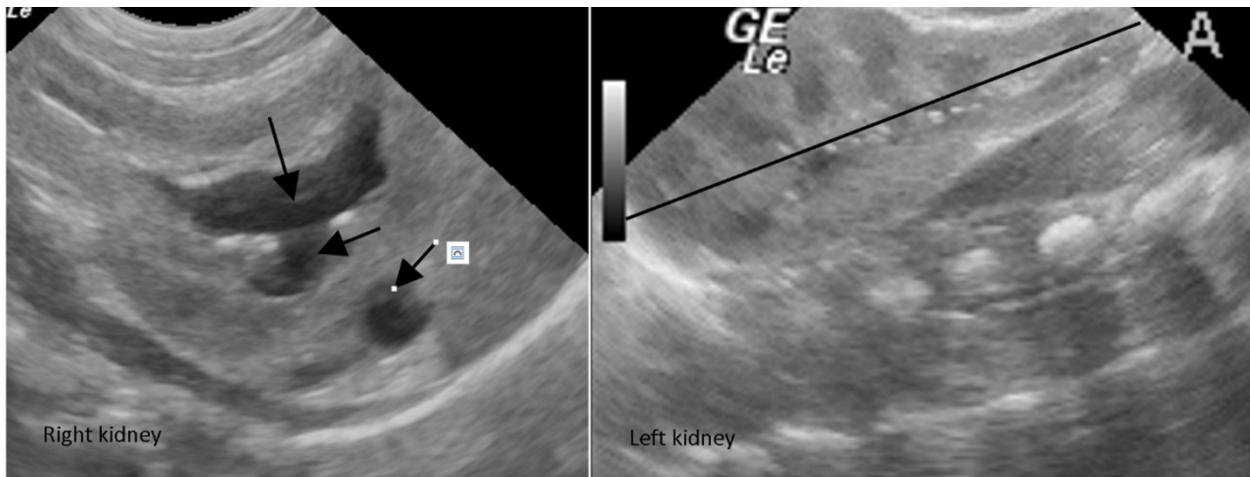


Fig.6B. Case 3, postpartum findings showed right unilateral pyelectasis and cortical cyst and normal left kidney.

Many cases had FT kidney images qualified by trained sonographers as “normal”. Subsequently development of unilateral MCDK (Fig. 7A and 7B), complete non-functional

kidneys (Fig.8, 9) and severe congenital hydronephrosis support our conclusions and confirm previous reports on natural history of congenital kidneys’ diseases [18-21].

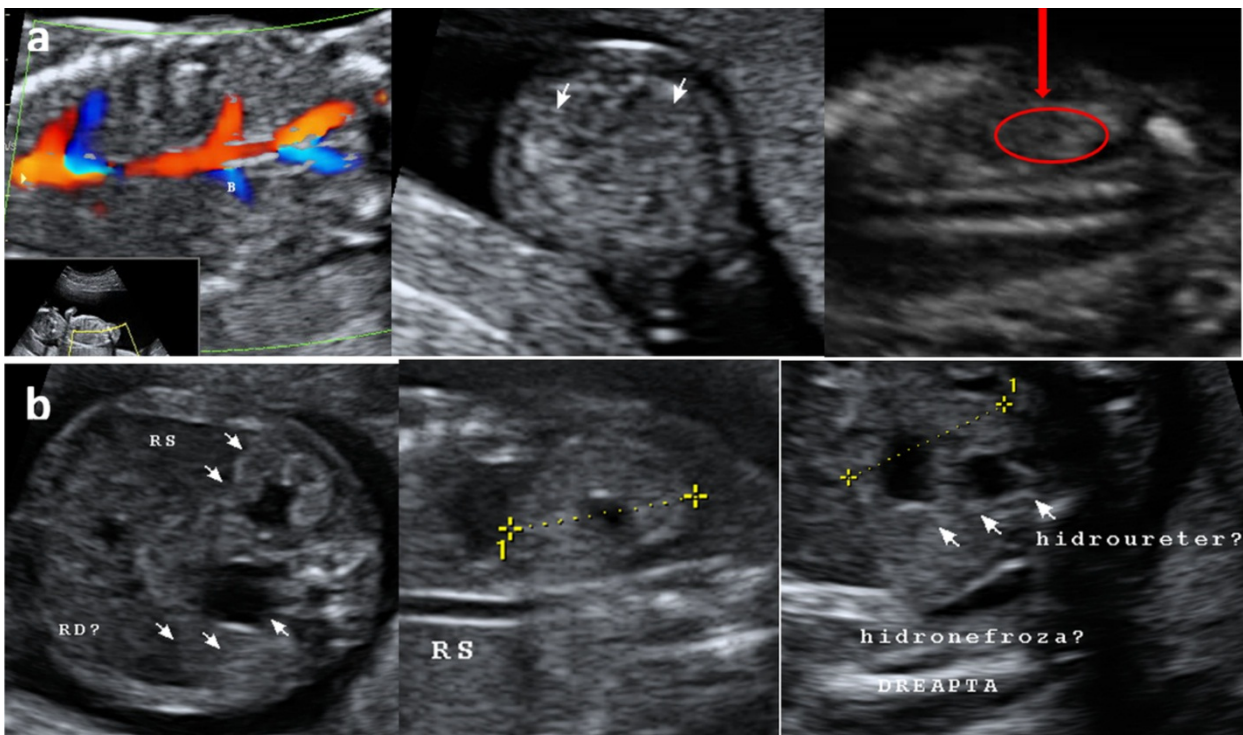


Fig.7A. Case of unilateral MCDK, ultrasound examination negative in the FT.
 - 12+0 WA: normal kidneys (first row)
 - 18+3 WA: bilateral hydronephrosis, mild on the left kidney. The right kidney moderate hydronephrosis and dilation of the right ureter.

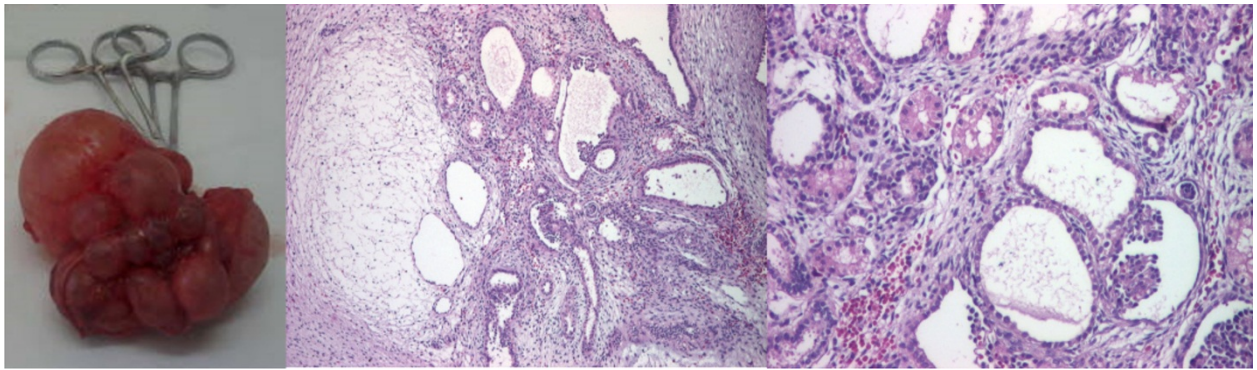


Fig.7B. Same case, unilateral MCDK, postpartum aspects, after unilateral nephrectomy; microscopic confirmation.

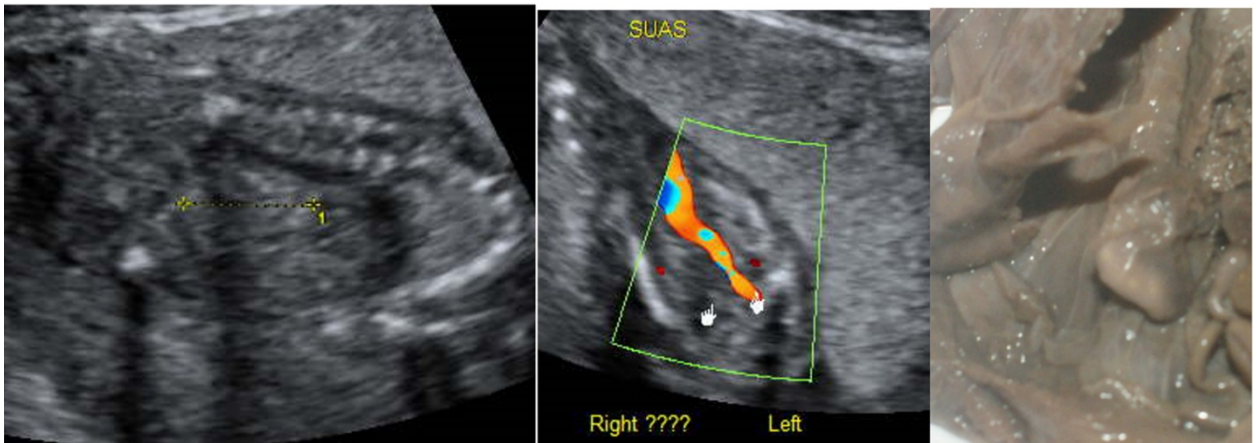


Fig.8. Case of Potter syndrome. FT detailed anomaly scan showed a single umbilical artery, normal kidney images, no structural anomaly.

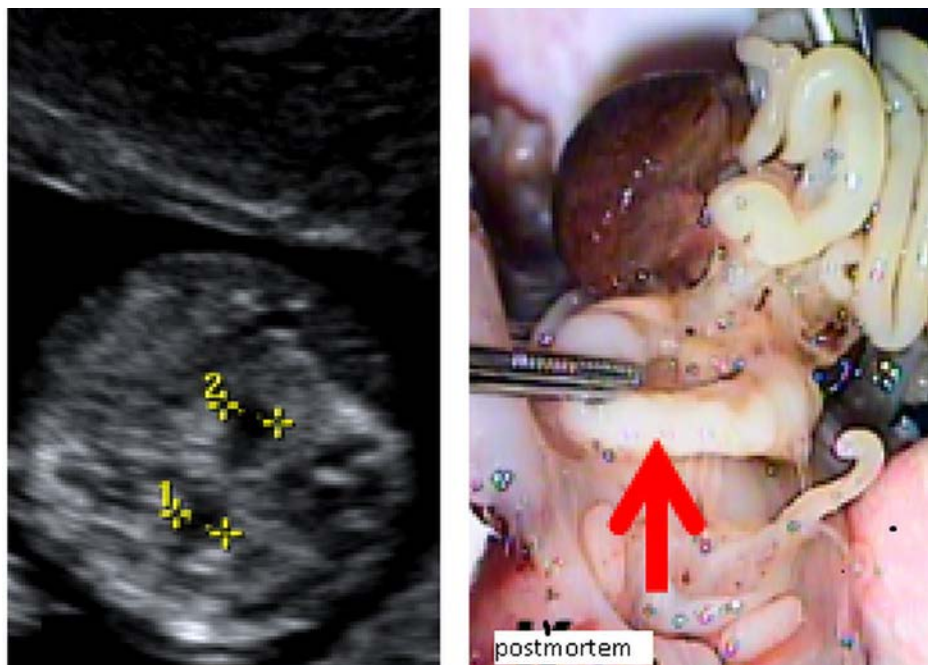


Fig.9. Case 2. Ultrasound kidneys' features at 12+3 WA: mild bilateral pyelectasis. Multiple associated additional markers for chromosome anomaly (cardiac anomaly, clenched hands, hypoplastic nasal bone) were found. Karyotype (from chorionic villus sampling) at 12+4 WA confirmed trisomy 18. Postmortem autopsy revealed horseshoe kidneys.

Conclusions

First trimester scan should be seen as a screening tool, despite the growing resolution of the machines.

Integration of high resolution US technology into standard clinical care will require thoughtful changes in patient counseling [22]. We do not need to increase the anxiety of the pregnant women (or the anxiety of the couple) before we can give any reliable explanation of our findings, because kidneys may appear hyperechoic in the FT, and may present pyelectasis appearance, without any subsequent abnormality in almost all cases.

Our results underline principles of uncertainty, and lack of correlation between the FT and the ST/third trimester/postnatal kidney findings. FT scan has reached perhaps the point where guidelines for scanning must be accompanied by guidelines for counseling in respect to FT findings, as they do for the ST scan. A correct diagnosis is essential for adequate counseling in pregnancy, and kidneys are inaccessible for the FT diagnosis. Clinicians involved in antenatal diagnostic should be competent, tactful and aware of the FT scan limits when counseling about suspected kidneys congenital anomalies in early pregnancy.

References

1. Syngelaki A, Chelemen T, Dagklis T et al. Challenges in the diagnosis of fetal non-chromosomal abnormalities at 11-13weeks. *Prenat Diagn* 2011; 31:90-102.
2. Iliescu DG, Tudorache S, Comanescu A et al. Improved detection rate of structural abnormalities in the first trimester using an extended examination protocol. *Ultrasound Obstet Gynecol* 2013; 42:300-309.
3. International Society of Ultrasound in Obstetrics & Gynecology. ISUOG Practice Guidelines: performance of first-trimester fetal ultrasound scan. *Ultrasound Obstet Gynecol* 2013; 41:102-13
4. Public Health Agency of Canada (PHAC). Perinatal health Indicators for Canada 2011. Ottawa, 2012: 19-21.
5. Abuhamad A, Chaoui R. Genetic aspects of congenital heart defects. In *A Practical Guide to Fetal Echocardiography: Normal and Abnormal Hearts*, 2nd ed. 2010, Philadelphia, PA: Lippincott Williams & Wilkins, 384 pp: 2009; 11
6. Demott K, Bick D, Norman R et al. Clinical Guidelines And Evidence Review For Postnatal Care: Routine Post Natal Care Of Recently Delivered Women And Their Babies. National Collaborating Centre For Primary Care And Royal College Of General Practitioners. 2006; 282-286. Available from: <http://www.nice.org.uk/nicemedia/pdf/CG037fullguideline.pdf>
7. Scheimberg I The genetic autopsy. *Curr Opin Pediatr*. 2013; 25:659-65.
8. Potter's Pathology of the Fetus, Infant and Child, 2nd Edition Editor(s) : Gilbert-Barness & Kapur & Oligny & Siebert 2007.
9. Bossuyt PM, Reitsma JB, Bruns DE et al. Standards for Reporting of Diagnostic Accuracy. Towards complete and accurate reporting of studies of diagnostic accuracy: the STARD initiative. Standards for Reporting of Diagnostic Accuracy. *Clin Chem*. 2003;49:1-6.
10. Kontopoulos E, Odibo A, Wilson RD. Current controversies in prenatal diagnosis 2: are we ready to screen for fetal anomalies with first trimester ultrasound?. *Prenat Diagn* 2013;33:9-12
11. Zalel Y, Lotan D, Achiron R et al. The early development of the fetal kidney—an in utero sonographic evaluation between 13 and 22 weeks' gestation. *Prenat Diagn*, 2002; 22: 962-965.
12. Bronshtein M, Kushnir O, Ben-Rafael Z et al. Transvaginal sonographic measurement of fetal kidneys in the first trimester of pregnancy. *J Clin Ultrasound* 1990; 18: 299-301.
13. Bronshtein M, Amit A, Achiron R, et al. The early prenatal sonographic diagnosis of renal agenesis: techniques and possible pitfalls. *Prenat Diagn*. 1994;14:291-7.
14. Williams L, Zapata LB, D'Angelo DV et al. Associations between preconception counseling and maternal behaviors before and during pregnancy. *Matern Child Health J*. 2012;16:1854-61.
15. Fisher J. First-trimester screening: dealing with the fall-out. *Prenat Diagn*, 2011; 31: 46-49.
16. Dagklis T, Plasencia W, Maiz N et al. Choroid plexus cyst, intracardiac echogenic focus, hyperechogenic bowel and hydronephrosis in screening for trisomy 21 at 11+0 to 13+6 weeks. *Ultrasound Obstet Gynecol*, 2008; 31:132-5
17. Whitlow B J, Lazanakis M L, Kadir R A et al. The significance of choroid plexus cysts, echogenic heart foci and renal pyelectasis in the first trimester. *Ultrasound Obstet Gynecol*, 1998; 12: 385-390.
18. Dungan JS, Fernandez MT, Abbitt PL et al. Multicystic dysplastic kidney: natural history of prenatally detected cases. *Prenat Diagn*. 1990;10:175-82.
19. Matsell DG, Bennett T, Goodyer P et al. The pathogenesis of multicystic dysplastic kidney disease: insights from the study of fetal kidneys. *Lab Invest*. 1996;74:883-93.
20. Chaumoitre K, Brun M, Cassart M et al and for the Groupe Radiopédiatrique de Recherche en Imagerie Foetale (GRRIF), Differential diagnosis of fetal hyperechogenic cystic kidneys unrelated to renal tract anomalies: a multicenter study. *Ultrasound Obstet Gynecol*, 2006; 28: 911-917.
21. Guerriero S, Gerada M, Piras S et al. Bilateral fetal hyperechogenic kidneys associated with normal amniotic fluid: an ethical dilemma in a normal variant? *Prenat Diagn* 2006; 26: 190-191.
22. Roume J and Ville Y. Prenatal diagnosis of genetic renal diseases: breaking the code. *Ultrasound Obstet Gynecol* 2004; 24: 10-18

Corresponding Author: Ștefania Tudorache, University of Medicine and Pharmacy Craiova, Obstetrics and Gynecology, Prenatal Diagnostic Unit, University Emergency Hospital, Craiova, Romania, Petru Rareș Street, No 2-4, 200345 Craiova, Romania; e-mail: stefania.tudorache@gmail.com