

## Aerosol containment box for laser treatment of retinopathy of prematurity in COVID-19 pandemic

Parveen Sen, Jaichandran V V<sup>1</sup>, Janani Sreenivasan

Type 1 retinopathy of prematurity (ROP) requires emergency intervention and laser is an established modality of treatment. Laser treatment for ROP under topical anesthesia can be considered as an aerosol-generating procedure due to crying that puts health care workers at high risk of COVID-19 transmission. Aerosol containment box (ACB) is known to minimize aerosol transmission and there are reports of ROP laser done through incubator. Combining these two ideas, we describe a new application of ACB with suction for laser treatment of ROP thereby, reducing risk to health care team without compromising timely effective, and safe treatment for ROP.

**Key words:** Aerosol containment box, aerosol-generating procedure, laser for retinopathy of prematurity, reduction of aerosol transmission, retinopathy of prematurity

### Access this article online

**Website:**

www.ijo.in

**DOI:**

10.4103/ijo.IJO\_3155\_20

### Quick Response Code:



Coronavirus disease-2019 (COVID-19) is an ongoing pandemic caused by severe acute respiratory syndrome coronavirus 2, transmitted from person to person, by small droplets (aerosols) produced when an infected patient coughs, sneezes, talks, or even breathe normally.<sup>[1]</sup> It is established that loud speaking results in the increased aerosol generation and the same may be extrapolated to a crying child.<sup>[2]</sup> Many innovations have been described to minimize aerosol transmission, notably for general anesthesia (GA).<sup>[3]</sup> We describe one such technique of utilizing aerosol containment box (ACB) with suction for laser treatment of infants with retinopathy of prematurity (ROP). The application of ACB has more relevance in the current COVID era, wherein the treating ophthalmologist can give the best of care to the child without exposing themselves and the fellow healthcare workers to the aerosol. Also, by applying suction inside the ACB, authors try to safely eliminate the aerosol generated, adding novelty to the technique.

### Case Report

A 26-day-old-male baby, born at 35 weeks gestational age with 2 kg birth weight was referred for ROP screening. During the early neonatal period, there was a history of multiple systemic problems like shock, seizures, anemia, and respiratory distress syndrome requiring ventilator support for four days. The child was diagnosed to have stage 3 zone 2 posterior ROP with flat neovascularization, multiple vascular loops with

intraretinal shunts in zone 2 posterior avascular retina, and plus disease in both eyes. In view of anticipated rapid progression, laser photocoagulation by Indirect ophthalmoscope laser delivery (LIO) was planned. Detailed history regarding COVID symptoms and travel from containment zone, elicited from parents, was negative. COVID-19 status of the parents and child was unknown. After obtaining informed consent from parents, the baby was taken up for LIO under topical anesthesia.

Laser treatment in a crying baby can be a significant aerosol-generating procedure.<sup>[2]</sup> To avoid this, an ACB was used. ACB has six sides, named A-F, described in detail later. The baby was dressed up in OR (operating room) dress and covered with a small blanket, adequate to prevent hypothermia. Trained OR assistants handled the baby under the supervision of the anesthetist and the surgeon. The baby was placed inside the ACB and removed via the open side B after lifting the plastic sheet. For easy access by the surgeon, the baby was placed over two pillows covered with blankets inside the ACB. ECG chest leads, and pulse oximeter probe were connected and, heart rate and oxygen saturation were monitored by an anesthetist throughout the laser procedure. The suction machine attached to a suction tube passed through Side A aperture was switched on. The baby was held by an assistant through side B, while the surgeon did laser by passing the hands through the holes in sides C, D, and E [Fig. 1]. The laser was performed using

Shri Bhagwan Mahavir Vitreoretinal Services, Medical Research Foundation, Sankara Nethralaya, <sup>1</sup>Department of Anaesthesiology, Medical Research Foundation, Sankara Nethralaya, Nungambakkam, Chennai, Tamil Nadu, India

**Correspondence to:** Dr. Parveen Sen, Senior Consultant, Shri Bhagwan Mahavir Vitreoretinal Services, Sankara Nethralaya, 18 College Road, Chennai - 600 006, Tamil Nadu, India. E-mail: parveensen@gmail.com

Received: 04-Oct-2020

Revision: 19-Nov-2020

Accepted: 29-Dec-2020

Published: 17-Feb-2021

This is an open access journal, and articles are distributed under the terms of the Creative Commons Attribution-NonCommercial-ShareAlike 4.0 License, which allows others to remix, tweak, and build upon the work non-commercially, as long as appropriate credit is given and the new creations are licensed under the identical terms.

**For reprints contact:** WKHLRPMedknow\_reprints@wolterskluwer.com

**Cite this article as:** Sen P, Jaichandran VV, Sreenivasan J. Aerosol containment box for laser treatment of retinopathy of prematurity in COVID-19 pandemic. Indian J Ophthalmol 2021;69:743-5.

double frequency ND: YAG (532 nm)—Oculight TX (IRIDEX, Mountain view, California, USA), with the power of 120 mW, exposure, and Interval of 100 mS each (1800 burns/eye), under topical anesthesia (0.5% Proparacaine). The laser burns of optimal intensity were obtained in the appropriate areas [Fig. 2]. There was one episode of bradycardia (heart rate lower than 100/minute), the procedure was paused, treated by applying gentle physical stimulus over the baby's sole, and then laser resumed. The child was observed two hours after the laser and was doing well. On follow up, the child was seen to have good regression of the disease, so the treatment was considered adequate and advised to review after a week.

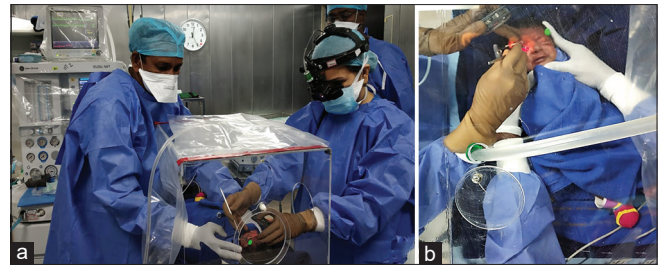
## Discussion

Type 1 ROP has been considered as one of the ocular emergencies during the ongoing COVID-19 pandemic worldwide.<sup>[1,4]</sup> Laser photocoagulation of the avascular retina is an established treatment modality for ROP.<sup>[5-7]</sup> The SARS-Cov-19 associated lockdown in India led to abrupt interruption of public transport and routine outpatient department (OPD) services of hospitals.<sup>[4]</sup> During and post lockdown period, less number of infants were screened both in the OPD and in the NICU (neonatal intensive care unit). As a result, babies presented with more advanced stages, many requiring surgery as the primary intervention.<sup>[4]</sup> This is mainly due to delayed referral and travel difficulties.<sup>[4]</sup> In developed countries, ROP laser is performed under GA or intravenous sedation with topical anesthesia whereas, in Asian countries including India, laser treatment is mostly done under topical anesthesia with vital parameters monitored in NICU or operation rooms, due to systemic complications and logistic issues.<sup>[5]</sup> Despite topical anesthesia, the infant cries due to the unfamiliar environment, LIO's bright light, and retinal burn, thus leading to aerosol generation.<sup>[7]</sup>

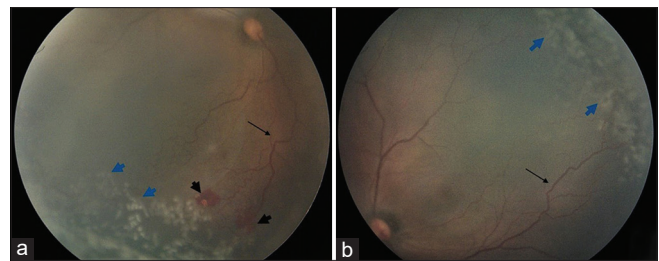
The particle emission rate during human speech is proportional to loudness, ranging from 1-50 particles/second (0.06 to 3 particles/cm<sup>3</sup>) for low to high amplitudes.<sup>[8]</sup> The infant cry, which is a high amplitude vocalization makes ROP laser a potential aerosol-generating procedure. COVID status of the baby is not always known and routine testing before the laser is not recommended (Indian ROP society guidelines).<sup>[1]</sup> Hence, we describe a new technique of using ACB with suction for ROP laser to minimize aerosol transmission.

Tanaka first described laser treatment of ROP in infants through the incubator wall.<sup>[9]</sup> He reported difficulty in focusing laser beam due to curvature of the incubator and a reduction in effective laser power due to "cracks" and "blurs" on the incubator wall.<sup>[9]</sup> Dogra *et al.* reported successful laser treatment of ROP through a double-walled, sloping incubator that had a transparent acrylic wall.<sup>[6]</sup>


ACB has been described to prevent aerosol transmission during general anesthesia.<sup>[3]</sup> We extended its use for ROP laser treatment, based on the reports of successful laser done through incubator walls.<sup>[6,9]</sup> ACB is a cuboid made up of a transparent acrylic sheet of 5 mm thickness with dimensions of 15" X 21" X 19" (length X width X height). ACB has six sides (A–F), two sides (B and F) are open, and the rest four (A, C, D and E) are non-slanting sides with apertures [Fig. 3]. A replaceable and appropriately sized transparent plastic sheet is attached to the upper surface of Side 'B', such that the sheet can be



**Figure 1:** Aerosol containment box (ACB) for ROP laser. (a) shows relative position of the surgeon approaching the baby's eye through the holes in the box and assistant holding the baby through the side covered with plastic sheet. (a) also shows the monitor displaying the vital parameters of the child. (b) shows the position of the baby inside the box and the suction tube passed through an aperture at the superior surface of the box



**Figure 2:** RetCam (Clarity MSI, Pleasanton, California) images of the fundus immediately after laser. RetCam images of the right eye (a) and the left eye (b) shows plus disease in the posterior pole (increased vessel dilatation and tortuosity) [black arrows] and laser marks of optimal intensity in the zone 2 posterior avascular retina [blue arrows]. Besides, blot hemorrhages [black arrowheads] can be appreciated in the right eye, the eye with more severe disease



**Figure 3:** Photograph of the aerosol containment box (ACB). ACB is a rectangular box made up of transparent acrylic sheet with five non-slanting sides, named A to F. Side 'A' is the superior surface with central aperture for passing a suction tube, connected to a suction machine. Side 'B' is open, covered by replaceable plastic sheet and side 'C' is closed except for two holes with cover. Sides D and E have one hole each, with cover. Side F is the inferior side, which is again open

lifted to access the box. A suction tube was inserted through the central aperture in the side 'A', the superior surface and it is connected to a suction machine with a bottle containing 1% Hypochlorite, to remove undesirable aerosol. The aim of the suction tube was not to create an absolute vacuum but to physically remove the aerosol generated. Even if the assistant, the surgeon, and the suction tube are occupying the possible routes of air entry, it is not completely air-tight and there is an adequate gap for air circulation to occur sufficiently which in-turn provided adequate oxygen to the baby. The arterial oxygen saturation remained the same and was monitored throughout the procedure using pulse oximeter. Side 'C' has two holes with cover, whereas sides D and E have one hole each, with covers. The size of each hole was 5" in diameter. The assistant holds the baby through side 'B' and the surgeon can perform laser by passing hands through holes in sides C, D, and E. The laser parameters including time taken for completion were not different from routine. This ACB can be made easily and indigenously in an ophthalmic setup, where incubators are not routinely available, and the addition of tubing attached to a suction machine can further minimize aerosol transmission. After the laser procedure, ACB is cleaned with 70% isopropyl alcohol and dried before using it on another patient. Despite ACBs are used to minimize aerosol transmission, they may not be effective in eliminating the aerosols.<sup>[10]</sup> ACBs are only an adjunct, not a sole barrier and the use of ACBs should never provide a false sense of security to the health care professionals.<sup>[10]</sup> Hence, there should not be any compromise on the need for adequate PPE (personal protective equipment) during aerosol-generating procedures irrespective of the use of ACBs.<sup>[10]</sup> The limitations of the study are application in a single case and the lack of quantitative data on aerosol reduction. These can be viewed as the future scope of the study.

Laser treatment for Type 1 ROP is an ophthalmic emergency which is an aerosol-generating procedure. We describe the novel application of ACB with suction, for ROP laser treatment to minimize the risk of aerosol transmission without compromising the efficiency of laser delivery.

#### Declaration of patient consent

The authors certify that they have obtained all appropriate patient consent forms. In the form the patient(s) has/have

given his/her/their consent for his/her/their images and other clinical information to be reported in the journal. The patients understand that their names and initials will not be published and due efforts will be made to conceal their identity, but anonymity cannot be guaranteed.

#### Financial support and sponsorship

Nil.

#### Conflicts of interest

There are no conflicts of interest.

#### References

1. Gupta V, Rajendran A, Narayanan R, Chawla S, Kumar A, Palanivelu MS, *et al.* Evolving consensus on managing vitreo-retina and uvea practice in post-COVID-19 pandemic era. *Indian J Ophthalmol* 2020;68:962-73.
2. Sivabalan S, Srinath MV. Does a crying child enhance the risk for COVID-19 transmission? *Indian Pediatr* 2020;57:586-87.
3. Hsu SH, Lai HY, Zabaneh F, Masud FN. Aerosol containment box to the rescue: Extra protection for the front line. *Emerg Med J* 2020;37:400-1.
4. Katoch D, Singh SR, Kumar P. Impact of the COVID-19 pandemic on retinopathy of prematurity practice: An Indian perspective. *Indian Pediatr* 2020;57:979-80.
5. Sen P, Wu WC, Chandra P, Vinekar A, Manchegowda PT, Bhende P. Retinopathy of prematurity treatment: Asian perspectives. *Eye (Lond)* 2020;34:632-42.
6. Dogra MR, Vinekar A, Viswanathan K, Sangtam T, Das P, Gupta A, *et al.* Laser treatment for retinopathy of prematurity through the incubator wall. *Ophthalmic Surg Lasers Imaging* 2008;39:350-2.
7. Jiang JB, Strauss R, Luo XQ, Nie C, Wang YL, Zhang JW, *et al.* Anaesthesia modalities during laser photocoagulation for retinopathy of prematurity: A retrospective, longitudinal study. *BMJ Open* 2017;7:e013344.
8. Asadi S, Wexler AS, Cappa CD, Barreda S, Bouvier NM, Ristenpart WD. Aerosol emission and superemission during human speech increase with voice loudness. *Sci Rep* 2019;9:2348.
9. Tanaka S. Laser indirect ophthalmoscope photocoagulation in an incubator for the treatment of retinopathy of prematurity. *Ophthalmic Surg* 1994;25:48-50.
10. Sorbello M, Rosenblatt W, Hofmeyr R, Greif R, Urdaneta F. Aerosol boxes and barrier enclosures for airway management in COVID-19 patients: A scoping review and narrative synthesis. *Br J Anaesth* 2020;125:880-94.