

Bilateral nephrectomy robotic-assisted laparoscopic in children with bilateral Wilms' tumor

Luis Fernando Macente Sala^{a,*}, Giuliano Betoni Guglielmetti^b, Rafael Ferreira Coelho^c

^a Resident in Urology, Division of Urology, Hospital Nossa Senhora das Graças, Curitiba, Paraná, Brazil

^b Department of Urology at the Cancer Institute of the State of São Paulo, São Paulo, Brazil

^c Cancer Institute of the State of São Paulo, ICESP, FMUSP, São Paulo, Brazil

ARTICLE INFO

Keywords:

Robotic
Pediatric
Partial nephrectomy
Radical nephrectomy
Bilateral

ABSTRACT

Our main objective is to report the feasibility of performing simultaneous robotic-assisted laparoscopic (RAL) right partial nephrectomy with contralateral radical nephrectomy in children with bilateral Wilms' tumor. The RAL right partial nephrectomy and contralateral radical nephrectomy were performed via trans-peritoneal with a four-port approach (five ports in one patient), and the patients were repositioned and draped when moving to the other side. The operative time was 90 min, estimated blood loss was 50 cc. Postoperative length of stay was 2 days. No significant intraoperative or postoperative complications occurred.

Introduction

Pediatric and adolescent renal tumours account for approximately 7% of all new cancer diagnoses in the USA each year. The prognosis and treatment are varied based on factors including the underlying histology and tumor stage.¹ The International Society of Pediatric Oncology (SIOP) in Europe advocates chemotherapy before nephrectomy, whereas the Children's Oncology Group (COG) in North America recommends immediate surgery. The two approaches result in comparable overall survival rates, currently reaching approximately 90%. Nevertheless, certain subsets of patients have survival estimates below 90%, including those who presented a tumor relapse. Some risk factors for relapse have been identified. Particularly, surgical factors have been associated with an increased risk of local recurrence.²

Case report

A 3-year-old boy weighing 14 kg, in investigation of macroscopic hematuria, presented with bilateral renal mass and pulmonary metastases. Diagnostic by ultrasound guided core biopsies, and Computer tomography abdomen and thorax(CT) which revealed Bilateral renal tumor. Started preoperative chemotherapy treatment according to protocol SIOP - UMBRELLA-2016, Reassessment of images one month later: of abdomen and thorax(CT) (Fig. 1), with resolution of pulmonary metastases and decrease of renal mass.

He was submitted to a right partial nephrectomy and contralateral radical nephrectomy, used the daVinci Si robotic system (Intuitive Surgical, Mountain View, California) in booth approach. The RAL partial nephrectomy and contralateral radical nephrectomy were performed via a four-port approach (five ports in one patient)(Fig. 2), and the patients were repositioned and draped when moving to the other side. The right partial nephrectomy (Fig. 3) was performed with 6 minutes of renal artery clamping. There were no intraoperative or postoperative complications. The overall surgical time was 1 hour and 30 minutes. Estimated blood loss was 50 cc. He was discharged home on postoperative day 2.

The stage at right kidney by The American Joint Committee on Cancer (AJCC) and International Union Against Cancer (UICC): III and left mass was stage I.

Therapeutic plan: left flank radiotherapy and chemotherapy for 27 weeks with the same scheme above. The need for lung radiation therapy is controversial.

Discussion

Wilms' tumor (WT), also called nephroblastoma, is the most common malignant renal tumor of childhood, affecting approximately one in 10,000 children. Through standardized treatment, outcomes of WT have been improved dramatically, with an overall cure rate of over 85%. Unfortunately, the current status of bilateral Wilms tumor (BWT) is

* Corresponding author.

E-mail addresses: luisfernandosala@gmail.com (L.F.M. Sala), giubg@terra.com.br (G.B. Guglielmetti), coelhohou@yahoo.com.br (R.F. Coelho).

<https://doi.org/10.1016/j.eucr.2020.101146>

Received 21 January 2020; Received in revised form 20 February 2020; Accepted 22 February 2020

2214-4420/© 2020 Published by Elsevier Inc. This is an open access article under the CC BY-NC-ND license (<http://creativecommons.org/licenses/by-nc-nd/4.0/>).

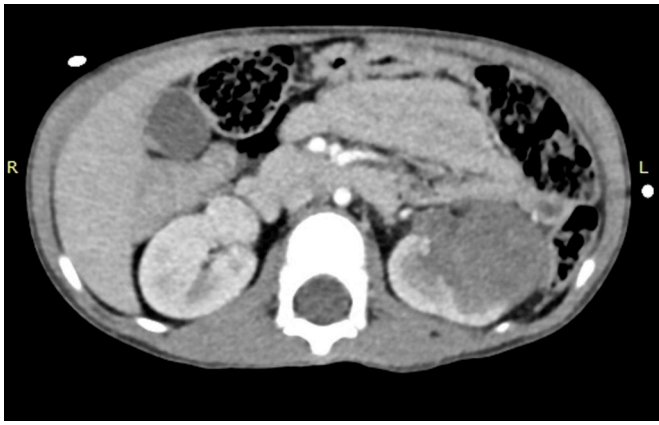

Fig. 1. Right kidney, with normal dimensions. Hypervascularized solid nodule in the anterior cortex of the middle third of the right kidney, measuring 1.8 cm, partially exophytic. Topical left kidney, enlarged, without calculi or hydronephrosis. Infiltrating mass measuring about 6.5 × 3.5 cm, extending from the upper to lower third parenchyma and presenting heterogeneous attenuation.

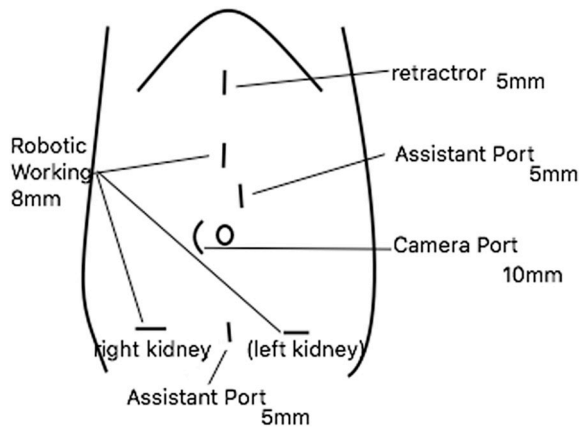


Fig. 2. Disposition of ports in RAL.

totally a different scene. BWT accounts for 5%–8%, of all WTs, which can be synchronous or metachronous.³

Treatment for BWT is challenging, resulting from high risk of relapse and renal failure. To preserve renal function, nephron-sparing surgery (NSS) was advocated in recent years.⁴

One of the changes in treatment for BWT was the application of neoadjuvant chemotherapy. Neoadjuvant chemotherapy was helpful to preserve renal function without survival to be compromised, it has already been accepted by most of surgeons.⁵

Few reports have demonstrated the safety and feasibility of simultaneous bilateral RAL procedures in children, and reports of bilateral simultaneous RAL surgery specifically for BWT are scarce.

In our case, first was performed the left radical nephrectomy, so flipped the patient and was done the right partial nephrectomy. The use of a transperitoneal approach provided direct access to the kidneys and the renal hilum, and a very good view of the tumours. Instead of the time constriction, it was used vicryl 2.0 and end-loaded with Hem-o-lock; clips (Teleflex Inc, Morrisville, USA). Comparing with other described cases the surgical time was inferior (90 minutes), and the blood loss was 50 cc. Xing-liu and cols described 18 BWT in 15 years and the meaning surgical time was 165 minutes and blood loss 173 ml.

We used the port placement an 8.5-mm camera port was placed at the umbilicus. A 10- mm robotic port was placed between the umbilicus and the pubic symphysis. A 10-mm robotic port was placed between the umbilicus and the xyphoid process. A fourth 5-mm assistant port was placed inferior to the xyphoid process. A fifth port was placed just superior to the umbilicus for liver retraction. Our approach allows operating on the contralateral side by reinserting the same ports after flipping the patient.

Conclusion

The robotic-assisted laparoscopic approach to bilateral nephrectomy is a great way to be a part of the treatment of this challenging disease and should be considered in children with bilateral Wilms’ tumor. Expert surgeons are required to minimize the blood loss and the clamping time of renal artery. Further prospective comparative studies with open and laparoscopic approaches are needed to highlight the possible advantages of the RAL method.

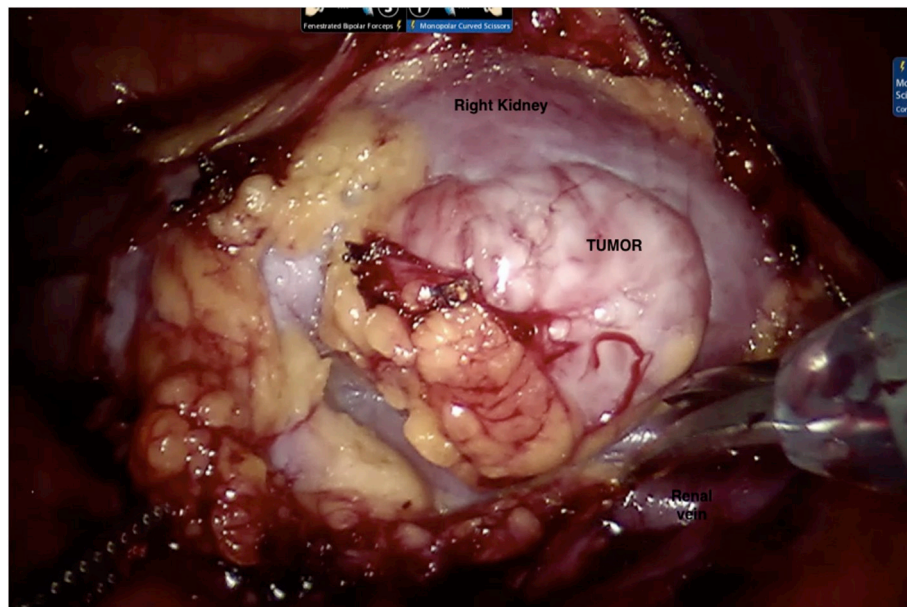


Fig. 3. Intraoperative image of solid nodule in the anterior cortex of right kidney.

Bibliografia

1. Walz AL, Fernandez CV, Geller JI. Novel therapy for pediatric and adolescent kidney cancer [Internet] *Canc Metastasis Rev*. 2019. <https://doi.org/10.1007/s10555-019-09822-4>. Available at: .
2. Schiavetti A, Bonci E, Varrasso G, De Grazia A, Cozzi DA. Evaluation of nephron-sparing surgery as potential risk factor for relapse in unilateral Wilms tumor [Internet] *J Surg Res*. 16 de dezembro de 2019. <https://doi.org/10.1016/j.jss.2019.11.001>. Available at: .
3. Pacilli M, O'Brien M, Heloury Y. Laparoscopic nephro-sparing surgery of juxtglomerular cell tumor in a child [Internet] *J Pediatr Urol*. 1 de outubro de 2016; 12(5):321–322. <https://doi.org/10.1016/j.jpuro.2016.04.035>. Available at: .
4. Roberto P, Lane P, Vance M, Israel F. Bilateral robotic assisted laparoscopic heminephroureterectomy [Internet] *J Urol*. 1 de junho de 2004;171(6 Part 1). <https://doi.org/10.1097/01.ju.0000124999.30706.2394-5>. Available at: .
5. Tan X-H, Zhang D-Y, Liu X, et al. Retrospective analysis to determine outcomes of patients with bilateral Wilms tumor undergoing nephron sparing surgery: 15-year tertiary single-institution experience [Internet] *Pediatr Surg Int*. 2018;34(4):427–433. <https://doi.org/10.1007/s00383-018-4232-6>. Available at: .