

Living donor liver transplantation prior to multiple myeloma treatment in a patient with hepatitis B-associated hepatocellular carcinoma and liver cirrhosis: a case report

Chan Woo Cho¹, Nuri Lee², Gyu-Seong Choi³, Jong Man Kim³, Choon Hyuck David Kwon³, Jae-Won Joh³

¹Department of Surgery, Yeungnam University College of Medicine, Daegu, Korea

²Department of Surgery, Pusan National University Hospital, Busan, Korea

³Department of Surgery, Samsung Medical Center, Sungkyunkwan University School of Medicine, Seoul, Korea

Clinical outcomes of living donor liver transplantation (LDLT) for hepatocellular carcinoma (HCC) in patients with multiple myeloma (MM) have not been established in terms of HCC recurrence and MM deterioration after LDLT. A 51-year-old man with chronic hepatitis B was diagnosed with HCC and MM. Since the patient also had decompensated liver cirrhosis (LC), he underwent LDLT prior to autologous peripheral blood stem cell transplantation (PBSCT) to prevent fulminant hepatitis due to HBV reactivation. The patient received Epstein-Barr virus prophylaxis and a triple immunosuppressive regimen of tacrolimus, everolimus, and steroid after LDLT. Autologous PBSCT was performed 7 months after LDLT. He showed a complete response to treatment of MM without post-LT complications or HCC recurrence. In conclusion, LDLT could be adapted for treatment of MM patients with combined HCC and decompensated LC because it is an effective strategy of preventing HBV reactivation and HCC recurrence after induction therapy of MM.

[Ann Surg Treat Res 2018;94(4):216-218]

Key Words: Living donor liver transplantation, Multiple myeloma, Hepatocellular carcinoma

INTRODUCTION

Multiple myeloma (MM) is a clonal plasma cell malignancy that predominantly affects bone marrow [1]. The prevalence of HBV in MM patients is higher than in other hematological malignancies [2]. Although 1 case report described a liver transplant (LT) recipient suffering from MM as a complication after LT, to the best of our knowledge, clinical outcomes of MM after living donor liver transplantation (LDLT) have not been reported in MM patients requiring LT for liver cirrhosis (LC) caused by chronic HBV infection. We report a case of LDLT prior to autologous peripheral blood stem cell transplantation (PBSCT)

in an MM patient with hepatitis B-associated hepatocellular carcinoma (HCC) and LC.

CASE REPORT

A 49-year-old male who had been an HBV carrier for nearly 30 years was admitted to Samsung Medical Center with a chief complaint of abdominal distention due to ascites related to LC in August 2015. On CT, 2 HCCs satisfying the Milan criteria were detected; they were 4 cm and 2.5 cm in diameter at segments 8 and 5, respectively. HBV DNA was 288 IU/mL. Alpha-fetoprotein and protein induced by vitamin K absence/antagonist-II

Received May 31, 2017, Revised June 22, 2017, Accepted July 12, 2017

Corresponding Author: Jae-Won Joh

Department of Surgery, Samsung Medical Center, Sungkyunkwan University School of Medicine, 81 Irwon-ro, Gangnam-gu, Seoul 06351, Korea

Tel: +82-2-3410-3466, Fax: +82-2-3410-0040

E-mail: jwjoh@naver.com

ORCID code: <https://orcid.org/0000-0003-1732-6210>

Copyright © 2018, the Korean Surgical Society

© Annals of Surgical Treatment and Research is an Open Access Journal. All articles are distributed under the terms of the Creative Commons Attribution Non-Commercial License (<http://creativecommons.org/licenses/by-nc/4.0/>) which permits unrestricted non-commercial use, distribution, and reproduction in any medium, provided the original work is properly cited.

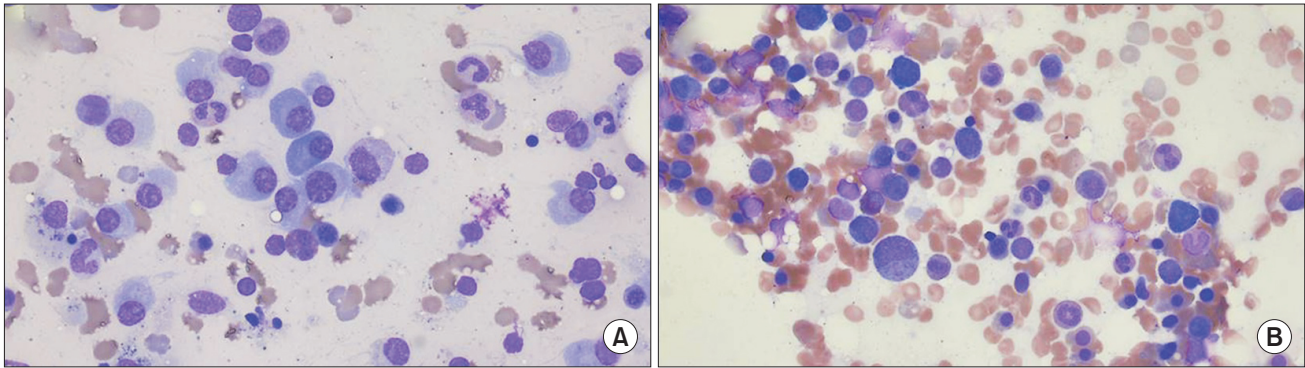


Fig. 1. Bone marrow aspiration ($\times 400$): plasma cell proliferation at the time of diagnosis (A), absence of residual plasma cells after autologous peripheral blood stem cell transplantation (B).

levels were 5.0 ng/mL and 30 mAU/mL, respectively. The patient's laboratory results indicated pancytopenia, and upon further evaluation he was diagnosed with monoclonal IgG- λ (monoclonal peak of 884 mg/L) MM, representing stage IIIA disease according to Salmon and Durie classification and stage II according to the International Scoring System. Bone marrow examination revealed 48% plasma cell proliferation (Fig. 1A). 1q21 amplification (67%) was detected on fluorescence *in situ* hybridization. Since fulminant hepatitis can occur during or after cytotoxic therapy for MM, the patient elected to undergo LDLT prior to treatment of MM. LDLT was performed on August 27, 2015. The patient received basiliximab twice at a cumulative dose of 40 mg on the day of operation and on postoperative day (POD) 4 as induction immunosuppression. Tacrolimus (FK), mycophenolate mofetil (MMF), and steroids were used as maintenance agents of immunosuppression. FK was initiated on POD 2 and the optimal target trough level during the first month was adjusted to 5–8 $\mu\text{g/mL}$, lower than that of routine recipients. MMF was initiated on POD 3 and administered 500 mg twice per day. On POD 21, MMF was tapered and 0.5 mg of everolimus was administered twice per day. The patient was given 500 mg of intravenous methylprednisolone (MPD) during the anhepatic phase until POD 2, followed by a tapered dose of 60 mg per day for a period of 5 days and 8 mg twice per day for 1 month thereafter starting on POD 8, and, finally, 4 mg of MPD twice a day for 2 months after that, which was discontinued 3 months into the post-LT period. Before LDLT, the patient was administered Epstein-Barr virus (EBV) prophylaxis (intravenous ganciclovir for 2 weeks after LT followed by oral acyclovir for 4 months after LDLT) based on the reported association between EBV and the pathogenesis of MM [3].

One month after LDLT, the patient also received 4 cycles of bortezomib (BOR, 1.3 mg/m²) via subcutaneous injection and dexamethasone (DEXA, 40 mg) on days 1, 4, 8, and 11. A trimethoprim-sulfamethoxazole combination (400 mg/80 mg) and acyclovir (400 mg) were administered as prophylactic therapy. The patient suffered from acute kidney injury with

ileus after the first cycle of the induction regimen, but recovered with conservative management. Two months after induction of BOR-DEXA, the patient underwent autologous PBSCT. The graft contained 3.75×10^6 CD34 cells/kg and the duration of aplasia was 15 days. He has received 5 units of single donor platelet transfusion since PBSCT started. In September 2016, 4 months after PBSCT, bone marrow examination revealed no residual plasma cells (Fig. 1B). A complete response was achieved without abnormal findings on serum and urine protein electrophoresis with immunofixation and quantification of monoclonal proteins. On follow-up CT in December 2016, the patient did not have any abnormal findings indicating recurrence of HCC.

This report was received institutional review board (No.2014-06-052) approval.

DISCUSSION

BOR-DEXA induction followed by autologous PBSCT is a common treatment protocol in MM patients less than 65 years of age [4]. Although MM, a hematologic malignancy, can occur after LT, the clinical outcomes of LT for HCC in MM patients and subsequent MM treatment strategies are not well established. We report the case of a patient who did not experience recurrence of HCC or MM during a follow-up period of more than 1 year after LDLT followed by autologous PBSCT.

With respect to treatment strategies in MM patient with HBV-associated HCC, there are several important considerations. The major issue before and after LDLT is that MM may be aggravated by immunosuppression. EBV infection is associated with MM and can lead to the development of MM after LDLT [3,5]. Thus, immunocompromised LT recipients need EBV prophylaxis. Our patient was given intravenous ganciclovir for 2 weeks postoperative and then oral acyclovir for 2 years according to our protocol. In addition, the trough level of FK, a key maintenance immunosuppressant, was kept low compared with routine recipients.

The second issue is HBV reactivation in MM patients with chronic HBV infection undergoing cytotoxic chemotherapy. Although BOR was found to suppress HBV reactivation *in vitro* study [6], 2 other reports described HBV reactivation in patients receiving BOR therapy for myeloma. Moreover, steroid treatment has most frequently been associated with HBV reactivation in HBsAg-positive patients [7]. LDLT prior to BOR-DEXA induction therapy of MM can decrease the risk of HBV reactivation. According to our protocol, this patient received hepatitis B immune globulin and tenofovir for HBV prophylaxis and was monitored closely.

The last consideration was the risk of combined HCC and MM recurrence. A systematic review demonstrated mTOR inhibition to be associated with a significantly lower rate of HCC recurrence [8]. In a preclinical study, mTOR inhibitors

exerted antimyeloma activity in MM [9]. Promising results were also reported for everolimus in the treatment of relapsed or refractory MM [10]. Thus, our patient was switched from MMF to everolimus with a low dose of FK maintained for 3 weeks after LT.

In conclusion, LDLT prior to BOR-DEXA induction followed by autologous PBSCT can be an effective treatment strategy with decreased risk of HBV reactivation and HCC recurrence in MM patients with combined HBV-associated LC and Milan-criteria HCC.

CONFLICTS OF INTEREST

No potential conflict of interest relevant to this article was reported.

REFERENCES

- Bhandari MS, Mazumder A, Vesole DH. Liver involvement in multiple myeloma. *Clin Lymphoma Myeloma* 2007;7:538-40.
- Huang B, Li J, Zhou Z, Zheng D, Liu J, Chen M. High prevalence of hepatitis B virus infection in multiple myeloma. *Leuk Lymphoma* 2012;53:270-4.
- Sadeghian MH, Ayatollahi H, Keramati MR, Memar B, Jamedar SA, Avval MM, et al. The association of Epstein-Barr virus infection with multiple myeloma. *Indian J Pathol Microbiol* 2011;54:720-4.
- Attal M, Harousseau JL, Stoppa AM, Sotto JJ, Fuzibet JG, Rossi JF, et al. A prospective, randomized trial of autologous bone marrow transplantation and chemotherapy in multiple myeloma. Intergroupe Français du Myelome. *N Engl J Med* 1996;335:91-7.
- Zhang Y, Zhao H, He X, Zheng S, Wang T, Yan D, et al. Effects of Epstein-Barr virus infection on the development of multiple myeloma after liver transplantation. *Sci China Life Sci* 2012;55:735-43.
- Bandi P, Garcia ML, Booth CJ, Chisari FV, Robek MD. Bortezomib inhibits hepatitis B virus replication in transgenic mice. *Antimicrob Agents Chemother* 2010;54:749-56.
- Yeo W, Johnson PJ. Diagnosis, prevention and management of hepatitis B virus reactivation during anticancer therapy. *Hepatology* 2006;43:209-20.
- Cholongitas E, Mamou C, Rodriguez-Castro KI, Burra P. Mammalian target of rapamycin inhibitors are associated with lower rates of hepatocellular carcinoma recurrence after liver transplantation: a systematic review. *Transpl Int* 2014;27:1039-49.
- Holdaas H, De Simone P, Zuckermann A. Everolimus and malignancy after solid organ transplantation: a clinical update. *J Transplant* 2016;2016:4369574.
- Gunther A, Baumann P, Burger R, Kellner C, Klapper W, Schmidmaier R, et al. Activity of everolimus (RAD001) in relapsed and/or refractory multiple myeloma: a phase I study. *Haematologica* 2015;100:541-7.