



Case Report

Pancreatic panniculitis complicated by infection with *Corynebacterium tuberculostearicum*: A case report



S.H. Omland ^{a,1}, C. Ekenberg ^{b,1,*}, R. Henrik-Nielsen ^c, A. Friis-Møller ^b

^a Department of Dermato-venereology, Bispebjerg Hospital, University of Copenhagen, Bispebjerg Bakke 23, 2400 Copenhagen NV, Denmark

^b Department of Clinical Microbiology, Hvidovre Hospital, University of Copenhagen, Kettegaard Allé 30, 2650 Hvidovre, Denmark

^c Department of Pathology, Rigshospitalet, University of Copenhagen, Section 5441, Blegdamsvej 9, 2100 Copenhagen O, Denmark

ARTICLE INFO

Article history:

Received 17 June 2014

Received in revised form 24 June 2014

Accepted 24 June 2014

Keywords:

Pancreatitis

Corynebacterium tuberculostearicum

Panniculitis

Lipophilic infections

ABSTRACT

We present a case of pancreatic panniculitis in a patient with alcohol abuse where *Corynebacterium tuberculostearicum* was isolated from a pannicular nodule on the crus. The patient was started on linezolid treatment leading to regression of the patient's symptoms. Upon discontinuation of linezolid treatment progression of the skin symptoms progressed.

© 2014 The Authors. Published by Elsevier Ltd. This is an open access article under the CC BY-NC-ND license (<http://creativecommons.org/licenses/by-nc-nd/3.0/>).

Introduction

Corynebacterium tuberculostearicum, belonging to the genus *Corynebacterium*, is a relatively “new” bacterium. The species was characterized validly in 2004, and current literature is still limited [1].

Corynebacteria are widely distributed in the environment and colonize the skin and mucous membranes of humans. They are frequently isolated in clinical specimens, and are, apart from *Corynebacterium diphtheriae*, often considered contaminants without clinical significance [2]. However, their clinical impact might be more pronounced. Recently *C. tuberculostearicum* was found being the etiologic agent in clinical infections in 7/18 patients [3]. The majority of these patients had either superinfection of empyema or osteomyelitis of chest wall and ribs, or both.

C. tuberculostearicum is a lipophilic corynebacterium which has also been associated with mastitis [4], and this tuberculostearic subgroup of the corynebacterium seems primarily to be causing nosocomial infections in immunocompromized patients [5].

In the following case report we present a patient with pancreatic panniculitis complicated by infection with *C. tuberculostearicum*.

Case report

A 49 year old man with hypertension, Scheuermann's disease (juvenile osteochondrosis of the spine), osteopenia and alcohol abuse was admitted to hospital due to bilateral, painful, erythematous nodules on the lower legs (Fig. 1), appeared and worsened 4 weeks prior to admission. The patient had been treated with penicillin by his general practitioner based on clinical suspicion of cellulitis. Due to insufficient response to penicillin he was started on intravenous cefuroxime upon admission, and two days later oral clindamycin was added. He soon developed arthralgia in both knees and later in his ankles. Further, severe abdominal pain arose along with increased serum amylases. Upon suspicion of pancreatitis a CT scan was performed revealing edema surrounding the pancreas supporting the diagnosis of pancreatitis. Ultrasound showed cirrhosis of the liver. The patient was treated conservatively for his pancreatitis and afterwards referred to the Department of Orthopedic Surgery due to progression of skin nodule to abscess on the leg. The abscess was incised revealing greasy, yellow material. Upon cultivation, growth of a pure culture of *C. tuberculostearicum* identified by Maldi-Tof (matrix assisted laser desorption ionization time-of-flight) was detected and multiresistance diagnosed following EUCAST criteria. Treatment

* Corresponding author at: Nørrebrogade 32 C, 1. th., 2200 København N, Denmark. Tel.: +45 21979712.

E-mail addresses: silje.haukali.omland.01@regionh.dk (S.H. Omland),

christina.ekenberg@regionh.dk (C. Ekenberg),

regitze.henrik.nielsen.01@regionh.dk (R. Henrik-Nielsen),

alice.friis-moeller@regionh.dk (A. Friis-Møller).

¹ Joint first authorship.

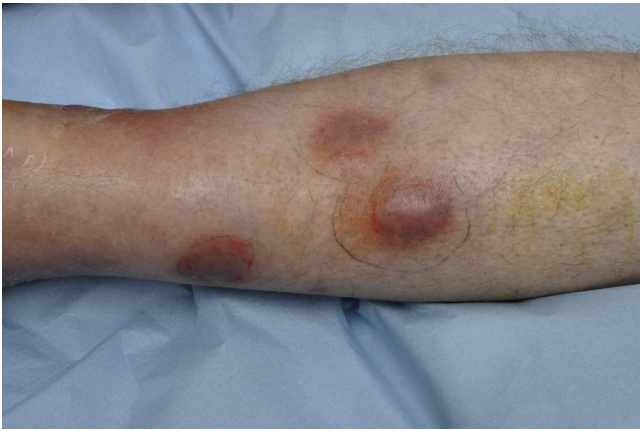

Fig. 1. Left crus with subcutaneous nodules of panniculitis.

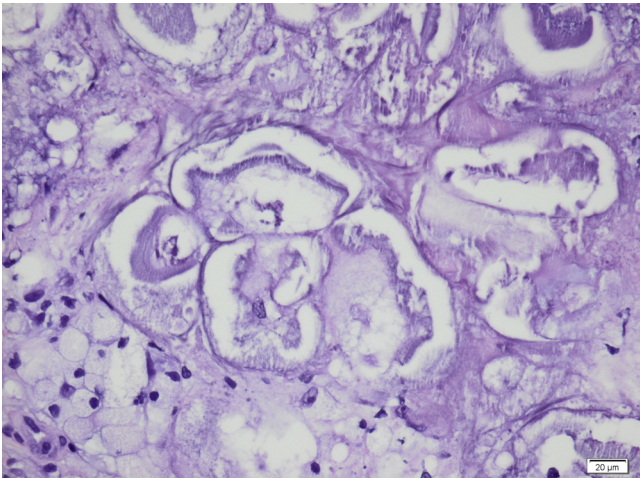


Fig. 2. Pancreatic fat necrosis with ghost cells (H&E 200×).

with linezolid was initiated and cefuroxime treatment was discontinued. The patient was referred to the Department of Dermatology for deep punch biopsy. The histopathologic picture showed a normal epidermis and dermis in continuation with subcutaneous fat with lobular panniculitis with necrosis of adipocytes and ghost-cells with calcification surrounded by a neutrophil rich inflammatory infiltrate. This histological presentation is characteristic for pancreatic panniculitis (Fig. 2). In a Van Kossa staining there was prominent calcification. The patient developed sepsis and blood cultures grew *Citrobacter koseri*. The treatment with linezolid was supplemented with gentamicin, metronidazole and piperacillin/tazobactam for 10 days. Upon discharge from hospital linezolid treatment was continued and the panniculitis was slowly regressing. At follow-up 1 month later in the Outpatient Clinic of Dermatology the panniculitis showed further regression without signs of infection and the linezolid treatment was stopped. Three weeks after linezolid was stopped, the skin again showed progression with 4 new elements.

Discussion

We have presented a case of pancreatic panniculitis with growth of *C. tuberculostearicum* isolated from a nodule in the skin. Pancreatic panniculitis is characterized by subcutaneous fat necrosis that affects 0.3–3% of individuals with a range of pancreatic disease. It may precede by 1–7 months the abdominal symptoms of pancreatic disease [6]. Like many other lipophilic Corynebacteria [2] the *C. tuberculostearicum* found in this patient

was multiresistant to most antimicrobial agents but sensitive to linezolid and tetracycline. The fact that the patient had good clinical response to the linezolid treatment elucidates the potential clinical impact of *C. tuberculostearicum*. This is further supported by the relapse of the patient's symptoms after treatment with linezolid was discontinued. The antimicrobial treatment with linezolid was in this case 36 days, and the relapse indicates that this is too short. A future strategy might be 3 months of tetracycline treatment in cases when clinically relevant infection caused by *C. tuberculostearicum* is suspected.

Current literature has primarily described a role for the bacterium in the etiology of chronic osteomyelitis and mastitis [3,4]. The latter (i.e. mastitis) highlights its potential relevance in fatty tissue infections and also elucidates its potential role in infections emerging from inflammatory fatty tissue such as panniculitis.

The deep punch biopsy from this patient's leg showed subcutaneous fat necrosis. Since *C. tuberculostearicum* is a lipophilic bacterium, the necrosis, apart from being a characteristic presentation of pancreatic panniculitis, could also be a result of possible bacterial lipase activity. However, we were not able to show lipase activity when testing in our laboratory.

15 of the 18 patients presented in Hinic et al's article [3] had a history of long hospital stays, and a majority had undergone prolonged therapy with broad-spectrum antimicrobials. This emphasises the role of *C. tuberculostearicum* in nosocomial infections. The patient presented in this case had prior to admission only been treated with penicillin. However, upon hospitalization broad-spectrum antimicrobial therapy was initiated. Furthermore, the patient did have various underlying comorbidity as well as alcohol abuse rendering his immune system more susceptible to infections. Pancreatic disease is often associated with alcohol abuse. *C. tuberculostearicum* might therefore be of particular relevance in patients suffering from panniculitis caused by pancreatic disorders, since this patient group in general has a higher risk for developing infections [7].

In conclusion we find *C. tuberculostearicum* to be a possible etiologic agent in worsening of infections in the fatty tissue, in particular for patients with decreased immune defence.

It seems probable that the symptoms presented in this case emerge from both pancreatic panniculitis and *C. tuberculostearicum* infection. If clinically relevant infection with *C. tuberculostearicum* is suspected long term treatment might be essential in order to eradicate the infection.

Further studies on cultures from inflammatory nodules in patients with pancreatic panniculitis are warranted in order to establish the role of *C. tuberculostearicum* in this rare inflammatory condition.

References

- [1] Feurer C, Clermont D, Bimet F, Candréa A, Jackson M, Glaser P, et al. Taxonomic characterization of nine strains isolated from clinical and environmental specimens, and proposal of *Corynebacterium tuberculostearicum* sp. nov. *Int J Syst Evol Microbiol* 2004;54(Pt 4):1055–61.
- [2] Meyer DK, Rebou AC. Other Coryneform Bacteria and Rhodococci. In: Mandell, Douglas and Bennett's principles and practice of infectious disease 7th ed. Philadelphia: Churchill Livingstone, Elsevier; 2010.
- [3] Hinic V, Lang C, Weisser M, Straub C, Frei R, Goldenberger D. *Corynebacterium tuberculostearicum*: a potential misidentified and multiresistant *Corynebacterium* species isolated from clinical specimens. *J Clin Microbiol* 2012;50(8):2561–7.
- [4] Paviour S, Musaad S, Roberts S, Taylor G, Taylor S, Shore K, et al. *Corynebacterium* species isolated from patients with mastitis. *Clin Infect Dis* 2002;35:1434–40.
- [5] Funke G, von Graevenitz A, Clarridge 3rd JE, Bernard KA. Clinical microbiology of coryneform bacteria. *Clin Microbiol* 1997;10:125–59.
- [6] Rongioletti F, Caputo V. Pancreatic panniculitis. *G Ital Dermatol Venereol* 2013;148:419–25.
- [7] Happel KI, Nelson S. Alcohol, immunosuppression and the lung. *Proc Am Thorac Soc* 2005;2(5):428–32.