


## Case report

# COVID-19-associated meningoencephalitis treated with intravenous immunoglobulin

Rayan S El-Zein ,<sup>1</sup> Serge Cardinali,<sup>1</sup> Christie Murphy,<sup>1</sup> Thomas Keeling<sup>2</sup>

<sup>1</sup>Department of Internal Medicine, OhioHealth Doctors Hospital, Columbus, OH, USA  
<sup>2</sup>Department of Infectious Disease, OhioHealth Doctors Hospital, Columbus, OH, USA

**Correspondence to**  
 Dr Christie Murphy;  
 cmazurk1@aol.com

Accepted 7 August 2020

## SUMMARY

A 40-year-old man presented with altered mental status after a recent hospitalisation for COVID-19 pneumonia. Cerebrospinal fluid (CSF) analysis showed lymphocytosis concerning for viral infection. The CSF PCR for SARS-CoV-2 was negative, yet this could not exclude COVID-19 meningoencephalitis. During hospitalisation, the patient's mentation deteriorated further requiring admission to the intensive care unit (ICU). Brain imaging and electroencephalogram (EEG) were unremarkable. He was, thus, treated with intravenous immunoglobulin (IVIg) for 5 days with clinical improvement back to baseline. This case illustrates the importance of considering COVID-19's impact on the central nervous system (CNS). Haematogenous, retrograde axonal transport, and the effects of cytokine storm are the main implicated mechanisms of CNS entry of SARS-CoV-2. While guidelines remain unclear, IVIg may be of potential benefit in the treatment of COVID-19-associated meningoencephalitis.

## BACKGROUND

A growing body of evidence is surfacing in regard to the neuroinvasiveness of COVID-19. Neurologic manifestations in patients infected with SARS-CoV-2 have been reported such as anosmia, ageusia, ataxia, seizures, haemorrhagic necrotising encephalopathy, and Guillain-Barré syndrome.<sup>1-3</sup> The neurotropism of COVID-19 remains undefined, although, previous coronaviruses have been implicated to involve the central nervous system (CNS).<sup>4</sup> Herein, we present a case of a patient with altered sensorium diagnosed with COVID-19-associated meningoencephalitis.

## CASE PRESENTATION

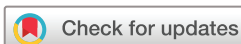A 40-year-old Hispanic man with no known medical history reported fevers, cough, and generalised fatigue in early April 2020 (day 1). On day 3, he presented to the emergency department and was confirmed to have COVID-19 via detection of SARS-CoV-2 viral nucleic acid in a nasopharyngeal swab specimen using the Simplexa SARS-CoV-2 assay (Diasorin Molecular LLC, Cypress, California, USA). He was subsequently hospitalised for 7 days for COVID-19-associated pneumonia. He completed a regimen of hydroxychloroquine (200 mg every 12 hours for 5 days). One day after discharge (day 7), he returns to the hospital with altered mental status. The patient's son reported that he was responding to questions

inappropriately, having visual hallucinations, and was forgetful. Neurological examination revealed confusion with orientation only to self, inability to follow commands, and no apparent focal neurological deficits. Otherwise, general examination was unremarkable and vital signs were within normal ranges (blood pressure 129/84 mm Hg, heart rate 104 bpm, SpO<sub>2</sub> 98% on room air and 98.5°F oral temperature).

## INVESTIGATIONS

After an unrevealing CT of the head, a lumbar puncture was performed. His cerebrospinal fluid (CSF) was clear and colourless with an elevated CSF cell count and lymphocytic predominance suspicious for viral encephalitis (table 1). The CSF glucose (70 mg/dL) was increased and CSF protein levels (19 mg/dL) were decreased. A CSF PCR panel including *Cryptococcus neoformans/gattii*, herpes simplex virus, varicella zoster virus, *Streptococcus pneumoniae*, *Neisseria meningitidis* and enterovirus was negative. The SARS-CoV-2 CSF PCR was negative; however, a high index of suspicion remained due to the temporal relationship of his current symptoms and the recent COVID-19 pneumonia. Due to the patient's lack of risk factors, testing for tuberculosis was not pursued, especially with the absence of an elevated CSF protein and decreased CSF glucose concentration. Also, mycoplasma studies were not performed. An empiric meningitis regimen (ceftriaxone, vancomycin, acyclovir and steroids) was initiated and he was admitted to the medical ward with the clinical diagnosis of encephalitis.

Blood analysis revealed an elevated ferritin (1127 ng/mL), lactate dehydrogenase (LDH) (295 U/L), and C reactive protein (10.6 mg/L). These are decreased in comparison with 2 days prior during his recent hospitalisation (ferritin 1225 ng/mL, LDH 355 U/L and CRP 58.2 mg/L). D-dimer was elevated at 1.42 µg/mL, which increased from 1.06 µg/mL. One day after admission (day 8), he was transferred to the intensive care unit (ICU) for progressively worsening mental status with increased agitation; a dexmedetomidine infusion was initiated. MRI of the brain did not reveal any significant alterations or contrast-enhanced areas within the brain and/or meninges (figure 1). A routine electroencephalogram (EEG) showed diffuse slowing in the theta range indicative of encephalopathy and lacked any epileptogenic activity. To this end, autoimmune encephalitis was less likely due to the absence of bilateral brain MRI



© BMJ Publishing Group Limited 2020. No commercial re-use. See rights and permissions. Published by BMJ.

**To cite:** El-Zein RS, Cardinali S, Murphy C, et al. *BMJ Case Rep* 2020;**13**:e237364. doi:10.1136/bcr-2020-237364

**Table 1** Cerebrospinal Fluid Analysis

CSF parametre	Result
Leucocyte count	0.044×10 <sup>9</sup> /L
Lymphocytes	85%
Neutrophils	1%
Glucose	70 mg/dL
Protein	19 mg/dL
Gram stain	Negative
Culture	Negative

findings in addition to lack of epileptogenic or focal slowing observed on EEG. The antimicrobial regimen was deescalated; the CSF Gram stain and culture were negative.

### TREATMENT

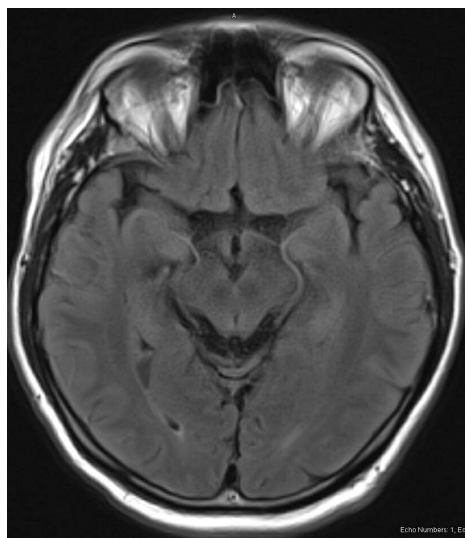
Two days after admission (day 9), he was started on intravenous immunoglobulin (IVIg) (0.4 g/kg) for 5 days. For concern of delay in viral clearance, glucocorticoids were avoided. Within the next 2 days, his altered mentation progressively improved; he was oriented to time and place, able to communicate, and was following commands. He could not recall recent events of the hospital admission. On the third day of treatment, the patient was back at his baseline. After completion of IVIg, at discharge, 7 days after admission (day 14), neurological examination was unremarkable.

### OUTCOME AND FOLLOW-UP

Two months after discharge, via a telephone follow-up encounter, the patient denied any symptoms. His son denied any further mental status changes.

### DISCUSSION

Our report describes a case of encephalitis associated with SARS-CoV-2 which showed clinical improvement with IVIg therapy. There are only a few cases previously reported on the neurologic involvement of COVID-19 with variable presentations, diagnostics and treatments. Moriguchi *et al*<sup>5</sup> described what appears to be the first case of COVID-19-associated meningoencephalitis presenting with convulsions and confirmed with a positive SARS-CoV-2 CSF PCR; their patient had abnormal



**Figure 1** Brain MRI demonstrating normal MRI findings on T2.

MRI findings of the medial temporal lobe and was treated with favipiravir. The patient remained in ICU at day 15 after onset of symptoms. Another report described a case of COVID-19-associated necrotising encephalopathy with multiple haemorrhagic rim enhancing lesions on MRI.<sup>2</sup> They used IVIg as the mainstay therapy but the outcome remained undefined. Paniz-Mondolfi *et al*<sup>6</sup> reported a case of COVID-19-associated pneumonia in a 74 years old with Parkinson's who succumbed to his illness on day 11; however, SARS-CoV-2 was found in the brain capillary endothelium and neuronal cell bodies on postmortem examination.

Large studies pertaining to the incidence, diagnostics, and therapeutics of COVID-19 neurologic manifestations remain lacking. A recent retrospective study showed that approximately 55 (25%) of 214 patients with COVID-19 had manifestations of CNS involvement with dizziness and headache being the most common.<sup>1</sup> CSF analysis was not performed in this cohort. In another retrospective study by Li *et al*, the incidence of cerebrovascular events in patients with COVID-19 was about 5% with a median time of stroke after COVID-19 diagnosis of 12 days.<sup>1</sup> As previously reported,<sup>7</sup> a subset of patients with COVID-19 could have neurologic signs and symptoms without the typical respiratory symptoms. As more reports emerge, there is a newfound interest in elucidating the mechanisms of SARS-CoV-2 neurotropism.

Lessons from the taxonomically related SARS-CoV<sup>8</sup> in the past have supported haematogenous spread and retrograde neuronal transport as the proposed routes of SARS-CoV-2 neuroinvasion. SARS-CoV-2, through its interaction with ACE2, could enter the CNS given that ACE2 is expressed in the vascular endothelium, neurons, and glial cells of the brain.<sup>9</sup> Under electron microscopy, SARS-CoV-2 viral particles have been shown to be actively budding across endothelial cells of frontal lobe brain sections.<sup>6</sup> The cytokine storm associated with COVID-19 may alter the permeability of the blood-brain barrier, thus further allowing entry. Retrograde propagation along the olfactory tract has been shown to occur by SARS-CoV, and thus may explain the anosmia associated with SARS-CoV-2.<sup>10</sup> Once within the CNS, viral-induced cytokine storm and glial cell activation may result in immunologic response and inflammatory injury leading to encephalitis in our patient. Although the CSF PCR was negative, this could not definitely exclude the diagnosis because SARS-CoV-2 dissemination is transient and its CSF titre may be extremely low, as shown in cases of West Nile and enterovirus infections.<sup>11 12</sup>

Our successful use of IVIg corroborates reporting of its possible benefit in COVID-19<sup>13 14</sup>; no specific guidelines regarding its use are released as of yet. Considering the aforementioned inflammatory state undermining COVID-19, IVIg's proposed mechanism consists of the inhibition of innate immune cells, neutralization of activated complement, modulation of B cells and regulatory T cells, and the inhibition of cytokines.<sup>15</sup>

### Learning points

- ▶ COVID-19 may involve the central nervous system irrespective of pulmonary involvement.
- ▶ The cerebrospinal fluid PCR for SARS-CoV-2 cannot be used definitively to exclude COVID-19-associated meningoencephalitis.
- ▶ Intravenous immunoglobulin may be of potential benefit in COVID-19-associated meningoencephalitis.

Caution must be taken with its increased risk of thromboembolism especially given the reports of COVID-19 hypercoagulability. Currently, several randomised controlled trials evaluating the efficacy of high-dose IVIg therapy in severe COVID-19 have been initiated (NCT04350580, NCT04381858 and NCT04261426).

**Twitter** Rayan S El-Zein @Rayan\_ElZein

**Acknowledgements** The authors would like to acknowledge members of the team who cared for the patient including neurologist, Dr Shnehal Patel; intensivists, Dr Lucia Chowdhury and Dr Harvinder Gill and hospitalist, Dr Sudhir Duvuru.

**Contributors** RSE, SC and TK participated in the care of the patient. Report was written by RSE, SC and CM.

**Funding** The authors have not declared a specific grant for this research from any funding agency in the public, commercial or not-for-profit sectors.

**Competing interests** None declared.

**Patient consent for publication** Obtained.

**Provenance and peer review** Not commissioned; externally peer reviewed.

This article is made freely available for use in accordance with BMJ's website terms and conditions for the duration of the covid-19 pandemic or until otherwise determined by BMJ. You may use, download and print the article for any lawful, non-commercial purpose (including text and data mining) provided that all copyright notices and trade marks are retained.

#### ORCID iD

Rayan S El-Zein <http://orcid.org/0000-0002-1437-7082>

#### REFERENCES

- Li Y, Li M, Wang M, *et al.* Acute cerebrovascular disease following COVID-19: a single center, retrospective, observational study. *Stroke Vasc Neurol* 2020. doi:10.1136/svn-2020-000431. [Epub ahead of print: 02 Jul 2020].
- Poyiadji N, Shahin G, Noujaim D, *et al.* COVID-19-associated acute hemorrhagic necrotizing encephalopathy: imaging features. *Radiology* 2020;296:E119–20.
- Zhao H, Shen D, Zhou H, *et al.* Guillain-Barré syndrome associated with SARS-CoV-2 infection: causality or coincidence? *Lancet Neurol* 2020;19:383–4.
- Desforges M, Le Coupanec A, Dubeau P, *et al.* Human coronaviruses and other respiratory viruses: underestimated opportunistic pathogens of the central nervous system? *Viruses* 2019;12. doi:10.3390/v12010014
- Moriguchi T, Harii N, Goto J, *et al.* A first case of meningitis/encephalitis associated with SARS-Coronavirus-2. *Int J Infect Dis* 2020;94:55–8.
- Paniz-Mondolfi A, Bryce C, Grimes Z, *et al.* Central nervous system involvement by severe acute respiratory syndrome coronavirus -2 (SARS-CoV-2). *J Med Virol* 2020.
- Wang H-Y, Li X-L, Yan Z-R, *et al.* Potential neurological symptoms of COVID-19. *Ther Adv Neurol Disord* 2020;13:175628642091783.
- Zhang Q-ling, Ding Y-qing, Hou J-lin, *et al.* [Detection of severe acute respiratory syndrome (SARS)-associated coronavirus RNA in autopsy tissues with in situ hybridization]. *Di Yi Jun Yi Da Xue Xue Bao* 2003;23:1125–7.
- Xia H, Lazartigues E. Angiotensin-Converting enzyme 2 in the brain: properties and future directions. *J Neurochem* 2008;107:1482–94.
- Netland J, Meyerholz DK, Moore S, *et al.* Severe acute respiratory syndrome coronavirus infection causes neuronal death in the absence of encephalitis in mice transgenic for human ACE2. *J Virol* 2008;82:7264–75.
- Ye M, Ren Y, Lv T. Encephalitis as a clinical manifestation of COVID-19. *Brain Behav Immun* 2020.
- Venkatesan A, Tunkel AR, Bloch KC, *et al.* Case definitions, diagnostic algorithms, and priorities in encephalitis: consensus statement of the International encephalitis Consortium. *Clin Infect Dis* 2013;57:1114–28.
- Xie Y, Cao S, Dong H, *et al.* Effect of regular intravenous immunoglobulin therapy on prognosis of severe pneumonia in patients with COVID-19. *J Infect* 2020;81:318–56.
- Cao W, Liu X, Bai T, *et al.* High-Dose intravenous immunoglobulin as a therapeutic option for deteriorating patients with coronavirus disease 2019. *Open Forum Infect Dis* 2020;7:ofaa102.
- Rizk JG, Kalantar-Zadeh K, Mehra MR, *et al.* Pharmacologic-immunomodulatory therapy in COVID-19. *Drugs* 2020. doi:10.1007/s40265-020-01367-z. [Epub ahead of print: 21 Jul 2020].

Copyright 2020 BMJ Publishing Group. All rights reserved. For permission to reuse any of this content visit <https://www.bmj.com/company/products-services/rights-and-licensing/permissions/>  
BMJ Case Report Fellows may re-use this article for personal use and teaching without any further permission.

Become a Fellow of BMJ Case Reports today and you can:

- Submit as many cases as you like
- Enjoy fast sympathetic peer review and rapid publication of accepted articles
- Access all the published articles
- Re-use any of the published material for personal use and teaching without further permission

#### Customer Service

If you have any further queries about your subscription, please contact our customer services team on +44 (0) 207111 1105 or via email at [support@bmj.com](mailto:support@bmj.com).

Visit [casereports.bmj.com](http://casereports.bmj.com) for more articles like this and to become a Fellow