



Extensive Inferior Vena Cava Thrombosis Related to COVID-19 Infection in a Patient with Retrievable Filter Due to Multiple Pelvic Bone Fractures

George S. Georgiadis¹, Christos Argyriou¹, Stylianos Tottas², Soultana Foutzitzi³, and Georgios Drosos²

Departments of ¹Vascular Surgery and ²Orthopaedic Surgery, Democritus University of Thrace, University General Hospital of Alexandroupolis, Alexandroupolis, ³Department of Radiology, University General Hospital of Alexandroupolis, Alexandroupolis, Greece

Inferior vena cava (IVC) thrombosis is often attributed to IVC filters. Here, we describe the first case of IVC filter thrombosis associated with severe acute respiratory syndrome coronavirus-2 infection in a 34-year-old male with multiple pelvic fractures. The IVC filter was initially placed prophylactically prior to major orthopedic trauma reconstruction complicated by silent pulmonary embolism, precluding the safe transition to therapeutic anticoagulation due to the high hemorrhagic risk from pelvic fracture fixation. This case highlights the potentially increased risk of severe complications in patients receiving vascular care if they were to contract coronavirus disease-2019 (COVID-19) in the hospital. IVC filter placement in the patient resulted in complete IVC thrombosis after he acquired COVID-19 infection. Prophylactic doses of low molecular weight heparin could not prevent this complication. However, prompt initiation of therapeutic anticoagulation with rivaroxaban led to the complete resolution of IVC thrombosis over weeks after viral negativization and discharge.

Key Words: COVID-19, Inferior vena cava, Vena cava filters, Venous thrombosis, Pelvic bones

Received October 14, 2021
Revised December 20, 2021
Accepted February 24, 2022
Published on March 24, 2022

Corresponding author: George S. Georgiadis

Department of Vascular Surgery,
Democritus University of Thrace,
University General Hospital of
Alexandroupolis, Alexandrou
Papanastasiou 7 Street, Alexandroupolis
68100, Greece
Tel: 30-2551037171
Fax: 30-2551353124
E-mail: ggeorgia@med.duth.gr
<https://orcid.org/0000-0003-1274-3445>

Copyright © 2022 The Korean Society for Vascular Surgery

This is an Open Access article distributed under the terms of the Creative Commons Attribution Non-Commercial License (<http://creativecommons.org/licenses/by-nc/4.0>) which permits unrestricted non-commercial use, distribution, and reproduction in any medium, provided the original work is properly cited.

Cite this article; Vasc Specialist Int 2022. <https://doi.org/10.5758/vsi.210070>

INTRODUCTION

Venous thromboembolism (VTE) is a common and potentially lethal sequelae occurring in patients after trauma. The incidence of deep vein thrombosis (DVT) and pulmonary embolism (PE) in high-risk trauma patients is 11.8% and 1.5%, respectively. Current guidelines recommend that inferior vena cava filters (IVCFs) should be considered in patients with acute PE and absolute contraindications to anticoagulation [1], as such in emergent procedures with a high risk for bleeding, or when anticoagulation for VTE is discontinued due to major bleeding. Interestingly, recent meta-analytical evidence is insufficient to prove that IVCFs

can reduce PE-related and overall mortality. However, their use decreases the occurrence of PE without increasing DVT or major bleeding [2]. IVC filtration is associated with several complications. Complete IVC or filter thrombosis, although rare, is a potentially lethal disease with serious morbidity, even with prompt diagnosis and early medical treatment [3]. Furthermore, in specific situations, such as coronavirus disease 2019 (COVID-19) infection during the postoperative course of a major trauma, this might be a more challenging situation. COVID-19 is associated with an increased risk of VTE. Notably, patients with severe acute respiratory syndrome coronavirus-2 (SARS-CoV-2) infection exhibit an unexpectedly high incidence of DVT at multiple

sites, whereas thromboprophylaxis does not adequately prevent these events in virus-positive patients [4]. Thus, the reported rates of IVCF-related thrombosis, ranging from 2.2% to 4.1% [5], may be higher in the COVID-19 population.

To the best of our knowledge, this is the first report of a COVID-19 patient presenting with symptomatic iliofemoral and IVCF thrombosis. We describe the case of a young male with IVCF thrombosis due to hospital-acquired COVID-19 infection. The IVCF was initially placed prior to major orthopedic reconstruction due to multi-trauma complicated by silent PE, precluding safe transition to therapeutic anticoagulation due to the high hemorrhagic risk of pelvic fracture fixation. Thus, a retrievable IVCF was used early to prevent recurrent PE. The patient consented to the publication of the case details and images. Institutional review board approval was waived owing to the retrospective nature of the case report.

CASE

A 34-year-old male involved in a motorcycle accident was transferred to our tertiary hospital. On presentation, the patient was alert and hemodynamically stable. Clinical assessment revealed marked tenderness over the lumbar spine, as well as pain and discomfort coupled with widespread ecchymoses over the pelvic area. Radiographic evaluation showed multiple fractures in the acetabula bilaterally and left ilium (Fig. 1A). Computed tomography (CT) of the abdomen and pelvis revealed a sizable retroperitoneal hematoma in the lesser pelvis, possibly attributed to presacral venous bleeding (Fig. 1B). No other injuries were detected, apart from dysesthesia with femoral nerve distribution and weakness of the right quadriceps muscle.

On the second hospital day, his clinical condition worsened due to sudden onset of chest pain and dyspnea. Initial urgent labs were notable for D-dimer level of 1,327 ng/mL, platelet count of 199 K/mm³, fibrinogen level of 470 mg/dL, and lactate dehydrogenase of 206 U/L, while a thoracic

CT scan revealed the presence of bilateral lower lobe PEs (Fig. 2). Venous phase CT revealed acute non-occlusive thrombosis of the right common and external iliac veins (Fig. 3). Considering that the patient was scheduled to undergo operative stabilization of the pelvic fractures, the multi-disciplinary team decided to provide a prophylactic dose of low molecular weight heparin (tinzaparin anti-Xa 4,500 IU daily) and inserted an IVCF to minimize the risk of a relapsing or worsening PE episode while minimizing the risk of ongoing bleeding or expanding hematoma of the lesser pelvis and of the upcoming orthopedic reconstruction. A 28-mm diameter Denali IVCF (Bard Peripheral Vascular Inc., Tempe, AZ, USA) was placed percutaneously using the right femoral approach. Prior to IVC filtration, an on-table diagnostic venogram revealed no active extravasation. The procedure was performed in the operating room using a portable C-arm image (Philips Medical Systems, Amsterdam, Netherlands).

On the third hospital day, orthopedic surgery was per-

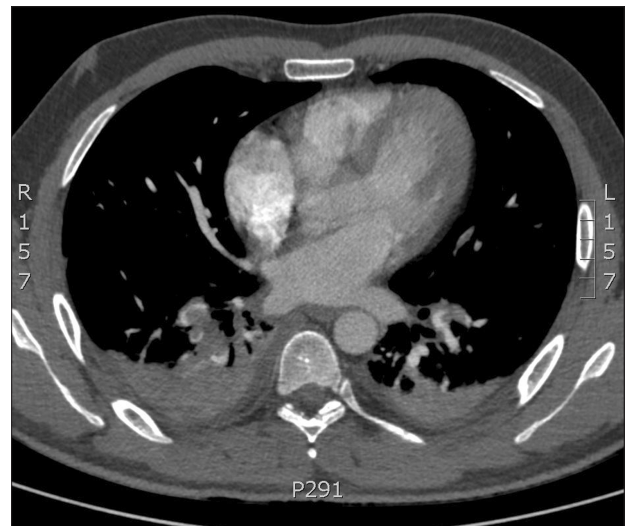

Fig. 2. Thoracic computed tomography scan revealed pulmonary embolism in bilateral lower lobes.

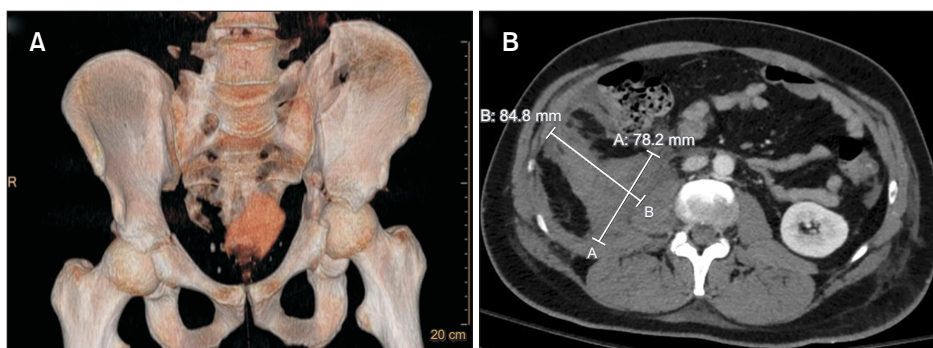


Fig. 1. (A) Computed tomography (CT) showed multiple pelvic fractures. (B) CT depicted a sizable retroperitoneal hematoma in the lesser pelvis.

formed through an extended posterior approach (Kocher-Langenbeck) of the left hip. Two 3.5-mm reconstruction plates were applied to the posterior wall and posterior column. Additionally, through the lateral window of the ilioinguinal approach, a dynamic compression plate was applied to fix the ilium fracture. After 2 days in the intensive care unit, the patient was transferred to the orthopedic department with bilateral leg retractions and systematic physiotherapeutic protocols. The same prophylactic anticoagulant dose was administered perioperatively. On postoperative day 5, his temperature was 38.1°C. As no etiologic factor was found for this and considering the current COVID-19 pandemic, a COVID-19 reverse transcription polymerase

chain reaction test was performed but showed negative results twice. On postoperative day 20, the patient again presented with a low-spike fever, tested positive for COVID-19, and was subsequently transferred to the infectious disease department for isolation and close monitoring. Fortunately, the patient did not develop respiratory symptoms and was treated with mild oxygen supplementation and respiratory physiotherapy. Moderate elevation of C-reactive protein levels up to 154 mg/L was observed.

On postoperative day 30, the patient returned to the orthopedic department after testing negative for COVID-19 twice. However, the next day, he complained of gradual-

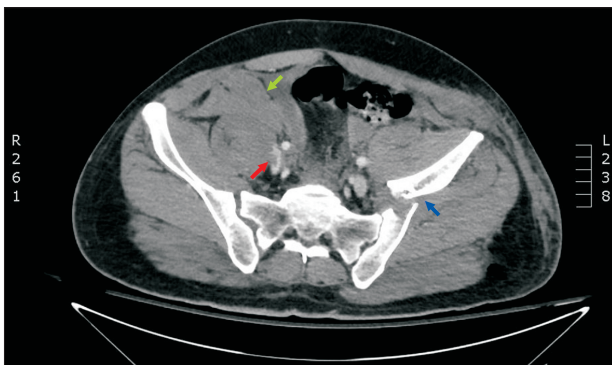


Fig. 3. Computed tomography axial image showed thrombosis of the right common iliac vein (red arrow), hematoma in the right pelvic fossa (green arrow), and left pelvic bone fracture (blue arrow).

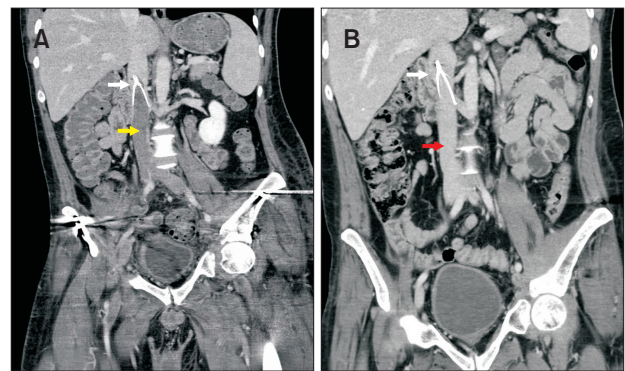


Fig. 5. (A) Computed tomography (CT) coronal image showed inferior vena cava (IVC) filter (white arrow) and IVC thrombosis (yellow arrow). (B) Follow-up CT image showed completely resolved IVC thrombosis (red arrow) and IVC filter (white arrow).

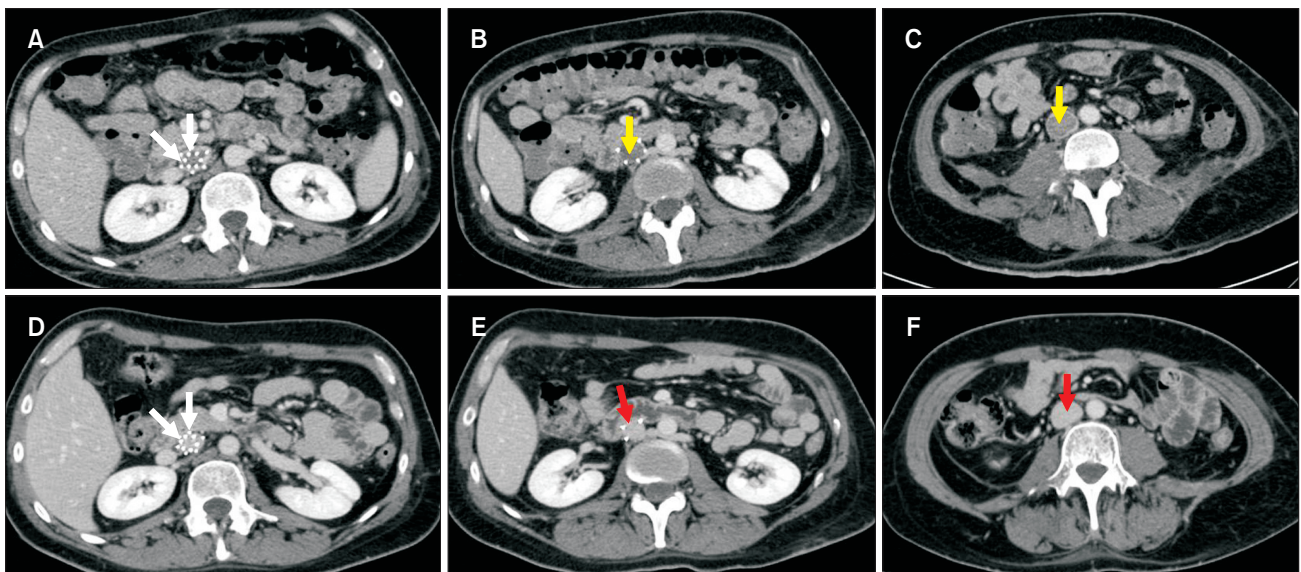


Fig. 4. (A-C) Computed tomography (CT) axial images taken in November 2020 showed inferior vena cava (IVC) filter (white arrows) and IVC thrombosis (yellow arrows). (D-F) CT images performed in January 2021 showed completely resolved IVC thrombosis (red arrows) and IVC filter (white arrow).

onset pain and swelling in both legs but did not approach phlegmasia. Homan signs were positive, and D-dimer levels increased to 4,759 ng/mL. Duplex ultrasonography revealed a hyperechoic intraluminal thrombus in the IVC, and CT revealed a fresh infrarenal IVC thrombus (Fig. 4, 5), as well as thrombosis of the bilateral iliofemoral and popliteal veins. The patient immediately initiated a therapeutic anticoagulation regimen with oral anticoagulants (rivaroxaban 20 mg once daily), remained bedridden, and had improved clinical status for the following 10 days when he was discharged from the hospital under the same anticoagulant dose. Surprisingly, follow-up CT scans at 2 and 6 months postoperatively showed complete resolution of the entire IVC thrombus up to the filter (Fig. 4, 5).

DISCUSSION

The sole purpose of IVCF is to prevent PE, thereby reducing PE-associated morbidity and mortality. Only patients with active lower-extremity DVT who cannot receive anticoagulation therapy might benefit from IVCF placement [1,6]. In our patient with documented proximal DVT and PE prior to urgent orthopedic fixation for pelvic fractures with a high hemorrhagic risk prohibiting therapeutic anticoagulation, the risk of recurrent PE would be high, possibly symptomatic during the initial 2 weeks. Therefore, we decided to perform temporary IVCF placement and prophylactic anticoagulation, mainly to reduce PE recurrence and death, but also to lower bleeding risk following pelvic fractures and orthopedic fixation.

Complications associated with IVCFs are common, and sometimes severe. Although rare, filter-related IVC thrombosis is a potentially lethal disease with serious morbidity, despite prompt diagnosis and early treatment.

Growing evidence suggests that thromboembolic complications may represent an integral part of the clinical features of SARS-CoV-2 infection and are already present at the time of the initial hospital admission [7]. Additionally, intensive care unit and floor patients are at a high risk of VTE and subsequent mortality [8]. Rashidi et al. [9] reported a 45-day cumulative rate of symptomatic VTE of 0.2% among recently hospitalized COVID-19 patients. COVID-19 patients may exhibit coagulation cascade activation upon presentation, as shown by elevated D-dimer levels, which are associated with a poor clinical course and greater risk of in-hospital mortality. High D-dimer levels upon admission have been correlated with an increased probability of DVT [10], while cut-off points of 2,450 ng/mL and 6,494 ng/mL had specificity and negative predictive values approaching 60% [10] and 88% [11], respectively. In this case, an increased D-dimer level of 4,759 ng/mL was observed

on postoperative day 31 when the patient was already COVID-19 infected.

In our case, despite thromboprophylaxis with low molecular-weight heparins (LMWHs), we failed to manage the coagulopathy and prevent IVC thrombosis. An explanation would be that the virus directly or indirectly interfered with coagulation pathways, causing a hyper-inflammatory state and endothelial dysfunction that were more prominent at the level of the IVCF. We can assume that concomitant factors, such as major trauma, pelvic surgery, and immobilization would increase the risk of VTE events in patients with COVID-19, as in our case.

The precise pathophysiology of IVCF thrombosis cannot be documented solely on the clinical basis. The IVCF can act as a foreign body, leading to the activation of the coagulation cascade. We cannot rule out that IVC thrombosis is the result of de novo filter thrombosis or entrapped emboli-induced thrombosis. The latter mechanism is the reason for IVCF prevention in PE and more catastrophic complications.

More importantly, the complete resolution of IVC thrombosis after SARS-CoV-2 negativization correlated with the regression of leg edema, suggesting the pivotal role of COVID-19 infection as a contributing factor for IVC thrombosis and the severity of clinical symptoms.

A recent, but pre-COVID-19 pandemic, multicenter trial did not find that early IVCF placement in trauma patients who had contraindication to anticoagulation led to a lower incidence of symptomatic PE or death than the absence of a filter [12]. Other studies have also reported the failure of prophylactic IVCFs to reduce mortality in trauma patients [13]. Clarifying the necessity of IVCFs in these patients will help establish the criteria for IVCF implantation in patients with COVID-19, eventually decreasing PE-related mortality. Notably, IVCFs have not been associated with an increased risk of DVT in many studies [12]. Furthermore, caval thrombosis is also rare, with a recent systematic review reporting a 2.8% frequency of caval thrombosis or stenosis in patients receiving a retrievable IVCF [14].

Slobogean et al. [15] reported that for VTE prevention in patients with pelvic and acetabular fractures, early administration of LMWH was the only intervention that demonstrated a clear reduction. Although there is some evidence suggesting that patients with an IVCF who remain on anticoagulation have lower rates of recurrent VTE and are less likely to form a thrombus within the filter, and despite the fact that we inserted the filter in the correct place and continued with prophylactic anticoagulation dose to counterbalance the risks of DVT and bleeding, IVC thrombosis eventually occurred in the infective period of COVID-19.

As mentioned above, the underlying SARS-CoV-2 infec-

tion and reduced rate of anticoagulation (low prophylactic LMWH dose) with filter placement may have contributed to this event. However, despite few cases observed, the cases of acute PE in 370 SARS-CoV-2 positive patients requiring hospitalization after complete recovery from acute COVID-19 within four weeks from viral negativization [16] forced our team to suggest therapeutic anticoagulation for more than 3 months.

However, the use of catheter-based techniques for iliofemoral DVT remains controversial. The highest-quality evidence from randomized controlled trials suggests that catheter-directed thrombolysis (CDT) may decrease the severity of post-thrombotic syndrome (PTS) and improve quality of life, although it failed to decrease the incidence of PTS. Consequently, the decision to perform CDT should be based on clinical judgment. In the case of relative contraindications for anticoagulation 4 weeks after trauma, we did not consider CDT or pharmacomechanical thrombectomy since oral anticoagulation was the main therapeutic strategy. Despite the recent major trauma precluding the use of advanced endovascular therapies, the fate of these dedicated and risky procedures has not been well studied within the course of SARS-CoV-2 infection. Furthermore, filter-related IVC thrombosis rarely causes complete venous wall occlusion. It has been shown that chronic venous occlusions usually recanalize [17].

In the COVID-19 Vascular Service study cohort [18], in-hospital mortality after vascular interventions was considerably higher than that in pre-pandemic reports from the national registry data. Predicting the exact duration of VTE and death risk can be difficult in our patient. For this reason, a new CT angiography was performed focusing on the venous phase. Although no thrombus burden was detected, the efficacy and safety of continuing thromboprophylaxis in ambulatory patients with previous COVID-19 infection, including IVCF placement in the setting of ineligibility to be anticoagulated due to trauma, could not be determined.

Regarding filter retrieval, FDA guidelines recommend removal of the retrievable IVCs within 29 to 54 days of implantation or as soon as the transient risk of PE resolves [19]. Although filter retrieval has a 97.3% success rate for Bard Denali filters [20], as in our case, the filter has not yet been removed. In fact, there is a management plan to remove the filter, which also depends on the patient's acceptance of a risky procedure. However, in cases in which retrieval is

not an option, either for being too risky or because of an attempted failure, consideration for permanent IVCF placement should be assessed and discussed between the clinician and the patient.

In conclusion, little is known about the outcomes of patients undergoing orthopedic surgery for major trauma and COVID-19 infection. In this setting, patients are at increased risk of thrombosis and serious surgical complications. Prophylactic IVC placement for patients with proximal DVT and PE during trauma care with contraindication for therapeutic anticoagulation can be complicated by acquired COVID-19 infection and subsequent thrombosis. Therefore, prompt diagnosis and early initiation of anticoagulation therapy are important.

FUNDING

None.

CONFLICTS OF INTEREST

The authors have nothing to disclose.

ORCID

George S. Georgiadis

<https://orcid.org/0000-0003-1274-3445>

Christos Argyriou

<https://orcid.org/0000-0003-3296-2303>

Stylianos Tottas

<https://orcid.org/0000-0003-1731-1668>

Soultana Foutzitz

<https://orcid.org/0000-0001-5090-6917>

Georgios Drosos

<https://orcid.org/0000-0003-4296-1750>

AUTHOR CONTRIBUTIONS

Concept and design: GSG, CA. Analysis and interpretation: GSG, CA, ST, SF. Data collection: all authors. Writing the article: GSG, CA. Critical revision of the article: GSG, CA, GD. Final approval of the article: all authors. Statistical analysis: none. Obtained funding: none. Overall responsibility: GSG.

REFERENCES

- 1) Konstantinides SV, Meyer G, Becattini C, Bueno H, Geersing GJ, Harjola VP, et al. 2019 ESC Guidelines for the

- diagnosis and management of acute pulmonary embolism developed in collaboration with the European Respiratory Society (ERS). *Eur Heart J* 2020;41:543-603.
- 2) Liu Y, Lu H, Bai H, Liu Q, Chen R. Effect of inferior vena cava filters on pulmonary embolism-related mortality and major complications: a systematic review and meta-analysis of randomized controlled trials. *J Vasc Surg Venous Lymphat Disord* 2021;9:792-800.e2.
 - 3) Min SK, Kim YH, Joh JH, Kang JM, Park UJ, Kim HK, et al. Diagnosis and treatment of lower extremity deep vein thrombosis: Korean practice guidelines. *Vasc Specialist Int* 2016;32:77-104.
 - 4) Avruscio G, Camporese G, Campello E, Bernardi E, Persona P, Passarella C, et al. COVID-19 and venous thromboembolism in intensive care or medical ward. *Clin Transl Sci* 2020;13:1108-1114.
 - 5) Lin L, Hom KC, Hohenwarter EJ, White SB, Schmid RK, Rilling WS. VenaTech convertible vena cava filter 6 months after conversion follow-up. *J Vasc Interv Radiol* 2020;31:1419-1425.
 - 6) Kakkos SK, Gohel M, Baekgaard N, Bauersachs R, Bellmunt-Montoya S, Black SA, et al. Editor's choice - European Society for Vascular Surgery (ESVS) 2021 clinical practice guidelines on the management of venous thrombosis. *Eur J Vasc Endovasc Surg* 2021;61:9-82.
 - 7) Lodigiani C, Iapichino G, Carenzo L, Cecconi M, Ferrazzi P, Sebastian T, et al. Venous and arterial thromboembolic complications in COVID-19 patients admitted to an academic hospital in Milan, Italy. *Thromb Res* 2020;191:9-14.
 - 8) Rali P, O'Corragain O, Oresanya L, Yu D, Sheriff O, Weiss R, et al. Incidence of venous thromboembolism in coronavirus disease 2019: an experience from a single large academic center. *J Vasc Surg Venous Lymphat Disord* 2021;9:585-591.e2.
 - 9) Rashidi F, Barco S, Kamangar F, Heresi GA, Emadi A, Kaymaz C, et al. Incidence of symptomatic venous thromboembolism following hospitalization for coronavirus disease 2019: prospective results from a multi-center study. *Thromb Res* 2021;198:135-138.
 - 10) Motaganahalli RL, Kapoor R, Timsina LR, Gutwein AR, Ingram MD, Raman S, et al. Clinical and laboratory characteristics of patients with novel coronavirus disease-2019 infection and deep venous thrombosis. *J Vasc Surg Venous Lymphat Disord* 2021;9:605-614.e2.
 - 11) Cho ES, McClelland PH, Cheng O, Kim Y, Hu J, Zenilman ME, et al. Utility of d-dimer for diagnosis of deep vein thrombosis in coronavirus disease-19 infection. *J Vasc Surg Venous Lymphat Disord* 2021;9:47-53.
 - 12) Ho KM, Rao S, Honeybul S, Zellweger R, Wibrow B, Lipman J, et al. A multi-center trial of vena cava filters in severely injured patients. *N Engl J Med* 2019;381:328-337.
 - 13) Hemmila MR, Osborne NH, Henke PK, Kepros JP, Patel SG, Cain-Nielsen AH, et al. Prophylactic inferior vena cava filter placement does not result in a survival benefit for trauma patients. *Ann Surg* 2015;262:577-585.
 - 14) Angel LF, Tapson V, Galgon RE, Restrepo MI, Kaufman J. Systematic review of the use of retrievable inferior vena cava filters. *J Vasc Interv Radiol* 2011;22:1522-1530.e3.
 - 15) Slobogean GP, Lefaivre KA, Nicolaou S, O'Brien PJ. A systematic review of thromboprophylaxis for pelvic and acetabular fractures. *J Orthop Trauma* 2009;23:379-384.
 - 16) Vlachou M, Drebes A, Candilio L, Weeraman D, Mir N, Murch N, et al. Pulmonary thrombosis in COVID-19: before, during and after hospital admission. *J Thromb Thrombolysis* 2021;51:978-984.
 - 17) Poon WL, Luk SH, Yam KY, Lee AC. Mechanical thrombectomy in inferior vena cava thrombosis after caval filter placement: a report of three cases. *Cardiovasc Intervent Radiol* 2002;25:440-443.
 - 18) Benson RA, Nandhra S; The Vascular and Endovascular Research Network (VERN) COVID-19 Vascular Service (COVER) Tier 2 Study. Outcomes of vascular and endovascular interventions performed during the coronavirus disease 2019 (COVID-19) pandemic. *Ann Surg* 2021;273:630-635.
 - 19) Guez D, Hansberry DR, Eschelmann DJ, Gonsalves CF, Parker L, Rao VM, et al. Inferior vena cava filter placement and retrieval rates among radiologists and nonradiologists. *J Vasc Interv Radiol* 2018;29:482-485.
 - 20) Stavropoulos SW, Sing RF, Elmasri F, Silver MJ, Powell A, Lynch FC, et al. The DENALI Trial: an interim analysis of a prospective, multicenter study of the Denali retrievable inferior vena cava filter. *J Vasc Interv Radiol* 2014;25:1497-1505, 1505.e1.