

Asymmetric hearing loss and chronic dizziness in a patient with idiopathic normal pressure hydrocephalus

Theodoros Varakliotis,¹ Federico Maspes,² Vittoria Di Rubbo,¹ Sara Cisternino,¹ Maria Lauriello,¹ Elisa Vitti,¹ Alberto Eibenstein^{1,2}

¹Department of Applied Clinical Sciences and Biotechnology, L'Aquila University, L'Aquila;

²Tinnitus Center European Hospital, Rome, Italy

Abstract

We report a case of a 54-year old female patient, complaining for chronic dizziness, hearing loss, tension headaches without aura, postural instability and gait dysfunction. The patient referred having these symptoms from 1992, but the last few months she experienced a noticeable aggravation of the symptoms. A magnetic resonance imaging test revealed a triventricular hydrocephalus, not associated with signs of intracranial hypertension decompensation. The ENT-Audiology evaluation revealed a bilateral sensorineural hearing loss with a conductive component, video-nystagmography resulted in an areflexia of the right ear and a reduced vestibular activity for the left ear. Auditory brainstem response test was also carried out and showed pathologic findings for the latencies of the waves I-III, III-V and I-V bilaterally but more significant in the right ear. On January 2016 the patient had endoscopic third ventriculostomy. On the follow up the patient referred an important subjective improvement regarding instability and gait dysfunction. In this paper we study the correlation between hydrocephalus, hearing loss and vestibular dysfunction.

Introduction

Hydrocephalus is a medical condition caused by the excessive accumulation of cerebrospinal fluid (CSF), which results from an imbalance between CSF production and absorption. It is classified as communicating or non-communicating. In the first case, there is a normal communication between the ventricular system and the subarachnoid space, but the CSF is not fully absorbed. In the second case, there is an obstruction in the ventricles, which prevents the normal flow of CSF in the subarachnoid space, which results in a dilatation of the ventricular system.¹

Idiopathic normal pressure hydrocephalus (INPH) consists of communicating hydrocephalus, with pressure in the CSF within the normal range (7-24 cm H₂O).^{2,3} It was first described by Hakim and Adams⁴ as a syndrome that consisted of the triad of gait apraxia dysfunction, dementia, and urinary incontinence, associated with ventricular dilation. The three symptoms are present in approximately 50% of the cases and the presence of two symptoms, investigations and differential diagnosis should be considered. Elderly population is more often affected, with an incidence approximately 6 per 100,000 and the prevalence 22 per 100,000.^{5,6} There is a correlation between INPH and hypertension, cerebrovascular diseases and Alzheimer Disease.^{7,8} The surgical treatment, which consists of the ventriculo-peritoneal shunt (VPS) and endoscopic third ventriculostomy (ETV),^{9,10} can improve the symptoms of INPH. However, both of them have disadvantages, such as necessity for reoperation, infections, overdrainage and perioperative mortality rates.¹¹⁻¹³

Correspondence: Theodoros Varakliotis, Department of Applied Clinical Sciences and Biotechnology (DISCAB), L'Aquila University, L'Aquila, Italy.

E-mail: theo_va@hotmail.com

Key words: Normal pressure hydrocephalus; hearing loss; chronic dizziness; gait dysfunction; headache.

Conflict of interest: the authors declare no conflict of interest.

Received for publication: 1 November 2017.

Revision received: 6 December 2017.

Accepted for publication: 16 December 2017.

This work is licensed under a Creative Commons Attribution NonCommercial 4.0 License (CC BY-NC 4.0).

©Copyright T. Varakliotis et al., 2018

Licensee PAGEPress, Italy

Audiology Research 2018;8:200

doi:10.4081/audiore.2018.200

Case Report

A female patient, 54 years old, came to our attention on April 2015 complaining for chronic dizziness, hearing loss, tension headaches without aura, postural instability and gait dysfunction. The patient referred having these symptoms from 1992, but the last few months she experienced a noticeable aggravation of the symptoms. The clinical tests, performed 23 years ago, revealed a mild bilateral sensorineural hearing loss, more noticeable on the right ear. Tympanometry and stapedial reflexes were normal, also auditory brainstem response (ABR) audiometry showed no abnormal findings. The CT scan, which was performed to study the middle ear structures, did not show morphological or structural anomalies, and normal central nervous system findings. Routine blood tests were normal. The patient never experienced typical vertigo crisis with tinnitus and fluctuating hearing loss, which would indicate Ménière's disease, but an aspecific chronic dizzi-

ness and assymetric hearing loss more prominent for the right ear, possibly of hydroptic type.

On April 2015, after ENT evaluation for vestibular deficit and hearing loss, it was prescribed an MRI test (Figure 1), which revealed a triventricular hydrocephalus, not associated with signs of intracranial hypertension decompensation. It was present a wide reduction of CSF spaces with no signs of trans-ependymal absorption as well as the absence of obstructive lesions responsible for impedance to the flow of CSF. Important reduction of the caliber of the aqueduct of Silvio was observed, likely to be on a congenital base. Finally, brainstem and cerebellopontine angle were free of pathological findings. As anatomical variant, we noted the high position of the right jugular bulb, without any clinical significance. Arnold-Chiari malformation or superior semicircular canal dehiscence syndrome were excluded by the neuroradiologist. On May 2015, the patient had an ENT-Audiology evaluation. The audiometry test (Figure 2A) revealed a bilateral sensorineural hearing loss, (middle level on the left ear and severe level on the right ear). Tympanometry was normal on both ears (type A), but the stapedial reflexes study demonstrated abnormalities, particularly the absence of the reflexes on the right ear, either ipsilateral and contralateral, the absence of contralateral reflex on the left ear, with normal ipsilateral left ear reflex. Routine vestibular examination showed no particular findings, with absence of nystagnus using Dix-Hallpike, Pagnini-McClure and Semont tests. The patient was studied also with video-nystagmography (System VNG Plus ECLERIS). The bicaloric stimulation test with water at 44° and 30° Celcius, resulted in an areflexia of the right ear and a reduced vestibular activity for the left ear.

Finally, the ABR test was carried out and showed increased interwave latencies (I-III, III-V and I-V), bilaterally but more significant in the right ear (Figure 3).

On January 2016 the patient had endoscopic third ventriculostomy (ETV). The CT scan demonstrated a high-grade dilatation of the supratentorial system, with a minimum air content on the right side and outcomes of right frontal craniotomy (Figure 4). On the follow up the patient referred an important subjective improve-

ment regarding instability and gait dysfunction. Nevertheless vestibular tests showed the persistence of areflexia and reduced vestibular activity, with not important changes regarding hearing loss, consistent with the follow up audiogram (Figure 2B).

Discussion

Various studies report the correlation between hydrocephalus and sensorineural hearing loss. To date, the pathophysiology which explains the hearing loss associated with hydrocephalus is conflicting in the literature that has been reviewed. Most of the studies focus on the effect of shunt-treated hydrocephalus.¹⁴⁻¹⁶ The authors hypothesised a hearing loss due to a decrease in pressure or volume of the CSF with a concomitant reduction in perilymphatic fluid, comparable to a transitory endolymphatic hydrops.¹⁶ An other study¹⁵ suggests that long-term shunting may result in overdrainage of the CSF and produce skull base hypoplasia with the involment of the brain stem, which determines a retrocochlear

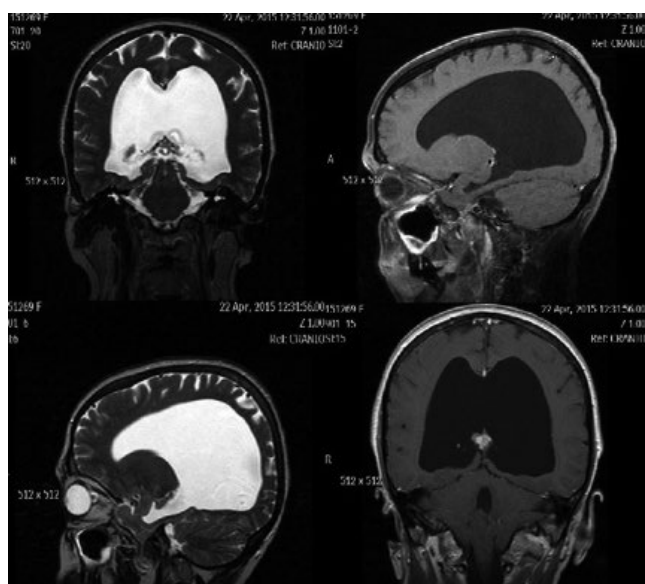


Figure 1. MRI images revealing the pronounced extension of hydrocephalus.

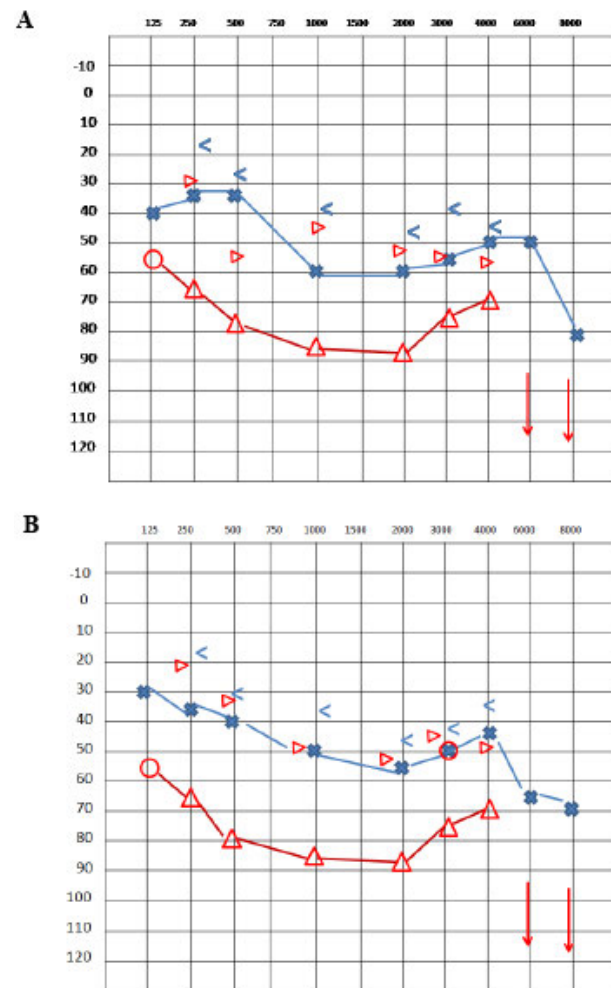


Figure 2. Audiogram (A) showing a gap between the right and left hearing thresholds, with severe sensorineural hearing loss on the right ear. Audiogram (B) demonstrating slight differences with persisting hearing loss after the ETV operation.

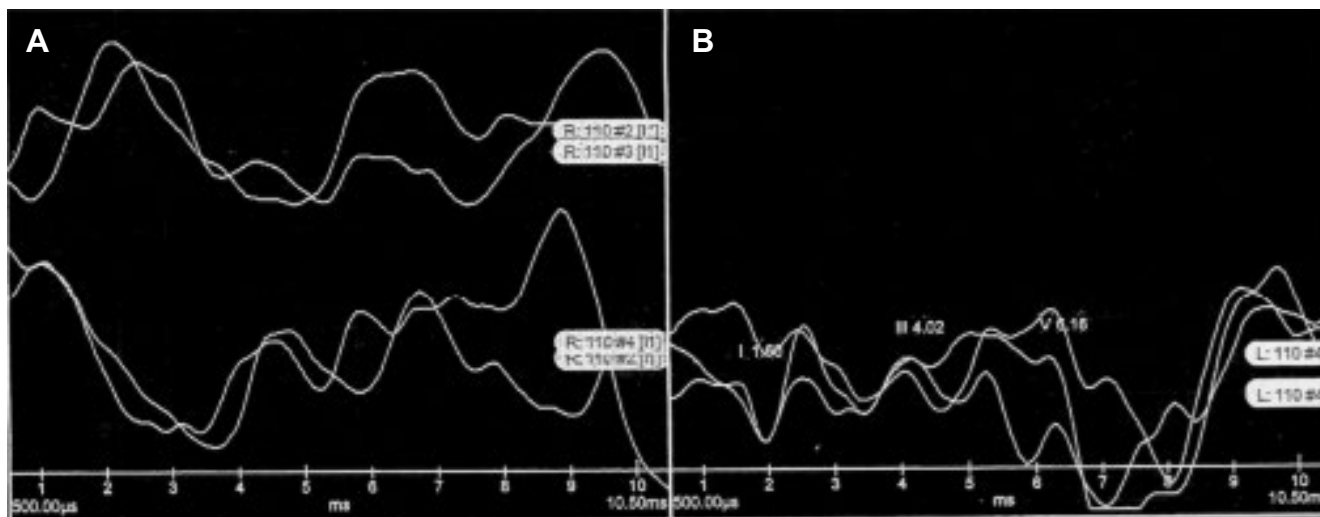


Figure 3. ABR pathologic findings for the latencies of the waves I-III, III-V and I-V bilaterally but more significant in the right ear (A).

dysfunction with elevated contralateral acoustic reflex threshold and significant difference (60 dB) between acoustic reflex threshold and hearing threshold, in absence of middle ear pathology. Other authors describe a bilateral low frequency SNHL that is resolved following shunt placement,^{17,18} suggesting that hearing loss associated with hydrocephalus has a pathogenesis similar to endolymphatic hydrop with fluctuating hearing loss. In the literature, is also described a persistent bilateral low frequency hearing loss one year after the placement of a ventriculoperitoneal shunt.¹⁹ All the authors propose a pathophysiology mechanism of a cochleo-vestibular damage, which consists of the transmission of the pressure variations in CSF to the inner ear labyrinth through the cochlear aqueduct. More specifically, the omeostasis of cochlear fluids and CSF pressure is due to the normal drainage through the cochlear aqueduct and the endolymphatic sac. Although there is not any direct communication endolymph-CSF, cochlear aqueduct permits a direct communication of perilymph and CSF, on the other hand, endolymphatic sac controls endolymphatic pressure, being positioned within subdural space, surrounded by CSF.^{17,20} Even a minimum variation of CSF pressure, can be transmitted through the cochlear aqueduct to the perilymph of the scala tympani and determine very small but important displacements within the cochlea. A minimal pressure difference amongst endolymph and perilymph can determine displacement of the Reissner's membrane and the effects on hearing threshold and vestibular function, in what we call *reverse like endolymphatic hydrop* mechanism effect. On the other side a low perilymphatic pressure can cause collapse and rupture of the Reissner's membrane.^{14,21}

Conclusions

The sensorineural hearing loss, with progressive deterioration of hearing and vestibular function in this patient, was associated with hydrocephalus. This particular pathologic correlation between hearing loss and hydrocephalus, could be explained by the anatomical relationship between the fluid spaces of the inner ear and the central nervous system.

In conclusion our case report refers to a patient that has a predisposition to cochleo-vestibular degenerative processes possibly related to phenomena of hydropic type or long standing old data

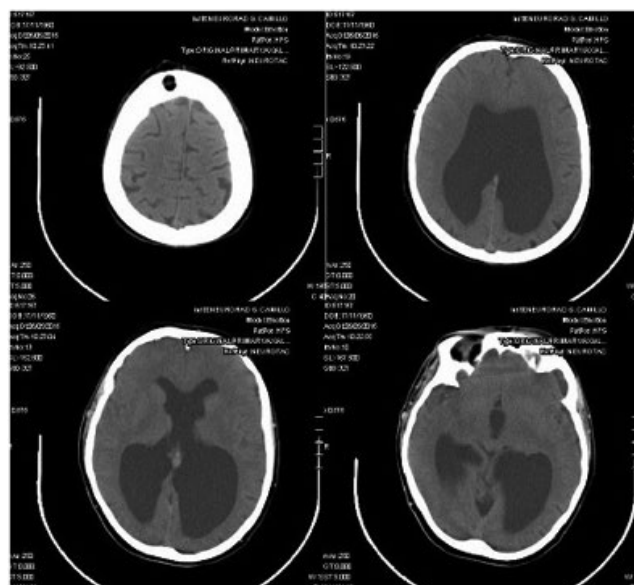


Figure 4. CT scan demonstrating a high grade dilatation of the supratentorial system, with a minimum air content on the right side and outcomes of right frontal craniotomy.

infections aggravated from hydrocephalus. The endoscopic third ventriculostomy operation resulted in a subjective improvement on gait and instability dysfunction, without significant variations of the hearing loss.

References

1. Spirakis SE, Hurley RM. Unilateral hearing loss in children with shunt-treated hydrocephalus. *J Am Acad Audiol* 2003;14:510-7.
2. Toma AK, Stapleton S, Papadopoulos MC, et al. Natural history of idiopathic normal-pressure hydrocephalus. *Neurosurg Rev* 2011;34:433-9.
3. McGirt MJ, Woodworth G, Coon AL, et al. Diagnosis, treatment, and analysis of long-term outcomes in idiopathic nor-

- mal-pressure hydrocephalus. *Neurosurgery* 2008;62:670-7.
4. Hakim S, Adams RD. The special clinical problem of symptomatic hydrocephalus with normal cerebrospinal fluid pressure. Observations on cerebrospinal fluid hydrodynamics. *J Neurol Sci* 1965;2:307-72.
 5. de Oliveira MF, Reis RC, Marramon Trindade E, Gomes Pinto FC. Evidences in the treatment of idiopathic normal pressure hydrocephalus. *Rev Assoc Med Bras* 2015;61:258-62.
 6. Brean A, Eide PK. Prevalence of probable idiopathic normal pressure hydrocephalus in a Norwegian population. *Acta Neurol Scand* 2008;118:48-53.
 7. Marmarou A, Bergsneider M, Klinge P, et al. The value of supplemental prognostic tests for the preoperative assessment of idiopathic normal-pressure hydrocephalus. *Neurosurgery* 2005;57:S17-28; discussion ii-v.
 8. Relkin N, Marmarou A, Klinge P, et al. Diagnosing idiopathic normal-pressure hydrocephalus. *Neurosurgery* 2005;57:S4-16; discussion ii-v.
 9. Kestle J, Drake J, Milner R, et al. Long-term follow-up data from the shunt design trial. *Pediatr Neurosurg* 2000;33:230-6.
 10. Chrissicopoulos C, Mourgela S, Kirgiannis K, et al. What is the appropriate shunt system for normal pressure hydrocephalus? *Acta Neurochir Suppl* 2012;113:119-21.
 11. Bakker SL, Boon AJ, Wijnhoud AD, et al. Cerebral hemodynamics before and after shunting in normal pressure hydrocephalus. *Acta Neurol Scand* 2002;106:123-7.
 12. Freimann FB, Streitberger KJ, Klatt D, et al. Alteration of brain viscoelasticity after shunt treatment in normal pressure hydrocephalus. *Neuroradiology* 2012;54:186-96.
 13. Chan AK, McGovern RA, Zacharia BE, et al. Inferior short-term safety profile of endoscopic third ventriculostomy compared with ventriculoperitoneal shuntplacement for idiopathic normal-pressure hydrocephalus: a population-based study. *Neurosurgery* 2013;73:951-60; discussion 960-1.
 14. Arenberg IK, Ackley RS, Ferraro J, Muchnick C. ECoG results in perilymphatic fistula: clinical and experimental studies. *Otolaryngol Head Neck Surg* 1988;99:435-43.
 15. Lopponen H, Sorri M, Serlo W, von Wendt L. Audiological findings of shunt-treated hydrocephalus in children. *Int J Pediatr Otolaryngol* 1989;18:21-30.
 16. Walstead A, Nielsen O, Borum P. Hearing loss after neurosurgery. The influence of low cerebrospinal fluid pressure. *J Laryngol Otol* 1994;108:637-41.
 17. Tandon PN, Sinha A, Kacker SK, et al. Auditory function in raised intracranial pressure. *J Neurol Sci* 1973;18:455-67.
 18. Barlas O, Gokay H, Turantan I, Baserer, N. Adult aqueductal stenosis with fluctuate hearing loss and vertigo. *J Neurosurg* 1983;59:703-5.
 19. Stoeckli S, Bohmer A. Persistent bilateral hearing loss after shunt placement for hydrocephalus. *J Neurosurg* 1999;90:773-5.
 20. Durrant JD, Lovrinic JH. Bases of hearing science. 3rd ed. Baltimore: Williams and Wilkins; 1995.
 21. Funai H, Hara M, Nomura Y. An electrophysiological study of experimental perilymphatic fistula. *Am J Otolaryngol* 1988;9:244-55.