

Epicardial ablation of a focal atrial tachycardia adjacent to the sinoatrial node: A case report



Yanhong Chen, MD, PhD, Chenggang Deng, MD, Jinlin Zhang, MD, PhD

From the Department of Cardiology, Wuhan Asia Heart Hospital, Wuhan, China.

Introduction

We report a case of focal atrial tachycardia ablated at the epicardial side adjacent to the sinoatrial node.

Case report

The patient was a 30-year-old woman who presented to our center for palpitation and shortness of breath for 1 month. Her electrocardiography (ECG) showed persistent atrial tachycardia, with P' waves that were positive in leads I/III/III/aVF/V₂-V₆, positive-negative in lead V₁, and negative in lead aVR. The P'R interval was approximately comparable to the RP' interval. The cycle length of the tachycardia varied between 264 and 467 ms. Her echocardiography showed a structurally normal heart. Previous electrophysiological study suggested a focal atrial tachycardia originating in the high right atrium (RA) near the right atrial appendage (RAA). But ablations in the endocardial side of the high RA failed to terminate the tachycardia.

The second ablation attempt was conducted under an ultra-high-density 3-D mapping system. The surface ECG showed a narrow-QRS tachycardia. The coronary sinus was activated from the proximal end to the distal end. Mapping of the RA revealed that the earliest activation point was at the root of the RAA, being close to the superior vena cava and the sinoatrial node (Figure 1A). The local bipolar potential of the target was 20 ms earlier than the surface P' wave. But repeated ablation here was ineffective.

Pericardium puncture and epicardial mapping were then performed. The epicardial earliest activation site was at the corresponding site of the endocardial target. Although the

KEYWORDS Focal atrial tachycardia; Epicardial ablation; Ultra-high-density mapping; Catheter ablation; Supraventricular tachycardia (Heart Rhythm Case Reports 2022;8:247-249)

Funding Support: This work was supported by the 2018 Wuhan Young & Middle-aged Medical Backbone Training Program for Yanhong Chen, and 2020 Wuhan Medical Research Project (WX20C44). **Disclosures:** The authors report no conflicts of interest. All authors have participated in the work and have reviewed and have agreed with the content of the article. The authors alone are responsible for the content and writing of the paper.

Address reprint requests and correspondence: Dr Chenggang Deng, Department of Cardiology, Wuhan Asia Heart Hospital, 753 Jinghan Rd, Wuhan, Hubei, China, 430000. E-mail address: dcg8889@sina.com.

KEY TEACHING POINTS

- Focal atrial tachycardia originating in the epicardial right atrium is very rare.
- Inappropriate sinus tachycardia and atrial tachycardias close to the right atrial appendage root could pose challenges for ablations.
- Epicardial mapping and ablation could be considered as an alternative for tachycardias resistant to endocardial ablation.

unipolar potential at the epicardial target had a small r wave, the bipolar potential here was fragmented and it was slightly earlier than the endocardial target (22 ms earlier than surface P' wave) (Figure 1B). Radiofrequency energy at the epicardial target was delivered (50 W, 43°C, 30 mL/min irrigated). A total of 5.9 seconds of single-point ablation terminated the tachycardia.

After the ablation of the tachycardia, we performed RA activation mapping under sinus rhythm. The earliest activation site was at the middle crista terminalis, close to but lower than the ablation target (Figure 2A). The sinus P wave had a cycle length of around 800 ms, with slightly different P-wave morphology from that of the tachycardia (Figure 2B). Compared with the sinus P wave, the tachycardia P' wave was less positive in lead aVL/V₂/V₃ and more positive in lead III/aVF (Figure 2C and 2D). Repeated atrial stimulation could not induce any tachycardia. After the ablation, Holter monitoring showed a significant decrease in maximal (115 beats per minute [bpm]) and mean heart rate (97 bpm), and the lowest heart rate was 80 bpm. ECG taken 3 months after the ablation was sinus. During our follow-up of 12 months, the patient did not have atrial tachycardia and remained symptom-free.

Discussion

We report a case of an epicardial right atrial tachycardia that was adjacent to the epicardial sinoatrial node area.

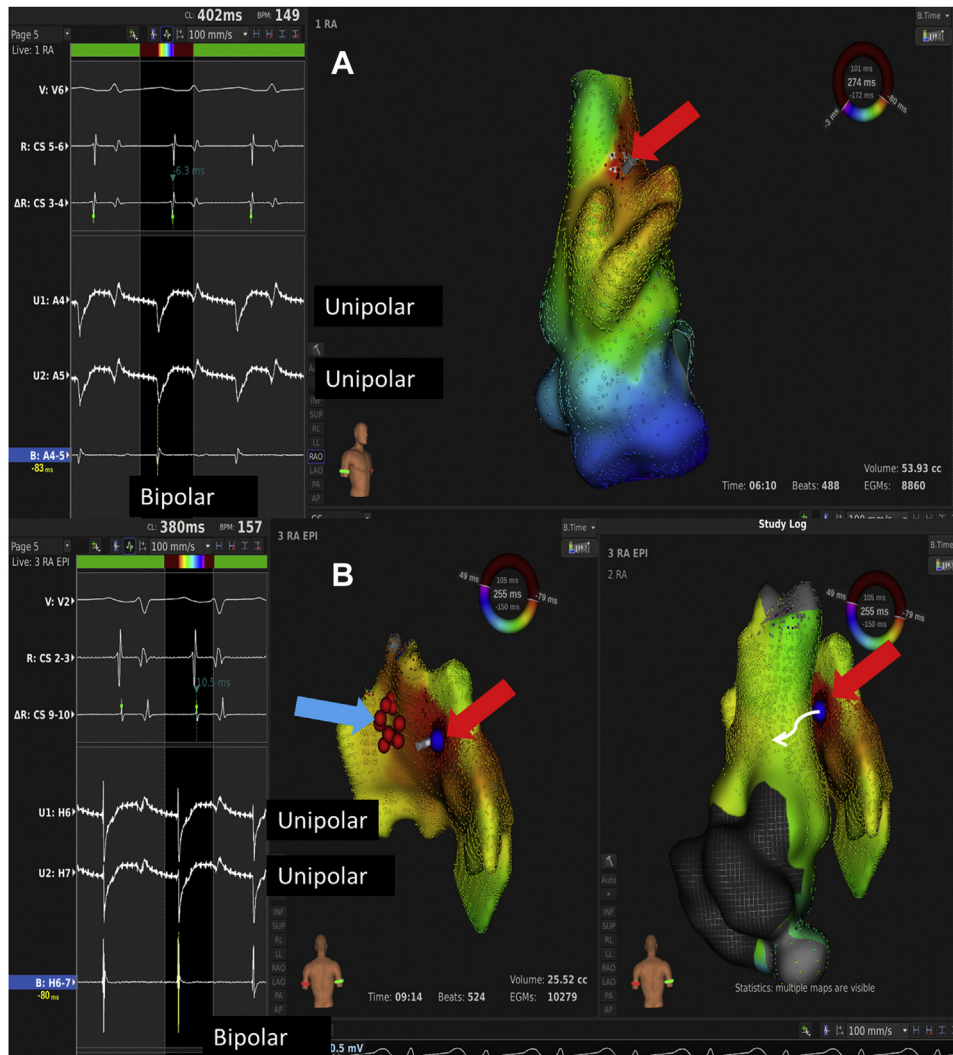


Figure 1 A: The left panel shows the unipolar and bipolar potentials recorded from the earliest activation site at the endocardial side. The right panel shows the endocardial mapping of the tachycardia. The earliest activation site was at the root of the right atrial appendage (red arrow). B: The left panel shows the unipolar and bipolar potentials at the epicardial side. The right panel shows epicardial and endocardial combined activation map performed under the tachycardia. The blue dots mark the epicardial target (red arrow) and the red dots mark the endocardial ablation site (blue arrow).

Origins of right atrial tachycardia include crista terminalis,¹ tricuspid annulus,² the para-His region,³ coronary sinus ostium,⁴ and, less frequently, the RAA.⁵ Almost all the focal atrial tachycardias can be ablated from the endocardial side of the RA. Some of the ATs from the RAA may need epicardial ablation or surgeries.

Still, focal atrial tachycardia originating in the epicardial RA is very rare. In this case, the earliest endocardial activation site of the tachycardia was located near the root of the RAA, adjacent to the sinoatrial nodal area. From the anatomy point of view, the crista terminalis goes through the root of the RAA, which continues in an anterosuperior arch (the pre-caval bundle). The sagittal bundle also originates from this area. The myocardial strands of these distinctive muscle bundles can be thicker than 10 mm (average thickness), which makes it hard to achieve a transmural lesion from the endocardial side.⁶

We also observed that the unipolar signals at the epicardial target had a small r wave at the initial part. As there is a layer of fat tissue in the pericardial cavity, between the mapping basket and the true origin of the tachycardia, it is actually very hard to achieve direct contact with the myocardium through the pericardium access. So we used comparatively high ablation energy during the operation (50 W, 43°C, 30 mL/min irrigated). Our case suggested that for some of the ablation-refractory tachycardia, it might be helpful to map and ablate from the epicardial side.

Also, it is hard to say whether this has been an inappropriate sinus tachycardia (IST) or not. The diagnosis of IST is based on persistent or recurrent sinus tachycardia. Patients with IST generally have resting daytime sinus rates of more than 100 bpm and average 24-hour heart rates of more than 90 bpm, which could not be explained by physiologic or emotional stress. The difference between the tachycardia P' wave and

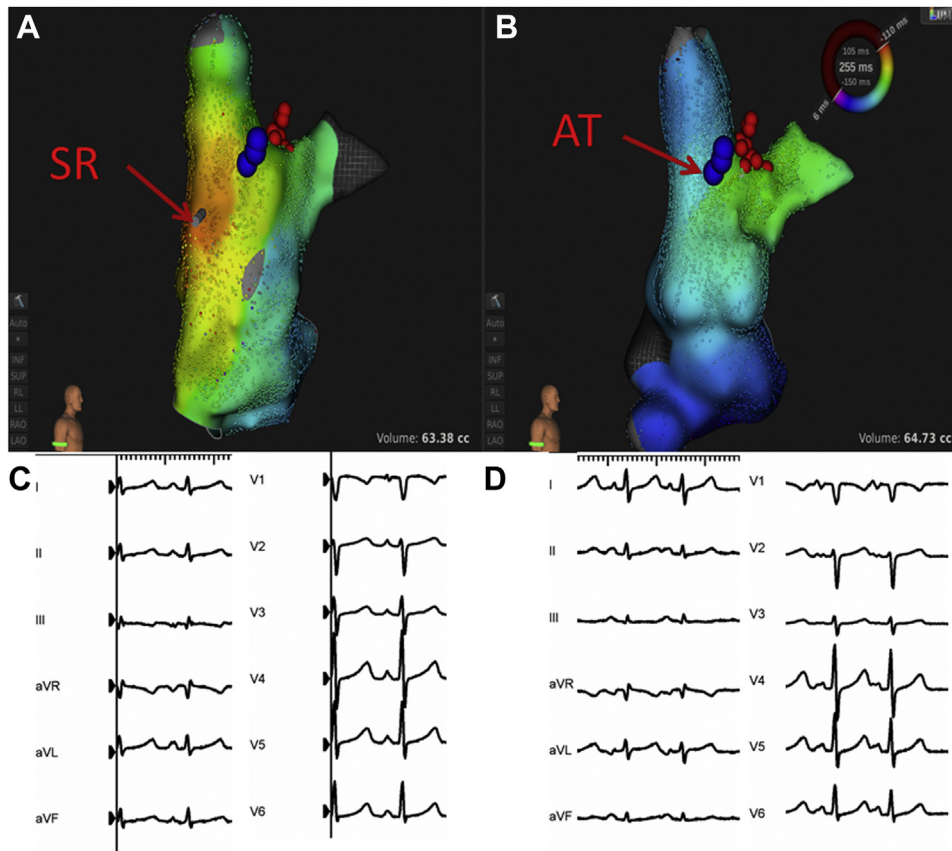


Figure 2 **A:** The endocardial activation map performed after the ablation, which shows the earliest activation site of the sinus rhythm (SR; **red arrow**). The blue dots mark the epicardial target and the red dots mark the endocardial ablation site. **B:** The endocardial activation map performed under the atrial tachycardia (AT), with the earliest activation site at the root of the right atrial appendage (**red arrow**). The blue dots mark the epicardial target and the red dots mark the endocardial ablation site. **C:** Twelve-lead surface electrocardiogram (ECG) recorded under sinus rhythm. **D:** Twelve-lead surface ECG recorded under tachycardia. Compared with the sinus P wave, the tachycardia P' wave was less positive in lead aVL/V₂/V₃ and more positive in lead III/aVF.

the sinus P wave was very subtle. And shifts in the earliest RA activation site are not uncommon after IST ablations.

Recent research has found evidence of the existence of superior and inferior sinoatrial nodes in the human heart,⁷ localized near the superior vena cava and the inferior vena cava, respectively. We think it likely that the atrial tachycardia originates in the paranodal transition area between the sinoatrial node pacing cells and the RA cardiomyocytes, considering the location of the epicardial target and its response to ablation.

In clinical practice, IST and atrial tachycardias close to the RAA root could pose challenges for ablations. Sinoatrial node modification to treat highly symptomatic tachycardia has been done at the endocardial side of the RA, which yields a high recurrence rate.⁸ Some ISTs need surgical interventions.⁹ Atrial tachycardia arising from the epicardial origin in the vicinity of the RAA has been chiefly treated successfully from the endocardial side using a cryoballoon or cryocatheter or by surgical excision of the RAA. There are few reports of successful treatment with epicardial mapping for high RA tachycardias. Epicardial mapping and ablation could be considered as an alternative for tachycardias resistant to endocardial ablation.

References

- Morris GM, Segan L, Wong G, et al. Atrial tachycardia arising from the crista terminalis, detailed electrophysiological features and long-term ablation outcomes. *JACC Clin Electrophysiol* 2019;5:448–458.
- Morton JB, Sanders P, Das A, Vohra JK, Sparks PB, Kalman JM. Focal atrial tachycardia arising from the tricuspid annulus: electrophysiologic and electrocardiographic characteristics. *J Cardiovasc Electrophysiol* 2001;12:653–659.
- Iwai S, Badhwar N, Markowitz SM, et al. Electrophysiologic properties of parahisian atrial tachycardia. *Heart Rhythm* 2011;8:1245–1253.
- Kistler PM, Fynn SP, Haqqani H, et al. Focal atrial tachycardia from the ostium of the coronary sinus: electrocardiographic and electrophysiological characterization and radiofrequency ablation. *J Am Coll Cardiol* 2005;45:1488–1493.
- Guo XG, Zhang JL, Ma J, et al. Management of focal atrial tachycardias originating from the atrial appendage with the combination of radiofrequency catheter ablation and minimally invasive atrial appendectomy. *Heart Rhythm* 2014;11:17–25.
- Ueda A, McCarthy KP, Sanchez-Quintana D, et al. Right atrial appendage and vestibule: further anatomical insights with implications for invasive electrophysiology. *Europace* 2013;15:728–734.
- Brennan JA, Chen Q, Gams A, et al. Evidence of superior and inferior sinoatrial nodes in the mammalian heart. *JACC Clin Electrophysiol* 2020;6:1827–1840.
- Olshansky B, Sullivan RM. Inappropriate sinus tachycardia. *J Am Coll Cardiol* 2013;61:793–801.
- Aalaei-Andabili SH, Miles WM, Burkart TA, et al. Minimally invasive thoracoscopic surgery is an effective approach for treating inappropriate sinus tachycardia. *J Cardiovasc Electrophysiol* 2019;30:1297–1303.