









# Diagnostic Performance of Digital Breast Tomosynthesis with the Two-Dimensional Synthesized Mammogram for Suspicious Breast Microcalcifications Compared to Full-Field Digital Mammography in Stereotactic Breast Biopsy

정위적 유방 조직검사 시 미세석회화 의심 병변에서의 디지털 유방단층영상합성법과 전역 디지털 유방촬영술의 진단능 비교

Jiwon Shin, MD<sup>1</sup> , Ok Hee Woo, MD<sup>1\*</sup> , Hye Seon Shin, MD<sup>1</sup> ,  
Sung Eun Song, MD<sup>2</sup> , Kyu Ran Cho, MD<sup>2</sup> , Bo Kyoung Seo, MD<sup>3</sup> 


<sup>1</sup>Department of Radiology, Korea University Guro Hospital, College of Medicine, Korea University, Seoul, Korea


<sup>2</sup>Department of Radiology, Korea University Anam Hospital, College of Medicine, Korea University, Seoul, Korea


<sup>3</sup>Department of Radiology, Korea University Ansan Hospital, College of Medicine, Korea University, Seoul, Korea


## ORCID iDs


Jiwon Shin  <https://orcid.org/0000-0002-7804-9539>

Ok Hee Woo  <https://orcid.org/0000-0003-3953-933X>

Hye Seon Shin  <https://orcid.org/0000-0001-8569-4360>

Sung Eun Song  <https://orcid.org/0000-0002-9259-8294>

Kyu Ran Cho  <https://orcid.org/0000-0002-8936-6468>

Bo Kyoung Seo  <https://orcid.org/0000-0002-9512-5361>

Received June 2, 2021  
Revised August 2, 2021  
Accepted September 23, 2021

## \*Corresponding author

Ok Hee Woo, MD  
Department of Radiology,  
Korea University Guro Hospital,  
College of Medicine,  
Korea University,  
148 Gurodong-ro, Guro-gu,  
Seoul 08308, Korea.

Tel 82-2-2626-1338  
Fax 82-2-863-9282  
E-mail wokhee@korea.ac.kr

This is an Open Access article distributed under the terms of the Creative Commons Attribution Non-Commercial License (<https://creativecommons.org/licenses/by-nc/4.0>) which permits unrestricted non-commercial use, distribution, and reproduction in any medium, provided the original work is properly cited.

**Purpose** To evaluate the diagnostic performance of digital breast tomosynthesis (DBT) with the two-

dimensional synthesized mammogram (2DSM), compared to full-field digital mammography (FFDM), for suspicious microcalcifications in the breast ahead of stereotactic biopsy and to assess the diagnostic image visibility of the images.

**Materials and Methods** This retrospective study involved 189 patients with microcalcifications, which were histopathologically verified by stereotactic breast biopsy, who underwent DBT with 2DSM and FFDM between January 8, 2015, and January 20, 2020. Two radiologists assessed all cases of microcalcifications based on Breast Imaging Reporting and Data System (BI-RADS) independently. They were blinded to the histopathologic outcome and additionally evaluated lesion visibility using a five-point scoring scale.

**Results** Overall, the inter-observer agreement was excellent (0.9559). Under the setting of category 4A as negative due to the low possibility of malignancy and to avoid the dilution of malignancy criteria in our study, McNemar tests confirmed no significant difference between the performances of the two modalities in detecting microcalcifications with a high potential for malignancy (4B, 4C, or 5;  $p = 0.1573$ ); however, the tests showed a significant difference between their performances in detecting microcalcifications with a high potential for benignancy (4A;  $p = 0.0009$ ). DBT with 2DSM demonstrated superior visibility and diagnostic performance than FFDM in dense breasts.

**Conclusion** DBT with 2DSM is superior to FFDM in terms of total diagnostic accuracy and lesion visibility for benign microcalcifications in dense breasts. This study suggests a promising role for DBT with 2DSM as an accommodating tool for stereotactic biopsy in female with dense breasts and suspicious breast microcalcifications.

**Index terms** Breast Neoplasm; Mammography; Biopsy

## INTRODUCTION

Breast cancer is one of the most common cancers affecting female. Therefore, breast screening is gaining importance. The most widely used image modality is mammography, which offers information about masses, asymmetries, calcifications, and architectural distortions. Detection of microcalcifications is key in early diagnosis of breast cancer.

Breast calcifications are detected frequently in breast cancer screening and have various causes. Most are benign, but some constitute an early sign of malignancy (1). With current imaging modalities, distinguishing malignant from benign calcifications is difficult, especially when considering suspicious breast microcalcifications that reveal malignancy, such as ductal carcinoma in situ (DCIS). Therefore, careful identification and characterization of the morphology of microcalcifications are crucial to stratify the risk of malignancy.

To date, the most widely used imaging technique for breast screening is full-field digital mammography (FFDM), which is considered the most effective tool for diagnosing early breast cancer and reducing cancer mortality rates. However, FFDM has several limitations due to its difficulty with clearly distinguishing suspicious breast lesions from overlapping breast tissue (2).

Digital breast tomosynthesis (DBT) is a state-of-the-art imaging technology for breast cancer screening and assessment that has been gaining popularity (3). DBT is a three-dimensional (3D) imaging modality that overcomes several problems of FFDM, especially tissue superimposition or overlapping, by providing a series of thin-section images from reconstructed

volume data. It possesses the potential to increase sensitivity in the detection of breast cancer and to reduce recall rates (4).

Currently, a combination of FFDM and DBT has been deployed in multiple breast imaging studies (5). This dual-imaging modality approach improved breast cancer accuracy, decreased the false-negative rate, and increased the sensitivity compared to FFDM alone; however, additional interpretation time and radiation exposure persisted as limitations. Still, recent technological improvements could resolve the problem by generating synthetic two-dimensional (2D) images from DBT data using a reconstruction algorithm, which does not require additional radiation doses (6-8).

As the value of DBT increases, assessments for masses, asymmetries, and architectural distortions have been performed in many studies, while studies including the evaluation of microcalcifications are more limited in number (9). Some studies have determined the clinical performance of DBT in detecting and characterizing microcalcifications, and the diagnostic performance of synthetic 2D images with or without DBT were not different from those of FFDM (10, 11). Another study estimated the 3D positions of microcalcifications in each of the clusters and reconstructed clusters as ellipsoids using multiple projections of DBT, which constitutes a possible method of 3D shape analysis that leads to more accurate diagnosis (12). These findings indicate that DBT with 2D synthesized mammogram (2DSM) has potential as a stand-alone modality for screening and diagnosis. However, the detectability of stand-alone DBT with 2DSM for elucidating breast microcalcifications remains controversial.

Also, image quality is important for calcification conspicuity and can affect image contrast and the number of visible calcifications. Recent technical advancements have helped improve visualization of calcifications and provide superior image quality. Greater image visibility influences the ability to examine how “clearly” calcifications are seen in opposition to the background of the breast (10).

There are several methods to confirm suspicious calcifications in the breast; among them, stereotactic breast biopsy has long been the preferred method for sampling microcalcifications and an alternative to surgical excision. It has shown high diagnostic accuracy ranging from 93% to 100% (13, 14).

To our knowledge, only a small number of articles has focused on the comparison of DBT with 2DSM and FFDM for elucidating breast microcalcifications, and no study has focused on the diagnostic power of DBT for stereotactic biopsy. The goal of this study was to determine whether DBT with 2DSM exhibits a diagnostic advantage over FFDM for suspicious breast microcalcifications before stereotactic biopsy and whether it provides superior lesion visibility.

## MATERIALS AND METHODS

### PATIENT SELECTION

This study was approved by the appropriate Institutional Review Board and relied on a retrospective electronic medical records review for data collection (IRB No. 2020GR0317). Data were collected from January 8, 2015, through January 20, 2020. To select study participants, those eligible included the following: 1) underwent DBT with 2DSM in combination with

FFDM, 2) microcalcifications detected by either DBT with 2DSM or FFDM and classified into category 4A or above based on the BI-RADS, 3) microcalcifications that were confirmed histopathologically through stereotactic biopsy in our hospital, and 4) at least two years of imaging follow-up data available. Separately, the study exclusion criteria were as follows: 1) history of breast cancer and 2) loss to follow-up or less than one year of follow-up data. Finally, a total of 189 patients who had undergone DBT with 2DSM along with FFDM and subsequent stereotactic biopsies for microcalcifications was included in this study.

## IMAGE ACQUISITION

A picture archiving and communication system (PACS) and electronic medical records were used to gather radiology reports from our institution. Patients underwent imaging using the same mammography machine for DBT and FFDM (Selenia Dimensions mammography system; Hologic, Bedford, MA, USA), and standard views of cranio-caudal and mediolateral oblique images were obtained sequentially during one session while the breast was compressed in a fixed position. For DBT, 15 projection images along 15 degrees of arc (1 image/degree of arc) were collected, and this image set was reconstructed automatically into 2DSM by a summing and filtering back-projection technique. All images were stored in the PACS. Additional images (e.g., magnification views) were not included in the current study.

## IMAGE ASSESSMENT

Imaging analysis was performed by two radiologists (O.H.W. and H.S.S.) with 18 and 9 years of breast imaging experience, respectively. Both readers have undergone training in the interpretation of DBT and routinely interpreted DBT and FFDM images in clinical practice for both screening and diagnostic reasons. Both readers were aware of the aim of the study but were blinded to the presence and type of lesions.

The present study was organized to encompass two separate reading sessions, each containing all cases randomized to 50% with FFDM and 50% with DBT with 2DSM. Readers were allowed to use the magnification function for both FFDM and DBT with 2DSM. As mentioned, additional images (e.g., magnification views) were not included in the present study. Reviews of the two datasets were spaced one month apart to avoid recall bias. In addition, reviewers were blinded to patient names, ages, and identification numbers.

All grading and reporting efforts employed the Breast Imaging Reporting and Data System (BI-RADS) classification system of the American College of Radiology (ACR)-BI-RADS fifth edition (2013) lexicon. Microcalcification status was stratified as follows using BI-RADS categories according to the lexicon: negative, no microcalcifications present = BI-RADS 1, benign microcalcifications = BI-RADS 2, probably benign microcalcifications (0%–2% malignant) = BI-RADS 3, suspicious microcalcifications = BI-RADS 4 (categorized further as BI-RADS 4A [2%–10%], BI-RADS 4B [10%–50%], and BI-RADS 4C [50%–95%]), and microcalcifications highly suggestive of malignancy ( $\geq 95\%$  malignant) = BI-RADS 5.

The primary outcome for the study was a positive histopathology result from stereotactic biopsy. Category 4A indicates a low suspicion of malignancy according to the ACR BI-RADS scoring system (15). Though histological diagnosis is necessary, as the possibility of a benign lesion is much larger than that of a malignant one, we treated a 4A result as a negative one in

our analysis to avoid dilution of malignant criteria by a high number of benign lesions.

Breast density was assigned based on ACR BI-RADS categories: fatty = A, scattered fibroglandular = B, heterogeneously dense = C, extremely dense = D. In this study, classified categories of ACR A and B indicated non-dense breast tissue, and categories of ACR C and D indicated dense breast tissue.

Regarding image visibility, as the object of the study was to assess how “clearly” microcalcifications can be delineated from a diagnostic perspective by each radiologist, findings were scored as follows: very indistinct = one point, indistinct = two points, fair = three points, clear = four points, very clear = five points. Each reader graded the cases individually (10, 16). Only the diagnostic quality of breast tissue appearance on the two modalities was tested, without detection of microcalcifications.

## STATISTICAL ANALYSIS

All statistical analyses were performed using the SPSS version 22.0 (IBM Corp., Armonk, NY, USA). Cohen's kappa ( $\kappa$ ) test was applied to evaluate inter-observer variability in the final assessment of BI-RADS categories. Inter-reader correlation coefficient was calculated to ascertain concurrence between the readers. Degrees of agreement were categorized, where 0.00 to 0.20 indicates slight agreement, 0.21 to 0.40 indicates fair agreement, 0.41 to 0.60 indicates moderate agreement, 0.61 to 0.80 indicates substantial agreement, and 0.81 to 1.00 indicates almost perfect agreement.

With the final BI-RADS scores assigned, sensitivity, specificity, positive predictive value (PPV), and negative predictive value (NPV) were obtained for DBT with 2DSM and FFDM. The McNemar test was used to assess the difference in detection rates of microcalcifications with high potential for malignancy (4B, 4C, or 5) and high potential for benignancy (4A) between the two modalities. To ascertain the difference in performance according to patient breast density, Fisher's exact test was used. The difference in receiver-operating characteristic curves was analyzed to compare the overall clinical performance, with corresponding 95% confidence interval values.

Scores for the visibility of suspicious breast lesions were compared by Wilcoxon signed-rank test, and weighted  $\kappa$  values for inter-reader agreement were calculated.

All statistical tests were two-sided, and  $p \leq 0.05$  was considered statistically significant.

## RESULT

### CHARACTERISTICS OF MICROCALCIFICATIONS AND BREAST DENSITY

A total of 189 patients ranging in age from 32 to 68 years (median, 49.2 years) with suspicious microcalcifications was included in the final study cohort. Fifty-four cases with suspicious microcalcifications (29%) proved to be malignant and 135 were benign (71%). There were 32 cases of DCIS (59%); five cases of microinvasive DCIS (9%); and 17 cases of invasive ductal carcinoma (31%), including those of ductal and lobular origins. Cases of benign lesions included 95 ductal hyperplasia (70%), 15 atypical hyperplasia (11%), nine sclerosing adenosis (6%), five columnar cell change (3%), seven fibrocystic change (5%), and four apocrine metaplasia (2%) (Table 1).

**Table 1.** Pathologic Types of Malignant and Benign Cases

	Pathology Type	n (%)
Malignant (n = 54)	Ductal carcinoma in situ	32 (59)
	Invasive ductal carcinoma	17 (31)
	Microinvasive ductal carcinoma in situ	5 (9)
Benign (n = 135)	Ductal hyperplasia	95 (70)
	Atypical hyperplasia	15 (11)
	Sclerosing adenosis	9 (6)
	Columnar cell change	5 (3)
	Apocrine metaplasia	4 (2)
	Fibrocystic change	7 (5)

**Table 2.** Distribution of Final Assessment Categories of Suspicious Microcalcifications Detected by DBT with 2DSM and FFDM

	Malignant		Benign	
	DBT with 2DSM (%)	FFDM (%)	DBT with 2DSM (%)	FFDM (%)
Category 4A	4 (7.4)	6 (11.1)	118 (87.4)	102 (75.5)
Category 4B	27 (50.0)	39 (72.2)	13 (9.6)	20 (14.8)
Category 4C	18 (33.3)	8 (14.8)	3 (2.2)	10 (7.4)
Category 5	5 (9.2)	1 (1.8)	1 (0.7)	3 (2.2)
Total	54	54	135	135

Category 4A = low suspicion for malignancy, Category 4B = moderate suspicion for malignancy, Category 4C = high suspicion for malignancy, Category 5 = highly suggestive of malignancy, DBT = digital breast tomosynthesis, FFDM = full-field digital mammography, 2DSM = two-dimensional synthesized mammogram

Category 4B was set as a cutoff value for malignancy, and categories for suspicious breast calcifications were assigned from 4A to 5 to assess the possibility of malignancy for each modality. Among the two benign and malignant microcalcification cases, the BI-RADS category distribution showed no significant difference. DBT with 2DSM assigned more cases in categories 4B, 4C, and 5 that were later recognized as malignancy than benignancy (Table 2).

The breast densities of the study population were stratified into four cases with fatty tissue (2%), 30 cases with scattered fibroglandular tissue (16%), 110 cases with heterogeneously dense tissue (58%), and 45 cases with extremely dense tissue (24%); overall, there were 34 non-dense breast cases (18%) and 155 dense breast cases (82%).

## DIAGNOSTIC ACCURACY & DETECTION ABILITY OF DBT WITH 2DSM AND FFDM FOR BREAST MICROCALCIFICATIONS

The result of Cohen's  $\kappa$  test showed that inter-observer agreement was excellent for BI-RADS classification (Cohen's  $\kappa = 0.83 \pm 0.04$  and  $0.94 \pm 0.02$ ).

Based on histopathologic results, the prevalence of breast malignancy was 28.5% (54/189). When categories 4B, 4C, and 5 were classified as breast malignancy, the diagnostic accuracy of DBT with 2DSM in microcalcifications with high potential for benignancy (4A) was significantly higher than that of FFDM (87.4% vs. 75.5%;  $p = 0.0020$ ). Also, that for microcalcifications with high potential for malignancy (4B, 4C, 5) in DBT with 2DSM was slightly higher than that

**Table 3.** Diagnostic Accuracy of DBT with 2DSM and FFDM in Detecting Breast Microcalcifications

	Malignant (%)	Benign (%)	Diagnostic Accuracy (%)
DBT with 2DSM			168/189 (88.8)
Malignant	50 (92.5)	17 (12.5)	
Benign	4 (7.4)	118 (87.4)	
Total	54	135	
FFDM			150/189 (79.3)
Malignant	48 (88.8)	33 (24.4)	
Benign	6 (11.1)	102 (75.5)	
Total	54	135	
<i>p</i>	0.52	< 0.01	< 0.01

DBT = digital breast tomosynthesis, FFDM = full-field digital mammography, 2DSM = two-dimensional synthesized mammogram

**Table 4.** Diagnostic Accuracy of DBT with 2DSM and FFDM in Determining Breast Densities

Breast Densities	Modality	Accuracy (%)	$\chi^2$	<i>p</i> -Value
ACR category A and B	DBT with 2DSM	88.2 (30/34)	0.532	0.4852
	FFDM	82.3 (28/34)		
ACR category C and D	DBT with 2DSM	89.0 (138/155)	4.700	0.0370
	FFDM	82.5 (128/155)		

ACR = American College of Radiology, DBT = digital breast tomosynthesis, FFDM = full-field digital mammography, 2DSM = two-dimensional synthesized mammogram

of FFDM, but without statistical significance (92.6% vs. 88.8%;  $p = 0.5218$ ).

Overall, the total diagnostic accuracy of DBT with 2DSM was higher than that of FFDM, with statistical significance (88.8% vs. 79.3%;  $p = 0.0112$ ) (Table 3). Values for the area under the receiver-operating characteristic curve were 0.876 (95% confidence interval, 0.863–0.932) for DBT with 2DSM and 0.840 (95% confidence interval, 0.774–0.859) for FFDM, and the difference was significant ( $p < 0.01$ ).

The sensitivity of DBT with 2DSM was 92.5% (50/54) and that of FFDM was 88.8% (48/54) ( $p = 0.37$ ), while the specificity of DBT with 2DSM was 87.4% (118/135) and that of FFDM was 75.5% (102/135) ( $p = 0.0009$ ). The PPVs of DBT with 2DSM and FFDM, respectively, were 74.6% (50/67) and 59.2% (48/81), and the NPVs were 96.7% (118/122) and 94.4% (102/108).

McNemar testing showed no significant difference between the two modalities in detecting microcalcifications with high potential for malignancy (4B, 4C, 5) that were later confirmed to exhibit malignancy ( $p = 0.1573$ ). However, statistical significance was shown in detecting microcalcifications with high potential for benignancy (4A) that were later proven benign ( $p = 0.0009$ ).

## DIAGNOSTIC ACCURACY OF DBT WITH 2DSM AND FFDM IN PATIENTS WITH DIFFERENT BREAST DENSITIES

Of all 189 patients with microcalcifications, 155 were classified as having dense breasts (categories of ACR C and D) and 34 as non-dense breast (categories of ACR A and B). In dense breasts, DBT with 2DSM was superior to FFDM in diagnosis, with statistical significance (89.0% vs. 82.5%;  $\chi^2 = 4.700$ ;  $p = 0.0370$ ). DBT with 2DSM also demonstrated slightly superior

**Table 5.** Interobserver Agreement for Final Assessment Category Assignment for DBT with 2DSM and FFDM Together with the Visibility Scores

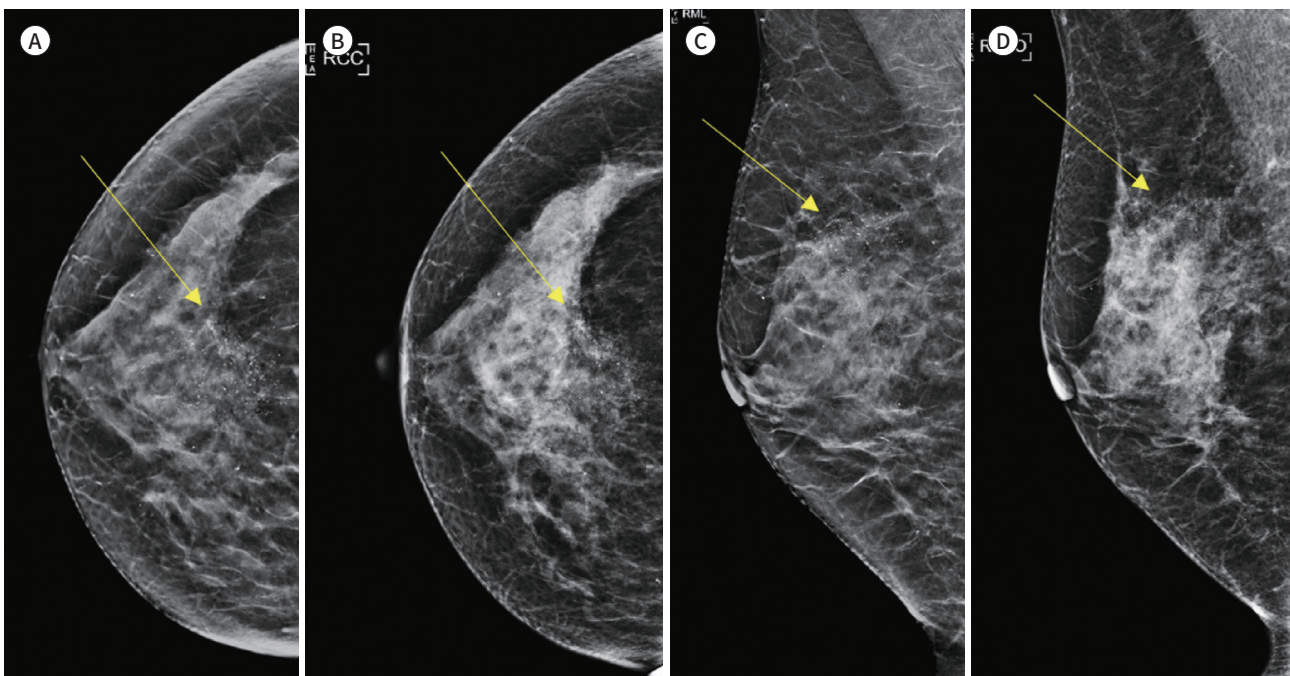
Breast Densities	DBT with 2DSM	FFDM
Interobserver agreement (Cohen's $\kappa$ )	0.96	0.95
Visibility score (median, interquartile range)	5 (4–5)	3 (2–4)

DBT = digital breast tomosynthesis, FFDM = full-field digital mammography, 2DSM = two-dimensional synthesized mammogram

**Fig. 1.** A 58-year-old female with stereotactic vacuum-assisted breast biopsy for suspicious fine pleomorphic calcifications in the right upper-mid breast.

**A-D.** Fine pleomorphic calcifications (arrows) in the right upper-mid breast are more clearly visible on digital breast tomosynthesis with 2DSM (**A, C**) than FFDM (**B, D**). Both readers given a visibility score of 4 for 2DSM while a score of 2 for FFDM.

FFDM = full-field digital mammography, 2DSM = two-dimensional synthesized mammogram



diagnostic performance over FFDM in non-dense breasts, but without statistical significance (88.8% vs. 82.3%;  $\chi^2 = 0.532$ ;  $p = 0.4852$ ) (Table 4).

## DIAGNOSTIC VISIBILITY OF MICROCALCIFICATIONS FOR DBT WITH 2DSM AND FFDM

The weighted  $\kappa$  statistic for inter-observer agreement was 0.9559, and DBT with 2DSM showed greater lesion visibility (median, 5 points; interquartile range, 4–5 points) than FFDM (median, 3 points; interquartile range, 2–4 points;  $p < 0.01$ ) (Table 5, Fig. 1).

## DISCUSSION

Specific recognition and characterization of microcalcifications play an important role in diagnosing breast malignancy. Stereotactic biopsy is a precise technique for sampling breast



microcalcifications and constitutes a better alternative to traditional surgical excision (17). Suspicious breast lesions undergo frequent ultrasound-guided biopsy; however, certain microcalcifications are not verifiable using this method and require stereotactic biopsy (18).

Our single-center study sought to approve the diagnostic accuracy of DBT with 2DSM relative to that of FFDM for suspicious breast microcalcifications in advance of stereotactic biopsy. As a final outcome, DBT with 2DSM can increase the sensitivity and specificity rates in diagnosing suspicious breast microcalcifications, especially benign microcalcifications in dense breasts. The diagnostic sensitivities of DBT with 2DSM and FFDM were 92.6% and 88.8%, respectively, while the specificities were 87.4% and 75.5%, with significant differences. DBT with 2DSM demonstrated a notable increase in diagnostic accuracy among all cases (88.8%) versus FFDM (79.3%). The difference in diagnostic accuracy for determining benign microcalcifications also was significant between DBT with 2DSM and FFDM, but this was not true for malignant microcalcifications. Choi et al. (19) reported that there was no difference in observer sensitivity between DBT and FFDM in detecting invasive breast cancer. Our results are concordant with previous studies reporting that DBT and FFDM show no difference in detecting malignant lesions. Also, previous studies have reported malignancy rates ranging from 10% to 39%, similar to our result (20, 21). In this study, among suspicious breast microcalcifications, 54 (29%) were identified as malignant and 135 (71%) were identified as benign.

Many studies have focused on the clinical performance of DBT and FFDM. Clauser et al. (22) reported that DBT and FFDM showed no notable differences in detecting and characterizing microcalcifications. Also, these authors concluded that DBT had a similar diagnostic accuracy to that of FFDM, but there was an inter-reader difference between the two modalities. Our study results showed a very high rate of inter-observer agreement, inconsistent with Clauser et al. (22) study, but it remains an issue whether inter-reader variability impacts the diagnostic success rate. In addition, few studies have suggested that, when predicting the probability of malignancy, inter-reader variability does not affect the difference in sensitivity, or specificity between the methods (23). During clinical application, decisive identification of microcalcifications on mammography depends upon operator experience. The two radiologists in our study both had considerable experience (> 5 years) with analyzing DBT with 2DSM images, which might have decreased inter-reader variability and ensured more reliable BI-RADS categorization.

Images acquisition of DBT with a narrow scan-angle, as was used in this study, allows better visualization of small-scale structures, like microcalcifications (24). Narrow-angle DBT has a greater ability to delineate detailed diameter data compared to wide-angle DBT (25). The DBT system provides wide variable visualization of microcalcifications, which is reliant on number of projections, number of projections, detector characteristics, and reconstruction algorithms. A wide scan-angle induces a larger radiation dose due to more projections and data, which can increase the noise and reduce the visibility of small-scale compositions, such as microcalcifications (24).

In this study, significant differences were observed in lesion visibility assessment between the two imaging modalities. DBT with 2DSM led to better image visibility than did FFDM, consistent with the result of studies reporting that DBT images showed better conspicuity than FFDM images in as many as 92.2% of patients (10, 26, 27). Hence, DBT is known to be

more efficient in detecting malignancy and reducing the recall rate (28, 29). Based on previous studies, DBT with 2DSM is a suitable method for evaluation and visualization of microcalcifications (30, 31). Moreover, this result underpins that DBT with 2DSM has superiority over FFDM in localizing lesions for targeted biopsies such as in stereotactic biopsy. Furthermore, in patients with dense breasts, FFDM showed difficulty in overcoming limitations of overlapping breast parenchyma mimicking suspicious asymmetries and obscuring noncalcified lesions. Accordingly, these results indicate that DBT with 2DSM can minimize unnecessary imaging or biopsies.

It is known that DBT assists radiologists in increasing their ability to reduce recall rates and the need for additional procedures (32, 33). Also, a previous study by Viala et al. (34) reported that DBT can detect suspicious BI-RADS 4 and BI-RADS 5 lesions not visualized on FFDM and indicate whether to biopsy these lesions. Meanwhile, in the present study, readers classified suspicious microcalcifications using BI-RADS categories 4A to 5 and evaluated the possibility of malignancy and the necessity for stereotactic biopsy. Both DBT with 2DSM and FFDM led cases to be classified into mostly BI-RADS 4B, 4C, and 5 categories for malignant calcification, which helps to avoid delay in diagnosing the disease. For the pathologically confirmed benign lesions, FFDM classified a significant proportion into the BI-RADS 4B category, which led to unnecessary biopsies. This result suggests that, in benign conditions such as microcalcifications, DBT has the advantage of avoiding unnecessary biopsies, and it supports findings from Tagliafico and Houssami (9).

In dense breasts, DBT with 2DSM images showed greater diagnostic accuracy than FFDM images, but this was not the case in non-dense breasts. This implies a diagnostic advantage of DBT with 2DSM in female with dense breasts. For these patients, DBT with 2DSM offers more promising benefits than FFDM in terms of reducing recall rates in screening mammography, improving cancer detection, increasing sensitivity by eliminating overlapping tissue, and limiting the number of biopsies (35).

Overall, our study supports previous studies suggesting that DBT can identify certain mammographic abnormalities that might not be well evaluated by or seen on FFDM, such as microcalcifications, and has superiority in dense breasts. Using only obtained stereotactic biopsy breast lesions and showing similar outcomes to previous studies with cases confirmed through surgical biopsy, this study reveals that DBT with 2DSM has significant clinical diagnostic performance for breast microcalcifications prior to mandatory biopsy, especially in the context of stereotactic biopsy.

However, there are several limitations to our study. First, our patients included only those who underwent stereotactic biopsy for suspicious microcalcifications (BI-RADS 4A category or above), and those classified in the BI-RADS 2 or 3 category by either DBT with 2DSM or FFDM were excluded, which led to an inevitable participant selection bias. Second, this was a retrospective single-center study with a small cohort of patients with no randomization of study participants, which might not be representative of the general population or clinical problems. Third, this study used its own rating system for visibility of microcalcifications, which has not been officially validated, and results might be subjective. Lastly, as the aim was to focus on pathological confirmation of suspicious microcalcifications, cases were selected carefully to allow a focused and objective evaluation of detection. Further studies from

other centers are recommended to validate these findings. Despite these limitations, the results of this study provide clues not only in diagnostic performance, but also in clinical operations such as stereotactic biopsy of suspicious breast microcalcifications.

In conclusion, this study showed that DBT with 2DSM enabled greater total diagnostic accuracy and better visibility of suspicious breast microcalcifications compared to the conventional FFDM option. Especially, DBT with 2DSM exhibited advantages in benign microcalcifications and in female with dense breasts. The direct comparison of these two imaging modalities suggests a promising role for DBT with 2DSM as an accommodating tool for stereotactic biopsy for female with suspicious breast microcalcifications in dense breasts. Thus, the findings will assist clinicians in selecting optimal techniques for different patients and further support the use of DBT with 2DSM in either a clinical or screening environment as a primary imaging modality.

### Author Contributions

Conceptualization, S.H.S., W.O.H.; data curation, S.J., S.H.S., W.O.H.; formal analysis, S.J., S.H.S., W.O.H.; investigation, S.J., S.H.S., W.O.H.; methodology, S.H.S., W.O.H.; project administration, W.O.H.; resources, S.J., S.H.S., W.O.H.; supervision, W.O.H.; writing—original draft, S.J.; and writing—review & editing, all authors.

### Conflicts of Interest

Kyu Ran Cho has been a Editorial Board Member of the Journal of the Korean Society of Radiology since 2013; however, she was not involved in the peer reviewer selection, evaluation, or decision process of this article. Otherwise, no other potential conflicts of interest relevant to this article were reported.

### Funding

None

## REFERENCES

1. Tse GM, Tan PH, Cheung HS, Chu WC, Lam WW. Intermediate to highly suspicious calcification in breast lesions: a radio-pathologic correlation. *Breast Cancer Res Treat* 2008;110:1-7
2. Carney PA, Miglioretti DL, Yankaskas BC, Kerlikowske K, Rosenberg R, Rutter CM, et al. Individual and combined effects of age, breast density, and hormone replacement therapy use on the accuracy of screening mammography. *Ann Intern Med* 2003;138:168-175
3. Ciatto S, Houssami N, Bernardi D, Caumo F, Pellegrini M, Brunelli S, et al. Integration of 3D digital mammography with tomosynthesis for population breast-cancer screening (STORM): a prospective comparison study. *Lancet Oncol* 2013;14:583-589
4. Friedewald SM, Rafferty EA, Rose SL, Durand MA, Plecha DM, Greenberg JS, et al. Breast cancer screening using tomosynthesis in combination with digital mammography. *JAMA* 2014;311:2499-2507
5. Ohashi R, Nagao M, Nakamura I, Okamoto T, Sakai S. Improvement in diagnostic performance of breast cancer: comparison between conventional digital mammography alone and conventional mammography plus digital breast tomosynthesis. *Breast Cancer* 2018;25:590-596
6. Zuley ML, Bandos AI, Abrams GS, Cohen C, Hakim CM, Sumkin JH, et al. Time to diagnosis and performance levels during repeat interpretations of digital breast tomosynthesis: preliminary observations. *Acad Radiol* 2010;17:450-455
7. Svahn TM, Houssami N, Sechopoulos I, Mattsson S. Review of radiation dose estimates in digital breast tomosynthesis relative to those in two-view full-field digital mammography. *Breast* 2015;24:93-99
8. Gur D, Zuley ML, Anello MI, Rathfon GY, Chough DM, Ganott MA, et al. Dose reduction in digital breast tomosynthesis (DBT) screening using synthetically reconstructed projection images: an observer performance study. *Acad Radiol* 2012;19:166-171

9. Tagliafico A, Houssami N. Digital breast tomosynthesis might not be the optimal modality for detecting microcalcification. *Radiology* 2015;275:618-619
10. Kopans D, Gavenonis S, Halpern E, Moore R. Calcifications in the breast and digital breast tomosynthesis. *Breast J* 2011;17:638-644
11. Choi JS, Han BK, Ko EY, Kim GR, Ko ES, Park KW. Comparison of synthetic and digital mammography with digital breast tomosynthesis or alone for the detection and classification of microcalcifications. *Eur Radiol* 2019;29:319-329
12. Ho CP, Tromans C, Schnabel JA, Brady M. Classification of clusters of microcalcifications in digital breast tomosynthesis. *Annu Int Conf IEEE Eng Med Biol Soc* 2010;2010:3166-3169
13. Kettritz U, Rotter K, Schreer I, Murauer M, Schulz-Wendtland R, Peter D, et al. Stereotactic vacuum-assisted breast biopsy in 2874 patients: a multicenter study. *Cancer* 2004;100:245-251
14. Rotter K, Haentschel G, Koethe D, Goetz L, Bornhofen-Pöschke A, Lebrecht A, et al. Evaluation of mammographic and clinical follow-up after 755 stereotactic vacuum-assisted breast biopsies. *Am J Surg* 2003;186:134-142
15. Elezaby M, Li G, Bhargavan-Chatfield M, Burnside ES, DeMartini WB. ACR BI-RADS assessment category 4 subdivisions in diagnostic mammography: utilization and outcomes in the national mammography database. *Radiology* 2018;287:416-422
16. Choi Y, Woo OH, Shin HS, Cho KR, Seo BK, Choi GY. Quantitative analysis of radiation dosage and image quality between digital breast tomosynthesis (DBT) with two-dimensional synthetic mammography and full-field digital mammography (FFDM). *Clin Imaging* 2019;55:12-17
17. Schradling S, Distelmaier M, Dirrichs T, Detering S, Brolund L, Strobel K, et al. Digital breast tomosynthesis-guided vacuum-assisted breast biopsy: initial experiences and comparison with prone stereotactic vacuum-assisted biopsy. *Radiology* 2015;274:654-662
18. Imschweiler T, Hauelsen H, Kampmann G, Rageth L, Seifert B, Rageth C, et al. MRI-guided vacuum-assisted breast biopsy: comparison with stereotactically guided and ultrasound-guided techniques. *Eur Radiol* 2014;24:128-135
19. Choi JS, Han BK, Ko EY, Ko ES, Hahn SY, Shin JH, et al. Comparison between two-dimensional synthetic mammography reconstructed from digital breast tomosynthesis and full-field digital mammography for the detection of T1 breast cancer. *Eur Radiol* 2016;26:2538-2546
20. Esen G, Tutar B, Uras C, Calay Z, İnce Ü, Tutar O. Vacuum-assisted stereotactic breast biopsy in the diagnosis and management of suspicious microcalcifications. *Diagn Interv Radiol* 2016;22:326-333
21. Ferreira VCCS, Etchebere ECSC, Bevilacqua JLB, de Barros N. Suspicious amorphous microcalcifications detected on full-field digital mammography: correlation with histopathology. *Radiol Bras* 2018;51:87-94
22. Clauser P, Nagl G, Helbich TH, Pinker-Domenig K, Weber M, Kapetas P, et al. Diagnostic performance of digital breast tomosynthesis with a wide scan angle compared to full-field digital mammography for the detection and characterization of microcalcifications. *Eur J Radiol* 2016;85:2161-2168
23. Dibble EH, Lourenco AP, Baird GL, Ward RC, Maynard AS, Mainiero MB. Comparison of digital mammography and digital breast tomosynthesis in the detection of architectural distortion. *Eur Radiol* 2018;28:3-10
24. Hadjipanteli A, Elangovan P, Looney PT, Mackenzie A, Wells K, Dance DR, et al. Detection of microcalcification clusters by 2D-mammography and narrow and wide angle digital breast tomosynthesis. *Medical Imaging* 2016;9783:978306
25. Sechopoulos I, Ghatti C. Optimization of the acquisition geometry in digital tomosynthesis of the breast. *Med Phys* 2009;36:1199-1207
26. Destounis SV, Arieno AL, Morgan RC. Preliminary clinical experience with digital breast tomosynthesis in the visualization of breast microcalcifications. *J Clin Imaging Sci* 2013;3:65
27. Svane G, Azavedo E, Lindman K, Urech M, Nilsson J, Weber N, et al. Clinical experience of photon counting breast tomosynthesis: comparison with traditional mammography. *Acta Radiol* 2011;52:134-142
28. Kopans DB. Digital breast tomosynthesis from concept to clinical care. *AJR Am J Roentgenol* 2014;202:299-308
29. Spangler ML, Zuley ML, Sumkin JH, Abrams G, Ganott MA, Hakim C, et al. Detection and classification of calcifications on digital breast tomosynthesis and 2D digital mammography: a comparison. *AJR Am J Roentgenol* 2011;196:320-324
30. Timberg P, Baath M, Andersson I, Mattsson S, Tingberg A, Ruschin M. Visibility of microcalcification clusters

and masses in breast tomosynthesis image volumes and digital mammography: a 4AFC human observer study. *Med Phys* 2012;39:2431-2437

31. Cockmartin L, Marshall NW, Van Ongeval C, Aerts G, Stalmans D, Zanca F, et al. Comparison of digital breast tomosynthesis and 2D digital mammography using a hybrid performance test. *Phys Med Biol* 2015;60: 3939-3958
32. Bernardi D, Ciatto S, Pellegrini M, Tuttobene P, Fanto' C, Valentini M, et al. Prospective study of breast tomosynthesis as a triage to assessment in screening. *Breast Cancer Res Treat* 2012;133:267-271
33. Andersson I, Ikeda DM, Zackrisson S, Ruschin M, Svahn T, Timberg P, et al. Breast tomosynthesis and digital mammography: a comparison of breast cancer visibility and BIRADS classification in a population of cancers with subtle mammographic findings. *Eur Radiol* 2008;18:2817-2825
34. Viala J, Gignier P, Perret B, Hovasse C, Hovasse D, Chancelier-Galan MD, et al. Stereotactic vacuum-assisted biopsies on a digital breast 3D-tomosynthesis system. *Breast J* 2013;19:4-9
35. Seo M, Chang JM, Kim SA, Kim WH, Lim JH, Lee SH, et al. Addition of digital breast tomosynthesis to full-field digital mammography in the diagnostic setting: additional value and cancer detectability. *J Breast Cancer* 2016;19:438-446

## 정위적 유방 조직검사 시 미세석회화 의심 병변에서의 디지털 유방단층영상합성법과 전역 디지털 유방촬영술의 진단능 비교

신지원<sup>1</sup> · 우옥희<sup>1\*</sup> · 신혜선<sup>1</sup> · 송성은<sup>2</sup> · 조규란<sup>2</sup> · 서보경<sup>3</sup>

**목적** 본 연구는 미세석회화가 의심되는 유방에서 정위적 조직검사에 앞서서 시행하는 디지털 유방단층영상합성법(digital breast tomosynthesis with the two-dimensional synthesized mammogram; 이하 DBT with 2DSM)과 전면디지털유방촬영술(full-field digital mammography; 이하 FFDM)의 진단능을 비교 평가하고 영상의 진단적 명확도를 평가하기 위해서 시행하였다

**대상과 방법** 2015년 1월에서 2020년 1월까지 후향적 연구로서 189명의 환자 중 정위적 조직검사를 통한 조직병리검사상 미세석회화 병변이 확인된 환자를 중 DBT with 2DSM나 FFDM을 시행한 환자군에서 시행되었다. 두 명의 영상의학과 의사가 눈가림 상태로, Breast Imaging Reporting and Data System (BI-RADS) 분류에 따른 미세석회화의 평가 및 본 연구에서 별도로 1-5점 척도를 통해 정의한 진단적 명확도에 대한 평가를 시행하였다.

**결과** 전반적인 검사자간 일치도는 우수한 것으로 확인되었다. 맥네머 검정에서 양성가능성이 높은 미세석회화(4B, 4C, or 5)의 검출에 있어서는 두 진단방법 간에 통계적 유의성은 보이지 않았으나, 양성가능성이 높은 미세석회화(4A)의 진단에 있어서는 통계적 유의성을 보였다. DBT with 2DSM는 FFDM보다 더 높은 가시성을 보임이 확인되었고, 치밀유방에서도 FFDM보다 진단에 있어서 더 우수하였다.

**결론** DBT with 2DSM는 FFDM과 비교하여 미세석회화 병변에 대해서 더 높은 전반적 진단적 정확도와 진단적 명확성을 제공하였다. DBT with 2DSM는 FFDM보다 양성 미세석회화 병변에서와 치밀유방에서 우수성을 보였다. 본 연구에서는 치밀 유방에서 미세석회화 병변에 대해서 정위적 생검을 시행할 때 유용한 진단 기구로서의 DBT with 2DSM의 역할을 확인할 수 있었다.

<sup>1</sup>고려대학교 의과대학 구로병원 영상의학과,

<sup>2</sup>고려대학교 의과대학 안암병원 영상의학과,

<sup>3</sup>고려대학교 의과대학 안산병원 영상의학과