

Quantitative MRI findings indicate diffuse white matter damage in Susac Syndrome

P Johnson , JK Chan, IM Vavasour , S Abel , LE Lee , H Yong, C Laule, DKB Li, R Tam, A Traboulsee, RL Carruthers  and SH Kolind

Multiple Sclerosis Journal—
Experimental, Translational and
Clinical

January–March 2022, 1–8

DOI: 10.1177/20552173221078834

© The Author(s), 2022.
Article reuse guidelines:
sagepub.com/journals-permissions

Abstract

Background: Susac Syndrome (SuS) is an autoimmune endotheliopathy impacting the brain, retina and cochlea that can clinically mimic multiple sclerosis (MS).

Objective: To evaluate non-lesional white matter demyelination changes in SuS compared to MS and healthy controls (HC) using quantitative MRI.

Methods: 3T MRI including myelin water imaging and diffusion basis spectrum imaging were acquired for 7 SuS, 10 MS and 10 HC participants. Non-lesional white matter was analyzed in the corpus callosum (CC) and normal appearing white matter (NAWM). Groups were compared using ANCOVA with Tukey correction.

Results: SuS CC myelin water fraction (mean 0.092) was lower than MS(0.11, $p = 0.01$) and HC(0.11, $p = 0.04$). Another myelin marker, radial diffusivity, was increased in SuS CC(0.27 $\mu\text{m}^2/\text{ms}$) compared to HC(0.21 $\mu\text{m}^2/\text{ms}$, $p = 0.008$) and MS(0.23 $\mu\text{m}^2/\text{ms}$, $p = 0.05$). Fractional anisotropy was lower in SuS CC(0.82) than HC(0.86, $p = 0.04$). Fiber fraction (reflecting axons) did not differ from HC or MS. In NAWM, radial diffusivity and apparent diffusion coefficient were significantly increased in SuS compared to HC($p < 0.001$ for both measures) and MS($p = 0.003$, $p < 0.001$ respectively).

Conclusions: Our results provided evidence of myelin damage in SuS, particularly in the CC, and more extensive microstructural injury in NAWM, supporting the hypothesis that there are widespread microstructural changes in SuS syndrome including diffuse demyelination.

Keywords : Susac syndrome, MRI, neuroimaging, multiple sclerosis, myelin water imaging, diffusion basis spectrum imaging, demyelination

Date received: 16 July 2021; accepted: 21 January 2022

Introduction

Susac Syndrome (SuS) is a rare autoimmune endotheliopathy of the brain, retina and cochlea.^{1,2} It causes branch retinal artery occlusions, hearing loss, and protean central nervous system dysfunction. Snowball-like lesions in the corpus callosum (CC) can be observed on conventional magnetic resonance imaging (MRI) scans.¹ SuS is a clinical mimic of multiple sclerosis (MS).

Relatively little is known about the microstructural brain damage in SuS. One reported case with brain biopsy showed demyelination in the perivenular white matter (WM) with relative preservation of

axons.³ Advanced MRI techniques can be used to probe tissue damage in SuS non-invasively. Myelin water imaging (MWI) can be used to measure the myelin water fraction (MWF), the ratio of magnetic resonance signal from the water between the myelin bilayers to the total water signal.⁴ MWF has been histopathologically validated as being a myelin-specific marker in human post-mortem tissue as well as preclinical models.^{4,5} Diffusion Tensor Imaging (DTI) is sensitive to microstructural architecture and reflects not only myelin, but also fibre coherence, axonal density, and membrane permeability.^{6,7} Previous DTI studies demonstrated decreased fiber integrity of the non-lesional WM in SuS patients,

Correspondence to:
Poljanka Johnson,
Department of Medicine
(Neurology), University of
British Columbia, M10-2221
Westbrook Mall, Vancouver,
BC, V6T 2B5, Canada
poljanka.johnson@ubc.ca

P Johnson,
JK Chan,
Department of Medicine
(Neurology), University of
British Columbia, Canada

IM Vavasour,
Department of Radiology,
University of British
Columbia, Canada
International Collaboration on
Repair Discoveries (ICORD)



S Abel,
LE Lee,
H Yong,
Department of Medicine
(Neurology), University of
British Columbia, Canada

C Laule,
Department of Radiology,
University of British
Columbia, Canada
International Collaboration on
Repair Discoveries (ICORD)
Department of Pathology and
Laboratory Medicine,
University of British
Columbia, Canada
Department of Physics and
Astronomy, University of
British Columbia, Canada

DKB Li,
Department of Medicine
(Neurology), University of
British Columbia, Canada
Department of Radiology,
University of British
Columbia, Canada

R Tam,
Department of Radiology,
University of British
Columbia, Canada
School of Biomedical
Engineering, University of
British Columbia, Canada

A Trabousee,
RL Carruthers,
Department of Medicine
(Neurology), University of
British Columbia, Canada

SH Kolind,
Department of Medicine
(Neurology), University of
British Columbia, Canada
Department of Radiology,
University of British
Columbia, Canada
International Collaboration on
Repair Discoveries (ICORD)
Department of Physics and
Astronomy, University of
British Columbia, Canada

particularly in the CC, compared to healthy controls (HC).^{8,9} Diffusion basis spectrum imaging (DBSI) is a recent advancement on DTI that can simultaneously quantify axonal injury, myelination, inflammation and oedema by modeling myelinated and unmyelinated axons as anisotropic diffusion tensors, and cells and extracellular space as isotropic diffusion tensors.¹⁰ Traditional DTI measurements can be extracted from DBSI with improved sensitivity and specificity since the confounding effects of inflammation are independently modeled as isotropic diffusion tensors. Fractional anisotropy (FA) is a measure of the degree of anisotropic diffusion of the water molecules;¹¹ generally, reduced FA is associated with WM damage.¹¹ Radial diffusivity (RD) increases with myelin damage.¹⁰ The apparent diffusion coefficient (ADC) measures overall diffusion and is indicative of non-specific overall tissue damage.¹² DBSI additionally estimates several other parameters. The fiber fraction (FF) measures fiber density and is a marker of axonal integrity.¹⁰ The hindered isotropic fraction (HIF) is thought to represent water accumulation in the extra-cellular space which could be representative of edema.¹² The restricted isotropic fraction (RIF) refers to intra-cellular water, which is found in microglia and other inflammatory cells.¹⁰ Axial diffusivity (AD) is another measure extracted from DBSI, however this measure has not been associated with a particular pathology in demyelinating diseases.¹³

Myelin loss in normal appearing white matter (NAWM) in Susac syndrome has not been previously investigated, or reported outside the brain biopsy.³ Our study used advanced MRI to more specifically investigate the biological underpinnings of previously reported decreased fractional anisotropy in SuS.⁹ We hypothesize that the macrostructural changes observed in SuS are due to myelin loss both within the CC and diffusely throughout the NAWM. Thus, we investigated MWF and DBSI metrics in the CC and NAWM in SuS compared to MS and HC.

Materials and methods

Participants

Seven participants with SuS were recruited for this study: 2 with definite SuS and 5 with probable SuS following the proposed European Susac Consortium diagnostic criteria.¹⁴ Data was also collected from 10 MS (MS subtype: 8 relapsing-remitting, 1 primary progressive, 1 sary progressive) and 20 HC participants (Table 1). The HC group was collated from 2 different studies such that 10 HC had DBSI data, and 10 HC had MWI data. There was no

overlap between HC groups. All studies were approved by the University of British Columbia Clinical Research Ethics Board and all participants provided written informed consent.

MRI

MRI scans were performed using a Philips Achieva 3.0T system (Philips Healthcare, Best, Netherlands) with an 8-channel SENSE head coil. MWI data were acquired with a 48-echo 3D gradient and spin echo (GRASE) sequence (TR = 1073 ms, echo spacing = 8 ms, 20 slices acquired at $1 \times 2 \times 5$ mm reconstructed to 40 slices at $1 \times 1 \times 2.5$ mm³).¹⁵ DBSI data were acquired with echo-planar diffusion weighted sequence with 99 diffusion encoding directions (range of b-values 0–1500s/mm², TR = 4943ms, TE = 85ms, voxel size = $2 \times 2 \times 2$ mm³, 40 slices). A 3DT₁-weighted scan (whole-brain 3D magnetization-prepared rapid gradient-echo (MPRAGE), TR = 3000 ms, inversion time (TI) = 1072 ms, $1 \times 1 \times 1$ mm³ voxel, 160 slices) was collected for tissue segmentation and spatial normalization. Sample images of 3DT₁, MWI, and DBSI-derived ADC shown in Figure 1.

Analysis

MWF maps were generated from the GRASE sequence using an in-house regularized non-negative least-squares fitting algorithm with stimulated echo correction.¹⁶ MWF was calculated as the area under the T₂ relaxation curve with times between 15 ms and 40 ms over the total area under the T₂ distribution.¹⁵ Eddy current correction on the diffusion data was performed using the FMRIB's FSL tool Top-up.¹⁷ The corrected DBSI data was analyzed using an in-house Matlab package which generated metric maps of FA, RD, AD, ADC, FF, HIF, and RIF.^{12,16}

Non-lesional NAWM masks were created using a method previously applied in MS studies.¹⁸ All images were registered to the GRASE 1st echo image using FMRIB's Linear Image Registration Tool (FLIRT) transformation with 9 degrees of freedom.¹⁹ Non-lesional NAWM masks were created using an automated brain segmentation algorithm (FAST) from the 3DT₁ images using 3 voxel classes.^{18,20} A neurologist (RC) confirmed that the creation of non-lesional NAWM masks removed all T₂-hyperintense lesions in the corpus callosum in SuS. 1 to 2 small (<1mm) non-specific lesions were included in each mask, however as they are so small, they do not drive the results. The 3DT₁ images were registered to

Table 1. Participant demographic information at the time of the MRI scan.

Cohort	N	Mean Age	Sex (F:M)	Mean Disease Duration	Median EDSS
SuS	7	43.5y (range 29-78)	6:1	6.6y (range 2-12)	3.0 (range 1.5-6.0)
MS	10	43.2y (range 26-70)	9:1	14.7y (range 3-33)	2.0 (range 0-6.5)
HC (DBSI)	10	35.9y (range 22-47)	5:5	N/A	N/A
HC (MWI)	10	44.0y (range 27-64)	9:1	N/A	N/A

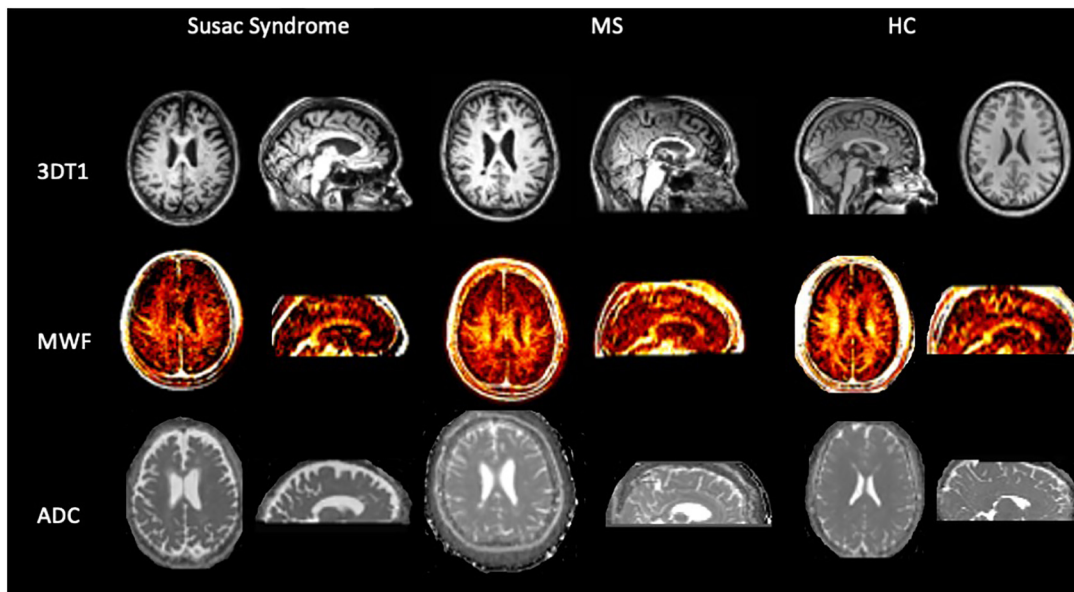


Figure 1. Representative MRI from susac syndrome, multiple sclerosis (MS) and a healthy control (HC). The 3DT1 is used as an anatomical image. The myelin water fraction (MWF) image reflects myelin content (hotter for more myelin).⁴ The apparent diffusion coefficient (ADC) is a measure extracted from diffusion basis spectrum imaging measuring overall diffusion and is indicative of non-specific overall tissue damage.¹²

MNI (standard template) space using FMRIB's Non-Linear Image Registration Tool (FNIRT) with 12 degrees of freedom.²¹ The CC ROIs obtained from the JHU atlas were then warped to GRASE space and multiplied by the WM mask to ensure proper registration of the ROIs and to exclude lesions.²²

Statistical Analysis

Participant demographics were compared using one-way ANOVA. SuS, MS, and HC values for MWF and DBSI metrics were compared using ANCOVA with age as a covariate with a Tukey comparison for multiple groups to correct for false positives. Disease duration was not included as a covariate since age and disease duration were colinear. Homogeneity of variance of the measures was tested with Levene's test Normality of the

measures was tested with the Shapiro-Wilks test Statistical significance was defined as $p < 0.05$.

Results

Participant demographics are shown in Table 1. Age was not significantly different between groups. SuS and MS groups were matched for EDSS. The MS group had a longer disease duration ($p = 0.03$).

There were no significant differences detected in any MRI metric between definite and probable SuS (Student's t-test $p > 0.05$). The variances of all measures were homogenous. All metrics in each population were normal except FF(SuS) and ADC(HC). FF was analyzed with non-parametric ANCOVA and the difference was not significant ($p = 0.12$). One outlier in the HC population violated normality; removing this data point allowed the population to conform to normality and did not change the ANCOVA results (significance

values do not change to the third decimal point). Mean MRI metrics and p-values for comparisons between groups are reported in Table 2, with boxplots illustrating group differences for each MRI metric between groups for CC in Figure 2 and NAWM in Figure 3.

Sus vs HC

Myelin metrics: CC MWF was 16% lower in the SuS group (mean ± standard deviation = 0.092 ± 0.01) compared to HC (0.11 ± 0.02 , $p=0.04$) (Figure 2(a)) while NAWM MWF demonstrated a trend-level 13% reduction ($p=0.1$, Figure 3(a)). RD was 15% higher in SuS CC compared to HC (SuS $0.27 \pm 0.03 \mu\text{m}^2/\text{ms}$ vs HC $0.21 \pm 0.01 \mu\text{m}^2/\text{ms}$, $p=0.008$ (Figure 2(b))) and 12% higher in NAWM (SuS 0.33 ± 0.02 vs HC $0.29 \pm 0.01 \mu\text{m}^2/\text{ms}$, $p<0.001$) (Figure 3(b)).

Tissue integrity metrics: The FA of SuS CC (0.82 ± 0.02) was 5% lower than HC (0.86 ± 0.02 , $p=0.02$) (Figure 2(c)) and demonstrated a trend-level 3% reduction in NAWM ($p=0.08$) (Figure 3(c)). ADC was 15% higher in the CC (0.84 ± 0.08 vs $0.71 \pm 0.04 \mu\text{m}^2/\text{ms}$, $p<0.001$) and 8% higher in NAWM (0.74 ± 0.04 vs $0.68 \pm 0.02 \mu\text{m}^2/\text{ms}$, $p<0.001$) for SuS compared to controls (Figure 3(d)).

Axonal metric: FF did not differ between SuS and HC.

Sus vs MS

Compared to MS, there was lower MWF and a higher RD and ADC in the CC and the NAWM while the NAWM only showed a lower MWF and higher RD and ADC for SuS (Table 2). FF did not differ between SuS and MS.

Discussion

We investigated the extent and nature of any damage to non-lesional white matter tissue in SuS. In this study, SuS patients had increased ADC values in non-lesion CC and NAWM and lower FA in the CC, which is consistent with the decreased fiber integrity described in earlier studies.^{8,9} The increased RD in both the CC and NAWM and the trend of decreased MWF in the CC suggests that demyelination contributes to the pathology of Susac syndrome. While in an increase in RD is generally related to a decrease in myelin, the increase in RD in the NAWM can also be attributed to tissue ischemia without the corroborating MWF results. FF, which represents fiber density, a putative axonal biomarker, was not significantly decreased in this small cohort, suggesting that

Table 2. Table of corpus Callosum results and normal appearing white matter results.

	Healthy Controls	Susac Syndrome	p-value SuS vs HC	Multiple Sclerosis	p-value SuS vs MS
Corpus Callosum					
MWF	0.11 ± 0.02	0.092 ± 0.01	$p = 0.04$	0.11 ± 0.02	$p = 0.01$
RD $\mu\text{m}^2/\text{ms}$	0.21 ± 0.03	0.27 ± 0.01	$p = 0.008$	0.23 ± 0.05	$p = 0.05$
FA	0.86 ± 0.02	0.82 ± 0.02	$p = 0.04$	0.85 ± 0.04	$p = 0.2$
ADC $\mu\text{m}^2/\text{ms}$	0.71 ± 0.04	0.84 ± 0.08	$p < 0.001$	0.73 ± 0.04	$p < 0.001$
FF	0.72 ± 0.05	0.69 ± 0.03	$p = 0.6$	0.73 ± 0.09	$p = 0.4$
RIF	0.037 ± 0.007	0.030 ± 0.004	$p = 0.1$	0.034 ± 0.008	$p = 0.4$
HIF	0.11 ± 0.04	0.12 ± 0.002	$p = 0.99$	0.12 ± 0.07	$p = 0.99$
Normal Appearing White Matter					
MWF	0.11 ± 0.02	0.096 ± 0.01	$p = 0.12$	0.12 ± 0.02	$p = 0.023$
RD $\mu\text{m}^2/\text{ms}$	0.29 ± 0.01	0.33 ± 0.02	$p < 0.001$	0.30 ± 0.01	$p = 0.003$
FA	0.78 ± 0.01	0.76 ± 0.01	$p = 0.08$	0.77 ± 0.02	$p = 0.3$
ADC $\mu\text{m}^2/\text{ms}$	0.68 ± 0.02	0.74 ± 0.04	$p < 0.001$	0.69 ± 0.02	$p < 0.001$
FF	0.64 ± 0.03	0.63 ± 0.03	$p > 0.05$	0.65 ± 0.02	$p > 0.05$
RIF	0.054 ± 0.004	0.046 ± 0.006	$p = 0.01$	0.051 ± 0.005	$p = 0.08$
HIF	0.19 ± 0.03	0.19 ± 0.009	$p = 0.99$	0.18 ± 0.02	$p = 0.6$

Legend: Myelin Water Fraction (MWF) decreases with demyelination; Radial Diffusivity (RD) increases with myelin damage; Fractional Anisotropy (FA) decreases with demyelination and axonal damage; Apparent Diffusion Coefficient (ADC) increases with overall tissue damage; Fiber Fraction (FF) decreases with loss of axons; Restricted Isotropic Fraction (RIF) increases with increased cellularity (e.g. microglia or inflammation); Hindered Isotropic Fraction (HIF) increases with edema. **BOLD** for significant differences between cohorts.

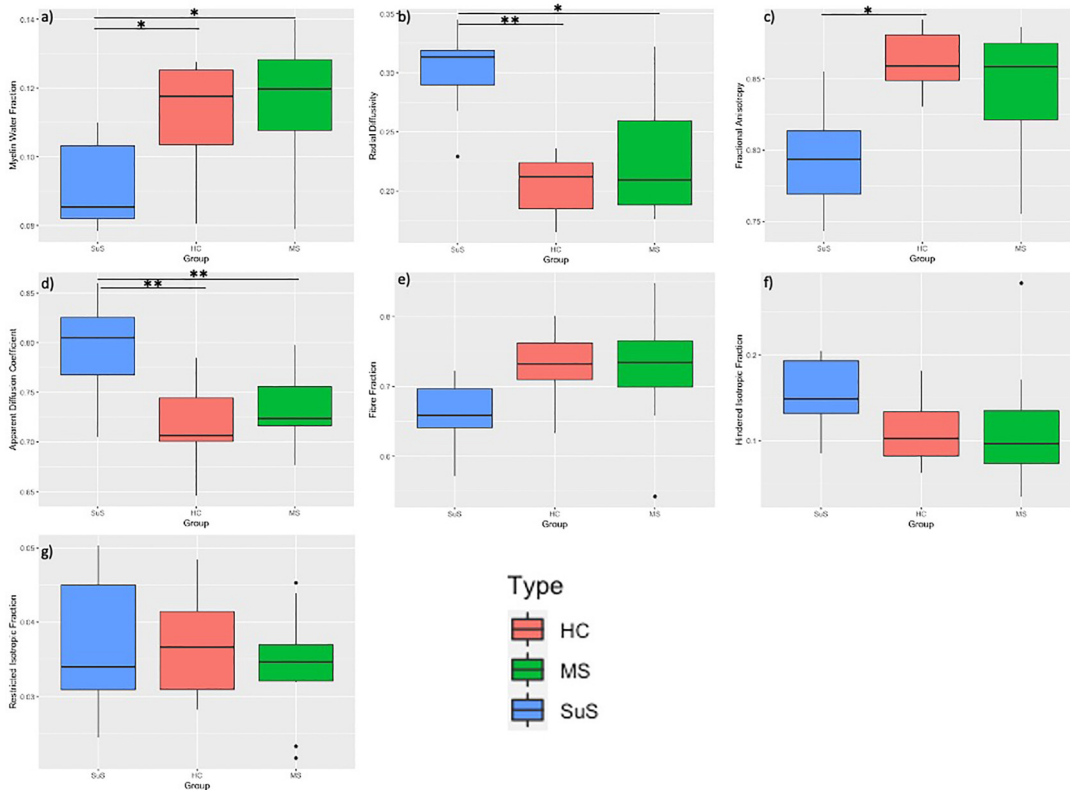


Figure 2. Advanced imaging results for the corpus callosum (CC) for controls (HC), multiple sclerosis (MS) and susac syndrome (SuS) participants. Significant results are a) Myelin water fraction (MWF). MWF of the CC of SuS (0.092 ± 0.01) was significantly lower than HC (0.11 ± 0.02) ($p = 0.04$) MS (0.11 ± 0.02) ($p = 0.01$). b) Radial diffusivity (RD). RD in SuS (0.27 ± 0.03) was significantly higher compared to HC (0.21 ± 0.01) ($p = 0.008$) and MS (0.23 ± 0.05) ($p = 0.05$). c) Fractional anisotropy (FA). FA of SuS (0.82 ± 0.02) was significantly lower than HC (0.86 ± 0.02) ($p = 0.04$). d) Apparent diffusion coefficient (ADC). ADC in the CC of SuS (0.84 ± 0.08) was significantly increased compared to MS (0.73 ± 0.04) and controls (0.71 ± 0.04) ($p < 0.001$ for both). * $p < 0.01$, ** $p < 0.001$.

axon integrity is relatively preserved. Nor was there evidence of global edema (increase in hindered isotropic fraction) or an increase in inflammatory cells (restricted isotropic fraction). Taken together, these findings increase the specificity of previous DTI findings and are consistent with the previous brain biopsy study, which showed demyelination with relative preservation of axons in SuS CC.³

This study had a few limitations. The sample size was small as the diagnosis is rare. Another limitation is that the MS group had a significantly longer disease duration than the SuS group, which is a discrepancy between the groups. Despite the longer disease duration in MS, SuS showed greater changes in the MRI parameters, strengthening the interpretation of increased tissue damage (particularly myelin) in SuS compared to MS. The DBSI controls contained a different sex ratio compared to the SuS and MS groups. Previous studies have not found sex dependent differences in the diffusion tensor metrics except FA, where

some regions of the corpus callosum show higher FA for each sex.²³ The MWF showed this same regional dependency, however no conclusion was drawn for the whole CC.²³ Furthermore, more extensive MWI studies have not shown sex dependent myelin content differences in HC or MS.^{24,25} MWF was not significantly decreased in SuS NAWM compared to healthy controls; this is likely due the large amount of heterogeneity in myelin across NAWM and between individuals, thus sometimes requiring large groups or severe disease courses to find group differences cross-sectionally.²⁶ Similarly, this study did not detect a significant decrease in MS NAWM compared to HC, which is in contrast to some previous studies,^{27,28} but is not consistently the case, depending on group size, age, disease severity, etc.¹⁸ MWF varies greatly between regions and individuals including healthy controls, and thus differences can be washed out when looking across a large heterogeneous ROI such as all NAWM.¹⁸ When narrowing the scope from NAWM to the CC, a region frequently involved

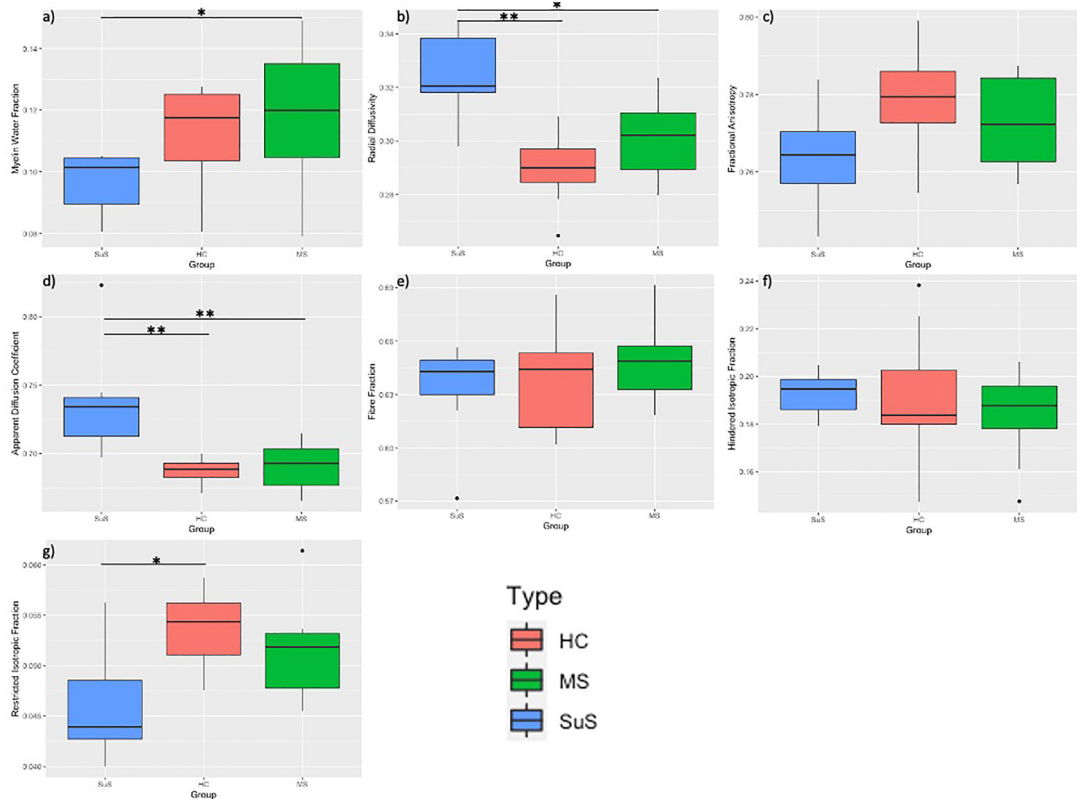


Figure 3. Advanced MRI results for white matter of the whole brain for controls (HC), multiple sclerosis (MS) and susac syndrome (SuS) participants. Significant results are a) Myelin water fraction of white matter. SuS is lower than MS (0.11 ± 0.02) ($p = 0.02$) b) Radial diffusivity (RD) of white matter. RD is higher in SuS (0.33 ± 0.02) compared to HC (0.29 ± 0.01) ($p < 0.001$) and MS (0.30 ± 0.01) ($p = 0.003$). d) The apparent diffusion coefficient (ADC) of white matter. SuS (0.74 ± 0.04) ADC is higher than HC (0.68 ± 0.01) ($p < 0.001$) and MS (0.69 ± 0.02) ($p < 0.001$). g) Restricted isotropic fraction (RIF) of white matter. SuS (0.046 ± 0.006) RIF is lower compared to HC (0.054 ± 0.004) ($p = 0.01$). * $p < 0.01$, ** $p < 0.001$.

in both SuS and MS, the trend toward decreased MWF supports the finding of more myelin damage in SuS.

This study supports the hypothesis that the microstructural damage observed in the CC of SuS patients includes demyelination. The NAWM results illustrate more widespread injury rather than injury focused in the CC. The two mechanisms of injury could either be demyelination or tissue ischemia. Existing data suggests that myelin loss potentially occurs as a secondary process and is a downstream consequence of damage to endothelial cells.^{3,29} Myelin damage has been found near injured blood vessels, which could suggest that demyelination is an epiphenomenon of autoimmune endotheliopathy. However, more brain biopsies are required to confirm this finding.

In patients with probable or definite SuS, the finding of diffuse myelin injury is a novel feature, providing further insight into the scope of the disease; in that it can affect the whole brain rather than only areas

associated with T2 hyperintense lesions. Future natural history and treatment studies of Sus may want to consider advanced imaging measures such as MWI and DWI to monitor global damage not evident on conventional MRI.

Acknowledgements

The authors would like to thank the participants and the MRI technologists at the UBC MRI Research Centre. We would like to thank Dr Woolfenden for his recruitment of Susac participants for our study. We thank Carolyn Taylor (UBC Applied Statistics and Data Science Group) for helpful discussions.

Declaration of conflicting interests






PJ, IV, SA, LL, HY, CL, and AW have nothing to disclose. JC has fellowship funding from Biogen. She has consulted for Roche. AT received funding from Chugai, Roche, Novartis, Genzyme, Biogen. He has received honoraria from Genzyme, Roche, Teva, Biogen and Serono. DL is the Emeritus Director of the UBC MS/MRI Research Group which has been contracted to perform central

analysis of MRI scans for therapeutic trials with Roche and Sanofi-Genzyme. The UBC MS/MRI Research Group has also received grant support for investigator-initiated independent studies from Genzyme, Novartis and Roche. He has acted as a consultant to Vertex Pharmaceuticals and served on the Scientific Advisory Boards for Adelphi Group, Biogen and Celgene. He has given lectures which have been supported by non-restricted education grants from Academy of Health Care Learning, Consortium of MS Centers and Sanofi-Genzyme. RT has received research support as part of sponsored clinical studies from Novartis, Roche and Sanofi Genzyme. RC is a site investigator for studies funded by Novartis, MedImmune and Roche and receives research support from Teva Innovation Canada, Roche Canada and Vancouver Coastal Health Research Institute. He has done consulting work and has received honoraria from Roche, EMD Serono, Sanofi, Biogen, Novartis and Teva. SK has received research funding from Sanofi Genzyme and F. Hoffmann La Roche.

Funding

The author(s) disclosed receipt of the following financial support for the research, authorship, and/or publication of this article: This work was supported by the Multiple Sclerosis Society of Canada (grant number 2302, 3031).

ORCID iDs

P Johnson  <https://orcid.org/0000-0003-4153-428X>
 IM Vavasour  <https://orcid.org/0000-0001-9286-0953>
 S Abel  <https://orcid.org/0000-0001-8547-1415>
 LE Lee  <https://orcid.org/0000-0002-8334-3740>
 RL Carruthers  <https://orcid.org/0000-0001-7085-1001>

References

- Dörr J, Krautwald S, Wildemann B, et al. Characteristics of susac syndrome: a review of all reported cases. *Nat Rev Neurol* 2013; 9: 307–316.
- Buzzard KA, Reddel SW, Yiannikas C, et al. Distinguishing susac's syndrome from multiple sclerosis. *J Neurol* 2015; 262: 1613–1621.
- Ryerson LZ, Kister I, Snuderl M, et al. Incomplete susac syndrome exacerbated after natalizumab. *Neurol Neuroimmunol NeuroInflammation* 2015; 2: –3.
- Laule C, Vavasour IM, Kolind SH, et al. Magnetic resonance imaging of myelin. *Neurotherapeutics* 2007; 4: 460–484.
- Alonso-Ortiz E, Levesque IR and Pike GB. MRI-based myelin water imaging: a technical review. *Magn Reson Med* 2015; 73: 70–81.
- Beaulieu C. The basis of anisotropic water diffusion in the nervous system - A technical review. *NMR Biomed* 2002; 15: 435–455.
- Harsan LA, Poulet P, Guignard B, et al. Brain dysmyelination and recovery assessment by noninvasive in vivo diffusion tensor magnetic resonance imaging. *J Neurosci Res* 2006; 83: 392–402.
- Kleffner I, Deppe M, Mohammadi S, et al. Diffusion tensor imaging demonstrates fiber impairment in susac syndrome. *Neurology* 2008; 70–19(PART 2):1867–1869.
- Kleffner I, Deppe M, Mohammadi S, et al. Neuroimaging in susac's syndrome: focus on DTI. *J Neurol Sci* 2010; 299: 92–96.
- Wang Y, Sun P, Wang Q, et al. Differentiation and quantification of inflammation, demyelination and axon injury or loss in multiple sclerosis. *Brain* 2015; 138: 1223–1238.
- Wang Q, Wang Y, Liu J, et al. Quantification of white matter cellularity and damage in preclinical and early symptomatic Alzheimer's disease. *NeuroImage Clin* 2019; 22: 101767.
- Cross AH and Song SK. A new imaging modality to non-invasively assess multiple sclerosis pathology. *J Neuroimmunol* 2017; 304: 81–85.
- Winklewski PJ, Sabisz A, Naumczyk P, et al. Understanding the physiopathology behind axial and radial diffusivity changes-what do we know? *Front Neurol* 2018; 9: 92.
- Kleffner I, Dörr J, Ringelstein M, et al. Diagnostic criteria for susac syndrome. *J Neurol Neurosurg Psychiatry* 2016; 87: 1287–1295.
- Prasloski T, Rauscher A, MacKay AL, et al. Rapid whole cerebrum myelin water imaging using a 3D GRASE sequence. *Neuroimage* 2012; 63: 533–539.
- Prasloski T, Mädler B, Xiang QS, et al. Applications of stimulated echo correction to multicomponent T2 analysis. *Magn Reson Med* 2012; 67: 1803–1814.
- Smith SM, Jenkinson M, Woolrich MW, et al. Advances in functional and structural MR image analysis and implementation as FSL. *NeuroImage* 2004; 23(Suppl 1): S208–S219. doi:10.1016/j.neuroimage.2004.07.051
- Abel S, Vavasour I, Lee LE, et al. Myelin damage in normal appearing white matter contributes to impaired cognitive processing speed in multiple sclerosis. *J Neuroimaging* 2020; 30: 205–211.
- Jenkinson M, Bannister P, Brady M, et al. Improved optimization for the robust and accurate linear registration and motion correction of brain images. *Neuroimage* 2002; 17: 825–841.
- Zhang Y, Brady M and Smith S. Segmentation of brain MR images through a hidden markov random field model and the expectation-maximization algorithm. *IEEE Trans Med Imaging* 2001; 20: 45–57.
- Andersson JLR, Jenkinson M and Smith S. Non-Linear registration Aka spatial normalisation FMRIB technical report TR07JA2. FMRIB Analysis Group of the University of Oxford; 2007.
- MRI Atlas of Human White Matter - Susumu Mori, S. Wakana, Peter C M van Zijl, L.M. Nagae-Poetscher - Google Books. Accessed July 8, 2020. https://books.google.ca/books?hl=en&lr=&id=ltwRYlvFNLIC&oi=fnd&pg=PR5&ots=gdOLiebLjp&sig=0NJEuVwXD_O1OaGRd7mLqVyPbXc&redir_esc=y#v=onepage&q&f=false.
- Liu F, Vidarsson L, Winter JD, et al. Sex differences in the human corpus callosum microstructure: a combined T2 myelin-water and diffusion tensor magnetic resonance imaging study. *Brain Res* 2010; 1343: 37–45.

24. Dvorak A V, Swift-Lapointe T, Vavasour IM, et al. An atlas for human brain myelin content throughout the adult life span. *Sci Reports* 2021; 11:269.
25. Faizy TD, Thaler C, Kumar D, et al. Heterogeneity of multiple sclerosis lesions in multislice myelin water imaging. *PLoS One* 2016; 11: e0151496.
26. Abel S, Vavasour I, Lee LE, et al. Associations between findings From myelin water imaging and cognitive performance Among individuals With multiple sclerosis. *JAMA Netw open* 2020; 3: e2014220.
27. Oh J, Han ET, Lee MC, et al. Multislice brain myelin water fractions at 3T in multiple sclerosis. *J Neuroimaging* 2007; 17: 156–163.
28. Laule C, Vavasour IM, Moore GRW, et al. Water content and myelin water fraction in multiple sclerosis. A T2 relaxation study. *J Neurol* 2004; 251: 284–293.
29. Agamanolis DP, Prayson RA, Asdaghi N, et al. Brain microvascular pathology in susac syndrome: an electron microscopic study of five cases. *Ultrastruct Pathol* 2019; 43: 229–236.