



Case report

Lung histopathological pattern in a survivor with rapidly progressive interstitial lung disease and anti-melanoma differentiation-associated gene 5 antibody-positive clinically amyopathic dermatomyositis



Atsushi Suzuki^a, Yasuhiro Kondoh^{a,*}, Hiroyuki Taniguchi^a, Kazuhiko Tabata^b, Tomoki Kimura^a, Kensuke Kataoka^a, Kenzo Ono^c, Mikiko Hashisako^b, Junya Fukuoka^b

^a Department of Respiratory Medicine and Allergy, Tosei General Hospital, Seto, Aichi, Japan

^b Department of Pathology, Nagasaki University Graduate School of Biomedical Sciences, Nagasaki, Japan

^c Department of Pathology, Tosei General Hospital, Seto, Aichi, Japan

ARTICLE INFO

Article history:

Received 4 April 2016

Received in revised form

27 May 2016

Accepted 28 May 2016

Keywords:

CADM

RP-ILD

MDA5

Lung histopathological pattern

DAD

ABSTRACT

Anti-melanoma differentiation-associated gene 5 (MDA5) antibodies are specific indicators of patients with dermatomyositis, particularly clinically amyopathic dermatomyositis (CADM). CADM is occasionally accompanied by fatal, treatment-resistant, rapidly-progressive interstitial lung disease (RP-ILD). All previous reports showed that histopathological findings in RP-ILD with anti-MDA5 antibody-positive CADM indicated diffuse alveolar damage (DAD). This is the first report describing a non-DAD pattern in RP-ILD with anti-MDA5 antibody-positive CADM, which was improved by immunosuppressive therapy. This case may be a milder clinical phenotype than a typical DAD pattern in RP-ILD with anti-MDA5 antibody-positive CADM.

© 2016 The Authors. Published by Elsevier Ltd. This is an open access article under the CC BY-NC-ND license (<http://creativecommons.org/licenses/by-nc-nd/4.0/>).

1. Introduction

Anti-melanoma differentiation-associated gene 5 (MDA5) antibodies are specific indicators of patients with dermatomyositis, particularly clinically amyopathic dermatomyositis (CADM) [1–6]. CADM is occasionally accompanied by fatal, treatment-resistant, rapidly-progressive interstitial lung disease (RP-ILD) [7,8]. A few reports have shown that diffuse alveolar damage (DAD) is a histopathological finding in RP-ILD with anti-MDA5 antibody-positive

CADM. However, these findings were confirmed only at autopsy [9,10]. To our knowledge, this is the first case report to show a non-DAD pattern in RP-ILD with anti-MDA5 antibody-positive CADM, which was improved by immunosuppressive therapy.

2. Case report

A 32-year-old woman was referred to our hospital with a 4-week history of fever, cough, and erythematous eruptions. She was a never-smoker and had no significant medical history or environmental risk for respiratory disease. Her physical examination revealed a fever (38.3 °C), facial erythema and heliotrope rash (Fig. 1a), erythema over the V area of the neck (Fig. 1b), scaly erythema with ulceration over the elbow (Fig. 1c), knee, and dorsum of her hands (Gottron's sign) (Fig. 1d), and skin thickening on the sides of her fingers (mechanic hands). There were no signs of muscle weakness. Fine crackles were heard in the bilateral lower lung fields. Arterial blood gas analysis showed normal partial pressure of oxygen and carbon dioxide (73.5 and 38.6 Torr, respectively). The alveolar-arterial oxygen difference was 28 mmHg. The serum levels of C-reactive protein and creatine kinase were not elevated. The serum levels of Krebs von den Lungen-6, lactate dehydrogenase,

Abbreviations: MDA5, melanoma differentiation-associated gene 5; CADM, clinically amyopathic dermatomyositis; RP-ILD, rapidly progressive interstitial lung disease; DAD, diffuse alveolar damage; CT, computed tomography; FVC, forced vital capacity; DLco, diffusing capacity of the lung for carbon monoxide; 6MWD, six-min walk distance; MMRC, modified medical research council dyspnea scale; NSIP, nonspecific interstitial pneumonia; IVCY, intravenous cyclophosphamide.

* Corresponding author. Department of Respiratory Medicine and Allergy, Tosei General Hospital, 160 Nishioiwake-cho, Seto, Aichi, 489-8642, Japan.

E-mail addresses: atsushi-salyu@hotmail.co.jp (A. Suzuki), konyasu2003@yahoo.co.jp (Y. Kondoh), taniguchi@tosei.or.jp (H. Taniguchi), t-kaz@nagasaki-u.ac.jp (K. Tabata), tomoki_kimura@tosei.or.jp (T. Kimura), kataoka@tosei.or.jp (K. Kataoka), byori@tosei.or.jp (K. Ono), mikiko-h@nagasaki-u.ac.jp (M. Hashisako), fukuokaj@nagasaki-u.ac.jp (J. Fukuoka).

<http://dx.doi.org/10.1016/j.rmcr.2016.05.008>

2213-0071/© 2016 The Authors. Published by Elsevier Ltd. This is an open access article under the CC BY-NC-ND license (<http://creativecommons.org/licenses/by-nc-nd/4.0/>).

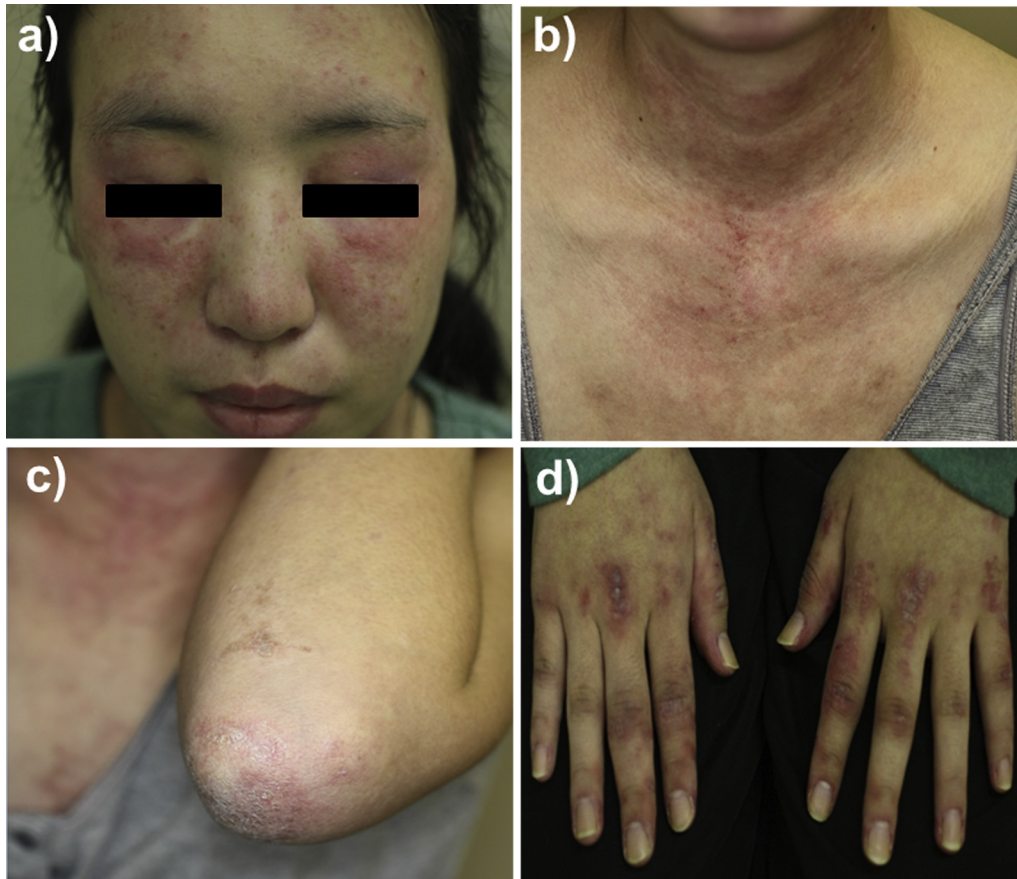


Fig. 1. Physical findings suggestive of clinically amyopathic dermatomyositis. a) facial erythema and heliotrope rash; b) erythema over the V area of the neck; c) scaly erythema with ulceration over the elbow; d) Gottron's sign.

aldolase, and ferritin were increased (726 U/ml, 551 U/l, 10.0 IU/l, and 1269 ng/ml, respectively). Anti-MDA5 antibody was detected (40.7 U/ml > 8 U/ml). Other autoantibodies suggesting autoimmune disorders were not detected. A chest computed tomography (CT) scan showed peribronchovascular ground-glass opacities and bilateral subpleural reticular opacities (Fig. 2). A pulmonary function test indicated normal predicted value for forced vital capacity (%FVC) and decreased predicted value for diffusing capacity of the lung for carbon monoxide (%DLco) (%FVC 86.5%; %DLco 71.9%). Bronchoalveolar lavage was performed in right B9. The total cell count was 1.38×10^5 cells m^{-1} , with a normal cellular profile and

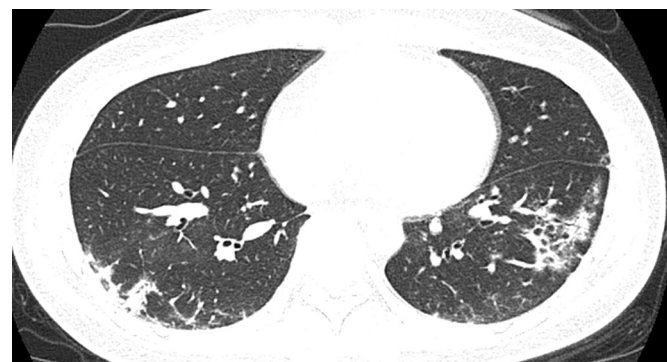


Fig. 2. Chest computed tomography. Peribronchovascular ground-glass opacities and bilateral subpleural reticular opacities.

CD4/CD8 ratio (the percentage of neutrophils and lymphocytes were 2 and 0%, respectively). Microbial culture results from the sputum and bronchoalveolar lavage fluid were negative. Six-min walk distance (6MWD) was 285 m, with 96% of minimum arterial oxygen saturation measured by pulse oximetry. The modified medical research council dyspnea scale (MMRC) was 2. Magnetic resonance imaging of inferior retinaculum of extensor muscles demonstrated muscle edema that was consistent with myositis. In a muscle biopsy, findings of perivascular inflammatory infiltrate and perifascicular muscle fiber atrophy were obtained.

While the definition of CADM by Sontheimer [5] requires that skin disease be present for 6 months without the development of muscle disease, Sontheimer et al. [6] has also described a subset of patients with CADM in whom fatal ILD developed within the first 6 months of their disease course. Although the disease duration was short in our patient, a presumptive diagnosis of CADM with RP-ILD was made on the basis of the described findings. One week after the first visit, in order to determine the histopathological pattern, we performed video-assisted thoracic surgical lung biopsy (SLB) (right S5, 8, 9).

The lesion was characterized by diffuse mild interstitial fibrosis and inflammatory cell infiltration mostly of lymphocytes, and the changes were homogeneous, as in a nonspecific interstitial pneumonia (NSIP) pattern (Fig. 3a). Meanwhile, mild peripheral accentuation and inflammatory changes around the respiratory bronchioles were also seen. There were accumulations of foamy macrophages and a few neutrophils in the airspace (Fig. 3b), and subacute changes such as scant airspace fibrin and scattered Mason bodies as a minor component of the pathology (Fig. 3c, d).

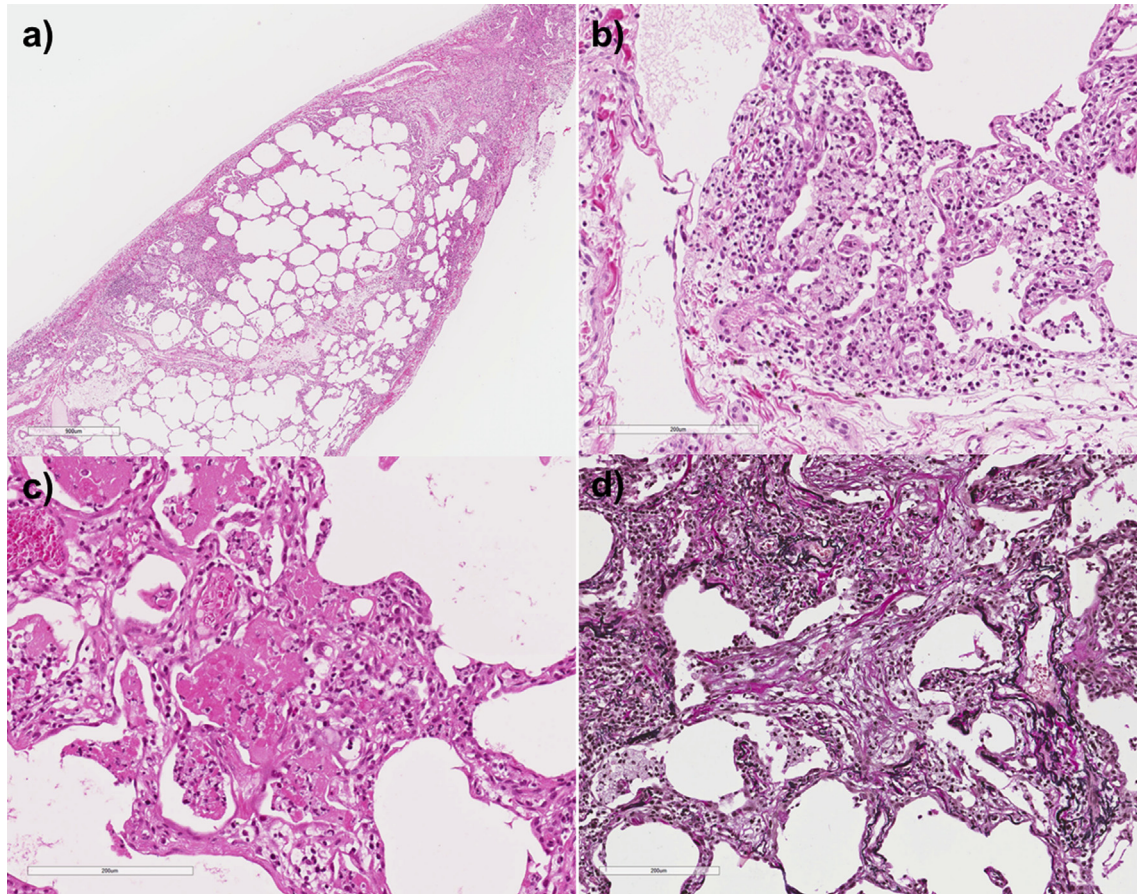


Fig. 3. Histopathological findings in lung biopsy specimen. a) diffuse involvement in secondary lobule with mild peripheral accentuation [haematoxylin-eosin (HE) stain]; b) accumulation of foamy macrophages accentuated in the periphery of the lobule along with a few neutrophils [HE stain]; c) no hyaline membrane or extensive fibrin are seen, but rare and scant airspace fibrin is found [HE stain]; d) Scattered Masson bodies as organizing pneumonia incorporating surrounding alveolar ducts in less than 20% of area [Elastic van Gieson stain]. Scale bars: 900 μm (a), 200 μm (b, c, d).

Findings suggestive of DAD such as hyaline membrane, remarkable airspace fibrin, and extensive interstitial edema were not found.

One week after SLB, two cycles of methylprednisolone pulse therapy (1000mg day^{-1} for 3 days) were initiated, followed by 10 mg of prednisolone and 5 mg of tacrolimus daily. This was associated with a significant resolution of symptoms within 1 month (MMRC was 1). The serum ferritin level decreased to 648 ng/ml, while %FVC increased to 96.0%. The 6MWD was improved to 560 m. These effects were maintained during the first year of treatment. No adverse events were observed.

3. Discussion

To our knowledge, this is the first case to show a non-DAD pattern in a survivor with RP-ILD and anti-MDA5 antibody-positive CADM. The important point here is that the histopathological findings indicated non-DAD pattern with a favorable clinical course. All previous reports showed that histopathological findings in RP-ILD with anti-MDA5 antibody-positive CADM indicated DAD [9,10]. However, our lung biopsy specimens showed diffuse and homogeneous inflammatory cell infiltration similar to NSIP with subacute inflammatory findings, which was different from DAD. These differences may have resulted from the timing of the lung biopsy or a difference in the type of interstitial pneumonia, which influences prognosis. We performed surgical lung biopsy one week after the first visit. Therefore, our lung specimens may reflect the early phase of RP-ILD, which may progress to DAD. Another

possibility is that there may be some heterogeneity with regards to ILD pattern in patients with RP-ILD and anti-MDA5 antibody-positive CADM [11]. Further studies are needed to clarify whether or not histopathologic pattern is associated with prognosis in patients with RP-ILD and anti-MDA5 antibody-positive CADM.

In our patient, both onset and histopathological findings were atypical for NSIP. Recent guidelines classified NSIP into chronic fibrosing interstitial pneumonia; however, the present case showed subacute onset [12]. As for histopathological findings, subacute changes were atypical for NSIP. Taken together, we diagnosed the histopathological pattern as unclassifiable interstitial pneumonia.

Another important point in this case is the treatment. Previous studies showed that anti-MDA5 antibody is associated with increased mortality in CADM [1,2,4]. Furthermore, some studies showed that high levels of ferritin are associated with the prognosis of anti-MDA5 antibody-positive CADM [2,13]. For this reason, a combination therapy including intravenous cyclophosphamide (IVCY) is recommended in RP-ILD patients with hyperferritinemia ($>500\text{ ng/ml}$) and/or anti-MDA5 antibody [14]. Although our patient had some poor prognostic factors, improvements were seen in symptoms, pulmonary function, 6MWD, and serum ferritin levels with only corticosteroids and tacrolimus. Wilkes et al. [15] showed that tacrolimus is a well-tolerated and effective therapy for managing refractory ILD and myositis in anti-aminoacyl-transfer RNA synthetase positive patients. Another study showed that combination therapy including IVCY was more frequently received in the dead subset than in the living subset of patients with anti-MDA5

antibody-positive DM [13]. These results suggest that some patients with anti-MDA5 antibody-positive CADM may not need strong immunosuppressive therapy.

In conclusion, this is the first report describing a non-DAD pattern in RP-ILD with anti-MDA5 antibody-positive CADM, which was improved by immunosuppressive therapy. This case may be a milder clinical phenotype than a typical DAD pattern in RP-ILD with anti-MDA5 antibody-positive CADM. Further studies are needed to determine the mechanisms of lung injury and an appropriate treatment of RP-ILD with anti-MDA5 antibody-positive CADM.

Financial disclosure and conflicts of interest

All of the authors confirm that there are no known conflicts of interest associated with this publication and there has been no significant financial support for this work that could have influenced its outcome.

References

- [1] T. Koga, K. Fujikawa, Y. Horai, et al., The diagnostic utility of anti-melanoma differentiation-associated gene 5 antibody testing for predicting the prognosis of Japanese patients with DM, *Rheumatology* 51 (2012) 1278–1284.
- [2] T. Gono, Y. Kawaguchi, T. Satoh, et al., Clinical manifestation and prognostic factor in anti-melanoma differentiation-associated gene 5 antibody-associated interstitial lung disease as a complication of dermatomyositis, *Rheumatology* 49 (2010) 1713–1719.
- [3] Y. Muro, K. Sugiura, K. Hoshino, M. Akiyama, Disappearance of anti-MDA-5 autoantibodies in clinically amyopathic DM/interstitial lung disease during disease remission, *Rheumatology* 51 (2012) 800–804.
- [4] S. Sato, M. Kuwana, T. Fujita, Y. Suzuki, Anti-CADM-140/MDA5 autoantibody titer correlates with disease activity and predicts disease outcome in patients with dermatomyositis and rapidly progressive interstitial lung disease, *Mod. Rheumatol.* 23 (2013) 496–502.
- [5] R.D. Sontheimer, Would a new name hasten the acceptance of amyopathic dermatomyositis (dermatomyositis sine myositis) as a distinctive subset within the idiopathic inflammatory dermatomyopathies spectrum of clinical illness? *J. Am. Acad. Dermatol.* 46 (2002) 626–636.
- [6] R.D. Sontheimer, S. Miyagawa, Potentially fatal interstitial lung disease can occur in clinically amyopathic dermatomyositis, *J. Am. Acad. Dermatol.* 48 (2003) 797–798.
- [7] T. Fujisawa, H. Hozumi, M. Kono, et al., Prognostic factors for myositis-associated interstitial lung disease, *PLoS One* 6 (2014) e98824.
- [8] H. Mukae, H. Ishimoto, N. Sakamoto, et al., Clinical differences between interstitial lung disease associated with clinically amyopathic dermatomyositis and classic dermatomyositis, *Chest* 136 (2009) 1341–1347.
- [9] K. Nagata, K. Tomii, S. Nanjo, M. Kubota, R. Tachikawa, M. Nishio, Four cases of interstitial pneumonia associated with amyopathic dermatomyositis characterized by the anti-CADM-140 antibody, *Nihon Kokyuki Gakkai Zasshi* 49 (2011) 30–36.
- [10] A. Sakai, T. Kita, Y. Ichikawa, Y. Oribe, M. Miyake, K. Kasahara, A case of rapidly progressive interstitial pneumonia with classic dermatomyositis with anti-CADM-140 antibody positive, *Nihon Kokyuki Gakkai Zasshi* 2 (2013) 761–766.
- [11] Y. Kondoh, H. Taniguchi, K. Kataoka, et al., Tokai diffuse lung disease study group. Prognostic factors in rapidly progressive interstitial pneumonia, *Respirology* 15 (2010) 257–264.
- [12] W.D. Travis, U. Costabel, D.M. Hansell, et al., ATS/ERS Committee on idiopathic interstitial pneumonias. An official American Thoracic Society/European Respiratory Society statement: update of the international multidisciplinary classification of the idiopathic interstitial pneumonias, *Am. J. Respir. Crit. Care Med.* 188 (2013) 733–748.
- [13] T. Gono, S. Sato, Y. Kawaguchi, et al., Anti-MDA5 antibody, ferritin and IL-18 are useful for the evaluation of response to treatment in interstitial lung disease with anti-MDA5 antibody-positive dermatomyositis, *Rheumatology* 51 (2012) 1563–1570.
- [14] H. Kawasumi, T. Gono, Y. Kawaguchi, H. Yamanaka, Recent treatment of interstitial lung disease with idiopathic inflammatory myopathies, *Clin. Med. Insights Circ. Respir. Pulm. Med.* 9 (2015) 9–17.
- [15] M.R. Wilkes, S.M. Sereika, N. Fertig, M.R. Lucas, C.V. Oddis, Treatment of antisynthetase-associated interstitial lung disease with tacrolimus, *Arthritis Rheum.* 52 (2005) 2439–2446.