



Sonographic Assessment of the Extent of Extrathyroidal Extension in Thyroid Cancer

Sae Rom Chung, PhD¹, Jung Hwan Baek, PhD¹, Young Jun Choi, PhD¹, Tae-Yon Sung, PhD², Dong Eun Song, PhD³, Tae Yong Kim, PhD⁴, Jeong Hyun Lee, PhD¹

¹Department of Radiology and Research Institute of Radiology, University of Ulsan College of Medicine, Asan Medical Center, Seoul, Korea; Departments of ²Surgery, ³Pathology, and ⁴Endocrinology and Metabolism, University of Ulsan College of Medicine, Asan Medical Center, Seoul, Korea

Objective: This study aimed to determine the sonographic features suggestive of extrathyroidal extension (ETE) of thyroid cancers.

Materials and Methods: We retrospectively reviewed the sonographic images of 1656 consecutive patients who had undergone thyroidectomy in 2017. The diagnostic performance of sonographic features suggestive of ETE was evaluated using operation and histopathologic reports. Sonographic features for gross ETE to the strap muscle and minor ETE were assessed for thyroid cancer abutting the anterolateral thyroid capsule. Sonographic features for tracheal invasion were assessed according to whether the angle between the tumor and the trachea was an acute, right, or obtuse angle. Sonographic features for recurrent laryngeal nerve (RLN) invasion were assessed based on the association between the tumor and tracheoesophageal groove (TEG) as preserved normal tissue, abutting or protruding into the TEG.

Results: ETE was observed in 783 patients (47.3%), including 123 patients with gross ETE (7.4% [strap muscle, n = 97; RLN, n = 24; and trachea, n = 14]) and 660 patients with minor ETE (39.9%). Regarding the diagnosis of gross and minor ETE to the strap muscle, sonographic features of replacement of the strap muscle and capsular disruption showed the highest positive predictive value (75.9% and 58.5%, respectively). Thyroid cancer forming an obtuse angle with the trachea had the highest sensitivity for the diagnosis of tracheal invasion (85.7%), and thyroid cancer protrusion into the TEG showed the highest sensitivity for the diagnosis of RLN (83.3%).

Conclusion: Sonography is considered beneficial in the diagnosis of ETE to the strap muscle, trachea, and RLN. Assessment of ETE is important for the accurate staging of thyroid cancer, which in turn determines the extent of surgery or whether active surveillance is appropriate or not.

Keywords: *Thyroid neoplasms; Ultrasonography; Diagnostic imaging; Neoplasm staging; Preoperative care*

INTRODUCTION

Extrathyroidal extension (ETE) is an involvement of perithyroidal structures by direct extension from the primary

thyroid cancer (1). ETE ranges from minor ETE identified by histological examination to gross ETE identified by preoperative or intraoperative evidence. The incidence of gross ETE in differentiated thyroid carcinoma (DTC) ranges from 5% to 34%, and ETE most commonly involves the strap muscle, recurrent laryngeal nerve (RLN), trachea, esophagus, and larynx (1-6).

The presence of ETE has been established as an important prognostic factor, and the 6th edition of the American Joint Committee on Cancer (AJCC) tumor-node-metastasis staging system for DTC first used minimal ETE as a staging variable (7). However, there is little evidence to support the use of minimal ETE as an independent prognostic factor (8-10), and establishing the histopathological diagnosis of

Received: December 31, 2019 **Revised:** March 19, 2020

Accepted: March 24, 2020

Corresponding author: Jung Hwan Baek, PhD, Department of Radiology and Research Institute of Radiology, University of Ulsan College of Medicine, Asan Medical Center, 88 Olympic-ro 43-gil, Songpa-gu, Seoul 05505, Korea.

• E-mail: radbaek@naver.com

This is an Open Access article distributed under the terms of the Creative Commons Attribution Non-Commercial License (<https://creativecommons.org/licenses/by-nc/4.0>) which permits unrestricted non-commercial use, distribution, and reproduction in any medium, provided the original work is properly cited.

minimal ETE is subjective and challenging (11). Hence, the 8th edition of the AJCC staging system defined minor ETE and gross ETE separately (1), with the presence of minor ETE detected only on histological examination no longer constituting a T3 category and with gross ETE to the strap muscle now being designated as the new T3b category. Thus, for thyroid cancer with anterolateral capsular abutment, it is important to differentiate minor ETE from gross ETE on ultrasound (US) imaging to ensure the accurate diagnosis of T3b disease. There have been few studies reporting the US features for differentially diagnosing gross ETE to the strap muscle from minor ETE (12).

T4a disease is defined as gross ETE invading the subcutaneous soft tissues, larynx, trachea, esophagus, or RLN, with the RLN and trachea being the two most commonly invaded structures. Recently, Ito et al. (13) reported the US features for the diagnosis of gross ETE invading the trachea and RLN, but their study was limited to patients with papillary thyroid microcarcinoma (PTMC).

To date, there has been no study reporting the US features of thyroid cancer with T3b or T4 disease after the application of the 8th edition of the AJCC staging system. Thus, this study aimed to evaluate the US features of thyroid cancer for diagnosing gross ETE to the strap muscle, trachea, and RLN.

MATERIALS AND METHODS

At the thyroid team meeting of our center attended by pathologists, surgeons, endocrinologists, and radiologists, it was agreed that thyroid cancer should be staged according to the 8th edition of the AJCC staging system from January 2017. We retrospectively reviewed patients' medical data after the study was approved by our Institutional Review Board. The study cohort included 1835 consecutive patients who underwent thyroidectomy in our institution from January 2017 to December 2017. The following patients were included in the study: 1) patients undergoing thyroidectomy for thyroid cancer and 2) patients undergoing US evaluation before surgery. However, the following patients were excluded from the study: 1) patients who did not undergo US evaluation before surgery at our institution, 2) patients undergoing an operation for recurrent thyroid cancer, and 3) patients who had incomplete surgical reports (Fig. 1). Finally, 1656 patients were included in the study population.

Imaging and Image Analysis

US examinations were performed using an iU22 unit (Philips Healthcare), an EUB-7500 unit (Hitachi Medical

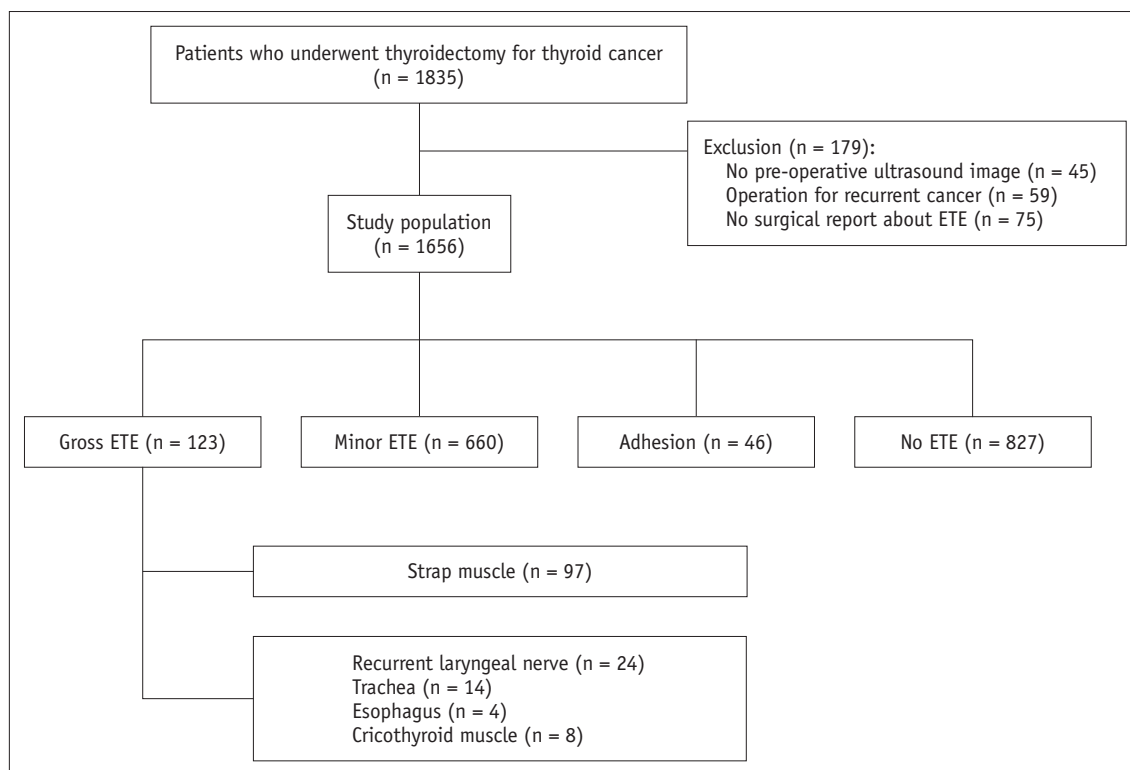


Fig. 1. Flowchart of study population. ETE = extrathyroidal extension

Sonographic Assessment of ETE in Thyroid Cancer

Systems), or a Sequoia (Acuson, Siemens Healthineers) instrument equipped with a linear high-frequency probe (5–14 MHz). All US-guided procedures were performed by radiologists under the supervision of two faculty radiologists (with 19 and 14 years of clinical experience in performing and evaluating thyroid US, respectively), and the US images were reviewed by two radiologists (with 19 and 8 years of clinical experience in thyroid US, respectively). If the patient had multiple thyroid cancers, we selected and analyzed the thyroid cancer diagnosed before surgery. Neither reviewer received any information regarding the patients' clinical histories, previous imaging results, or operative findings. Any diagnostic discrepancies between the two reviewers were resolved by consensus.

The radiologists evaluated the following sonographic features: capsular abutment by the nodule, capsular disruption, bulging of the normal thyroid contour, and replacement of the strap muscle (Fig. 2). Capsular abutment

was defined as a lack of intervening thyroid tissue between the thyroid cancer and the thyroid capsule. Capsule disruption was defined as loss of the anterior perithyroidal echogenic line at the site of contact with the thyroid cancer. Contour bulging was defined as outward bulging of the contour of the anterior capsule by the thyroid nodule beyond the expected normal thyroid margin. The replacement of the strap muscle was defined as the thyroid cancer protruding into the strap muscle and the margin with the strap muscle being indistinct or spiculated. Each feature was evaluated as "present" or "not." For nodules with capsular abutment, the extent of contact between the thyroid nodule and thyroid capsule was graded on the image where the nodule was in greatest contact with the capsule. In this image, the percentage of the perimeter of the nodule that contacted the thyroid capsule was graded into less than 25% contact, 25–50% contact, and greater than 50% contact.

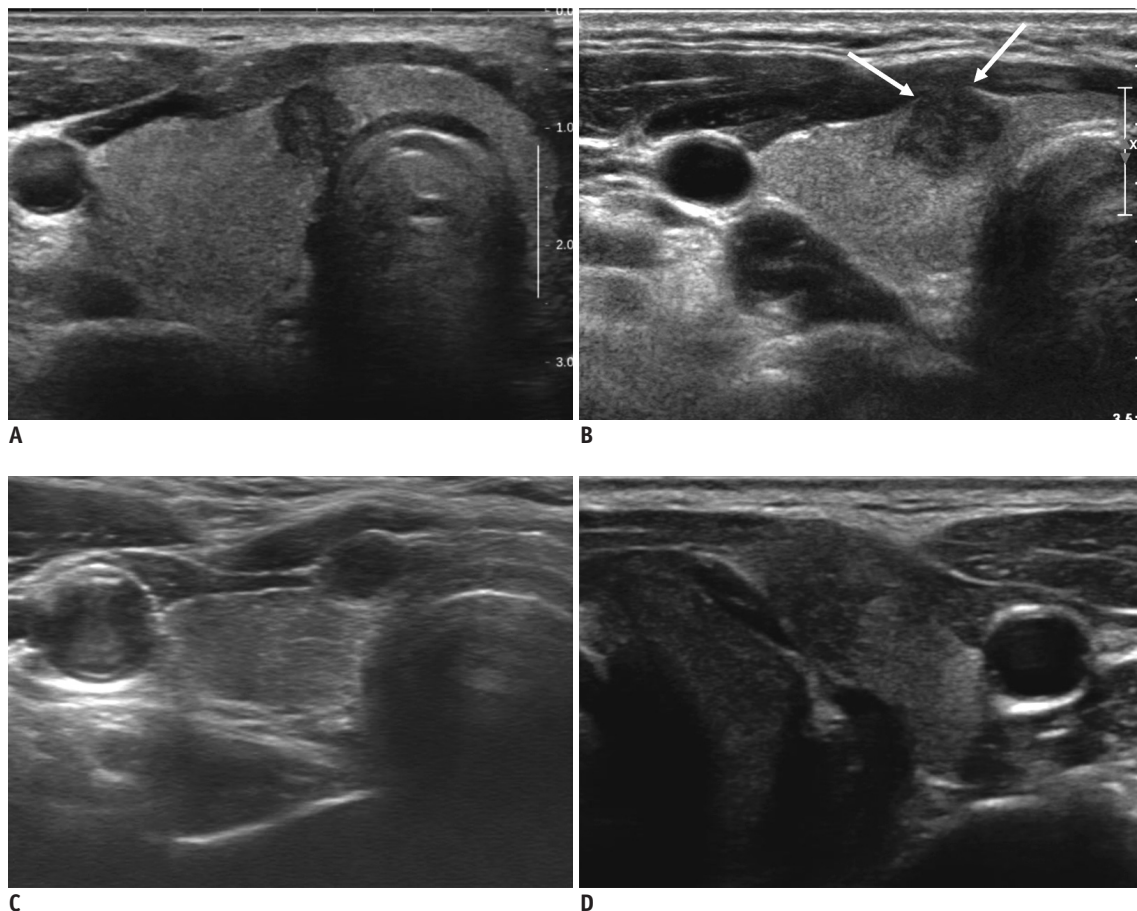


Fig. 2. Risk classification of strap muscle invasion.

A. Capsular abutment is defined as lack of intervening thyroid tissue between thyroid cancer and thyroid capsule. **B.** Capsular disruption is defined as loss of perithyroidal echogenic line at site of contact with thyroid cancer (arrows). **C.** Contour bulging is defined as outward bulging of contour of anterior capsule by thyroid nodule beyond expected normal thyroid margin. **D.** Replacement of strap muscle is defined as thyroid cancer being protruded into strap muscle and margin with strap muscle being indistinct.

The risk of tracheal invasion was categorized into the three categories of acute, right, and obtuse angle, according to the angles formed by the tumor surface and tracheal cartilage (Fig. 3). If the tumor had different angle at the sites of attachment to the trachea, a larger one was adapted. The risk of RLN invasion was categorized into the three categories of presence or absence of a normal rim of the thyroid between the tracheoesophageal groove (TEG) and cancer and protrusion of the cancer into the TEG (Fig. 4).

Definitions of ETE

Gross ETE was defined according to previous descriptions (1, 14) as gross tumor invasion identified at the time of surgery and confirmed by histopathologic review. Minor ETE was defined as tumor invasion beyond the thyroid capsule identified at the time of pathologic examination. No ETE means that histopathologic review and intraoperative inspection could not find any capsular or ETE. If gross tumor invasion was suspected in the surgical field but tumor was confined to the thyroid on histopathologic review and had not invaded the capsule surroundings, it was defined as simple adhesion (15).

The thyroid team of our center (endocrinologists,

endocrine surgeons, pathologists, nuclear medicine doctors, and radiologists) gathered and agreed to stage thyroid cancer according to the 8th edition of the AJCC staging system from January 2017. Surgeons described the presence of gross invasion of the cancer in the surgical report, and pathologists described the presence of tumor invasion beyond the thyroid capsule in the histopathologic report.

Outcome Measures

The primary study outcome was to determine the performance of US findings for the diagnosis of gross ETE to the strap muscle, trachea, and RLN. US findings for the diagnosis of minor ETE were also evaluated for thyroid cancer abutting the anterolateral thyroid capsule to establish the findings differentiating it from gross ETE to the strap muscle. US findings for the diagnosis of gross ETE to the strap muscle were selected with preference toward a high positive predictive value (PPV), while US findings for diagnosing gross ETE to the trachea and RLN were selected with a preference toward high sensitivity.

Statistical Analyses

The numbers of true-positive (TP), true-negative (TN),

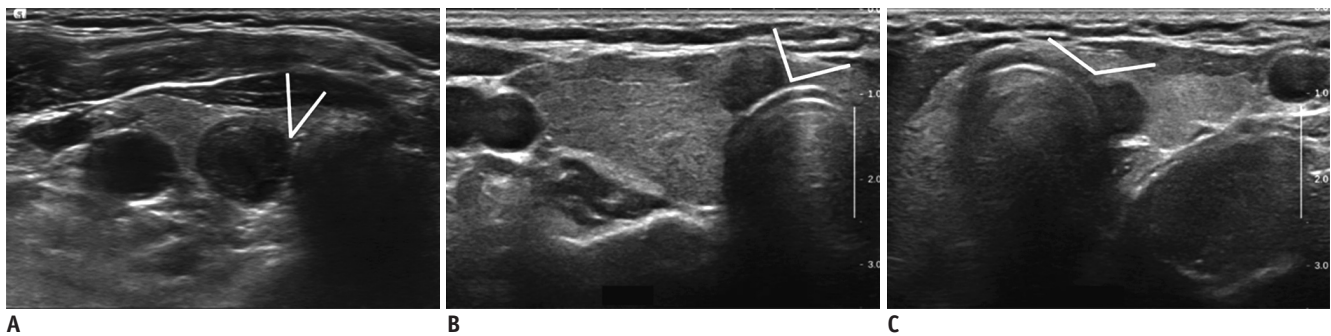


Fig. 3. Risk classification of tracheal invasion according to angles between tumor and tracheal wall. Angles were categorized as acute (A), right (B), and obtuse (C).

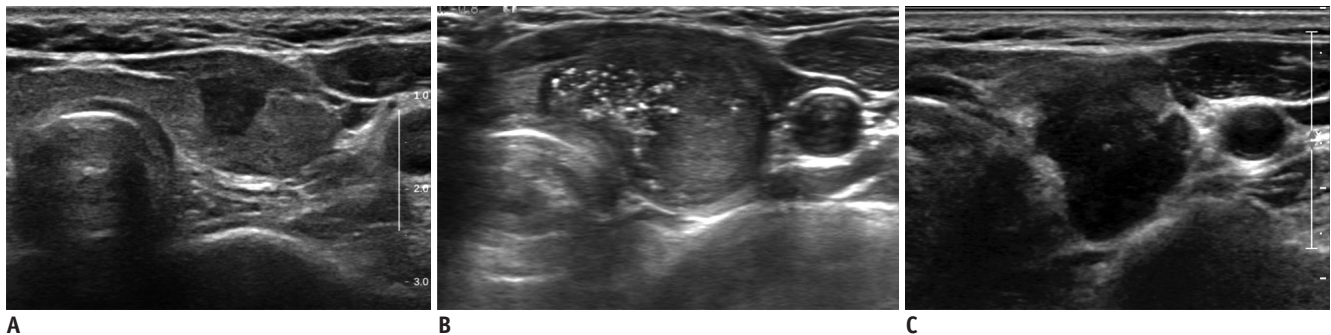


Fig. 4. Risk classification of recurrent laryngeal nerve invasion. Presence or absence of normal rim of thyroid present between tracheoesophageal groove and cancer (A, B) and protrusion of cancer into tracheoesophageal groove (C).

false-positive (FP), and false-negative (FN) US diagnoses were determined. Sensitivity, specificity, PPV, and negative predictive value (NPV) were calculated as $TP / (TP + FN)$, $TN / (TN + FP)$, $TP / (TP + FP)$, and $TN / (TN + FN)$, respectively. Subgroup analysis was performed for PTMC.

RESULTS

Demographic Data of the Patients

The demographic data of the patients and the histological characteristics of the tumors are detailed in Table 1. Of the 1656 patients, ETE was observed in 783 (47.3%) patients,

Table 1. Baseline Characteristics of Patients and Nodules

Characteristics	Value
Age* (years)	46.6 (8–86)
Sex (male/female)	372/1284
Size* (cm)	1.3 (0.2–11.0)
Size ≤ 1 cm	921 (55.6%)
Pathology	
Papillary thyroid carcinoma	1584
Follicular thyroid carcinoma	56
Medullary thyroid carcinoma	10
Others	6
Anaplastic carcinoma	2
Poorly differentiated carcinoma	4

*Data are expressed as median with range in parenthesis.

which included 123 patients with gross ETE (7.4%) and 660 patients with minor ETE (39.9%). A total of 97, 24, and 14 patients had gross ETE to the strap muscle, RLN, and trachea, respectively. Four patients had gross ETE to the esophagus, and all of these patients also had RLN invasion.

ETE to the Strap Muscle

From the total of 1656 patients, gross ETE to the strap muscle and minor ETE were diagnosed in 97 and 378 patients, respectively.

Tables 2 and 3 show the diagnostic performance of the US findings for predicting minor and gross ETE to the strap muscle, including sensitivity, specificity, accuracy, PPV, NPV, and diagnostic accuracy. Capsular disruption had the highest PPV and diagnostic accuracy (58.8% and 81.3%, respectively) for the diagnosis of minor ETE. Abutment with the capsule of greater than 25% but without capsular disruption had a lower PPV (26.6%). For US findings for the diagnosis of gross ETE to the strap muscle, the PPV and diagnostic accuracy were highest when the strap muscle was replaced by thyroid cancer (75.9% and 96.0%, respectively). The PPVs of other US features for predicting gross ETE to the strap muscle ranged from 13.8% to 31.3%.

The subgroup analysis for PTMC showed the same trends as the total study population: capsular disruption of thyroid cancer showed the highest PPV for diagnosing minor ETE

Table 2. Diagnostic Performance of Sonographic Findings of Minor ETE

Sonographic Findings	Sensitivity	Specificity	PPV	NPV	Diagnostic Accuracy
> 25% contact with adjacent capsule	71.4 (270/378)	73.9 (945/1278)	44.8 (270/603)	89.7 (945/1053)	73.4 (1215/1656)
> 50% contact with adjacent capsule	2.1 (8/378)	99.4 (1270/1278)	50.0 (8/16)	77.4 (1270/1640)	77.2 (1278/1656)
Capsular disruption	61.6 (233/378)	87.1 (1113/1278)	58.5 (233/398)	88.5 (1113/1258)	81.3 (1346/1656)
Abutment (> 25%) only without capsule disruption	18.3 (69/378)	85.1 (1088/1278)	26.6 (69/259)	77.9 (1088/1397)	69.9 (1157/1656)
Abutment (> 50%) only without capsule disruption	0.5 (2/378)	99.8 (1275/1278)	40.0 (2/5)	77.2 (1275/1651)	77.1 (1277/1656)
Contour bulging*	52.7 (199/378)	80.9 (1034/1278)	44.9 (199/443)	85.2 (1034/1213)	74.5 (1233/1656)
Replacement of strap muscle	3.7 (17/378)	96.6 (1234/1278)	24.1 (14/58)	77.2 (1234/1598)	75.4 (1248/1656)

Data are percentages. *Nodules with contour bulging with or without capsular disruption. ETE = extrathyroidal extension, NPV = negative predictive value, PPV = positive predictive value

Table 3. Diagnostic Performance of Sonographic Findings of Gross ETE to Strap Muscle

Sonographic Findings	Sensitivity	Specificity	PPV	NPV	Diagnostic Accuracy
> 25% contact with adjacent capsule	85.6 (83/97)	66.7 (1039/1559)	13.8 (83/603)	98.7 (1039/1053)	67.8 (1122/1656)
> 50% contact with adjacent capsule	5.2 (5/97)	99.3 (1548/1559)	31.3 (5/16)	94.4 (1548/1640)	93.8 (1553/1656)
Capsular disruption	89.7 (87/97)	80.1 (1248/1559)	21.9 (87/398)	99.2 (1248/1258)	80.6 (1335/1656)
Contour bulging*	83.5 (81/97)	76.8 (1197/1559)	18.3 (81/443)	98.7 (1197/1213)	77.2 (1278/1656)
Replacement of strap muscle	45.4 (44/97)	99.1 (1545/1559)	75.9 (44/58)	96.7 (1545/1598)	96.0 (1590/1656)

Data are percentages. *Nodules with contour bulging with or without capsular disruption.

(sensitivity, 58.7%; specificity, 92.6%; PPV, 68.1%; NPV, 89.4%; diagnostic accuracy, 85.5%), and tumor replacement of the strap muscle showed the highest PPV for diagnosing gross ETE to the strap muscle (sensitivity, 15.4%; specificity, 99.7%; PPV, 40.0%; NPV, 98.8%; diagnostic accuracy, 98.5%).

Gross ETE to the RLN

Of the 24 thyroid cancers that invaded the RLN, 20 (83.3%) were associated with protrusion into the TEG (sensitivity, 83.3%; specificity, 96.5%; PPV, 25.6%; NPV, 99.8%; diagnostic accuracy, 96.3%) (Table 4). Furthermore, all three cases requiring resection of the RLN were associated with protrusion of the cancer into the TEG. Loss of normal thyroid tissue between the cancer and TEG without protrusion showed a sensitivity of 8.3% and PPV of 1.2% for RLN invasion. Two patients had RLN invasion by thyroid cancer although normal thyroid tissue remained at the TEG; both of these patients had thyroid cancer

protruding posteriorly with a preserved TEG (Fig. 5).

Gross ETE to the Trachea

Table 5 summarizes the association between the risk grades and the intraoperative findings of tracheal invasion. Twelve (92.3%) of the 14 thyroid cancers that invaded the trachea formed an obtuse angle with the trachea (sensitivity, 85.7%; specificity, 98.9%; PPV, 40.0%; NPV, 99.9%; diagnostic accuracy, 98.8%). Both of the two patients who had a positive resection margin after thyroidectomy had an obtuse angle with the trachea.

DISCUSSION

Our study demonstrated the US findings for the diagnosis of T3b and T4a thyroid cancer disease of the invading strap muscle, trachea, and RLN. For thyroid cancer with replacement of the strap muscle on US, gross ETE to the strap muscle should be suspected, whereas thyroid

Table 4. Relationships between Sonographic and Postoperative Findings of RLN Invasion

Sonographic Findings	No invasion	RLN Shaving	RLN Resection	Total
Preserved normal parenchyma	1410	2	0	1412
Abutting TEG	164	2	0	166
Protrusion into TEG	58	17	3	78

RLN = recurrent laryngeal nerve, TEG = tracheoesophageal groove

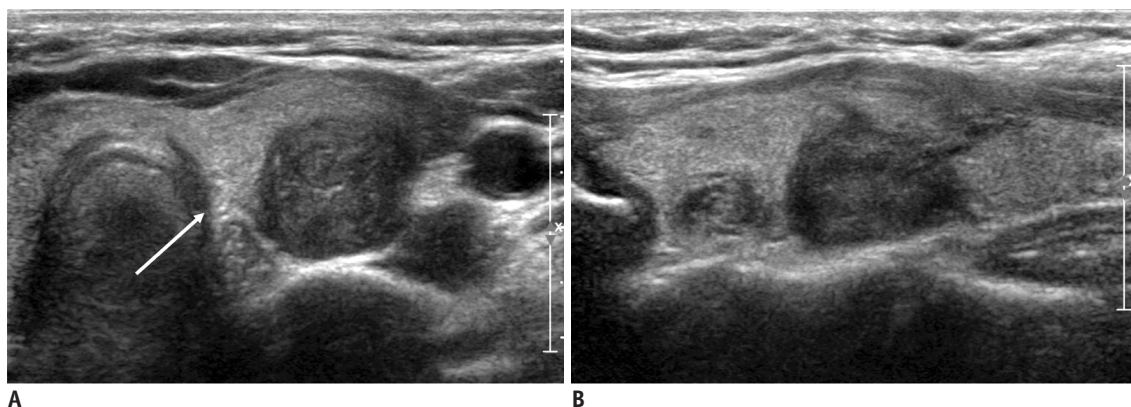


Fig. 5. 41-year-old female patient with papillary thyroid carcinoma invading recurrent laryngeal nerve. Transverse (A) and longitudinal (B) gray-scale sonograms show thyroid cancer protruding into posterior aspect of thyroid gland with preserved normal thyroid tissue at tracheoesophageal groove (arrow).

Table 5. Relationships between Sonographic and Postoperative Findings of Tracheal Invasion

Angle between Tumor and Trachea	No Tracheal Invasion	Tracheal Invasion		Total
		(Resection Margin Negative)	(Resection Margin Positive)	
No contact	1225	1	0	1226
Acute angle	265	0	0	265
Right angle	134	1	0	135
Obtuse angle	18	10	2	30

cancer with capsular disruption is indicative of minor ETE. Formation of an obtuse angle with the trachea and protrusion into the TEG are indicative of invasion to the trachea and invasion to the RLN, respectively. Our study is the first to differentiate the US findings of gross and minor ETE according to the 8th edition of the AJCC staging system.

There are several reasons why the prediction of ETE on US examination is of clinical value. First, accurate preoperative staging is important for determining the extent of surgery. Although the extent of surgery required when treating thyroid cancer remains a topic of debate, when determining whether to perform a total thyroidectomy or lobectomy, several authors have considered the preoperative influencing factors to include tumor size, age, ETE, lymph node involvement, bilateral disease, distant metastases, and prior history of radiation exposure (16-18). Therefore, ETE is an important factor in determining the extent of the required surgery. Second, ETE is an important factor in determining whether to perform active surveillance for PTMC because it is generally accepted that gross ETE is not appropriate for active surveillance.

Although several studies have reported US features for predicting minimal ETE (19-22), only one study by Rim et al. (12) analyzed gross ETE and microscopic ETE (which we define as "minor ETE" in our study) separately. The authors reported that papillary thyroid carcinoma (PTC) with capsular abutment and an invisible capsule was associated with microscopic ETE, which is consistent with our study result. They found that gross ETE to the strap muscle was associated with PTC with contour bulging and an indistinct or invisible capsule. However, for the diagnosis of gross ETE to the strap muscle, the calculated diagnostic performance based on the criteria of Rim et al. (12) had a low PPV of 30.8%. Several studies have reported that the invasion of the strap muscle has little effect on the survival of patients (8, 10, 23, 24). Thus, the US findings for the detection of minor and gross ETE to the strap muscle should have a high PPV, rather than a high sensitivity, to prevent the overtreatment of thyroid cancer. In our study, the US feature of replacement of the strap muscle showed the highest PPV and diagnostic accuracy for the diagnosis of gross ETE to the strap muscle. However, some surgeons may want to diagnose gross ETE to the strap muscle with higher sensitivity, and if so, they could choose an appropriate US finding based on Tables 2 and 3 we have provided.

Thyroid cancer with gross ETE to the RLN or trachea was

shown to be associated with a poor prognosis and required total thyroidectomy followed by adjuvant radioactive iodine treatment (16). Therefore, it is reasonable to adapt US findings with a high sensitivity rather than a high PPV. We assessed the risk of tracheal invasion on US according to the angle formed by the tumor and tracheal surface, as proposed by Ito et al. (13). Our results were similar to their results, with an obtuse margin between the thyroid cancer and trachea having the highest diagnostic performance for tracheal invasion. Ito et al. (13) graded RLN invasion into two categories based on whether the normal thyroid rim was clearly present in the direction of the TEG or not. In our study, we further categorized loss of normal thyroid rim into cancer just abutting the capsule at the TEG and cancer protruding into the TEG. We found that of the 22 thyroid cancers invading the RLN, two abutted the capsule at the TEG and 20 protruded into the TEG. Thus, we suggest that thyroid cancer that protrudes into the TEG is indicative of RLN invasion. However, two patients showed RLN invasion although the tissue at the TEG was a normal thyroid tissue. Both of these patients had posteriorly protruding thyroid cancer with a preserved TEG. This may be associated with variation in the course of the RLN (25). Considering that in some anatomical variations the course of the RLN can be located posteriorly to the thyroid gland, posterior protrusion of thyroid cancer also carries the possibility of RLN invasion.

The general consensus is to consider PTMC with tumor abutting the trachea or TEG as a contraindication for active surveillance. However, there is controversy over thyroid cancer attached to the anterolateral thyroid capsule: Miyauchi & Ito (26) mentioned that minimal ETE of the anterolateral thyroid capsule is not a contraindication for active surveillance, while Brito et al. (27) stated that thyroid cancer with evidence of ETE is inappropriate for active surveillance. However, there are no previous studies on definite US findings of ETE and on US findings that differentiate minor ETE from gross ETE in PTMC. According to a subgroup analysis, we found that PTMC abutting the anterolateral capsule suggests minor ETE if there is capsular disruption, but it suggests gross ETE to the strap muscle if there is a replacement of the strap muscle on US. Therefore, PTMC in contact with the anterolateral thyroid capsule or having a contour bulging at the anterolateral aspect may be considered a candidate for active surveillance if there is no thyroid capsular disruption.

This study has several limitations. First, because it was a

retrospective study, the US features were evaluated using previously captured images. Second, we did not assess the interobserver agreement on the US features of ETE. A future large prospective study assessing the interobserver agreement is required to evaluate the clinical significance of our study results. Third, we did not evaluate minor ETE for thyroid cancer abutting the posterolateral capsule. In several cases, the presence of posterolateral capsular disruption or protrusion is unclear on US, and it is not included in the AJCC staging system. Further studies using other imaging modalities such as computed tomography may be required to determine its clinical significance and imaging features.

In conclusion, sonography is considered beneficial to establish the diagnosis of ETE to the strap muscle, trachea, and RLN. Assessment of ETE is important for the accurate staging of thyroid cancer, which in turn determines the extent of surgery or whether active surveillance is appropriate or not.

Conflicts of Interest

The authors have no potential conflicts of interest to disclose.

ORCID iDs

Jung Hwan Baek

<https://orcid.org/0000-0003-0480-4754>

Sae Rom Chung

<https://orcid.org/0000-0003-4219-7166>

REFERENCES

- Amin MB, Edge SB, Greene FL, Byrd DR, Brookland RK, Washington MK, et al. *AJCC cancer staging manual*, 8th ed. New York: Springer, 2017
- Dralle H, Sekulla C, Haerting J, Timmermann W, Neumann HJ, Kruse E, et al. Risk factors of paralysis and functional outcome after recurrent laryngeal nerve monitoring in thyroid surgery. *Surgery* 2004;136:1310-1322
- Randolph GW, Kamani D. The importance of preoperative laryngoscopy in patients undergoing thyroidectomy: voice, vocal cord function, and the preoperative detection of invasive thyroid malignancy. *Surgery* 2006;139:357-362
- Shindo ML, Caruana SM, Kandil E, McCaffrey JC, Orloff LA, Porterfield JR, et al. Management of invasive well-differentiated thyroid cancer: an American Head and Neck Society consensus statement. *AHNS consensus statement. Head Neck* 2014;36:1379-1390
- Hu A, Clark J, Payne RJ, Eski S, Walfish PG, Freeman JL. Extrathyroidal extension in well-differentiated thyroid cancer: macroscopic vs microscopic as a predictor of outcome. *Arch Otolaryngol Head Neck Surg* 2007;133:644-649
- Ortiz S, Rodríguez JM, Soria T, Pérez-Flores D, Piñero A, Moreno J, et al. Extrathyroid spread in papillary carcinoma of the thyroid: clinicopathological and prognostic study. *Otolaryngol Head Neck Surg* 2001;124:261-265
- Greene FL, Page DL, Fleming ID, Fritz AG, Balch CM, Haller DG, et al. *AJCC cancer staging manual*, 6th ed. New York: Springer, 2002
- Ito Y, Tomoda C, Urano T, Takamura Y, Miya A, Kobayashi K, et al. Prognostic significance of extrathyroid extension of papillary thyroid carcinoma: massive but not minimal extension affects the relapse-free survival. *World J Surg* 2006;30:780-786
- Kim JM, Lee YY, Choi CW, Lim SM, Lee SS, Cho SY, et al. The clinical importance of minimal extrathyroid extension on tumor recurrence in patients with papillary thyroid carcinoma. *Endocrinol Metab* 2010;25:340-346
- Jin BJ, Kim MK, Ji YB, Song CM, Park JH, Tae K. Characteristics and significance of minimal and maximal extrathyroidal extension in papillary thyroid carcinoma. *Oral Oncol* 2015;51:759-763
- Mete O, Rotstein L, Asa SL. Controversies in thyroid pathology: thyroid capsule invasion and extrathyroidal extension. *Ann Surg Oncol* 2010;17:386-391
- Rim JH, Chong S, Ryu HS, Chung BM, Ahn HS. Feasibility study of ultrasonographic criteria for microscopic and macroscopic extra-thyroidal extension based on thyroid capsular continuity and tumor contour in patients with papillary thyroid carcinomas. *Ultrasound Med Biol* 2016;42:2391-2400
- Ito Y, Miyauchi A, Oda H, Kobayashi K, Kihara M, Miya A. Revisiting low-risk thyroid papillary microcarcinomas resected without observation: was immediate surgery necessary? *World J Surg* 2016;40:523-528
- Arora N, Turbendian HK, Scognamiglio T, Wagner PL, Goldsmith SJ, Zarnegar R, et al. Extrathyroidal extension is not all equal: implications of macroscopic versus microscopic extent in papillary thyroid carcinoma. *Surgery* 2008;144:942-947; discussion 947-948
- Jung SP, Kim M, Choe JH, Kim JS, Nam SJ, Kim JH. Clinical implication of cancer adhesion in papillary thyroid carcinoma: clinicopathologic characteristics and prognosis analyzed with degree of extrathyroidal extension. *World J Surg* 2013;37:1606-1613
- Haugen BR, Alexander EK, Bible KC, Doherty GM, Mandel SJ, Nikiforov YE, et al. 2015 American Thyroid Association management guidelines for adult patients with thyroid nodules and differentiated thyroid cancer: the American Thyroid Association guidelines task force on thyroid nodules and differentiated thyroid cancer. *Thyroid* 2016;26:1-133
- Perros P, Boelaert K, Colley S, Evans C, Evans RM, Gerrard Ba G, et al. Guidelines for the management of thyroid cancer. *Clin Endocrinol (Oxf)* 2014;81 Suppl 1:1-122

18. National Comprehensive Cancer Network®. NCCN clinical practice guidelines in oncology (NCCN guidelines®). Thyroid carcinoma, Version 1. NCCN, 2017. Available at: http://www.klinikum.uni-muenchen.de/Schilddruesenzentrum/download/inhalt/Leitlinien/NCCN/thyroid_2017.pdf. Accessed August 5, 2019
19. Kamaya A, Tahvildari AM, Patel BN, Willmann JK, Jeffrey RB, Desser TS. Sonographic detection of extracapsular extension in papillary thyroid cancer. *J Ultrasound Med* 2015;34:2225-2230
20. Kim H, Kim JA, Son EJ, Youk JH, Chung TS, Park CS, et al. Preoperative prediction of the extrathyroidal extension of papillary thyroid carcinoma with ultrasonography versus MRI: a retrospective cohort study. *Int J Surg* 2014;12:544-548
21. Kwak JY, Kim EK, Youk JH, Kim MJ, Son EJ, Choi SH, et al. Extrathyroid extension of well-differentiated papillary thyroid microcarcinoma on US. *Thyroid* 2008;18:609-614
22. Moon SJ, Kim DW, Kim SJ, Ha TK, Park HK, Jung SJ. Ultrasound assessment of degrees of extrathyroidal extension in papillary thyroid microcarcinoma. *Endocr Pract* 2014;20:1037-1043
23. Shin JH, Ha TK, Park HK, Ahn MS, Kim KH, Bae KB, et al. Implication of minimal extrathyroidal extension as a prognostic factor in papillary thyroid carcinoma. *Int J Surg* 2013;11:944-947
24. Song E, Lee YM, Oh HS, Jeon MJ, Song DE, Kim TY, et al. A relook at the T stage of differentiated thyroid carcinoma with a focus on gross extrathyroidal extension. *Thyroid* 2019;29:202-208
25. Sturniolo G, D'Alia C, Tonante A, Gagliano E, Taranto F, Lo Schiavo MG. The recurrent laryngeal nerve related to thyroid surgery. *Am J Surg* 1999;177:485-488
26. Miyauchi A, Ito Y. Conservative surveillance management of low-risk papillary thyroid microcarcinoma. *Endocrinol Metab Clin North Am* 2019;48:215-226
27. Brito JP, Ito Y, Miyauchi A, Tuttle RM. A clinical framework to facilitate risk stratification when considering an active surveillance alternative to immediate biopsy and surgery in papillary microcarcinoma. *Thyroid* 2016;26:144-149