

# Effect of 16% Carbamide Peroxide Bleaching Gel on Enamel and Dentin Surface Micromorphology and Roughness of Uremic Patients: An Atomic Force Microscopic Study

Salah Hasab Mahmoud<sup>a</sup>  
Abeer El Sayed Elembaby<sup>b</sup>  
Ahmed Ragheb Zaher<sup>c</sup>  
Mohammed El-Awady Grawish<sup>d</sup>  
Heba M Elsabaa<sup>e</sup>  
Salwa Abd El-Raof El- Negoly<sup>f</sup>  
Mohamed Abdel Kader Sobh<sup>g</sup>

## ABSTRACT

**Objectives:** To investigate the effect of 16% carbamide peroxide bleaching gel on surface micromorphology and roughness of enamel and root dentin of uremic patients receiving hemodialysis using atomic force microscopy (AFM).

**Methods:** A total of 20 sound molars were collected from healthy individuals (n=10) and uremic patients (n=10). The roots were separated from their crowns at the cemento-enamel junction. Dental slabs (3 mm x 2 mm x 2 mm) were obtained from the buccal surface for enamel slabs and the cervical third of the root surface for dentin slabs. Dental slabs were then flattened and serially polished up to #2500-grit roughness using silicon carbide abrasive papers. Half of the slabs obtained from healthy individuals and uremic patients were stored in artificial saliva and left without bleaching for control and comparison. The remaining half was subjected to a bleaching treatment using 16% carbamide peroxide gel (Polanight, SDI Limited) 8 h/day for 14 days and stored in artificial saliva until AFM analysis was performed. Statistical analysis of the roughness average (Ra) results was performed using one-way ANOVA and Bonferroni post hoc multiple comparisons test.

**Results:** The micromorphological observation of bleached, healthy enamel showed exaggerated prism irregularities more than non-bleached specimens, and this observation was less pronounced in bleached uremic enamel specimens with the lowest Ra. Bleached healthy dentin specimens showed protruded peritubular dentin and eroded intertubular dentin with the highest Ra compared to bleached uremic dentin.

**Conclusions:** The negative effects of the bleaching gel on uremic tooth substrates are less dramatic and non-destructive compared to healthy substrates because uremia confers different micromorphological surface changes. (Eur J Dent 2010;4:175-181)

**Key words:** Bleaching; Atomic force microscopy; Uremic patients; Carbamide peroxide; Chronic renal failure.

- <sup>a</sup> Associate Professor of Operative Dentistry, Head of Conservative Dentistry Department, Faculty of Dentistry, Mansoura University, Mansoura, Egypt.
- <sup>b</sup> Lecturer of Operative Dentistry, Conservative Dentistry Department, Faculty of Dentistry, Mansoura University, Mansoura, Egypt.
- <sup>c</sup> Professor, Department of Oral Biology, Faculty of Dentistry, Mansoura University, Mansoura, Egypt.
- <sup>d</sup> Associate Professor, Department of Oral Biology, Faculty of Dentistry, Mansoura University, Mansoura, Egypt.
- <sup>e</sup> Lecturer, Department of Oral Biology, Faculty of Dentistry, Mansoura University, Mansoura, Egypt.

- <sup>f</sup> Lecturer, Department of Dental Biomaterial, Faculty of Dentistry, Mansoura University, Egypt.
- <sup>g</sup> Professor and Head of Nephrology Department, Urology and Nephrology Center, Faculty of Medicine, Mansoura University, Mansoura, Egypt.

■ Corresponding author: Salah Hasab Mahmoud  
Associate Professor of Operative Dentistry,  
Head of Conservative Dentistry Department, Faculty of  
Dentistry, Mansoura University, Mansoura, Egypt.  
Phone: +2 010 0824141  
Fax: +2 050 2260173  
E-mail: dr\_salahhasab@yahoo.com

## INTRODUCTION

Chronic renal failure (CRF) is defined as a progressive decline in renal function associated with a reduced glomerular filtration rate. The most common causes are diabetes mellitus, glomerulonephritis, polycystic kidney disease, pyelonephritis and chronic hypertension. CRF is considered both a social and economic problem. Worldwide, the number of cases of CRF is increasing; oral health-care providers are increasingly likely to provide care for patients with this disease.<sup>1-3</sup>

The clinical signs and symptoms of renal failure are collectively termed 'uremia'. CRF affects most body systems, and its clinical features are dependent upon the stage of renal failure and the systems involved. The treatment of CRF includes dietary changes, correction of systemic complications and dialysis or renal transplant.<sup>1</sup>

CRF can give rise to a wide spectrum of oral manifestations, which affect the hard or soft tissues of the mouth.<sup>4</sup> Delayed eruption of permanent teeth in children with CRF,<sup>5,6</sup> enamel hypoplasia of the primary and permanent teeth with or without brown discoloration<sup>7</sup> and narrowing or calcification of the pulp chamber of teeth of adults with CRF have been reported.<sup>8,9</sup> Changing rates of dental caries have also been observed in groups of patients with CRF.<sup>3,10</sup>

The findings of a previous study showed that the pH of the saliva of uremic patients receiving hemodialysis is alkaline because of the high concentration of ammonia as a result of ureal hydrolysis.<sup>12,13</sup> Mahmoud et al<sup>14</sup> investigated the influence of uremia on the shear bond strength of composite resin to enamel and dentin substrates along with an assessment of the micromorphological etching pattern of the enamel and dentin surfaces using atomic force microscopy. The authors found that uremia adversely affects bonding of resin composites to enamel and dentin and confers an altered micromorphological etching pattern.

The appearance of teeth is of great importance to patients that seek esthetic treatments related to dental discoloration. Among treatments, tooth bleaching has attracted the interest of patients and dentists because it represents a non-invasive option and is relatively simple to carry out.<sup>15</sup> In particular, at-home bleaching techniques re-

ceived worldwide acceptance after first being described in 1989 by Haywood and Heymann.<sup>16</sup> Ten percent carbamide peroxide is the bleaching agent most used for this technique<sup>16</sup> because it is considered safe and effective.<sup>17</sup> As whitening of vital teeth generally involves direct and frequent contact of the bleaching agent with the outer enamel surface and sometimes with dentine for an extensive period of time, *in vitro* studies have evaluated the effects of carbamide peroxide on dental hard tissues. Changes have been observed in surface texture,<sup>18-22</sup> mineral content,<sup>23-26</sup> chemical composition,<sup>20,27,28</sup> and loss by tooth brushing abrasion.<sup>29</sup>

Additionally, some *in situ* studies, which represent an intermediate stage between *in vitro* studies and clinical trials,<sup>30</sup> have investigated the effects of bleaching treatment on microhardness of dental enamel<sup>27,31-33</sup> and dentine.<sup>32,34</sup> Surface morphology,<sup>27,35</sup> roughness<sup>35</sup> and calcium content in enamel<sup>27</sup> have also been investigated. However, the effect of whitening agents on enamel and dentin of uremic patients has still not been evaluated.

Considering the preceding information together with the desire of uremic patients to bleach his/her teeth, the present study aimed to investigate the effect of 16% carbamide peroxide bleaching gel on surface micromorphology and roughness of the enamel and root dentin of uremic patients receiving hemodialysis using atomic force microscopy (AFM).

## MATERIALS AND METHODS

### Preparation of dental slabs

Twenty caries-free molar teeth that had been extracted for periodontal reasons were collected from healthy individuals (n=10 molars) and uremic patients (n=10 molars). The teeth were obtained according to a protocol that was approved by our Institution Committee for Ethics of Research.

Both healthy individuals and uremic patients were seeking dental care advise at the Outpatient Dental Clinic, Faculty of Dentistry, Mansoura University. However, uremic patients were referred by the Outpatient Clinic of Mansoura Urology and Nephrology Center. Uremic patients were under regular hemodialysis treatment by biocompatible membranes that were dialyzed with a volumetric machine using bicarbonate dialysate three times weekly for four hours each (12 h/ week). None of the uremic patients had decompensated organs

other than the kidney, and all patients had a serum creatinine level above 7 mg/dl and a creatinine clearance rate of less than 10 ml/min. Three patients were normotensive, while the remaining had controlled hypertension.

All the collected teeth were subjected to thorough scaling (Varios 550, NSK Nakanishi, Japan) and ultrasonic cleaning (Pro-sonic 300 MTH, Sultan Chemists Inc, Englewood, NJ) to get rid of both hard and soft deposits and stored in 0.1% thymol (pH=7.0). The roots were separated from their crowns at the cemento-enamel junction using a low speed water-cooled diamond saw (Isomet 1000, Buehler, Lake Bluff, IL, USA). Enamel slabs (3 mm x 2 mm x 2 mm) were obtained from the middle third of the buccal surface, while dentin slabs were cut from the cervical third of the root surface with the same dimensions. Dental slabs were fixed with stick wax in acrylic resin cylinders, and the upper surface of the specimens was then flattened and serially polished up to #2500-grit roughness with silicon carbide abrasive papers. Specimens were placed in an ultrasonic cleaner (T1440D, Odontobra's Ltda., Ribeirão Preto, SP, Brazil) with distilled water for 10 min to remove polishing debris. A stereomicroscope (Nikon 88286, Tokyo, Japan) at 40x magnification was employed to select the samples without cracks or structural defects, which would compromise the results of the study.

Half of the specimens in each category (healthy enamel, uremic enamel, healthy dentin, and uremic dentin) were bleached. Bleaching treatment was performed with 16% carbamide peroxide bleaching gel with neutral pH (Polanight, lot # 03072, SDI Limited, Bayswater, Victoria, 3153, Australia). The application protocol was for 8 h, and then the specimens were rinsed with distilled water and stored in artificial saliva at 37°C. These procedures were repeated for 14 days according to the manufacturer's directions. The remaining half were stored in artificial saliva and left without bleaching for control and comparison. The artificial saliva used was the one described by Arvidson and Johansson<sup>36</sup> and was prepared by Chemistry Department, Faculty of Pharmacy, Mansoura University. It consisted of 4.1 mM  $\text{KH}_2\text{PO}_4$ , 4.0 mM  $\text{Na}_2\text{HPO}_4$ , 24.8 mM  $\text{KHCO}_3$ , 16.5 mM  $\text{NaCl}$ , 0.25 mM  $\text{MgCl}_2$ , 4.1 mM citric acid, and 2.5 mM  $\text{CaCl}_2$ . The pH of the saliva was adjusted to 6.7 with 10 N

HCl and then sterilized by 0.2- $\mu\text{m}$  filtration before use.<sup>36</sup>

#### Atomic force microscopic examination

All specimens were analyzed using AFM. Each specimen was fixed to the microscope holder with a cyanoacrylate adhesive and examined using AFM (Thermomicroscop Autoprob cp, Model No: AP-0100, Santa Barbara, CA, USA). The surface morphology of the tooth specimens was probed in 'contact' mode; physical contact between the tooth surface and the AFM tip was maintained at all times with constant force. Imaging was performed with standard geometry silicon nitride probes. AFM images were collected at a very low scan rate of 1 Hz to obtain details of the enamel and dentin structure and to avoid damaging the tip. An area of 25.0  $\mu\text{m}^2$  was captured for the AFM image using a scanning speed of 80  $\mu\text{ms}$  in air. The results of Ra are expressed as the means  $\pm$ SD. A one-way Analysis of Variance (ANOVA) and Bonferroni post hoc multiple comparisons test were conducted to determine if there were differences among the bleached and non-bleached groups. A P value <.05 was considered statistically significant.

## RESULTS

AFM images of non-bleached enamel specimens obtained from healthy individuals (HE) showed the surface of the enamel rods with tightly packed projections of smaller sized grains in close proximity to each other without any specific alignment. Several longitudinal grooves appeared in between enamel rods (Figure 1A). In contrast, AFM images of bleached specimens (BHE) revealed enamel grains of larger size with deep microporosities in between (Figure 1B).

In the non-bleached enamel specimens obtained from uremic patients' (UE), the micromorphological observation of the AFM images revealed less distinct sized enamel grains with mild surface pitting and several shallow, longitudinal grooves in between the enamel rods (Figure 1C). Meanwhile, the bleached uremic enamel specimens (BUE) showed small enamel projections in close proximity to each other with no specific rod alignment (Figure 1D).

The micromorphological observation of the dentin specimens obtained from non-bleached healthy individuals (HD) revealed regularly arranged dentinal tubules with the peritubular

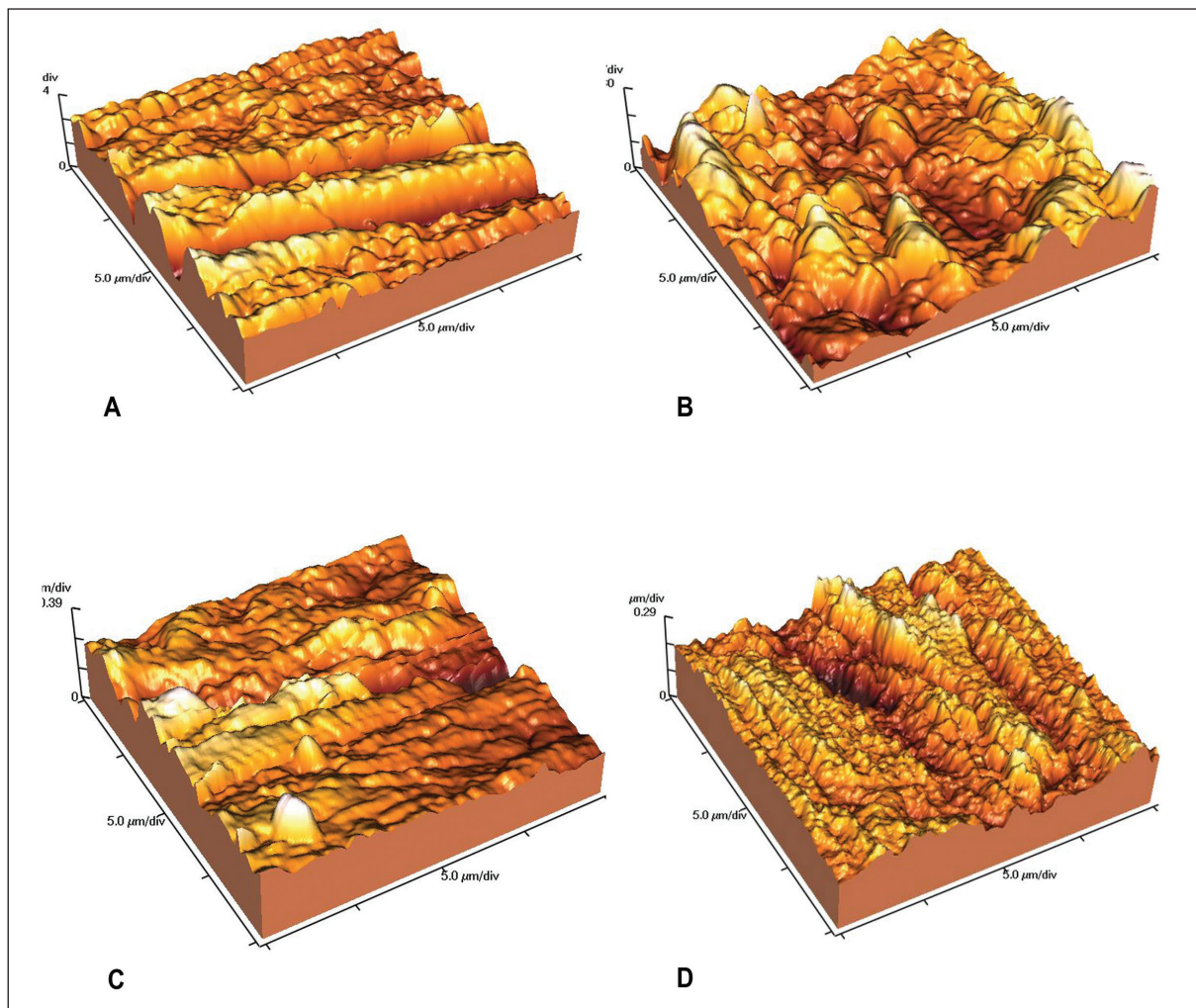
dentin protruding slightly above the intertubular dentine (Figure 2A). However, the bleached specimens (BHD) showed erosion of intertubular dentin, and the peritubular dentine subsequently became more protruded (Figure 2B). Moreover, AFM images of dentin specimens obtained from uremic patients (UD) showed an increase in the amount of intertubular dentin on the expanse of the dentinal tubules lumen as most of the tubules lumens were occluded (Figure 2C). However, the bleached specimens (BUD) showed no observable changes compared to non-bleached uremic ones (Figure 2D)

Means and standard deviations of the average roughness (Ra) for non-bleached and bleached enamel and dentin specimens obtained from healthy individuals and uremic patients extrapolated from AFM digital images records are presented in (Table 1, Figure 3). The ANOVA for sur-

face roughness of enamel and dentin obtained from bleached and non-bleached healthy individuals and uremic patients (Table 2) reveals a significant effect in the interaction of the substrate and bleaching agent ( $P=0.000$ ). Bonferroni Post Hoc multiple comparisons test showed no significant difference between the mean Ra of healthy enamel and bleached uremic enamel specimens ( $P=0.285$ ). In contrast, significant differences were found between the mean Ra of the other tested specimens ( $P<.05$ ).

## DISCUSSION

In vitro models can be used to gain important information on the safety of products in terms of their effects on the hard tissues and to provide mechanistic understanding of the bleaching process. This laboratory study was undertaken to evaluate the impact of 16% carbamide peroxide



**Figure 1.** Three-dimensional presentation of the AFM contact mode images of an enamel specimen prepolished with # 2500-grit silicon carbide abrasive paper, non bleached healthy enamel (A), bleached healthy enamel (B), non bleached uremic enamel (C) and bleached uremic enamel (D).

bleaching gel on surface roughness of structurally different tooth substrates obtained from healthy individuals and uremic patients.

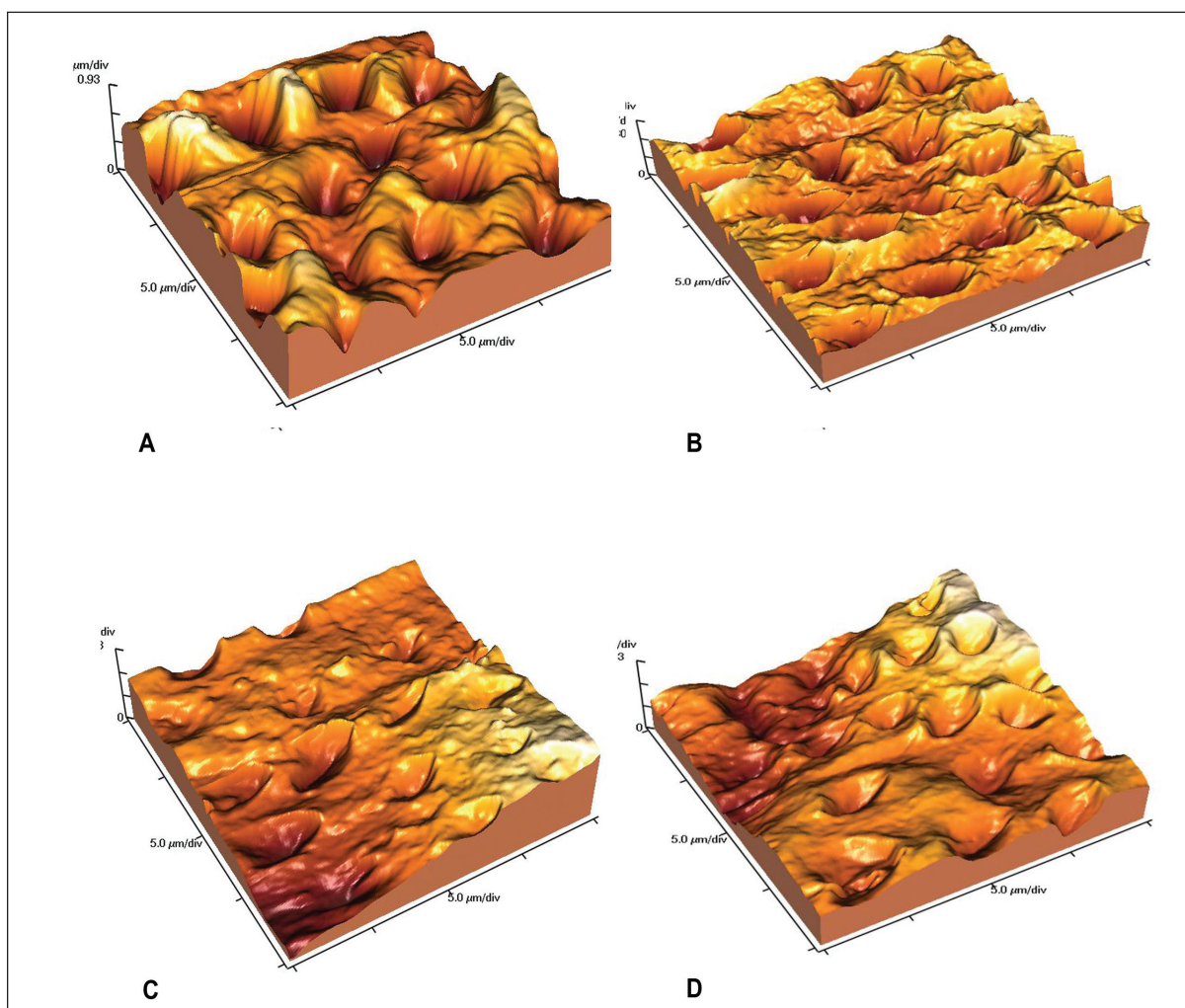
Carbamide peroxide is the most common agent used for tooth whitening. Overall, when carbamide peroxide comes in contact with the outer enamel surface, it breaks down into water and oxygen, which diffuses through the organic content of enamel. This causes oxidation of organic pigments that are mainly located within dentine, which results in a reduction or elimination of the discoloration.

When comparing hydrogen peroxide to carbamide peroxide, the approximate equivalent of 3.3% hydrogen peroxide equals 10% carbamide peroxide.<sup>29</sup> In accordance with Habelitz et al,<sup>37</sup> a cyclic model including periods of bleaching and remineralization with artificial saliva was used in this study to simulate physiological conditions during home bleaching procedures. It was assumed that a bleaching period of 8 h would reflect

the clinical situation. The amount of carbamide peroxide that was chosen would be sufficient to fully cover the surface of the enamel and dentin. The artificial saliva used had a pH of 6.7 and contained electrolytes to mimic human saliva.

The micromorphologic patterns of bleached enamel and dentin were also assessed using AFM. Compared to conventional microscopes (such as scanning electron microscopes, transmission electron microscopes and electron probe micro-analyzers) and other newer microscopes (such as confocal laser scanning microscopes and X-ray scanning analytical microscopes), AFM offers a powerful tool for directly observing demineralization because it offers advantages of high resolution and the potential to operate in the air or in solution. AFM can also provide quantitative data regarding surface morphology.<sup>31,32</sup>

In the present study, AFM evaluation of the alterations in surface topography after 16% carbamide peroxide cyclic bleach application for 14



**Figure 2.** Three-dimensional presentation of the AFM contact mode images of a dentin specimen prepolished with # 2500-grit silicon carbide abrasive paper, non bleached healthy dentin (A), bleached healthy dentin (B), non bleached uremic dentin (C) and bleached uremic dentin (D).

days on the enamel specimens obtained from healthy individuals revealed increased microporosities after bleaching. This is in accordance with Efeoglu et al<sup>24</sup> who concluded that in vitro application of 10% carbamide peroxide on enamel for two weeks causes demineralization of the enamel, extending to a depth of 50 µm below the enamel surface.

AFM images of bleached, healthy dentin showed that both intertubular and peritubular dentin was affected by carbamide peroxide, with peritubular dentin appearing more affected than intertubular dentin. This is likely due to the difference in chemical composition between the two. This is similar to a study by Chnga et al<sup>38</sup> who indicated that peritubular dentin is hyper-mineralized and lacks collagen as an organic component of its matrix. The authors also demonstrated that collagen is the major organic component of intertubular dentin, making up approximately 92% of the organic matrix.

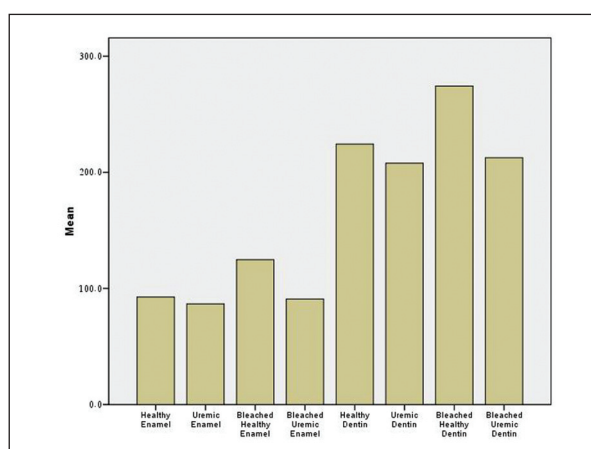


Figure 3. Descriptive presentation of means of surface roughness (Ra) by AFM.

Table 1. Surface roughness (Ra) measurements by AFM.

Enamel substrate	Ra (nm) Mean±SD	Dentin substrate	Ra (nm) Mean±SD
HE	92.5±1.7 a	HD	224.3±1.9 a
UE	86.7±1.2 a	UD	207.8±1.5 a
BHE	124.7±1.5 a	BHD	274.3±0.87 a
BUE	90.9±0.89 b	BUD	212±0.94 a

Values with the different letter are significantly different (P<.05). Ra: roughness average; nm: nanometer; SD: standard deviation.

Table 2. Analysis of variance- surface roughness.

Source	Sum-of-Squares	df	Mean-Square	F-Ratio	P
Between groups	380281.448	7	54325.921	27789.972	0.000
Within groups	140.751	72	1.955		
Total	380422.199	79			

Meanwhile, the AFM images of non-bleached uremic enamel showed flat topographic rod surfaces with shallow longitudinal grooves in between, while the enamel of these teeth when bleached showed small enamel grains that have a tendency for close packing with shallow porosities in between, which indicates a resistance to demineralization. This can be explained on the basis that uremia makes enamel more resistant to demineralization and agrees with the findings of a previous study that showed that the pH of the saliva of uremic patients receiving hemodialysis was alkaline because of the high concentration of ammonia as a result of ureal hydrolysis.<sup>12</sup>

The loss of metabolic control of calcium and phosphorus parallels the loss of renal function. Therefore, renal failure-mediated phosphate retention plus dietary phosphorus could lead to an increased phosphorus level in saliva up to 10-11 mg/dl in contrast to a normal level of 5-6 mg/dl. Consequently, one could speculate that uremia and its effect on the salivary phosphorus level and composition renders the enamel more acid resistant and therefore a cause for the decreased roughness after enamel bleaching compared to healthy enamel.<sup>14</sup>

Uremic non-bleached dentin specimens showed occlusion of dentinal tubules' lumens, and the effect of the bleaching agent was not observable on these teeth. These results are in agreement with previous studies,<sup>35,39</sup> which showed that characteristic changes analogous to those seen in bone were detected in dentin of erupted teeth in patients with CRF. A morphometric analysis of teeth extracted from healthy individuals and patients with CRF revealed that the predentin in pa-

tients suffering from CRF is significantly thicker than normal.<sup>40</sup> Van Meerbeek et al<sup>41</sup> suggested that demineralization is more difficult in both the peritubular and intertubular regions of sclerotic dentin.

Jandt<sup>42</sup> reported that surface roughness values obtained with AFM from different biomaterials can only be compared if the area of the obtained value is of similar size. In this study, AFM measurements were taken for a 20 µm x 20 µm area of the surface; the mean Ra of either bleached or non-bleached specimens varied significantly between the samples obtained from healthy individuals and uremic patients (P<.001). The mean values for the non-bleached uremic specimens showed the smallest Ra for enamel (86 nm) and dentin (207 nm), whereas the mean Ra values for the healthy bleached specimens were the highest for enamel (126 nm) and dentin (274 nm). Additionally, the roughness average of the bleached and non-bleached healthy specimens exceeded that of the uremic bleached and non-bleached ones. To our knowledge, there is no available data in the literature to confirm or contradict the results of the present study, and further investigations are still needed to further clarify these observations. Further clinical studies regarding the degree of bleaching of uremic teeth will also be necessary.

## CONCLUSIONS

On the basis of these results and despite the limitations of this study, it seems reasonable to conclude that the negative effects of using bleaching gel on uremic tooth substrates are less dramatic and non-destructive compared to healthy substrates because uremia confers different micromorphological surface changes.

## ACKNOWLEDGMENTS

The authors would like to thank Dr. Esam Nasar for his valuable assistance in revising this paper.

## REFERENCES

1. St Peter W. Introduction: chronic kidney disease: a burgeoning health epidemic. *J Manag Care Pharm* 2007;13:2-5.
2. Grassmann A, Gioberge S, Moeller S, Brown G. ESRD patients in 2004: global overview of patient numbers, treatment modalities and associated trends. *Nephrol Dial Transplant* 2005;20:2587-2593.
3. Klassen JT, Krasko BM. The dental health status of dialysis patients. *J Can Dent Assoc* 2002;68:34-38.
4. Proctor R, Kumar N, Stein A, Moles D, Porter S. Oral and dental aspects of chronic renal failure. *J Dent Res* 2005;84:199-208.
5. Carl W. Chronic renal disease and hyperparathyroidism: dental manifestations and management. *Compend Contin Educ Dent* 1987;8:697-704.
6. Jaffe EC, Roberts J, Chantler C, Carter JE. Dental maturity in children with chronic renal failure assessed from dental panoramic tomographs. *J Int Assoc Dent Child* 1990;20:54-58.
7. Ganibegovic M. Dental radiographic changes in chronic renal disease. *Med Arch* 2000;54:115-118.
8. Nasstrom K. Dentin formation after corticosteroid treatment. A clinical study and an experimental study on rats. *Swed Dent J* 1996;115:1-45.
9. Nasstrom K, Moller B, Petersson A. Effect on human teeth of renal transplantation: a postmortem study. *Scand J Dent Res* 1993;101:202-209.
10. Al Nowaiser A, Robert GJ, Trompeter RS, Wilson M, Lucas VS. Oral health in children with chronic renal failure. *Pediatr Nephrol* 2003;18:39-45.
11. Chuang SF, Sung JM, Kuo SC, Huang JJ, Lee SY. Oral and dental manifestations in diabetic and nondiabetic ureamic patients receiving hemodialysis. *Oral Surg Oral Med Oral Pathol Oral Radiol Endod* 2005;99:689-695.
12. Kho H, Lee S, Cheng S, Kim Y. Oral manifestations and salivary flow rate, pH and buffer capacity in patients with end-stage renal disease underlying hemodialysis. *Oral Surg Oral Med Oral Pathol Oral Radiol Endod* 1999;88:316-319.
13. Lucas VS, Robert CJ. Oro-dental health in children with chronic renal failure and after renal transplantation: a clinical review. *Pediatr Nephrol* 2005;20:1388-1394.
14. Mahmoud SH, Sobh MA, Zaher AR, Ghazy MH, Abdel Aziz KM. Bonding of resin composite to tooth structure of uremic patient receiving hemodialysis: shear bond strength and acid-etch patterns. *J Adhes Dent* 2008;10:335-338.
15. Sulieman M. An overview of bleaching techniques. I. History, chemistry, safety and legal aspects. *Dent Update* 2005;32:39-46.
16. Haywood VB, Heymann HO. Nightguard vital bleaching. *Quintessence Int* 1989;20:173-176.
17. Dahl JE, Pallesen U. Tooth bleaching—a critical review of the biological aspects. *Crit Rev Oral Biol Med* 2003;14:292-304.
18. Ben-Amar A, Liberman R, Gorfil C, Bernstein Y. Effect of mouthguard bleaching on enamel surface. *Am J Dent* 1995;8:29-32.

19. McGuckin RS, Babin JF, Meyer BJ. Alterations in human enamel surface morphology following vital bleaching. *J Prosthet Dent* 1992;68:754-760.
20. Potocnik I, Kosec L, Gaspersic D. Effect of 10% carbamide peroxide bleaching gel on enamel microhardness, microstructure, and mineral content. *J Endod* 2000;26:203-206.
21. Shannon H, Spencer P, Gross K, Tira D. Characterization of enamel exposed to 10% carbamide peroxide bleaching agents. *Quintessence Int* 1993;24:39-44.
22. Zalkind M, Arwaz JR, Goldman A, Rotstein I. Surface morphology changes in human enamel, dentin and cementum following bleaching: a scanning electron microscopy study. *Endod Dent Traumatol* 1996;12:82-88.
23. Attin T, Vollmer D, Wiegand A, Attin R, Betke H. Subsurface microhardness of enamel and dentin after different external bleaching procedures. *Am J Dent* 2005;18:8-12.
24. Efeoglu N, Wood D, Efeoglu C. Microcomputerised tomography evaluation of 10% carbamide peroxide applied to enamel. *J Dent* 2005;33:561-567.
25. Freitas PM, Basting RT, Rodrigues Jr AL, Serra MC. Effects of two 10% peroxide carbamide bleaching agents on dentin microhardness at different time intervals. *Quintessence Int* 2002;33:370-375.
26. Freitas PM, Turssi CP, Hara AT, Serra MC. Dentin microhardness during and after whitening treatments. *Quintessence Int* 2004;35:411-417.
27. Justino LM, Tames DR, Demarco FF. In situ and in vitro effects of bleaching with carbamide on human enamel. *Oper Dent* 2004;29:219-225.
28. Rotstein I, Dankner E, Goldman A, Heling I, Stabholz A, Zalkind M. Histochemical analysis of dental hard tissues following bleaching. *J Endod* 1996;22:23-26.
29. Wiegand A, Otto YA, Attin T. In vitro evaluation of toothbrushing abrasion of differently bleached bovine enamel. *Am J Dent* 2004;17:412-416.
30. Clasen AB, Ogaard B. Experimental intra-oral caries models in fluoride research. *Acta Odontol Scand* 1999;57:334-341.
31. Araujo EM, Barartieri LN, Vieira LC, Ritter AV. In situ effect of 10% carbamide peroxide on microhardness of human enamel: function of time. *J Esthet Restor Dent* 2003;15:166-173.
32. Basting RT, Rodrigues Jr AL, Serra MC. The effect of 10% carbamide peroxide bleaching material on microhardness of sound and demineralized enamel and dentin in situ. *Oper Dent* 2003;26:531-539.
33. Maia E, Baratieri LN, de Andrada MAC, Monteiro Jr S, Vieira LCC. The influence of two home-applied agents on enamel microhardness: an in situ study. *J Dent* 2008;36:2-7.
34. Arcari GM, Baratieri LN, Maia HP, de Freitas SFT. Influence of the duration of treatment using a 10% carbamide peroxide bleaching gel on dentin surface microhardness: an in situ study. *Quintessence Int* 2005;36:15-24.
35. Basting RT, Rodrigues Jr AL, Serra MC. Micromorphology and surface roughness of sound and demineralized enamel and dentin bleached with a 10% carbamide peroxide bleaching agent. *Am J Dent* 2007;20:97-102.
36. Arvidson K, Johansson EG. Galvanic currents between dental alloys in vitro. *Scand J Dent Res* 1985; 93:467-473.
37. Habelitz S, Balooch M, Marshall GW, Breunig TM, and Marshall SJ. AFM-based nanomechanical properties and storage of dentin and enamel. *Mater Res Soc Symp Proc* 676:Y.3.27.1-Y.3.27.5, 2001.
38. Chnga HK, Ramlib HN, Yapa AUJ, Lim CT. Effect of hydrogen peroxide on intertubular dentine. *J Dent* 2005;5:363-369.
39. Daley TD, Wysocki GP, Ulan RA. Dental changes in patients on chronic hemodialysis. *Canadian Dent Res* 1982;1:17-21.
40. Wysocki GP, Daly TD, Raymond A, Ulan MD. Pre-dentin changes in patients with chronic renal failure. *J Oral Surg* 1983;56:167-173.
41. Van Meerbeek B, Braem M, Lambrechts P, Vanherle G. Morphological characterization of the interface between resin and sclerotic dentin. *J Dent Res* 1994; 22:141-146.
42. Jandt KD. Atomic force microscopy of biomaterials surfaces and interfaces. *Surf Sci* 2001;491:303-332.