



Associations of cortical thickness, surface area and subcortical volumes with insight in drug-naïve adults with obsessive-compulsive disorder

Wanting Liu^{a,b}, Jun Gan^a, Jie Fan^a, Hong Zheng^a, Sihui Li^a, Raymond C.K. Chan^{c,d}, Changlian Tan^{e,**}, Xiongzhaohu^{a,b,*}

^a Medical Psychological Center, The Second Xiangya Hospital, Central South University, Changsha, Hunan, China

^b Medical Psychological Institute of Central South University, Changsha, Hunan, China

^c Neuropsychology and Applied Cognitive Neuroscience Laboratory, CAS Key Laboratory of Mental Health, Institute of Psychology, Chinese Academy of Sciences, Beijing, China

^d Department of Psychology, University of Chinese Academy of Sciences, Beijing, China

^e Department of Radiology, Second Xiangya Hospital, Central South University, Changsha, Hunan, China

ARTICLE INFO

Keywords:

Obsessive-compulsive disorder
Insight
Cortical thickness
Surface-based morphometry

ABSTRACT

Poor insight in obsessive-compulsive disorder (OCD) is associated with several adverse clinical outcomes. However, the neurobiological basis of this insight deficit is not clearly understood. The present study thus aimed to investigate associations of cortical thickness, cortical surface area and subcortical volumes with insight in a sample of drug-naïve adults with OCD. Forty-seven OCD patients and 42 healthy controls (HCs) underwent MRI scanning, depression and anxiety assessments. The Brown Assessment of Beliefs Scale (BABS) measured insight levels and patients were divided into two groups: poor insight (OCD-PI; $n = 21$), and good insight (OCD-GI; $n = 26$). Cortical thickness and surface area between groups were compared with whole-brain exploratory vertex-by-vertex analyses, while subcortical volumes were compared on a structure-by-structure basis. Partial correlation analyses were then performed to assess associations between regional cortical and subcortical measures and insight levels. OCD-GI and OCD-PI groups displayed partly shared, but also partly distinct brain structural alterations. Strikingly, OCD-PI showed decreased cortical thickness in the left superior frontal gyrus, left anterior cingulate cortex (ACC) and right inferior parietal gyrus, compared to both OCD-GI and HCs. Average cortical thickness extracted from these areas was further negatively correlated with BABS scores in the OCD-PI patients. Our findings suggest that poor insight in patients with OCD may have a neural substrate involving the left medial frontal and the right inferior parietal cortices.

1. Introduction

It is generally accepted that poor insight is a hallmark of psychotic disorders (Amador and David, 2004), the clinical significance of which was underscored due to its close relationship with treatment non-adherence (Leclerc et al., 2015). For many years, the study of insight has been primarily centered on schizophrenia (Mintz et al., 2003; Pousa et al., 2017), and only very recently it has become a focus of interest in obsessive-compulsive disorder (OCD). Up to 15–36% of OCD patients demonstrated poor insight into their symptoms and pathology (Catapano et al., 2010; Matsunaga et al., 2002). Importantly, poor insight in OCD has been linked with an array of less favorable clinical outcomes, including more severe OC symptoms (Bellino et al., 2005; Catapano et al., 2001; Ravi et al., 2004), lower age at illness onset

(Catapano et al., 2010; Matsunaga et al., 2002., Ravi et al., 2004), higher rates of psychiatric co-morbidity with depression (Ravi et al., 2004) and body dysmorphic disorder (Eisen et al., 2004), and insufficient responses to both behavior therapy (Himle et al., 2006; Mataix-Cols et al., 2002) and pharmacological interventions (Catapano et al., 2001, 2010; Erzegovesi et al., 2001; Ravi et al., 2004), all of which are believed to contribute to a worse prognosis. These results promote research efforts to elucidate the neurobiological mechanisms that underline poor insight in OCD.

Several studies suggested that insight in OCD has a structural brain basis. Evidence has come from studies examining neuropsychological correlates of poor insight in OCD and then detecting a significant relationship between poor insight and worse cognitive performance, such as executive function and verbal memory (Kashyap et al., 2012;

* Corresponding author at: Medical Psychological Center, The Second Xiangya Hospital, Central South University, Changsha, Hunan 410011, China.

** Co-corresponding author at: Department of Radiology of the Second Xiangya Hospital, Central South University, Changsha, Hunan 410011, China.

E-mail addresses: tanchanglian@csu.edu.cn (C. Tan), xiongzhaohu@csu.edu.cn (X. Zhu).

Kitis et al., 2007; Tumkaya et al., 2009), which are in turn associated with volume of specific brain regions (Choi et al., 2004; Christian et al., 2008). Compared to their good insight counterparts, OCD patients with poor insight demonstrated more severe neurological soft signs, indicating more extensive neurodevelopmental abnormalities in this subgroup (Karadag et al., 2011), which could be reflected in changes of brain morphometry. Aigner et al. (2005) directly compared Magnetic Resonance Imaging (MRI) findings between OCD patients with good and poor insight and found that the poor insight cohort showed a higher frequency of structural abnormalities. However, imaging findings in this study were qualitatively evaluated as abnormal or normal, from which we can only infer that poor insight would be at the more "organic" end of the spectrum. The neuroanatomical basis of poor insight in OCD remains largely unknown.

In recent years, surface-based morphometry (SBM) methods have been increasingly applied to investigate the neuroanatomical mechanisms of psychiatric disorders. Unlike the traditional voxel-based morphometry (VBM), which involves a generic voxel-wise comparison of regional concentration or volume of gray matter between different groups (Ashburner and Friston, 2000), SBM utilizes cortical geometric models to partition its constituent cortical thickness and surface area components, which are thought to have differing genetic determinants, phylogeny, and development trajectories (Armstrong et al., 1995; Joyner et al., 2009; Panizzon et al., 2009; Wierenga et al., 2014). It has been proposed that measures of cortical thickness and surface area reflect distinct aspects of the underlying neural architecture. For instance, according to the radial unit hypothesis, the cerebral cortex is organized into ontogenetic columns, and cells within a column have a common origin before moving to their location within the cortex during development (Rakic et al., 1988). In this model, cortical thickness is a marker for the number of cells within columns, whereas surface area primarily reflects the number of cortical columns (Rakic, 1988, 1995, 2007). It is easy to understand that reduction of cells in columns could first result in a thinner thickness but don't have to cause a significant decrease in surface area or volume. Therefore, surface-based analysis, especially the cortical thickness, has been proposed to be a more useful measure to assess the neuroanatomical patterns associated with the neurodegenerative process and a more biologically informative approach with particular sensitivity in capturing subtle, previously undetected anatomical changes (Kelly et al., 2013; Pereira et al., 2012).

In previous SBM studies, cortical abnormalities were well documented to be involved in the pathophysiology of OCD and have been linked to OCD-specific clinical characteristics (Fan et al., 2013; Fouche et al., 2017; Fullana et al., 2014; Kühn et al., 2013; Nakamae et al., 2012; Shin et al., 2007; Venkatasubramanian et al., 2012). A recent meta- and mega-analysis argued that cortical thickness and surface area represent distinct morphological features and may be differentially affected by different stages of illness and disease profiles of OCD (Boedhoe et al., 2017). Notably, emerging evidence has linked thickness reduction in the frontal, parietal as well as temporal regions with poor insight in schizophrenia and psychosis (Buchy et al., 2012, 2017; Emami et al., 2016). Though not examined in OCD patients yet, these results suggest that cortical measures could be helpful for better understanding the neural underpinnings of insight in OCD.

There are also potential links between subcortical volumes and insight. For example, verbal memory deficit was associated with poor insight in OCD (Kashyap et al., 2012; Kitis et al., 2007; Tumkaya et al., 2009), whose correlation may lie in regions beyond the cortex, especially in the hippocampus, which was generally regarded to be the core region for memory processing. Fan et al. (2017a) have found decreased spontaneous neural activity in the left hippocampus in OCD patients with poor insight when compared with healthy controls. Moreover, McFarland et al. (2013) detected a relationship between increased caudate, putamen and thalamus volumes, and impaired insight in first-episode affective and non-affective psychosis patients.

Thus, the present study was designed to clarify the neuroanatomical

correlates of insight by comparing both the cortical architectures and subcortical volumes in OCD patients with good versus poor insight. As psychotropic medication and age are known to affect cortical structures in OCD (Boedhoe et al., 2017; Fouche et al., 2017), we conducted our analyses in a sample of drug-naïve adults. As a means of comparison, a healthy control group was also included. Although this study is primarily exploratory, we expected to replicate previous results of cortical abnormalities in multiple brain regions in both OCD groups, with structural changes in OCD patients with poor insight presenting in a more widespread and severe manner. We also expected to find a relationship between decreased cortical thickness in the frontal, parietal and temporal cortices, as well as decreased hippocampus volume, and poor insight in OCD.

2. Materials and methods

2.1. Participants

Forty-seven drug-naïve OCD patients were recruited from the psychology clinic at Second and Third Xiangya Hospital of Central South University. To be eligible, patients fulfilled criteria for OCD, as confirmed by the Structured Clinical Interview for DSM-IV-TR Axis I Disorders-Patient Edition (First et al., 2001), administered to each patient by two experienced clinical psychiatrists. Exclusion criteria included: (a) a diagnosis of other axis I and II psychiatric disorders; (b) a present or previous history of major medical or neurological problems; (c) a present or previous history of drug or alcohol abuse; (d) pregnancy; (e) unable to obtain MRI. Forty-two healthy people were recruited as healthy controls (HCs). Each of the HCs underwent the Structured Clinical Interview for DSM-IV-TR Axis I Disorders-Non-patient version (First et al., 2002) to exclude any current or past Axis I and II disorders. The other exclusion criteria were the same as in the patient group.

All subjects were right-handed as assessed by the Edinburgh Handedness Inventory (Oldfield, 1971) and have an education for more than 9 years. The study was approved by the Ethics Committee of the Second Xiangya Hospital of Central South University. Prior to participating in this study, all subjects signed a written informed consent after being told all procedures involved.

2.2. Clinical assessment

OC symptoms severity was assessed in patients using the Yale-Brown Obsessive-Compulsive Scale (Y-BOCS; Goodman et al., 1989). The Chinese version of the Brown Assessment of Beliefs Scale (BABS; Niu et al., 2016) was used to measure insight levels. It is a 7-item semi-structured scale that was developed to evaluate multidimensional construct of insight across a variety of psychiatric conditions. Each item is rated on a 5-point Likert scale, ranging from 0 (non-delusional or least pathological) to 4 (delusional or most pathological). Patients were divided into two groups based on total BABS score in conjunction with rating on Item #1 "conviction": OCD patients with poor insight (OCD-PI; total BABS score ≥ 12 and Item #1 score ≥ 3) and patients with good insight (OCD-GI; total BABS score < 12 or Item #1 score < 3) (Fan et al., 2017a, 2017b). Consequently, of the 47 OCD patients enrolled, 21 were classified into the OCD-PI group and 26 into the OCD-GI group.

The Beck Depression Inventory (BDI; Beck et al., 1961) and the State-Trait Anxiety Inventory (STAI; Spielberger, 1983) were used to assess the severity of depressive and anxiety symptoms experienced by each participant, respectively, among all participants.

2.3. Image acquisition

MRI scans were collected on a Siemens Skyra 3-T magnetic resonance scanner with a 32-channel head coil at the Second Xiangya

Table 1
Demographic and clinical characteristics for participants in the study.

Characteristics	OCD-GI (n = 26)	OCD-PI (n = 21)	HCs (n = 42)	F/t/ χ^2	p
Age, years, mean (SD)	21.65 (3.83)	23.19 (3.75)	21.07 (2.46)	6.323	0.053
Gender, M/F	12/14	14/7	17/25	3.914	0.141
education, years, mean (SD)	14.03 (1.96)	14.04 (3.67)	15.02 (1.93)	1.371	0.259
Age of onset, years, mean (SD)	18.34 (3.87)	19.47 (4.63)		-0.912	0.367
Illness duration, month, mean (SD)	39.58 (43.36)	57.76 (59.76)		-1.168	0.251
STAI-S, mean (SD)	53.46 (11.72)	52.62 (13.31)	37.29(9.26)	22.720	<0.001
STAI-T, mean (SD)	58.92 (9.77)	58.62 (9.57)	41.57(10.23)	33.171	<0.001
BDI, mean (SD)	21.19 (10.96)	20.90 (12.21)	6.95(5.36)	26.509	<0.001
Y-BOCS, mean (SD)	20.73 (3.70)	22.95 (6.33)		-1.424	0.165
BABS, mean (SD)	7.23 (4.33)	16.29 (2.74)		-8.718	<0.001

OCD-GI, OCD with good insight; OCD-PI, OCD with poor insight; HCs, healthy controls; Y-BOCS, Yale-Brown Obsessive-Compulsive Scale; STAI-S, Spielberger State-Trait Anxiety Inventory-State Form; STAI-T, Spielberger State-Trait Anxiety Inventory-Trait Form; BDI, Beck Depression Inventory; BABS, Brown Assessment of Beliefs Scale.

F/t/ χ^2 : variables of age, education, STAI-T, STAI-S, and BDI were tested by one-way ANOVAs (results were indicated by F); Categorical data such as gender was tested using chi-squared tests (results were indicated by χ^2), and variables such as age of onset, duration, Y-BOCS and BABS were statistically tested by two-sample t-test (results were indicated by t); p, statistical significance, significant at $p < 0.05$.

Significant post hoc tests: STAI-S: OCD-GI > HCs, OCD-PI > HCs ($p < 0.001$); STAI-T: OCD-GI > HCs, OCD-PI > HCs ($p < 0.001$); BDI: OCD-GI > HCs, OCD-PI > HCs ($p < 0.001$).

Hospital of Central South University. For each subject, we obtained high resolution brain structural images by using a T1-weighted sagittal magnetization-prepared, rapid acquisition gradient-echo (MPRAG) sequence. The sequence parameters were as follows: repetition time (TR) = 1900 ms, echo time (TE) = 2.01 ms, flip angle (FA) = 9°, field of view (FOV) = 256 mm, slice thickness = 1.0 mm, matrix = 256 × 256, voxel size = 1.0 × 1.0 × 1.0 mm³ and 176 slices covering the whole brain.

2.4. Image processing

Cortical surface reconstruction and volumetric segmentation were performed using the FreeSurfer software v. 5.3.0 (<http://surfer.nmr.mgh.harvard.edu/>). The FreeSurfer automated processing pipeline was used, briefly involving motion correction, skull stripping, registration to FreeSurfer's Talairach atlas, intensity normalization, subcortical segmentation and cortical parcellation based on the Desikan-Killiany Atlas (Desikan et al., 2006; Fischl and Dale, 2000; Fischl et al., 2004). Cortical thickness was defined as the distance between equivalent vertices of the grey/white boundary and pial surface, whereas surface area was calculated as the sum of the area of the vertices falling within a given region on the white matter surface. Volumes of seven subcortical regions encompassing accumbens, amygdala, caudate nucleus, hippocampus, pallidum, putamen and thalamus, and estimated intracranial volume (eICV) were obtained from the automated procedure for volumetric measures implemented in FreeSurfer (Fischl et al., 2002, 2004).

2.5. Statistical analysis

Statistical analyses were carried out using SPSS software version 18.0. Demographic and clinical variables were compared with χ^2 test for categorical variables and independent-sample t-tests or one-way ANOVA for continuous variables. Pearson correlations were conducted to evaluate the relationships between insight levels and other clinical variables in OCD (e.g., Y-BOCS, BDI, and STAI scores, age of onset and illness duration).

Cortical measures were compared in a pairwise manner among groups by fitting a general linear model at each vertex with cortical thickness and cortical surface area respectively as dependent variables, group (OCD-PI, OCD-GI or HCs) as the independent variable, and age and gender as covariates. For the comparison between OCD-GI and OCD-PI, additional covariates including Y-BOCS and BDI scores, and age of onset were also controlled due to their potential effects on cortical measures (Boedhoe et al., 2017; Piras et al., 2015) and/or their

relationship with the BABS score (see details in Results section). To this end, vertex-wise estimates of cortical surface architecture were mapped into FreeSurfer default template and smoothed using a Gaussian kernel with a full width at half maximum (FWHM) of 15 mm. All results were corrected for multiple comparisons using a cluster-wise Monte Carlo simulation implemented in FreeSurfer (Hagler et al., 2006; Hayasaka and Nichols 2003). The Monte Carlo simulations test the data against an empirical null distribution of maximal suprathreshold cluster size across 10,000 iterations, using a primary cluster-forming threshold of $p < 0.05$, yielding clusters fully corrected for multiple comparisons across the surfaces. The p-values of the resulting clusters of the original data expressed as cluster-wise probability (CWP) represent the probability of detecting a maximum cluster of that size or larger during the simulation step. Clusters with a CPW $p < 0.05$ were regarded as significant in this study. Only clusters that survived multiple corrections were presented in the Results.

For the subcortical analyses, we used ANCOVAs with each subcortical volume as the dependent variable, group (OCD-PI, OCD-GI or HCs) as the independent variable, and age, gender, BDI scores, and eICV as covariates. Significant results ($p < 0.05$) were corrected using Bonferroni-Holmes procedure.

To further examine core regions that could account for poor insight in OCD, mean values were extracted from those impaired regions where significant differences in cortical thickness and surface area were observed between OCD-PI and OCD-GI. Partial correlation analyses between mean cortical values and subcortical measures, and BABS scores were then examined in OCD-GI and OCD-PI group separately, with the Y-BOCS score controlled as a covariate. Multiple comparisons for these correlation analyses were corrected using Bonferroni-Holmes procedure.

3. Results

3.1. Demographic and clinical characteristics

Demographic and clinical characteristics of the participants are found in Table 1.

There were no significant group differences in terms of age, gender, and education levels. Subscales of STAI and BDI scores differed among the three groups, with both OCD-PI and OCD-GI groups showing higher scores than HCs on all three measures, and no difference observed between the patient groups. Furthermore, no significant difference was found between the OCD-GI and OCD-PI in terms of age of onset, illness duration, and Y-BOCS scores. Among all the clinical variables, the BABS

Table 2
Correlations between BABS scores and other clinical variables in OCD patients.

	Y-BOCS		STAI-S		STAI-T		BDI		Age of onset		Illness duration	
	<i>r</i>	<i>p</i>	<i>r</i>	<i>p</i>	<i>r</i>	<i>p</i>	<i>r</i>	<i>p</i>	<i>r</i>	<i>p</i>	<i>r</i>	<i>p</i>
BABS	0.413	0.004	0.069	0.649	-0.020	0.893	0.095	0.531	0.038	0.802	-0.048	0.751

Y-BOCS, Yale-Brown Obsessive-Compulsive Scale; STAI-S, Spielberger State-Trait Anxiety Inventory-State Form; STAI-T, Spielberger State-Trait Anxiety Inventory-Trait Form; BDI, Beck Depression Inventory; BABS, Brown Assessment of Beliefs Scale.

r, Pearson's correlation coefficient; *p*, statistical significance, significant at $p < 0.05$.

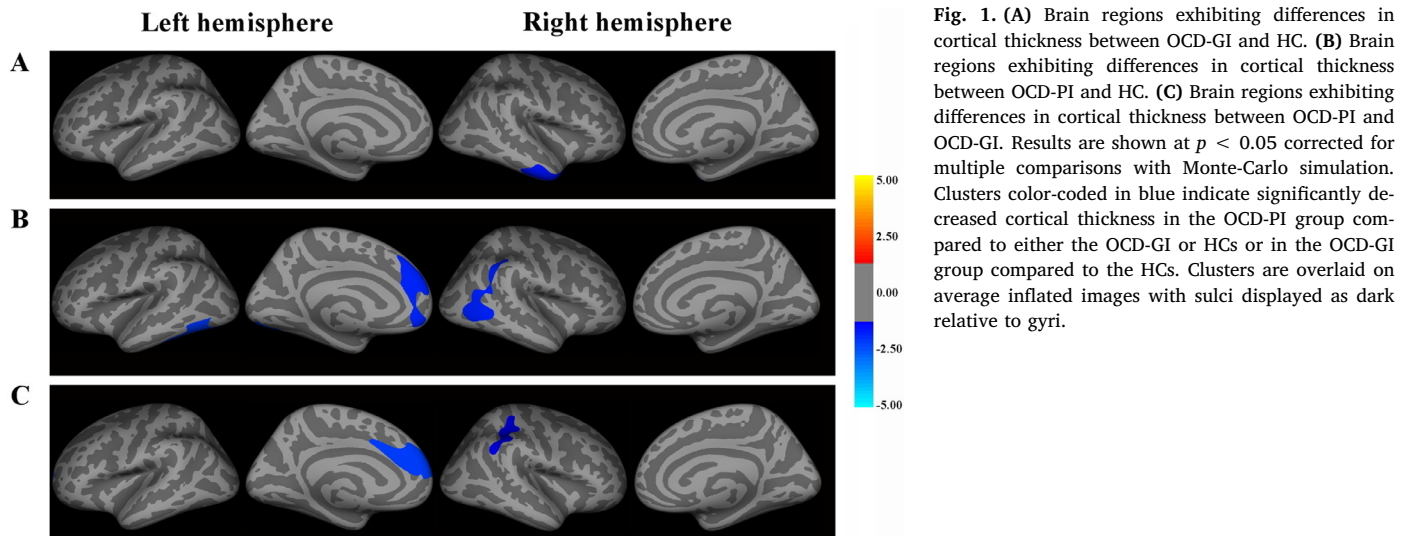


Fig. 1. (A) Brain regions exhibiting differences in cortical thickness between OCD-GI and HC. (B) Brain regions exhibiting differences in cortical thickness between OCD-PI and HC. (C) Brain regions exhibiting differences in cortical thickness between OCD-PI and OCD-GI. Results are shown at $p < 0.05$ corrected for multiple comparisons with Monte-Carlo simulation. Clusters color-coded in blue indicate significantly decreased cortical thickness in the OCD-PI group compared to either the OCD-GI or HCs or in the OCD-GI group compared to the HCs. Clusters are overlaid on average inflated images with sulci displayed as dark relative to gyri.

score was significantly correlated with the Y-BOCS score (see Table 2).

3.2. Group comparisons in cortical thickness and surface area

3.2.1. Cortical thickness

Group differences in cortical thickness are summarized in Fig. 1.

OCD-GI vs. HCs: The whole-brain analysis revealed a single cluster of decreased thickness in OCD-GI patients compared to controls in the left hemisphere which located in the temporal region, including the right middle gyrus, the inferior temporal gyrus, and the temporal pole. No significant group differences were found in the right hemisphere.

OCD-PI vs. HCs: Cortical thickness was significantly decreased in OCD-PI compared with HCs in several regions, mainly located in the left medial frontal lobes, including the left anterior cingulate cortex (ACC), and in the bilateral temporal lobes, but the right inferior parietal gyrus and a smaller lateral occipital region were also affected.

OCD-PI vs. OCD-GI: OCD-PI showed decreased cortical thickness compared to OCD-GI in two clusters. One is in the left hemisphere, including the superior frontal gyrus and ACC and the other is in the right lateral parietal regions with peak vertex in the inferior parietal gyrus.

3.2.2. Cortical surface area

There were no significant findings for all pairwise comparisons.

3.3. Group comparisons in subcortical volumes

ANCOVA analyses revealed significantly group difference in the left [$F_{(2,89)} = 3.901, p = 0.024$] and right [$F_{(2,89)} = 4.455, p = 0.015$] accumbens. No other significant effect of group was found on volumes of the thalamus, caudate, putamen, pallidum, hippocampus, or amygdala (all $ps > 0.05$). Post hoc tests showed smaller bilateral accumbens volumes in OCD-GI compared with HCs (left: $p = 0.007$; right: $p = 0.008$), with no difference between OCD-PI and HCs or between two patient

groups. Both results could not survive the Bonferroni-Holmes correction (lowest $p = 0.0036$).

3.4. Correlations between cortical thickness and insight level

We extracted average cortical thickness from the left superior frontal cluster and the right inferior parietal cluster and examined their correlation with insight levels in the OCD-GI and OCD-PI insight cohorts separately with Y-BOCS scores controlled. Results showed that cortical thickness in the left superior frontal cluster was correlated negatively with BABS scores in both OCD-GI ($r = -0.449, p = 0.021$, see Fig. 2A) and the OCD-PI ($r = -0.517, p = 0.016$, see Fig. 2B). For the inferior parietal cluster, correlation analyses revealed a significant relationship between mean cortical thickness and BABS scores in the OCD-PI group ($r = -0.508, p = 0.019$, see Fig. 2D) but this relationship was not significant in the OCD-GI group ($r = -0.238, p = 0.241$, see Fig. 2C). All significant correlations survived the Bonferroni-Holmes correction (lowest $p = 0.025$).

4. Discussion

To our knowledge, this is the first study to date having examined neurobiological basis underlying poor insight in OCD using an SBM approach, in which cortical thickness, cortical surface area as well as subcortical volumes were comprehensively compared among OCD patients with good and poor insight, and HCs. We observed a thinner cortex in OCD-PI in the left superior frontal gyrus and ACC as well as in the right lateral parietal region, when compared to both the OCD-GI group and HCs. Moreover, mean values of cortical thickness extracted from each cluster were further correlated with insight levels in the OCD-PI patients. By choosing a cohort of drug-naïve adult patients with OCD and controlling for illness severity, age of onset and depressive symptoms, we ruled out the effects of potential clinical confounders.

Consistent with our first hypothesis, we replicated previous findings

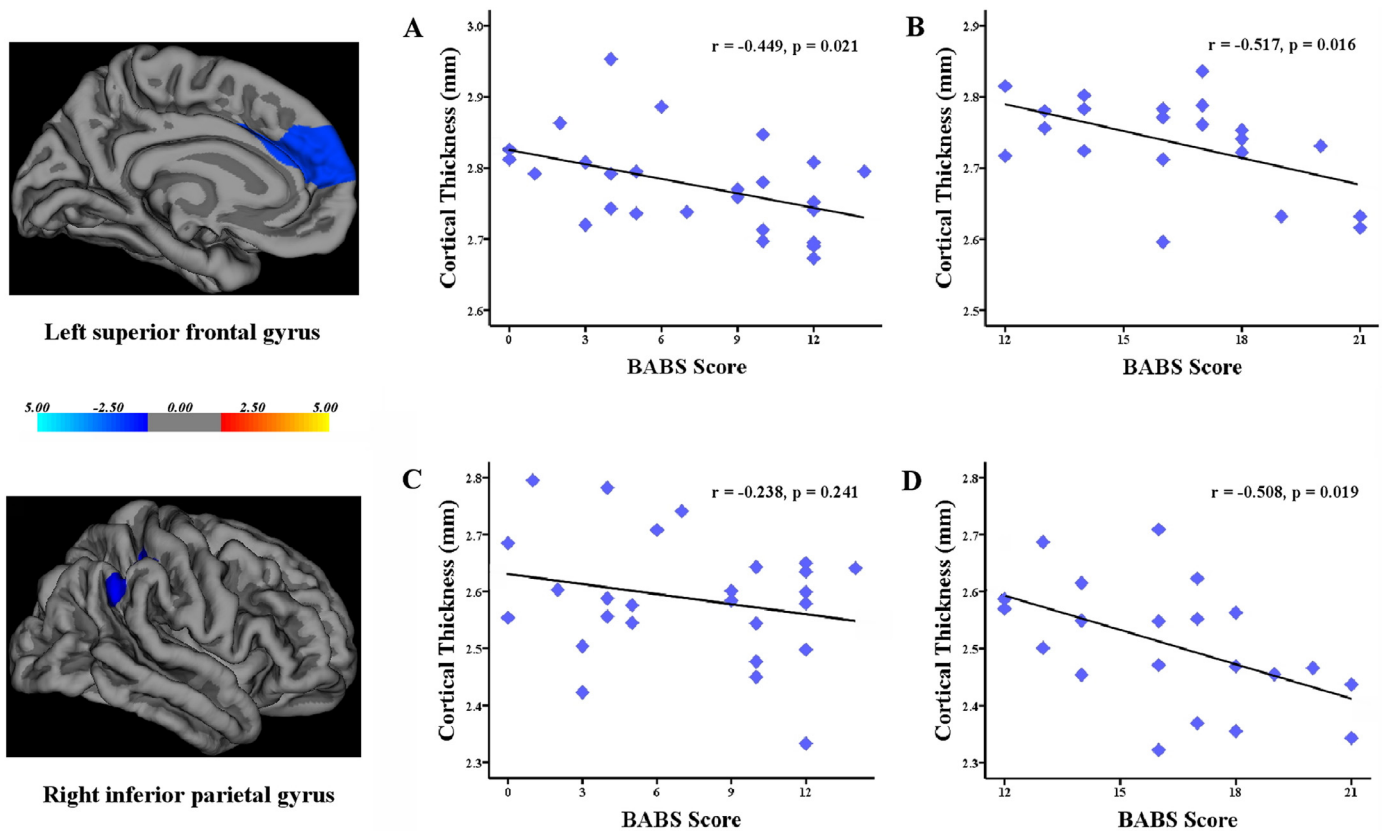


Fig. 2. Scatter plots showing significant negative correlations between BABS scores and average cortical thickness in the superior frontal cluster in OCD-GI group (A) and OCD-PI group (B); and in the right inferior parietal cluster in the OCD-GI group (C) and OCD-PI group (D), controlling for the Y-BOCS score (significant with Bonferroni-Holmes correction [0.05/2]).

by demonstrating decreased cortical thickness in the middle and inferior temporal gyri in both OCD-GI and OCD-PI (Fouche et al., 2017; Shin et al., 2007). Piras et al. (2015) also proposed a dorsolateral prefronto-striatal "executive" circuit to explain the involvement of temporal region in the pathophysiology of OCD. Our results thus indicate that cortical thickness is a sensitive and solid enough index to understand the neurobiological mechanisms associated with structural abnormalities in OCD. On the other hand, OCD-PI and OCD-GI displayed some distinct cortical characteristics. For example, while OCD-PI showed cortical thinning in the temporal pole, the OCD-GI showed that in the superior temporal gyrus (STG). Even for the same structures, their specific locations were different. This finding could help to explain the inconsistency in previous results, i.e., while some studies showed cortical thinning in a certain area, such as STG, others not. Besides, we observed more widespread cortical abnormalities encompassing medial frontal, lateral parietal and occipital regions in OCD-PI, which support the notion that the specifier "poor insight" helps to classify a subgroup of patients at the more severe end of OCD spectrum (Catapano et al., 2010).

The most outstanding finding of the current study is the identification of an association between cortical thinning in the left medial frontal cortex (including ACC) with poor insight. This decreased cortical thickness, which biologically represents the reduction of neurons within cortical columns, may be regarded as a reflection of insight-related neurodegenerative changes as having been suggested in a previous NSS study (Karadag et al., 2011). Since cortical thickness constitutes a reliable measure to identify brain-behavior relationships between regional structural changes and cognitive performance (Dickerson et al., 2008), and there is strong evidence of associations between reduced cortical thickness and impaired cognitive performance both in healthy population and disease (Hartberg et al., 2010;

Tuladhar et al., 2015), we would also like to explain our result from a functional perspective, mainly on the basis of connections between the median walls, particularly the ACC and the medial prefrontal cortex (mPFC), with limbic structures in an effort to management and integrate sensory and emotional information (Etkin et al., 2006; 2011). Some researchers have described appraisal functions of the mPFC and the ACC, such as representing the value of stimuli or actions (Kalisch et al., 2006; Ochsner and Gross, 2005; Rushworth et al., 2007). Decreased thickness of these areas may therefore be related to a deficit in the integration and evaluation of incoming signals from afferent limbic structures, which causes difficulty in tagging unusual mental events as pathological.

Besides, our results revealed that OCD-PI had decreased thickness in the right lateral parietal cortex, especially in the inferior parietal gyrus, compared with both OCD-PI and HCs. Moreover, in a poor insight cohort, there is a significant relationship between cortical thickness and insight level in this region. Our failure in detecting such a significant relationship in the OCD-GI group may be due to the relatively small sample size of the current study. Clearly, though, the parietal cortex played a role in determining insight in OCD patients. Interestingly, previous studies have linked lesions in the parietal lobe, especially in the right hemisphere, to anosognosia (i.e., unawareness of symptoms in neurological deficit, Bisiach et al., 1986; Ramachandran, 1995) and found reduced oligodendroglial density in the inferior parietal lobule (IPL) in schizophrenia patients with poor insight (Vostrikov et al., 2013). These similarities in insight-related structural abnormalities indicated that various psychiatric disorders and primary neurological disorders (associated with anosognosia) may share a similar basis of poor insight. This is also supported by evidence that frontal abnormalities have been ascribed a key role in the pathogenesis of poor insight in psychosis (Flashment et al., 2001; Sapaea et al., 2007; Shad et al.,

2006) and anosognosia (Pia et al., 2004).

The involvement of the inferior parietal cortex may be explained by its role in self-other discrimination (Uddin et al., 2006). Specifically, a network comprising the mPFC, ACC and IPL, but also the PCC and insula has been proposed to be involved in the self-reflection (van der Meer et al., 2010), an ability to process information about the "self", and in patients, representing their capacity to self-reflect, to question unusual mental experiences and willingness to consider alternative explanations. Functional MRI studies have demonstrated an involvement of self-reflection networks underlying poor insight in schizophrenia (Ćurčić-Blake et al., 2015; van der Meer et al., 2012). Moreover, a specific metacognitive dimension of insight (i.e. cognitive insight) has been hypothesized (Orfei et al., 2013; Buchy et al., 2016) and in these studies, reduced volume or thickness in the prefrontal and parietal regions has been reported to correlate with lower self-reflectiveness. Hence, it is plausible that decreased thickness in the medial frontal and inferior parietal regions was involved in the pathophysiology of insight in OCD via their role in metacognition, especially in self-reflectiveness. This would be true since impaired metacognition and theory of mind (ToM) have been reported in OCD patients with poor insight (Önen et al., 2013; Tulacı et al., 2018). However, it still needs further functional MRI studies which include self-reflection tasks to confirm these associations and elucidate its neural mechanism.

Finally, we failed to find a significant relationship between subcortical volumes, for instance, the hippocampus volume, and insight, indicating that the effect of subcortical structures on insight may be minimal. This may be due to insight in OCD was related to higher-order cognitive processing such as executive function, verbal working memory and metacognition (Kashyap et al., 2012; Önen et al., 2013; Tumkaya et al., 2009), whose correlations are mainly lie in cortical structures. Another explanation is that the subcomponents of subcortical structures may have distinct roles. Further studies that assess the link between insight and subfields of these subcortical structures may draw out a different picture.

There are several limitations to be mentioned in the present study. First, it should be noted that the BABS employed in our study assessed the severity of a multidimensional construct of insight resulting in a total score. Such being this case, individuals who rate the same scores on this measure could exhibit very different insight profiles. Unfortunately, this problem has not been resolved, and the BABS is still one of the best and the most popular instruments available for assessing insight in OCD; second, this is a preliminary study restricted to structural neural correlates of insight with relatively small sample size. Future studies to replicate and extend these findings are needed.

5. Conclusions

Taken together, an association between thickness reduction in the left superior frontal gyrus, the left ACC and the right inferior parietal regions, and poor insight in OCD patients was observed. We thus propose that cortical thinning in the left medial frontal and right inferior parietal cortices may be neural underpinnings of poor insight in OCD. In spite of the aforementioned limitations, our structural data points to the need for future studies to investigate the structural, functional, and neurochemical correlates of insight deficits in OCD.

Funding

This work was supported by the National Key Technology Research and Development Program of the Ministry of Science and Technology of China(2012BA136B01), the Beijing Training Project for the Leading Talents in S&T (Z151100000315020), and the Strategic Priority Research Program (B) of the Chinese Academy of Science (XDB02030002).

CRedit authorship contribution statement

Wanting Liu: Formal analysis, Writing - original draft. **Jun Gan:** Data curation. **Jie Fan:** Data curation. **Hong Zheng:** Data curation. **Sihui Li:** Data curation. **Raymond C.K. Chan:** Supervision. **Changlian Tan:** Conceptualization. **Xiongzhuo Zhu:** Conceptualization.

Declaration of Competing Interest

None.

Acknowledgement

The authors thank all the participants for their invaluable contribution to this study.

References

- Aigner, M., Zitterler, W., Prayer, D., Demal, U., Bach, M., Prayer, L., et al., 2005. Magnetic resonance imaging in patients with obsessive-compulsive disorder with good versus poor insight. *Psychiatry Res.* 140, 173–179. <https://doi.org/10.1016/j.psychres.2005.03.002>.
- Amador, X.F., David, A.S., 2004. *Insight and Psychosis: Awareness of Illness in Schizophrenia and Related Disorders*, second ed. Oxford University Press, New York.
- Armstrong, E., Schleicher, A., Omran, H., Curtis, M., Zilles, K., 1995. The ontogeny of human gyrification. *Cereb. Cortex.* 5, 56–63. <https://doi.org/10.1093/cercor/5.1.56>.
- Ashburner, J., Friston, K.J., 2000. Voxel-based morphometry—the methods. *Neuroimage* 11, 805–821. <https://doi.org/10.1006/nimg.2000.0582>.
- Beck, A.T., Ward, C.H., Mendelson, M., Mock, J., Erbaugh, J., 1961. An inventory for measuring depression. *Arch. Gen. Psychiatry* 4, 561–571. <https://doi.org/10.1001/archpsyc.1961.01710120031004>.
- Bellino, S., Patria, L., Ziero, S., Bogetto, F., 2005. Clinical picture of obsessive-compulsive disorder with poor insight: a regression model. *Psychiatry Res.* 136, 223–231. <https://doi.org/10.1016/j.psychres.2004.04.015>.
- Bisiach, E., Vallar, G., Perani, D., Papagno, C., Berti, A., 1986. Unawareness of disease following lesions of the right hemisphere: anosognosia for hemiplegia and anosognosia for hemianopia. *Neuropsychologia* 24, 471–482. [https://doi.org/10.1016/0028-3932\(86\)90092-8](https://doi.org/10.1016/0028-3932(86)90092-8).
- Boedhoe, P.S.W., Schmaal, L., Abe, Y., Alonso, P., Ameis, S.H., Anticevic, A., et al., 2017. Cortical abnormalities associated with pediatric and adult obsessive-compulsive disorder: findings from the enigma obsessive-compulsive disorder working group. *Am. J. Psychiatry* 175, 453–462. <https://doi.org/10.1176/appi.ajp.2017.17050485>.
- Buchy, L., Ad-Dab'bagh, Y., Lepage, C., Malla, A., Joobar, R., Evans, A., et al., 2012. Symptom attribution in first episode psychosis: a cortical thickness study. *Psychiatry Res.* 203, 6–13. <https://doi.org/10.1016/j.psychres.2011.09.009>.
- Buchy, L., Barbato, M., Macmaster, F.P., Bray, S., Clark, D., Deighton, S., et al., 2016. Cognitive insight is associated with cortical thickness in first-episode psychosis. *Schizophr. Res.* 172, 16–22. <https://doi.org/10.1016/j.schres.2016.02.026>.
- Buchy, L., Makowski, C., Malla, A., Joobar, R., Lepage, M., 2017. Longitudinal trajectory of clinical insight and covariation with cortical thickness in first-episode psychosis. *J. Psychiatr. Res.* 86, 46–54. <https://doi.org/10.1016/j.jpsychires.2016.11.008>.
- Catapano, F., Perris, F., Fabrazzo, M., Cioffi, V., Giacco, D., De Santis, V., et al., 2010. Obsessive-compulsive disorder with poor insight: a three-year prospective study. *Prog. Neuropsychopharmacol. Biol. Psychiatry* 34, 323–330. <https://doi.org/10.1016/j.pnpbp.2009.12.007>.
- Catapano, F., Sperandio, R., Perris, F., Lanzaro, M., Maj, M., 2001. Insight and resistance in patients with obsessive-compulsive disorder. *Psychopathology.* 34, 62–68. <https://doi.org/10.1159/000049282>.
- Choi, J.S., Kang, D.H., Kim, J.J., Ha, T.H., Lee, J.M., Youn, T., et al., 2004. Left anterior subregion of orbitofrontal cortex volume reduction and impaired organizational strategies in obsessive-compulsive disorder. *J. Psychiatr. Res.* 38, 193–199.
- Christian, C.J., Lencz, T., Robinson, D.G., Burdick, K.E., Ashtari, M., Malhotra, A.K., et al., 2008. Gray matter structural alterations in obsessive-compulsive disorder: relationship to neuropsychological functions. *Psychiatry Res.* 164, 123–131. <https://doi.org/10.1016/j.psychres.2008.03.005>.
- Ćurčić-Blake, B., van der Meer, L., Pijnenborg, G.H., David, A.S., Aleman, A., 2015. Insight and psychosis: functional and anatomical brain connectivity and self-reflection in schizophrenia. *Hum. Brain. Mapp.* 36, 4859–4868. <https://doi.org/10.1002/hbm.22955>.
- Desikan, R.S., Ségonne, F., Fischl, B., Quinn, B.T., Dickerson, B.C., Blacker, D., et al., 2006. An automated labeling system for subdividing the human cerebral cortex on MRI scans into gyral based regions of interest. *Neuroimage* 31, 968–980. <https://doi.org/10.1016/j.neuroimage.2006.01.021>.
- Dickerson, B.C., Fenstermacher, E., Salat, D.H., Wolk, D.A., Maguire, R.P., Desikan, R., et al., 2008. Detection of cortical thickness correlates of cognitive performance: reliability across mri scan sessions, scanners, and field strengths. *Neuroimage* 39, 10–18. <https://doi.org/10.1016/j.neuroimage.2007.08.042>.
- Eisen, J.L., Phillips, K.A., Coles, M.E., Rasmussen, S.A., 2004. Insight in obsessive compulsive disorder and body dysmorphic disorder. *Compr. Psychiatry* 45, 10–15. <https://doi.org/10.1016/j.comppsy.2003.09.010>.

- Emami, S., Guimond, S., Mallar, C.M., Lepage, M., 2016. Cortical thickness and low insight into symptoms in enduring schizophrenia. *Schizophr. Res.* 170, 66–72. <https://doi.org/10.1016/j.schres.2015.10.016>.
- Erzegovesi, S., Cavallini, M.C., Cavellini, P., Diaferia, G., Locatelli, M., Bellodi, L., 2001. Clinical predictors of drug response in obsessive-compulsive disorder. *J. Clin. Psychopharmacol.* 21, 488–492. [https://doi.org/10.1016/S0924-977X\(02\)80566-1](https://doi.org/10.1016/S0924-977X(02)80566-1).
- Etkin, A., Egner, T., Kalisch, R., 2011. Emotional processing in anterior cingulate and medial prefrontal cortex. *Trends Cogn. Sci.* 15, 85–93. <https://doi.org/10.1016/j.tics.2010.11.004>.
- Etkin, A., Egner, T., Peraza, D.M., Eric, R.K., Hirsch, J., 2006. Resolving emotional conflict: a role for the rostral anterior cingulate cortex in modulating activity in the amygdala. *Neuron* 51, 871–882. <https://doi.org/10.1016/j.neuron.2006.07.029>.
- Fan, J., Zhong, M., Gan, J., Liu, W., Niu, C., Liao, H., et al., 2017a. Spontaneous neural activity in the right superior temporal gyrus and left middle temporal gyrus is associated with insight level in obsessive-compulsive disorder. *J. Affect. Disord.* 207, 203–211. <https://doi.org/10.1016/j.jad.2016.08.027>.
- Fan, J., Zhong, M., Zhu, X., Gan, J., Liu, W., Niu, C., et al., 2017b. Resting-state functional connectivity between right anterior insula and right orbital frontal cortex correlate with insight level in obsessive-compulsive disorder. *Neuroimage. Clin.* 15, 1–7. <https://doi.org/10.1016/j.nicl.2017.04.002>.
- Fan, Q., Palaniyappan, L., Tan, L., Wang, J., Wang, X., Li, C., et al., 2013. Surface anatomical profile of the cerebral cortex in obsessive-compulsive disorder: a study of cortical thickness, folding and surface area. *Psychol. Med.* 43, 1081–1091. <https://doi.org/10.1017/S0033291712001845>.
- First, M.B., Spitzer, R.L., Gibbon, M., Williams, J.B.W., 2001. Structured Clinical Interview for DSM-IV-TR Axis I Disorders, Research Version, Patient Edition. New York State Psychiatric Institute, New York.
- First, M.B., Spitzer, R.L., Gibbon, M., Williams, J.B.W., 2002. Structured Clinical Interview for DSM-IV-TR Axis I Disorders, Research Version, Non-Patient Edition. New York State Psychiatric Institute, New York.
- Fischl, B., Dale, A.M., 2000. Measuring the thickness of the human cerebral cortex from magnetic resonance images. *Proc. Natl. Acad. Sci.* 97, 11050–11055. <https://doi.org/10.1073/pnas.200033797>.
- Fischl, B., Salat, D.H., Busa, E., Albert, M., Dieterich, M., Haselgrove, C., et al., 2002. Whole brain segmentation: automated labeling of neuroanatomical structures in the human brain. *Neuron* 33, 341–355. [https://doi.org/10.1016/S0896-6273\(02\)00569-X](https://doi.org/10.1016/S0896-6273(02)00569-X).
- Fischl, B., van der Kouwe, A., Destrieux, C., Halgren, E., Ségonne, F., Salat, D.H., et al., 2004. Automatically parcellating the human cerebral cortex. *Cereb. Cortex.* 14, 11–22. <https://doi.org/10.1093/cercor/bhg087>.
- Flashman, L.A., McAllister, T.W., Johnson, S.C., Rick, J.H., Green, R.L., Saykin, A.J., 2001. Specific frontal lobe subregions correlated with unawareness of illness in schizophrenia: a preliminary study. *J. Neuropsychiatry Clin. Neurosci.* 13, 255–257. <https://doi.org/10.1176/jnp.13.2.255>.
- Fouche, J.P., du Plessis, S., Hattings, C., Roos, A., Lochner, C., Soriano-Mas, C., et al., 2017. Cortical thickness in obsessive-compulsive disorder: multisite mega-analysis of 780 brain scans from six centres. *Br. J. Psychiatry* 210, 67–74. <https://doi.org/10.1192/bjp.bp.115.164020>.
- Fullana, M.A., Cardoner, N., Alonso, P., Subirà, M., López-Solà, C., Pujol, J., et al., 2014. Brain regions related to fear extinction in obsessive-compulsive disorder and its relation to exposure therapy outcome: a morphometric study. *Psychol. Med.* 44, 845–856. <https://doi.org/10.1017/S0033291713001128>.
- Goodman, W.K., Price, L.H., Rasmussen, S.A., Mazure, C., Fleischmann, R.L., Hiller, C.L., et al., 1989. The Yale-Brown obsessive compulsive scale: I. Development, use, and reliability. *Arch. Gen. Psychiatry* 46, 1006–1111. <https://doi.org/10.1001/archpsyc.1989.01810110048007>.
- Hagler, D.J., Saygin, A.P., Sereno, M.I., 2006. Smoothing and cluster thresholding for cortical surface-based group analysis of fMRI data. *Neuroimage* 33, 1093–1103. <https://doi.org/10.1016/j.neuroimage.2006.07.036>.
- Hartberg, C.B., Lawyer, G., Nyman, H., Jönsson, E.G., Haukvik, U.K., Saetre, P., et al., 2010. Investigating relationships between cortical thickness and cognitive performance in patients with schizophrenia and healthy adults. *Psychiatry Res.* 182, 123–133. <https://doi.org/10.1016/j.psychres.2010.01.001>.
- Hayasaka, S., Nichols, T.E., 2003. Validating cluster size inference: random field and permutation methods. *Neuroimage* 20, 2343–2356. <https://doi.org/10.1016/j.neuroimage.2003.08.003>.
- Himle, J.A., Van Etten, M.L., Janeck, A.S., Fischer, D.J., 2006. Insight as a predictor of treatment outcome in behavioral group treatment for obsessive-compulsive disorder. *Cognitive. Ther. Res.* 30, 661–666. <https://doi.org/10.1007/s10608-006-9079-9>.
- Joyner, A.H., J., C.R., Bloss, C.S., Bakken, T.E., Rimol, L.M., Melle, I., et al., 2009. A common mecp2 haplotype associates with reduced cortical surface area in humans in two independent populations. *Proc. Natl. Acad. Sci.* 106, 15483–15488. <https://doi.org/10.1073/pnas.0901866106>.
- Kalisch, R., Wiech, K., Critchley, H.D., Dolan, R.J., 2006. Levels of appraisal: a medial prefrontal role in high-level appraisal of emotional material. *Neuroimage* 30, 1458–1466. <https://doi.org/10.1016/j.neuroimage.2005.11.011>.
- Karadag, F., Tumkaya, S., Kırtas, D., Efe, M., Alacam, H., Oguzhanoglu, N.K., 2011. Neurological soft signs in obsessive compulsive disorder with good and poor insight. *Prog. Neuropsychopharmacol. Biol. Psychiatry* 35, 1074–1079. <https://doi.org/10.1016/j.pnpbp.2011.03.003>.
- Kashyap, H., Kumar, J.K., Kandavel, T., Reddy, Y.C., 2012. Neuropsychological correlates of insight in obsessive-compulsive disorder. *Acta Psychiatr. Scand.* 126, 106–114. <https://doi.org/10.1111/j.1600-0447.2012.01845.x>.
- Kelly, P.A., Viding, E., Wallace, G.L., Schaefer, M., De Brito, S.A., Robustelli, B., et al., 2013. Cortical thickness, surface area, and gyrification abnormalities in children exposed to maltreatment: neural markers of vulnerability? *Biol. Psychiatry* 74, 845–852. <https://doi.org/10.1016/j.biopsych.2013.06.020>.
- Kitis, A., Akdede, B.B., Alptekin, K., Akvardar, Y., Arkar, H., Erol, A., et al., 2007. Cognitive dysfunctions in patients with obsessive-compulsive disorder compared to the patients with schizophrenia patients: relation to overvalued ideas. *Prog. Neuropsychopharmacol. Biol. Psychiatry* 31, 254–261. <https://doi.org/10.1016/j.pnpbp.2006.06.022>.
- Kühn, S., Kaufmann, C., Simon, D., Endrass, T., Gallinat, J., Kathmann, N., 2013. Reduced thickness of anterior cingulate cortex in obsessive-compulsive disorder. *Cortex* 49, 2178–2185. <https://doi.org/10.1016/j.cortex.2012.09.001>.
- Leclerc, E., Noto, C., Bressan, R.A., Brietzke, E., 2015. Determinants of adherence to treatment in first-episode psychosis: a comprehensive review. *Braz. J. Psychiatry* 37, 168–176. <https://doi.org/10.1590/1516-4446-2014-1539>.
- Mataix-Cols, D., Marks, I.M., Greist, J.H., Kobak, K.A., Baer, L., 2002. Obsessive-compulsive symptom dimensions as predictors of compliance with and response to behaviour therapy: results from a controlled trial. *Psychother. Psychosom.* 71, 255–262. <https://doi.org/10.1159/000064812>.
- Matsunaga, H., Kirilke, N., Matsui, T., Oya, K., Iwasaki, Y., Koshimune, K., et al., 2002. Obsessive-compulsive disorder with poor insight. *Compr. Psychiatry* 43, 150–157. <https://doi.org/10.1053/comp.2002.30798>.
- Mcfarland, J., Cannon, D.M., Schmidt, H., Ahmed, M., Hehir, S., Emsell, L., et al., 2013. Association of grey matter volume deviation with insight impairment in first-episode affective and non-affective psychosis. *Eur. Arch. Psychiatry Clin. Neurosci.* 263, 133–141. <https://doi.org/10.1007/s00406-012-0333-8>.
- Mintz, A.R., Dobson, K.S., Romney, D.M., 2003. Insight in schizophrenia: a meta-analysis. *Schizophr. Res.* 61, 75–88. [https://doi.org/10.1016/S0920-9964\(02\)00316-X](https://doi.org/10.1016/S0920-9964(02)00316-X).
- Nakamae, T., Narumoto, J., Sakai, Y., Nishida, S., Yamada, K., Kubota, M., et al., 2012. Reduced cortical thickness in non-medicated patients with obsessive-compulsive disorder. *Prog. Neuropsychopharmacol. Biol. Psychiatry* 37, 90–95. <https://doi.org/10.1016/j.pnpbp.2012.01.001>.
- Niu, C., Liu, W., Lei, H., Gan, J., Fan, J., Wang, X., et al., 2016. The Chinese version of the brown assessment of beliefs scale: psychometric properties and utility in obsessive compulsive disorder. *J. Obsess-Compuls. Rel.* 11, 39–42. <https://doi.org/10.1016/j.jocrd.2016.08.003>.
- Ochsner, K.N., Gross, J.J., 2005. The cognitive control of emotion. *Trends Cogn. Sci.* 9, 242–249. <https://doi.org/10.1016/j.tics.2005.03.010>.
- Oldfield, R.C., 1971. The assessment and analysis of handedness: the Edinburgh inventory. *Neuropsychologia* 9, 97–113. [https://doi.org/10.1016/0028-3932\(71\)90067-4](https://doi.org/10.1016/0028-3932(71)90067-4).
- Önen, S., Karakaş, U.G., Çayköylü, A., 2013. The relationship between metacognitions and insight in obsessive-compulsive disorder. *Compr. Psychiatry* 54, 541–548. <https://doi.org/10.1016/j.comppsych.2012.11.006>.
- Orfei, M., Piras, F., Macci, E., Caltagirone, C., Spalletta, G., 2013. The neuroanatomical correlates of cognitive insight in schizophrenia. *Soc. Cogn. Affect. Neurosci.* 8, 418–423. <https://doi.org/10.1093/scan/nss016>.
- Panizzon, M.S., Fennema-Notestine, C., Eyler, L.T., Jernigan, T.L., Prom-Wormley, E., Neale, M., et al., 2009. Distinct genetic influences on cortical surface area and cortical thickness. *Cereb. Cortex.* 19, 2728–2735. <https://doi.org/10.1093/cercor/bhp026>.
- Pereira, J.B., Ibarretxe-Bilbao, N., Martí, M.J., Compta, Y., Junqué, C., Bargallo, N., et al., 2012. Assessment of cortical degeneration in patients with parkinson's disease by voxel-based morphometry, cortical folding, and cortical thickness. *Hum. Brain. Mapp.* 33, 2521–2534. <https://doi.org/10.1002/hbm.21378>.
- Pia, L., Neppi-Modona, M., Ricci, R., Berti, A., 2004. The anatomy of anosognosia for hemiplegia: a meta-analysis. *Cortex* 40, 367–377. [https://doi.org/10.1016/S0010-9452\(08\)70131-X](https://doi.org/10.1016/S0010-9452(08)70131-X).
- Piras, F., Piras, F., Chiapponi, C., Girardi, P., Caltagirone, C., Spalletta, G., 2015. Widespread structural brain changes in ocd: a systematic review of voxel-based morphometry studies. *Cortex* 62, 89–108. <https://doi.org/10.1016/j.cortex.2013.01.016>.
- Pousa, E., Ochoa, S., Cobo, J., Nieto, L., Usall, J., Gonzalez, B., et al., 2017. A deeper view of insight in schizophrenia: insight dimensions, unawareness and misattribution of particular symptoms and its relation with psychopathological factors. *Schizophr. Res.* 189, 61–68. <https://doi.org/10.1016/j.schres.2017.02.016>.
- Rakic, P., 1988. Defects of neuronal migration and the pathogenesis of cortical malformations. *Prog. Brain Res.* 73, 15–37. [https://doi.org/10.1016/S0079-6123\(08\)60494-X](https://doi.org/10.1016/S0079-6123(08)60494-X).
- Rakic, P., 1995. A small step for the cell, a giant leap for mankind: a hypothesis of neocortical expansion during evolution. *Trends Neurosci.* 18, 383–388. [https://doi.org/10.1016/0166-2236\(95\)93934-P](https://doi.org/10.1016/0166-2236(95)93934-P).
- Rakic, P., 2007. The radial edifice of cortical architecture: from neuronal silhouettes to genetic engineering. *Brain Res. Rev.* 55, 204–219. <https://doi.org/10.1016/j.brainresrev.2007.02.010>.
- Ramachandran, V.S., 1995. Anosognosia in parietal lobe syndrome. *Conscious. Cogn.* 4, 22–51. <https://doi.org/10.1006/ccog.1995.1002>.
- Ravi, K.V., Samar, R., Janardhan, R.Y.C., Chandrasekhar, C.R., Thennarasu, K., 2004. Clinical characteristics and treatment response in poor and good insight obsessive-compulsive disorder. *Eur. Psychiatry* 19, 202–208. <https://doi.org/10.1016/j.eurpsy.2003.12.005>.
- Rushworth, M.F., Buckley, M.J., Behrens, T.E., Walton, M.E., Bannerman, D.M., 2007. Functional organization of the medial frontal cortex. *Curr. Opin. Neurobiol.* 17, 220–227. <https://doi.org/10.1016/j.conb.2007.03.001>.
- Sapara, A., Cooke, M., Fannon, D., Francis, A., Buchanan, R.W., Anilkumar, A.P., et al., 2007. Prefrontal cortex and insight in schizophrenia: a volumetric MRI study. *Schizophr. Res.* 89, 22–34. <https://doi.org/10.1016/j.schres.2006.09.016>.
- Shad, M.U., Muddasani, S., Keshavan, M.S., 2006. Prefrontal subregions and dimensions of insight in first-episode schizophrenia — a pilot study. *Psychiatry Res.* 146, 35–42.
- Shin, Y.W., Yoo, S.Y., Lee, J.K., Ha, T.H., Lee, K.J., Lee, J.M., et al., 2007. Cortical

- thinning in obsessive compulsive disorder. *Hum. Brain. Mapp.* 28, 1128–1135. <https://doi.org/10.1002/hbm.20338>.
- Spielberger, D.C., 1983. *Manual For the State-Trait Anxiety Inventory (Form Y) ("self-evaluation questionnaire")*. Consulting Psychologists Press, Palo Alto.
- Tulacı, R.G., Cankurtaran, E.Ş., Özdel, K., Öztürk, N., Kuru, E., Özdemir, İ., 2018. The relationship between theory of mind and insight in obsessive-compulsive disorder. *Nord. J. Psychiatry* 72, 273–280. <https://doi.org/10.1080/08039488.2018.1436724>.
- Tuladhar, A.M., Reid, A.T., Shumskaya, E., de Laat, K.F., van Norden, A.G., van Dijk, E.J., et al., 2015. Relationship between white matter hyperintensities, cortical thickness, and cognition. *Stroke* 46, 425–432. <https://doi.org/10.1161/STROKEAHA.114.007146>.
- Tumkaya, S., Karadag, F., Oguzhanoglu, N.K., Tekkanat, C., Varma, G., Ozdel, O., et al., 2009. Schizophrenia with obsessive-compulsive disorder and obsessive-compulsive disorder with poor insight: a neuropsychological comparison. *Psychiatry Res.* 165, 38–46. <https://doi.org/10.1016/j.psychres.2007.07.031>.
- Uddin, L.Q., Molnar-Szakacs, I., Zaidel, E., Iacoboni, M., 2006. rTMS to the right inferior parietal lobule disrupts self-other discrimination. *Soc. Cogn. Affect. Neurosci.* 1, 65–71. <https://doi.org/10.1093/scan/nsi003>.
- van der Meer, L., Costafreda, S., Aleman, A., David, A.S., 2010. Self-reflection and the brain: a theoretical review and meta-analysis of neuroimaging studies with implications for schizophrenia. *Neurosci. Biobehav. Rev.* 34, 935–946. <https://doi.org/10.1016/j.neubiorev.2009.12.004>.
- van der Meer, L., de Vos, A.E., Stiekema, A.P., Pijnenborg, G.H., van Tol, M.J., Nolen, W.A., et al., 2012. Insight in schizophrenia: involvement of self-reflection networks? *Schizophr. Bull.* 39, 1288–1295. <https://doi.org/10.1093/schbul/sbs122>.
- Venkatasubramanian, G., Zutshi, A., Jindal, S., Srikanth, S.G., Kovoov, J.M., Kumar, J.K., et al., 2012. Comprehensive evaluation of cortical structure abnormalities in drug-naive, adult patients with obsessive-compulsive disorder: a surface-based morphology study. *J. Psychiatr. Res.* 46, 1161–1168. <https://doi.org/10.1016/j.jpsychires.2012.06.003>.
- Vostrikov, V.M., Kolomeets, N.S., Uranova, N.A., 2013. Reduced oligodendroglial density in the inferior parietal lobule and lack of insight in schizophrenia. *Eur. J. Psychiatry* 27, 111–121. <https://doi.org/10.4321/S0213-61632013000200004>.
- Wierenga, L.M., Langen, M., Oranje, B., Durston, S., 2014. Unique developmental trajectories of cortical thickness and surface area. *Neuroimage* 87, 120–126. <https://doi.org/10.1016/j.neuroimage.2013.11.010>.