

CASE REPORT

Minimally invasive arthroscopy of the knee using a new 2 mm device

Christian Konrads¹  | Thomas Notheisen² | Stefan Döbele²

¹Department of Orthopaedic Surgery, University of Tübingen, Tübingen, Germany

²Trauma Center Tübingen, BG Klinik, University of Tübingen, Tübingen, Germany

Correspondence

Christian Konrads, MD, Senior Consultant Orthopaedic Surgeon, Department of Orthopaedic Surgery, University of Tübingen, Hoppe-Seyler-Str. 3, 72076 Tübingen, Germany. Email: christian.konrads@gmail.com

Funding information

None

Abstract

Arthroscopy has been evolving over the last decades, whereas arthroscopic devices have not changed much. Smaller diameter arthroscopes would potentially reduce the intraoperative trauma for cartilage and soft tissues. Two-millimeter-diameter arthroscopy demonstrated very good visualization and reach of intra-articular structures—similar to knee arthroscopy using a standard arthroscopic system.

KEYWORDS

biopsy, joint, meniscus, mini-arthroscopy, nanoscope

1 | INTRODUCTION

Arthroscopic procedures have been evolving continuously over the last decades, whereas arthroscopes itself have not changed much. Smaller diameter arthroscopes could potentially reduce the risk of damaging cartilage or soft tissues. In the past, small needle arthroscopes did not provide sufficient image quality.^{1,2} Here, we describe the surgical technique of diagnostic and therapeutic knee arthroscopy under local anesthesia using a new arthroscope with a diameter in the two-millimeter range.

2 | SURGICAL TECHNIQUE

A compact arthroscopic system (NanoScope™, Arthrex, Naples, FL, USA) was used for arthroscopy of the knee under local anesthesia. The two main components of this system are a tablet-like, medical-grade control unit and a

disposable handpiece. The handpiece contains both the LED light source and the camera sensor (pixel number 400 × 400), which is located at the tip of the handpiece tube. As compared to conventional small-diameter arthroscopes, this chip-on-tip technology entails a semi-rigid device without delicate rod lenses. Furthermore, the handpiece tube features an outer diameter (OD) of 1.9 mm and a 0° direction of view with an extended field of view of 120°. The handpiece comes with a sheath (OD: 2.2 mm) and accessories that allow for scope insertion and the connection of distention systems. Various disposable small-diameter hand instruments (OD: 2 mm) and cannulas (OD: 3.4 mm) are available for therapeutic procedures.

After sterile draping of the leg in a supine patient position in the operating room, a standard team time-out was performed. The patella, patellar tendon, tibial tubercle, and the medial and lateral femoro-tibial joint lines were marked. Local anesthesia was performed by injecting a

This is an open access article under the terms of the Creative Commons Attribution-NonCommercial-NoDerivs License, which permits use and distribution in any medium, provided the original work is properly cited, the use is non-commercial and no modifications or adaptations are made.

© 2022 The Authors. *Clinical Case Reports* published by John Wiley & Sons Ltd.

10 ml 1% mepivacaine solution into the cutaneous and subcutaneous tissues. In order to develop a high anterolateral portal for knee arthroscopy, a 3 mm longitudinal incision was performed. The NanoScope trocar was introduced through the skin until contact with the joint capsule was felt. Via the trocar, 15 ml mepivacaine 1% was injected to the joint capsule. The trocar was then allowed to penetrate the capsule and was introduced into the joint. Via the trocar, intraarticular injection of 15 ml ropivacaine 0.5% was subsequently administered. After 3 minutes of exposure time, surgery was to be continued and arthroscopy was performed in a standard fashion (Figure 1 and Video 1).

During surgery, photograph and video documentation was done. To sedate the patient during the procedure, remifentanyl 1.3 g/kg body weight/h can be infused via venous access.

During the course of surgery, the patient did not suffer any pain. The surgeon reported, that for him, the operation did not differ substantially from standard knee arthroscopy. The surgical procedure—diagnostic and therapeutic arthroscopy of the knee—provided excellent visualization and reach of the intraarticular structures (Figure 1 and Video 1).

3 | DISCUSSION

The miniature arthroscopic system provided sufficient surgical handling, patient comfort, and quality of imaging. The device and the procedure is well suited for diagnostic means. Additional instruments of extra-small size are available to address certain pathologies like meniscal tears.

The implications of the clinical feasibility of a 2 mm arthroscope for the knee can be underlined in its advantage as a powerful additional diagnostic tool when MRI or CT findings remain unclear—especially for chondral or osteochondral lesions.³ It could also be used as a standard procedure during osteotomies around the knee. Further indications might be biopsies of the synovial membrane or of osteochondral cylinders for autologous chondral transplantation (ACT).^{4,5} The NanoScope might also be helpful for visualization of the reduction in intraarticular fractures during open or closed reduction and fixation. Further indications are repair and debridement of meniscal tears⁶ and partial synovectomy.⁷

Of course, this procedure is not limited to the knee. Safety and effectiveness of ankle arthroscopy⁸ and tenoscopy⁹ have been demonstrated recently in two cadaver studies. It can also be used in shoulder¹⁰ and elbow¹¹ arthroscopy. More clinical research for further evaluation is needed in the future.

A disadvantage of the new thin device could be seen in the lack of a 30° optical lens. Although a 120° field of view compensates for this to a certain extent, the location of portals should be planned precisely.

Indications and contraindications are similar to standard arthroscopy using standard arthroscope and instruments.

Because of its minimal invasiveness, the procedure can not only be performed under general or spinal anesthesia, but it is also very well suited to be performed under local anesthesia as demonstrated allowing for the expansion of the utility settings.

It is a known fact that local anesthetics have a chondrotoxic potential.^{12,13} Theoretically, this is less

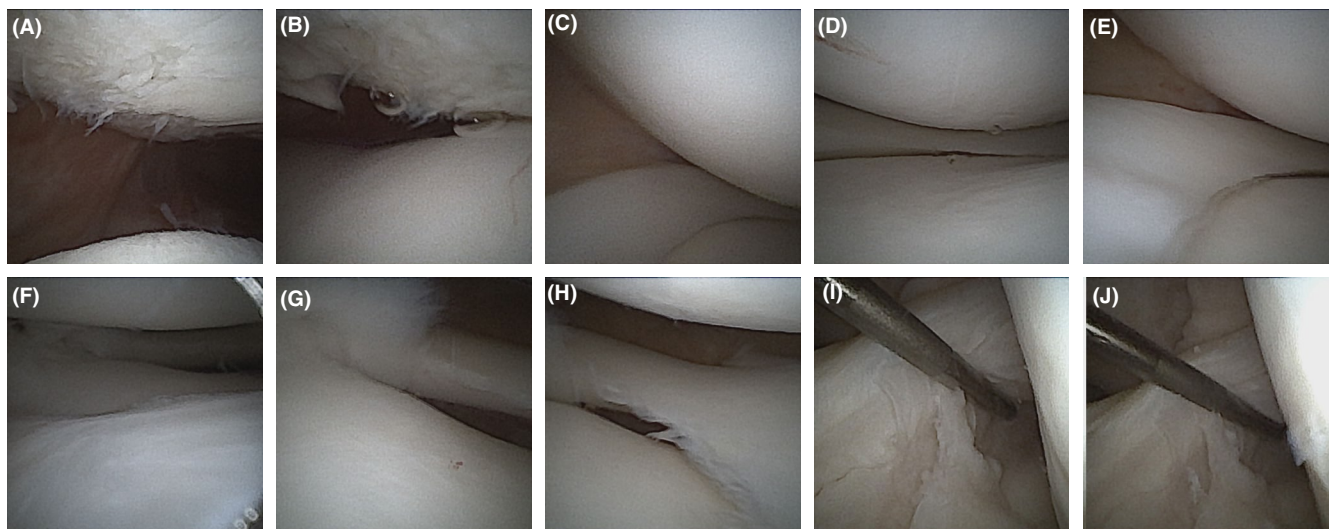
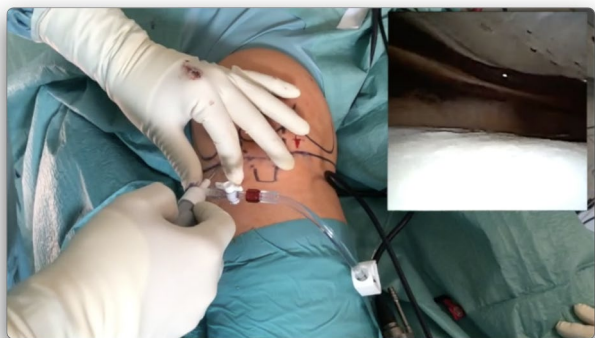

FIGURE 1 Initial diagnostic arthroscopy of a left knee. Patellofemoral compartment (A, B). Medial compartment (C-E). Lateral compartment (F-H). Intact Anterior Cruciate Ligament (I, J)



VIDEO 1 Arthroscopy of a right knee with debridement and nanofracturing at the medial femoral condyle.

To view this video please visit <https://onlinelibrary.wiley.com/doi/10.1002/ccr3.5590>

important using the described procedure because for intraarticular injection we used ropivacaine that demonstrated low toxicity compared with other substances, and it is diluted immediately after intraarticular injection as the joint is filled with saline fluid for arthroscopy.¹⁴ The dilution minimalizes potential cytotoxic effects.¹⁵

4 | CONCLUSIONS

In conclusion, we demonstrated successful needle arthroscopy of the knee. The two-millimeter device further decreases the invasiveness of arthroscopic procedures providing excellent images. This might expand the versatility of arthroscopy as a diagnostic and therapeutic tool to treat joint pathologies.

ACKNOWLEDGEMENT

None.

CONFLICT OF INTEREST

None.

AUTHOR CONTRIBUTIONS

Christian Konrads wrote the manuscript. Thomas Notheisen revised the manuscript. Stefan Doebele conducted the procedure.

ETHICAL APPROVAL

No study on humans or animals was conducted. Informed consent for publication was received by the patient.

CONSENT

Written informed consent was obtained from the patient to publish this report in accordance with the journal's patient consent policy.

DATA AVAILABILITY STATEMENT

The data that support the findings of this work are available from the corresponding author upon reasonable request.

ORCID

Christian Konrads  <https://orcid.org/0000-0002-1285-4615>

REFERENCES

- Zhang K, Crum RJ, Samuelsson K, Cadet E, Ayeni OR, de Sa D. In-office needle arthroscopy: a systematic review of indications and clinical utility. *Arthroscopy*. 2019;35:2709-2721.
- Meister K, Harris NL, Indelicato PA, Miller G. Comparison of an optical catheter office arthroscope with a standard rigid rod-lens arthroscope in the evaluation of the knee. *Am J Sports Med*. 1996;24:819-823.
- Deirmengian CA, Dines JS, Vernace JV, Schwartz MS, Creighton RA, Gladstone JN. Use of a small-bore needle arthroscope to diagnose intra-articular knee pathology: comparison with magnetic resonance imaging. *Am J Orthop*. 2018;47:1-5.
- Moreland LW, Calvo-Alen J, Koopman WJ. Synovial biopsy of the knee joint under direct visualization by needle arthroscopy. *J Clin Rheumatol*. 1995;1:103-109.
- Baeten D, Van den Bosch F, Elewaut D, Stuer A, Veys EM, De Keyser F. Needle arthroscopy of the knee with synovial biopsy sampling: technical experience in 150 patients. *Clin Rheumatol*. 1999;18:434-441.
- Quinn R, Lang SD, Gilmer BB. Diagnostic arthroscopy and partial medial meniscectomy using small bore needle arthroscopy. *Arthrosc Tech*. 2020;9:e645-650.
- Lavander C, Patel T, Adil S, Blickenstaff B, Oliashirazi A. Incisionless knee synovectomy and biopsy with needle arthroscope and autologous tissue collector. *Arthrosc Tech*. 2020;9:e1259-1262.
- Stornebrink T, Altink JN, Appelt D, Wijdicks CA, Stufkens SAS, Kerkhoffs GMMJ. Two-millimetre diameter operative arthroscopy of the ankle is safe and effective. *Knee Surg Sports Traumatol Arthrosc*. 2020;28:3080-3086.
- Stornebrink T, Stufkens SAS, Appelt D, Wijdicks CA, Kerkhoffs GMMJ. 2-mm diameter operative tendoscopy of the tibialis posterior, peroneal, and achilles tendons: a cadaveric study. *Foot Ankle Int*. 2020;41:473-478.
- Shafi N, Lang SD, Kassam H, Gilmer BB. Diagnostic and therapeutic shoulder arthroscopy using small-bore needle arthroscopy. *Arthrosc Tech*. 2020;9:e1087-e1093.
- Peters M, Gilmer B, Kassam HF. Diagnostic and therapeutic elbow arthroscopy using small-bore needle arthroscopy. *Arthrosc Tech*. 2020;9:e1703-e1708.
- Breu A, Rosenmeier K, Kujat R, Angele P, Zink W. The cytotoxicity of bupivacaine, ropivacaine, and mepivacaine on human chondrocytes and cartilage. *Anesth Analg*. 2013;117:514-522.
- Gulihar A, Robati S, Twajj H, Salih A, Taylor GJS. Articular cartilage and local anaesthetic: a systematic review of the current literature. *J Orthop*. 2015;12(Suppl 2):S200-210.
- Piper SL, Kim HT. Comparison of Ropivacaine and Bupivacaine toxicity in human articular chondrocytes. *J Bone Joint Surg Am*. 2008;90:986-991.

15. Kreuz PC, Steinwachs M, Angele P. Single-dose local anesthetics exhibit a type-, dose-, and time-dependent chondrotoxic effect on chondrocytes and cartilage: a systematic review of the current literature. *Knee Surg Sports Traumatol Arthrosc.* 2018;26:819-830.

How to cite this article: Konrads C, Notheisen T, Döbele S. Minimally invasive arthroscopy of the knee using a new 2 mm device. *Clin Case Rep.* 2022;10:e05590. doi:[10.1002/ccr3.5590](https://doi.org/10.1002/ccr3.5590)