


CLINICAL IMAGE

Fusion imaging of three-dimensional echocardiographic speckle-tracking with cardiac computed tomography for identification of myocardial ischemia

Yoichi Takaya¹  | Rie Nakayama¹ | Nobuhisa Watanabe² | Norihisa Toh¹ | Toru Miyoshi¹ | Hiroshi Ito¹¹Department of Cardiovascular Medicine, Okayama University Graduate School of Medicine, Dentistry and Pharmaceutical Sciences, Okayama, Japan²Division of Medical Support, Okayama University Hospital, Okayama, Japan**Correspondence**

Yoichi Takaya, Department of Cardiovascular Medicine, Okayama University Graduate School of Medicine, Dentistry and Pharmaceutical Sciences, 2-5-1 Shikata-cho, Kitaku, Okayama 700-8558, Japan.

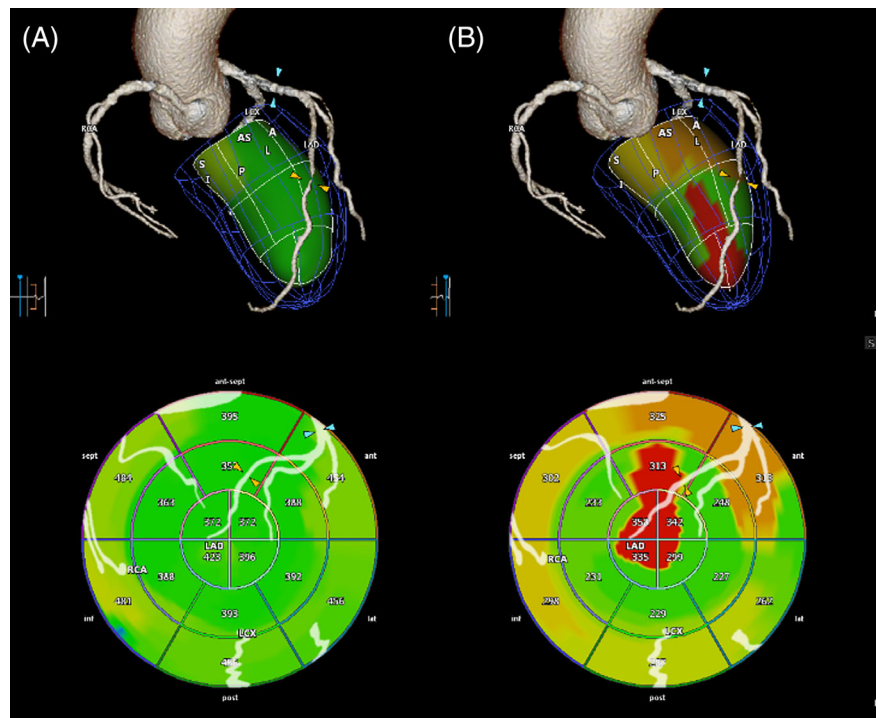
Email: takayaoyoichi@yahoo.co.jp

1 | CASE DESCRIPTION

A 73-year-old woman was referred to our institution because of exertional chest pain. Electrocardiogram and transthoracic echocardiography

showed no abnormalities. Cardiac computed tomography (CT) showed coronary artery stenosis at the distal-segment and the proximal-segment of left anterior descending artery (LAD). Dobutamine stress three-dimensional (3D) echocardiographic speckle-tracking was performed

FIGURE 1 A, Fusion imaging at rest showing no myocardial ischemia depicted by green. B, Fusion imaging at stress showing myocardial ischemia in the territory of the distal-segment of LAD (yellow arrow) depicted by red, and the proximal-segment of LAD, involving the first diagonal branch (blue arrow), depicted by orange



This is an open access article under the terms of the Creative Commons Attribution-NonCommercial-NoDerivs License, which permits use and distribution in any medium, provided the original work is properly cited, the use is non-commercial and no modifications or adaptations are made.

© 2021 The Authors. *Health Science Reports* published by Wiley Periodicals LLC.

using Aplio (Canon Medical Systems, Otawara, Japan). Myocardial ischemia was evaluated by dyssynchrony imaging of area change ratio, which assessed the delays of strain value peaks from end-systole, indicating postsystolic shortening,¹ and was shown on the color-coded polar map. The delays of strain value peaks were shown from green (no delay) to red (delay greater). The images of 3D echocardiographic speckle-tracking and coronary artery tree derived by CT were automatically combined on the single display using Vitrea systems (Canon Medical Systems) to match the size and location of the left ventricle such as the anterior and inferior walls. The fusion imaging at rest showed no myocardial ischemia (Figure 1A), while the fusion imaging at stress indicated myocardial ischemia in the territories of the distal-segment and the proximal segment of LAD, involving the first diagonal branch (Figure 1B). Coronary angiography revealed significant stenosis at the distal-segment, the proximal-segment, and the first diagonal branch of LAD, which were confirmed as ischemia by fractional flow reserve. The patient underwent percutaneous revascularization of these lesions.

Cardiac CT indicates the severity of coronary artery stenosis but cannot diagnose myocardial ischemia of the lesions. 3D echocardiographic speckle-tracking detects subtle changes of myocardial function but cannot confirm as contractile abnormality due to coronary artery disease. In recent years, some studies reported the usefulness of the fusion imaging of CT coronary angiography with 3D echocardiography.²⁻⁴ In this case, the fusion imaging at stress could accurately show the presence of myocardial ischemia related to coronary artery stenosis. Furthermore, the severity of myocardial ischemia, which was depicted by orange to red, could be evaluated. The fusion imaging of 3D echocardiographic speckle-tracking with cardiac CT, which allows for the display of coronary artery and its territorial function, can identify the presence and severity of myocardial ischemia. The fusion imaging has the potential to contribute to therapeutic strategy for the revascularization of coronary artery disease.

FUNDING INFORMATION

None.

CONFLICT OF INTEREST

The authors declare no conflicts of interest.

AUTHOR CONTRIBUTIONS

Conceptualization: Yoichi Takaya, Hiroshi Ito

Data Curation: Yoichi Takaya, Rie Nakayama, Nobuhisa Watanabe, Norihisa Toh, Toru Miyoshi

Writing – Original Draft Preparation: Yoichi Takaya

Writing – Review and Editing: Yoichi Takaya

All authors have read and approved the final version of the manuscript.

The corresponding author will have to confirm that he had full access to all of the data in the study and takes complete responsibility for the integrity of the data and the accuracy of the data analysis.

TRANSPARENCY STATEMENT

The Yoichi Takaya affirms that this manuscript is an honest, accurate, and transparent account of the study being reported; that no important aspects of the study have been omitted; and that any discrepancies from the study as planned have been explained.

DATA AVAILABILITY STATEMENT

The data that support the findings of this study are available from the corresponding author on reasonable request.

ORCID

Yoichi Takaya  <https://orcid.org/0000-0003-4872-8669>

REFERENCES

1. Onishi T, Uematsu M, Watanabe T, et al. Objective interpretation of dobutamine stress echocardiography by diastolic dyssynchrony imaging: a practical approach. *J Am Soc Echocardiogr.* 2010;23:1103-1108.
2. Maffessanti F, Patel AR, Patel MB, et al. Non-invasive assessment of the haemodynamic significance of coronary stenosis using fusion of cardiac computed tomography and 3D echocardiography. *Eur Heart J Cardiovasc Imaging.* 2017;18:670-680.
3. Patel AR, Maffessanti F, Patel MB, et al. Hemodynamic impact of coronary stenosis using computed tomography: comparison between non-invasive fractional flow reserve and 3D fusion of coronary angiography with stress myocardial perfusion. *Int J Cardiovasc Imaging.* 2019;35:1733-1743.
4. Takaya Y, Ito H. New horizon of fusion imaging using echocardiography: its progress in the diagnosis and treatment of cardiovascular disease. *J Echocardiogr.* 2020;18:9-15.

How to cite this article: Takaya Y, Nakayama R, Watanabe N, Toh N, Miyoshi T, Ito H. Fusion imaging of three-dimensional echocardiographic speckle-tracking with cardiac computed tomography for identification of myocardial ischemia. *Health Sci Rep.* 2021;4:e285. <https://doi.org/10.1002/hsr2.285>