

Accurate Prediction of Submental Lymph Nodes Using Magnetic Resonance Imaging for Lymphedema Surgery

Mora-Ortiz Asuncion, MD*

Sung-Yu Chu, MD†

Yen-Ling Huang, MD†

Chia-Yu Lin, MSc‡

Ming-Huei Cheng, MD, MBA†§

Background: Submental lymph node transfer has proved to be an effective approach for the treatment of lymphedema. This study was to investigate the anatomy and distribution of vascularized submental lymph node (VSLN) flap using magnetic resonance imaging (MRI) and their clinical outcome.

Methods: Fifteen patients who underwent 19 VSLN flap transfers for upper or lower limb lymphedema were retrospectively analyzed. The number of submental lymph nodes was compared among preoperative MRI, preoperative sonography, intraoperative finding, postoperative sonography, and postoperative computed tomography angiography. The outcome was compared between preoperatively and postoperatively.

Results: All 19 VSLN flaps survived. Two hundred fifteen lymph nodes were identified in 30 submandibular regions by MRI. The mean number of submental lymph nodes on preoperative MRI was 7.2 ± 2.4 , on preoperative sonography was 3.2 ± 1.1 , on intraoperative finding was 3.1 ± 0.6 , postoperative sonography was 4.6 ± 1.8 , and postoperative CTA was 5.2 ± 1.9 . Sixty-one percent of the lymph nodes were located in the central two-quarters of the line drawn from the mental protuberance to the mandibular angle. The actual harvest rate of submental lymph nodes was 72.2%. At a 12-month follow-up, mean episodes of cellulitis were improved from 2.7 ± 0.6 to 0.8 ± 0.2 ($P < 0.01$); mean of circumferential difference was improved 3.2 ± 0.4 cm ($P < 0.03$). The overall lymphedema quality-of-life was improved 4.9 ± 0.3 ($P < 0.04$).

Conclusions: The preoperative MRI is a useful tool for the detection of mean 7.2 submental lymph nodes. Mean 72.2% of submental lymph nodes can be successfully transferred for extremity lymphedema with optimal functional recovery. (*Plast Reconstr Surg Glob Open* 2018;6:e1691; doi: 10.1097/GOX.0000000000001691; Published online 23 March 2018.)

INTRODUCTION

Lymphedema is a chronic disease characterized by an accumulation of proteins and fluid within the interstitial space

From the *Department of Plastic and Reconstructive Surgery, Virgen de la Arrixaca University Clinical Hospital, Murcia, Spain; †Department of Medical Imaging and Intervention, Chang Gung Memorial Hospital, Chang Gung University, College of Medicine, Taoyuan, Taiwan; ‡Division of Reconstructive Microsurgery, Department of Plastic and Reconstructive Surgery, Chang Gung Memorial Hospital, College of Medicine, Chang Gung University; Taoyuan, Taiwan; and §Center for Tissue Engineering, Chang Gung Memorial Hospital, Taoyuan, Taiwan.

Received for publication January 19, 2017; accepted January 5, 2018.

Copyright © 2018 The Authors. Published by Wolters Kluwer Health, Inc. on behalf of The American Society of Plastic Surgeons. This is an open-access article distributed under the terms of the Creative Commons Attribution-Non Commercial-No Derivatives License 4.0 (CCBY-NC-ND), where it is permissible to download and share the work provided it is properly cited. The work cannot be changed in any way or used commercially without permission from the journal.

DOI: 10.1097/GOX.0000000000001691

of the extremities. It is often a sequela of cancer or its treatment in developed and developing countries. Vascularized lymph node flap transfers are gaining popularity in lymphedema treatment. They were first reported by Shesol in 1979 in an animal model and clinically in 2 patients in 1982 by Clodius.¹ This technique gained popularity in the late 2000s when Becker et al.² and Lin et al.³ reported successful outcomes.

The vascularized lymph node flap is transferred into lymphedematous regions to restore the lymphatic drainage function. Only a few hypotheses have been proposed regarding its mechanism of action. One theory points out that lymphangiogenesis occurs via growth factors produced by the transplanted lymph nodes. Another theory proposed by our team is that a vascularized lymph node transfer acts as a lymphatic pump through lymphovenous shunts inside the flap and bypasses the lymph into the venous system.⁴⁻⁶ A few donor sites have been described

Disclosure: The authors have no financial interest to declare in relation to the content of this article. Ming-Huei Cheng at Chang Gung Memorial Hospital is responsible for paying for the Article Processing Charge.

as suitable for lymph node transfers. The groin transfer was the first reported donor site; however, the harvest of the flap could lead to iatrogenic lymphedema in the lower limb.⁷⁻⁹ Submental lymph node transfers have been proposed as an effective and safe alternative donor site.¹⁰⁻¹²

The ideal number of lymph nodes to be transferred for an optimal functional result is yet unknown. An experimental study on rats published recently by Nguyen et al.¹³ suggests that greater quantity of lymph nodes correlates with improvement in lymphatic drainage and limb volume reduction, especially in the early phase. This functional benefit might continue over time as old lymphatic channels reopen, the accumulation of lymph decreases, and lymphangiogenesis by the transferred lymph nodes occurs in the surrounding tissue.

Based on this theory, it would be beneficial to select the donor site including a greater number of lymph nodes. Previous studies performed by ultrasound sonography showed that submental and groin flaps had the higher lymph node quantity and density compared with supraclavicular flap.¹⁴

The aim of this study was to find the ideal design of the vascularized submental lymph node (VSLN) flap to harvest the largest number of lymph nodes available with the aid of magnetic resonance imaging (MRI) for preoperative evaluation; and their correlated clinical application and outcome.

PATIENTS AND METHODS

This study was approved by the Institutional Research Board 101-3282A3 at Chang Gung Memorial Hospital. Fifteen patients affected with either lower or upper limb lymphedema were evaluated preoperatively to assess their suitability to undergo a vascularized lymph node transfers at Chang Gung Memorial Hospital between

2012 and 2013. The patients underwent elective MRI (acquired on MR750, GE Healthcare) to evaluate the artery and lymph nodes of the submental area. The MRI sequence included fat-suppressed 3-dimensional fast spin echo T1-weighted (CUBE T1), T2-weighted (CUBE T2), and MR angiography. The MRI was performed on a standard position (no hyperextension), which might have hindered our study.

MRI data from 30 sides of submental areas were analyzed retrospectively. All the data were collected and transferred to an Image Workstation (OsiriX, v.6.5.2, 64-bit, Switzerland), where reconstruction was performed to obtain 3-dimensional images. A line was marked on the mandibular ridge from the mental protuberance to the mandibular angle. This line was further divided into 4 quarters. Lymph nodes larger than 1 mm were located along this axis and along a line perpendicular to this axis as shown (Fig. 1). Lymph node location around the submandibular gland was also evaluated.

All 15 patients also underwent a preoperative ultrasound Doppler (Siemens, Acuson S3000, Erlangen, Germany) study for the evaluation of the sizable lymph nodes with the diameter greater than 3 mm in both submental areas. After explanations of the possible complications and informed consent obtained, all 15 patients underwent 19 VSLN flap transfers. Four of them received bilateral VSLN flaps transfers. The intraoperative findings of the sizable lymph nodes were recorded. At a 12-month follow-up, all patients were evaluated with both ultrasound sonography and computed tomography angiography (CTA) for the number of transferred lymph nodes in the recipient sites (Table 1). The number of submental lymph nodes in preoperative MRI, preoperative sonography, intraoperative finding, postoperative sonography, and postoperative CTA was compared in Table 1.

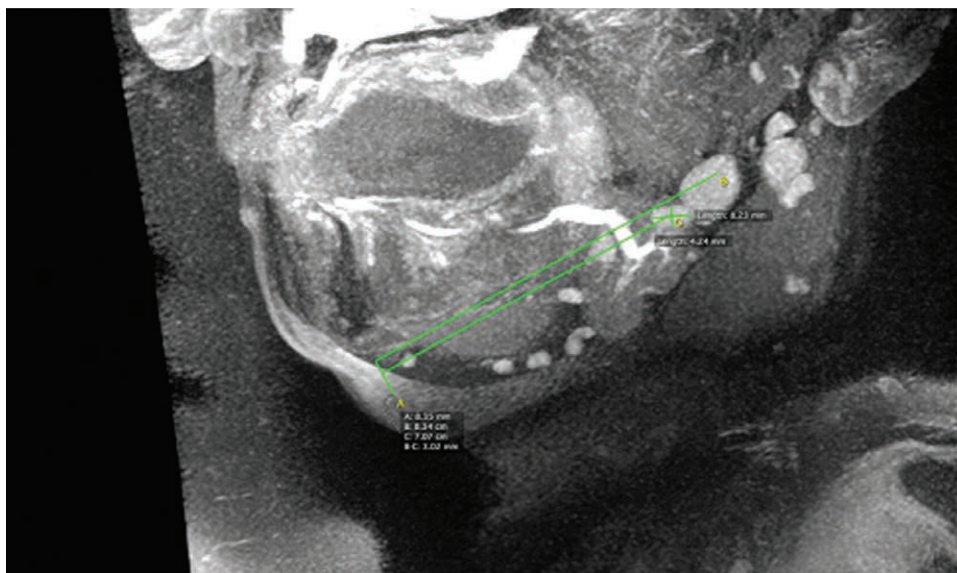


Fig. 1. Magnetic resonance image (sagittal section) showing submental and submandibular lymph nodes distributed along a line drawn from the mental protuberance to the mandibular angle (green line).

Table 1. Comparisons of the Number of Lymph Nodes between Preoperative MRI, Preoperative Sonography, Intraoperative Finding, Postoperative Sonography, and Postoperative CTA in 15 Consecutive Patients Undergoing 19 VSLN Flap Transfers for Upper or Lower Limb Lymphedema

No. Cases	Age (y)	Body Mass Index (kg/m ²)	Donor Site						Recipient Site								
			Preoperative MRI			Preoperative Sonography			Intraoperative Sizable Finding			Postoperative Sonography			Postoperative CTA		
			No. LN	Right	Left	Mean	No. LN	Right	Left	Mean	No. LN	Right	Left	Mean	No. LN	Right	Left
1	3	18.5	5	3	3	3	2	2.5	5	4	4	4.5	5	3	4	4.5	
2	22	25.3	9	3	3	3	N/A	4	3	3	N/A	3	3	3	N/A	3	
3	68	23.5	10	6	3	3	3	3.5	4	4	3	3.5	5	5	5	5	
4	66	34.2	7	5	4	4	N/A	4	4	4	N/A	4	10	10	N/A	10	
5	66	24.3	10	15	3	3	3	3	N/A	3	3	3	3	N/A	7	7	
6	60	31.2	6	5	4	3	3.5	4	4	4	N/A	4	4	7	N/A	7	
7	75	24.5	7	8	3	3	3.5	2	N/A	2	3	3	3	N/A	3	3	
8	62	35.2	5	8	4	4	2	2.5	3	3	3	2.5	4	4	4	4	
9	52	28.4	4	4	2	2	2	2	3	3	N/A	3	5	3	N/A	3	
10	51	26.2	9	7	3	3	2.5	3	N/A	3	3	3	5	5	4	4	
11	51	39.5	8	8	3	3	3	3	3	3	N/A	3	5	N/A	4	4	
12	52	26.5	5	2	3	3	2.5	3	N/A	3	3	3	3	6	N/A	6	
13	14	19.3	4	4	2	2	3	3	3	3	N/A	3	5	6	N/A	6	
14	63	26	7	8	2	2	2	4	N/A	4	4	4	6	6	N/A	6	
15	58	28.1	11	6	6	6	6	3	3	3	3	5	5	5	5	5.5	
Total	50.9±20.7	27.4±5.6	7.1±2.2	7.2±2.6	2.3±0.6	3.2±1.1	3.2±0.6	3.1±0.6	3.2±0.2	3.0±0.3	4.3±1.5	4.6±1.8	5.1±2.1	5.6±2.2	4.7±1.9	5.2±1.9	
(mean ± SD)	(3–75)	(18.5–39.5)	(4–11)	(4–15)	(2–6)	(2–6)	(2–6)	(2–4)	(2–4)	(2–4)	(3–6)	(3–10)	(3–10)	(3–10)	(3–7)	(3–10)	

LN, lymph node; N/A, not available.

Statistics

All statistical analysis was performed using SPSS 17.0 statistical software (SPSS, Inc., Chicago, Ill.). A Wilcoxon signed-rank test was used comparing preoperative MRI with preoperative sonography, intraoperative sizable finding, postoperative sonography, and postoperative CTA. The Spearman’s correlation coefficients assessed the relationship between preoperative MRI and preoperative sonography, intraoperative sizable finding, postoperative sonography, and postoperative CTA. A value of *P* < 0.05 was considered statistically significant.

RESULTS

All 19 VSLN flaps survived, giving a success rate of 100%. The mean age was 50.9±20.7 years (range, 3–75 years) with a mean body mass index of 27.4±5.6 (range, 18.5–39.5). The mean number of submental lymph nodes on preoperative MRI was 7.2±2.4 (range, 4–15), on preoperative sonography was 3.2±1.1 (range, 2–6), on intraoperative finding was 3.1±0.6 (range, 2–7), postoperative sonography was 4.6±1.8 (range, 3–10), and postoperative CTA was 5.2±1.9 (range, 3–10; Table 1).

A total of 215 lymph nodes were identified in 30 submandibular regions. An average of 7.2±2.4 lymph nodes were found in each region. No statistically significant differences were found between right and left sides (left side, 7.2±2.6; right side, 7.1±2.2). Lymph nodes were located 13.6±4.7mm deep from the skin in standard position of the neck. About 61% of the lymph nodes were located in the central two-quarters of the abovementioned line (Figs. 2, 3). About 94% of these were found below the mandibular ridge.

The average size observed of the submandibular gland was 34.6×24.2 mm ± 5.2×4.1 mm). About 63.7% of the lymph nodes were located in a 2cm radius circle drawn from the medial border of the submandibular gland (Figs. 4, 5). The number of lymph nodes observed was independent of the mandibular length and submandibular gland size.

Preoperative MRI had detected statistically greater number of submental lymph nodes than preoperative sonography, intraoperative finding, postoperative sonography, and postoperative CTA using Wilcoxon signed-rank test (*P* < 0.01, *P* < 0.01, *P* < 0.01, *P* < 0.01, respectively). Using Spearman’s correlation coefficients to check lymph node number correlation, the association in the mean number of submental lymph nodes was statistically significant between postoperative sonography and intraoperative sizable finding (*P* = 0.02) and between postoperative CTA and postoperative sonography (*P* < 0.01; Table 2).

The actual harvest rate of submental lymph nodes in this series was 72.2% using the mean number of lymph nodes on postoperative CTA (5.2±1.9) divided by the mean number of lymph nodes on preoperative MRI (7.2±2.4).

All patients with 12 months of follow-up following surgery were evaluated with the lymphedema quality-of-life study, which is a condition-specific, validated questionnaire, which includes function, appearance, symptoms,

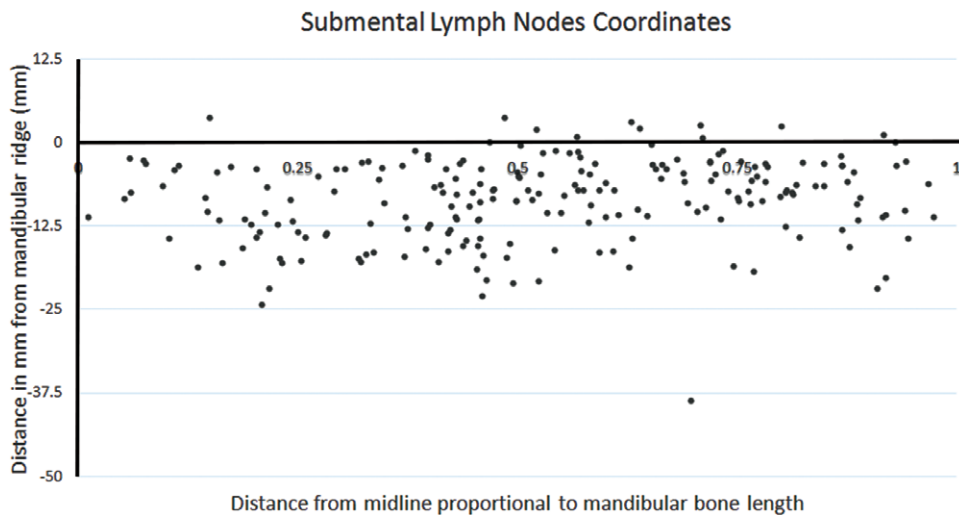


Fig. 2. Locations of 215 submental lymph nodes in 30 submandibular areas plotted around a line drawn from the mental protuberance to the mandibular angle. Axis x: distance from the mental protuberance proportional to the mandibular length. Axis y: distance in mm from a mandibular ridge, perpendicular to axis x.

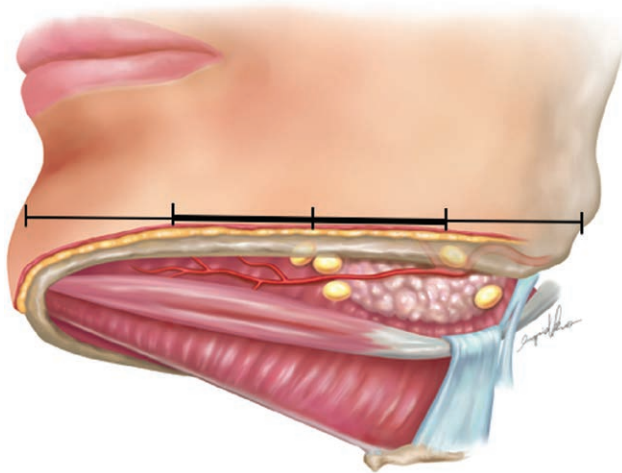


Fig. 3. Illustration showing the relationship between anatomic landmarks and lymph nodes in a submental lymph node flap. Sixty-one percent of lymph nodes were found in the central two-quarters of a line drawn from the mental protuberance to the mandibular angle.

and mood. Each domain is scored from 1 to 4, with 1 representing a response of “not at all,” and 4 representing a response of “a lot.” Overall quality-of-life scores were assessed on a scale of 1–10, with higher scores indicating a higher rated overall quality of life. The preoperative occurrence of cellulitis 2.7 ± 0.6 times per year was significantly decreased as compared with postoperative 0.8 ± 0.2 times per year ($P < 0.01$). Mean of circumferential difference was found to improve 3.2 ± 0.4 cm at a 12-month follow-up ($P < 0.03$). A specific comparison of the preoperative assessment and 12-month assessment revealed significant improvements in the scores for appearance 8.2 ± 0.5 point, function 13.1 ± 0.7 point, symptom 7.0 ± 0.3 point, mood 12.1 ± 0.6 point, and overall quality of life 4.9 ± 0.3 point

($P < 0.04$, $P < 0.04$, $P < 0.03$, $P < 0.02$, and $P < 0.04$, respectively; Table 3).

DISCUSSION

Clinical success following vascularized lymph node transfers has been reported by several groups.^{15–19} Four donor sites are commonly selected: groin, axilla, supraclavicular, and submental regions.²⁰ The vascularized groin lymph node was the most popular donor site due to its reliability and success. Furthermore, it can be combined with deep inferior epigastric perforator flap for breast reconstruction and lymphedema treatment simultaneously.²¹ Many anatomical studies^{22–25} and techniques such as reverse lymphatic mapping²⁶ have been described to avoid or minimize the morbidity of the donor site. But the risk of lymphatic dysfunction that may develop in lower limb following the vascularized groin lymph node transfer represents a main concern.^{7–9}

As a result, other lymphatic donor sites such as submental, supraclavicular, or thoracodorsal regions have recently gained popularity. Submental lymph node transfers were described by Cheng in 2012.¹¹ These include submental and submandibular lymph nodes (Ia and Ib neck dissection levels),²⁷ which are vascularized by submental and facial artery.²⁸ To the best of our knowledge, no neck or face lymphedema was reported after submental lymph node transfer, including bilateral transfers. There is a possibility of damaging the marginal mandibular nerve when harvesting a VSLN flap, which can be avoided by meticulous dissection under microscope. Another complication of VSLN flap was the marginal mandibular nerve pseudo-paralysis, which can be solved by modification of platysma-sparing VSLN flap transfer.²⁹ Furthermore, from a cosmetic point of view, the scar on the submental area is inconspicuous.

MRI or MR angiography (MRA) is the most recent development used for perforator flap design and its major advantage is the absence of ionizing radiation.^{30,31} It is

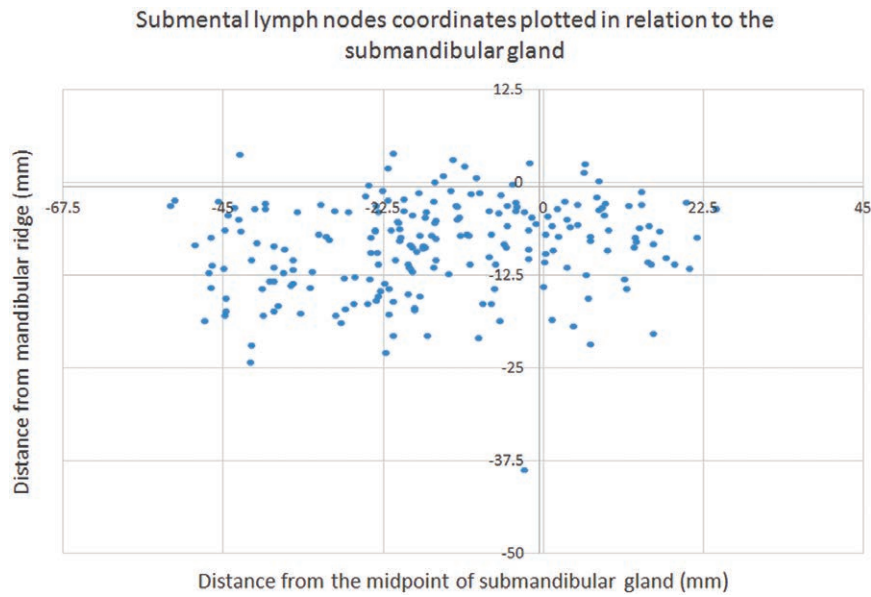


Fig. 4. Coordinate axes showing lymph nodes plotted around the center of the submandibular gland (0, 0). Axis x represents the distance from the midpoint of the gland in mm, and axis y represents the distance from the mandibular ridge in mm.

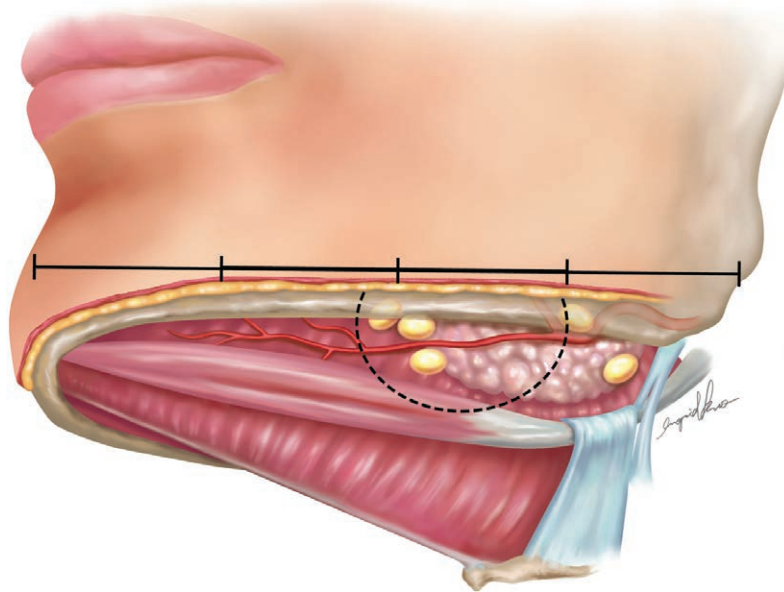


Fig. 5. Illustration to show the relationship between the lymph nodes and the submandibular gland. About 63.7% of the lymph nodes were located in a 2-cm radius circle drawn from the medial border of the submandibular gland.

Table 2. The Spearman’s Correlation Coefficients of Mean Number of Submental Lymph Nodes Detected by Preoperative MRI, Preoperative Sonography, Intraoperative Finding, Postoperative Sonography, and Postoperative CTA

Assessment of Submental Lymph Nodes	Preoperative MRI	Preoperative Sonography	Intraoperative Sizable Finding	Postoperative Sonography	Postoperative CTA
Preoperative MRI	1				
Preoperative sonography	r = 0.1; P = 0.6	1			
Intraoperative sizable lymph nodes	r = 0.1; P = 0.6	r = -0.03; P = 0.9	1		
Postoperative sonography	r = -0.2; P = 0.4	r = 0.3; P = 0.3	r = 0.6; P = 0.02*	1	
Postoperative CTA	r = 0.2; P = 0.5	r = 0.3; P = 0.2	r = 0.4; P = 0.1	r = 0.7; P ≤ 0.01*	1

*, statistical difference of the correlations.

Table 3. Comparisons of the Functional Outcomes and Lymphedema Quality of Life Questionnaire in 15 Lymphedema Patients Undergoing 19 VSLN Flap Transfers at a Follow-up of 12 Months

No. Cases	Cellulitis (Times per Year)		After Postoperative 12-mo Improvement of Circumferential Difference (cm)				After Postoperative 12-mo Improvement of LYMQOL (Score)				
	Preoperative	Postoperative	AK 15 cm / BK 15 cm / BE 10 cm		Mean	Part of Lymphedema	Appearance (Score*: 5-20); (Score†: 7-28)	Function (Score*: 10-40); (Score†: 8-32)	Symptom (Score*: 6-24); (Score†: 5-20)	Mood (Score*: 0-10); (Score†: 6-24)	Overall QOL (Score*: 0-10); (Score†: 0-10)
			AE 10 cm	BE 10 cm							
1	5	1	3.0	2.0	2.5	ULL and LLL	9	11	7	13	5
2	5	1	5.5	5.0	5.3	LLL	9	13	6	12	6
3	1	1	4.5	4.0	4.3	Bilateral LLL	10	14	8	14	7
4	6	3	3.0	2.0	2.5	ULL	5	10	8	9	3
5	0	0	2.0	2.0	2.0	Bilateral LLL	5	12	6	10	2
6	5	1	5.0	3.0	4.0	LLL	10	17	9	14	6
7	2	1	2.0	1.0	1.5	LLL	9	13	7	13	5
8	3	1	2.0	1.0	1.5	LLL	8	12	8	14	4
9	0	0	2.0	0	1.0	ULL	7	17	6	8	5
10	0	0	3.0	1.0	2.0	ULL	6	18	6	9	6
11	5	2	7.5	5.5	6.5	LLL	11	10	7	14	5
12	0	0	5.0	3.0	4.0	LLL	7	10	6	13	4
13	2	0	5.5	2.0	3.8	LLL	10	13	6	14	6
14	1	0	2.0	1.0	1.5	ULL	7	14	7	9	5
15	5	1	6.5	3.5	5.0	Bilateral LLL	10	13	8	15	5
Total mean ± SD	2.7 ± 0.6	0.8 ± 0.2	3.9 ± 0.5	2.4 ± 0.4	3.2 ± 0.4		8.2 ± 0.5	13.1 ± 0.7	7.0 ± 0.3	12.1 ± 0.6	4.9 ± 0.3
P; preoperative versus postoperative	< 0.01*		< 0.04*	< 0.04*	< 0.03*		< 0.04*	< 0.04*	< 0.03*	< 0.02*	< 0.04*

Score: means upper limb quality of life score; †Score†: means lower limb quality of life score. LLL, lower limb lymphedema; LYMQOL, lymphedema quality-of-life study; QOL, quality of life; ULL, upper limb lymphedema. AK: above knee; AE: above elbow; BK: below knee; BE: below elbow.

routinely used at Chang Gung Memorial Hospital for donor site evaluation in VSLN flap transfers. MRA provides a high definition of the facial artery course and its relationship with the submandibular gland. Additionally, MRI accurately detects lymph nodes larger than 1 mm, whereas ultrasound imaging can only detect those larger than 3 mm. This is probably the reason why higher numbers of lymph nodes can be found by MRI (7.2 ± 2.4 lymph nodes on each flap) in comparison with ultrasound previous studies (3.2 ± 1.1 lymph nodes on each flap). Initially, we chose the donor site according to the ultrasound sonography study. But because the preoperative MRI had detected statistically greater number of submental lymph nodes, we chose the donor site based on the MRI results with the greater number of lymph nodes. We may conclude that in average there are 3 sizable lymph nodes (greater than 3 mm in diameter) and 4 small lymph nodes (between 1 and 3 mm in diameter) in a VSLN flap. The mean number of submental lymph nodes on postoperative sonography was 4.6 ± 1.8 and on postoperative CTA was 5.2 ± 1.9 , which was greater than that of preoperative sonography 3.2 ± 1.1 . This was possibly due to the transferred lymph nodes flap absorbing too much lymph but draining into the venous system inadequately due to pedicle vein compressed by scarring tissue. Then the smaller lymph nodes swell and can easily be detected by the postoperative sonography or CTA.

Sixty-one percentage of lymph nodes were found in the central quarters of the line drawn from the mental protuberance to the mandibular angle. These data can help as a static anatomic reference for the design of the flap. We also observed that about 63% of the lymph nodes were located in a 2-cm radius circle drawn from the medial border of the submandibular gland. This information should be carefully considered to include and preserve as many lymph nodes as possible during surgery. The VSLN flap was designed to harvest the majority of lymph node on the submental area, majorly located the central 2 quarters, and 2 cm of circus on the medial submandibular gland after this study (Fig. 5). Although there are 1 or 2 Ia lymph nodes on the medial submental area, they are not routinely harvested with the preservation of the medial platysma due to the possible complication of marginal mandibular pseudo-paralysis.²⁹ In this technique modification, we are able to harvest 72% of submental lymph nodes detected by preoperative MRI and minimizing the donor-site complications. As for the size of lymph nodes correlated with the functional outcome requires further investigation with more cases.

MRI is an important tool to evaluate patients preoperatively. The information acquired by MRI not only include just the number and size of lymph nodes but also the submental facial arterial anatomy, their relationship with submandibular gland, and differences between left and right side, that could help to reduce flap harvest time.³² The cost of decreasing operation time may be worthy for the use of preoperative MRI, but require more study.

The reasons for choosing CTA instead of MRI for the evaluation of the transferred submental lymph nodes postoperatively were as follows: The metallic hemoclips abutting the vascular pedicle of flap could produce sus-

ceptibility artifact with local signal change or focal image distortion in the MRI. This sometimes would result in difficulty to interpret the status of vessels and lymph nodes of the flap. Although metallic hemoclips could produce artifact in the CTA, we could overcome this problem with beam hardening correction kernel and CTA subtraction.

CONCLUSIONS

The preoperative MRI is a useful tool for the detection of mean 7.2 submental lymph nodes. Mean 72.2% of submental lymph nodes can be successfully transferred for extremity lymphedema with optimal functional recovery.

Ming-Huei Cheng, MD, MBA, FACS

Division of Reconstructive Microsurgery
Department of Plastic and Reconstructive Surgery
Chang Gung Memorial Hospital
College of Medicine
Chang Gung University
5 Fu-Hsing Street, Kueishan
Taoyuan 333, Taiwan
E-mail: minghuei@cgmh.org.tw

ACKNOWLEDGMENT

The authors thank Guadalupe Ruiz Merino, at Biosanitary Research Institute Virgen de la Arrixaca, Murcia, Spain for the statistical analysis.

REFERENCES

1. Raju A, Chang DW. Vascularized lymph node transfer for treatment of lymphedema: a comprehensive literature review. *Ann Surg.* 2015;261:1013–1023.
2. Becker C, Assouad J, Riquet M, et al. Postmastectomy lymphedema: long-term results following microsurgical lymph node transplantation. *Ann Surg.* 2006;243:313–315.
3. Lin CH, Ali R, Chen SC, et al. Vascularized groin lymph node transfer using the wrist as a recipient site for management of postmastectomy upper extremity lymphedema. *Plast Reconstr Surg.* 2009;123:1265–1275.
4. Cheng MH, Huang JJ, Wu CW, et al. The mechanism of vascularized lymph node transfer for lymphedema: natural lymphaticovenous drainage. *Plast Reconstr Surg.* 2014;133:192e–198e.
5. Ito R, Zelken J, Yang CY, et al. Proposed pathway and mechanism of vascularized lymph node flaps. *Gynecol Oncol.* 2016;141:182–188.
6. Tourani SS, Taylor GI, Ashton MW. Vascularized lymph node transfer: a review of the current evidence. *Plast Reconstr Surg.* 2016;137:985–993.
7. Pons G, Masia J, Loschi P, et al. A case of donor-site lymphedema after lymph node-superficial circumflex iliac artery perforator flap transfer. *J Plast Reconstr Aesthet Surg.* 2014;67:119–123.
8. Vignes S, Blanchard M, Yannoutsos A, et al. Complications of autologous lymph-node transplantation for limb lymphedema. *Eur J Vasc Endovasc Surg.* 2013;45:516–520.
9. Viitanen TP, Mäki MT, Seppänen MP, et al. Donor-site lymphatic function after microvascular lymph node transfer. *Plast Reconstr Surg.* 2012;130:1246–1253.
10. Allen RJ Jr, Cheng MH. Lymphedema surgery: patient selection and an overview of surgical techniques. *J Surg Oncol.* 2016;113:923–931.
11. Cheng MH, Huang JJ, Huang JJ, et al. A novel approach to the treatment of lower extremity lymphedema by transferring a vascularized submental lymph node flap to the ankle. *Gynecol Oncol.* 2012;126:93–98.

12. Ito R, Lin MC, Cheng MH. Simultaneous bilateral submental lymph node flaps for lower limb lymphedema post leg Charles procedure. *Plast Reconstr Surg Glob Open*. 2015;3:e513.
13. Nguyen DH, Chou PY, Hsieh YH, et al. Quantity of lymph nodes correlates with improvement in lymphatic drainage in treatment of hind limb lymphedema with lymph node flap transfer in rats. *Microsurgery*. 2016;36:239–245.
14. Patel KM, Chu SY, Huang JJ, et al. Preplanning vascularized lymph node transfer with duplex ultrasonography: an evaluation of 3 donor sites. *Plast Reconstr Surg Glob Open*. 2014;2:e193.
15. Cheng MH, Chen SC, Henry SL, et al. Vascularized groin lymph node flap transfer for postmastectomy upper limb lymphedema: flap anatomy, recipient sites, and outcomes. *Plast Reconstr Surg*. 2013;131:1286–1298.
16. Cheng MH, Chen SC, Henry SL, et al. Reply: vascularized groin lymph node flap transfer for postmastectomy upper limb lymphedema: the flap anatomy, recipient sites, and outcomes. *Plast Reconstr Surg*. 2014;133:428e–429e.
17. Patel KM, Lin CY, Cheng MH. From theory to evidence: long-term evaluation of the mechanism of action and flap integration of distal vascularized lymph node transfers. *J Reconstr Microsurg*. 2015;31:26–30.
18. Patel KM, Lin CY, Cheng MH. A prospective evaluation of lymphedema-specific quality-of-life outcomes following vascularized lymph node transfer. *Ann Surg Oncol*. 2015;22:2424–2430.
19. Qiu SS, Chen HY, Cheng MH. Vascularized lymph node flap transfer and lymphovenous anastomosis for Klippel-Trenaunay syndrome with congenital lymphedema. *Plast Reconstr Surg Glob Open*. 2014;2:e167.
20. Ito R, Suami H. Overview of lymph node transfer for lymphedema treatment. *Plast Reconstr Surg*. 2014;134:548–556.
21. Saaristo AM, Niemi TS, Viitanen TP, et al. Microvascular breast reconstruction and lymph node transfer for postmastectomy lymphedema patients. *Ann Surg*. 2012;255:468–473.
22. Dayan JH, Dayan E, Kagen A, et al. The use of magnetic resonance angiography in vascularized groin lymph node transfer: an anatomic study. *J Reconstr Microsurg*. 2014;30:41–45.
23. Scaglioni MF, Suami H. Lymphatic anatomy of the inguinal region in aid of vascularized lymph node flap harvesting. *J Plast Reconstr Aesthet Surg*. 2015;68:419–427.
24. Tourani SS, Taylor GI, Ashton MW. Anatomy of the superficial lymphatics of the abdominal wall and the upper thigh and its implications in lymphatic microsurgery. *J Plast Reconstr Aesthet Surg*. 2013;66:1390–1395.
25. Zhang H, Chen W, Mu L, et al. The distribution of lymph nodes and their nutrient vessels in the groin region: an anatomic study for design of the lymph node flap. *Microsurgery*. 2014;34:558–561.
26. Dayan JH, Dayan E, Smith ML. Reverse lymphatic mapping: a new technique for maximizing safety in vascularized lymph node transfer. *Plast Reconstr Surg*. 2015;135:277–285.
27. Robbins KT, Clayman G, Levine PA, et al; American Head and Neck Society; American Academy of Otolaryngology–Head and Neck Surgery. Neck dissection classification update: revisions proposed by the American Head and Neck Society and the American Academy of Otolaryngology–Head and Neck Surgery. *Arch Otolaryngol Head Neck Surg*. 2002;128:751–758.
28. Tan PW, Goh T, Nonomura H, et al. Hilar vessels of the submandibular and upper jugular neck lymph nodes: anatomical study for vascularized lymph node transfer to extremity lymphedema. *Ann Plast Surg*. 2016;76:117–123.
29. Poccia I, Lin CY, Cheng MH. Platysma-sparing vascularized submental lymph node flap transfer for extremity lymphedema. *J Surg Oncol*. 2017;115:48–53.
30. Kagen AC, Hossain R, Dayan E, et al. Modern perforator flap imaging with high-resolution blood pool MR angiography. *Radiographics*. 2015;35:901–915.
31. Mathes DW, Neligan PC. Preoperative imaging techniques for perforator selection in abdomen-based microsurgical breast reconstruction. *Clin Plast Surg*. 2010;37:581–591, xi.
32. Cheng MH, Lin CY, Patel KM. A prospective clinical assessment of anatomic variability of the submental vascularized lymph node flap. *J Surg Oncol*. 2017;115:43–47.