



Extramedullary plasmacytoma of the tongue base

George Garas¹ • Natasha Choudhury¹ • Nidhi Prasad² • Taran Tatla¹

¹Department of Otorhinolaryngology and Head & Neck Surgery, Northwick Park Hospital, North West London Hospitals NHS Trust, London, UK

²Department of Pathology, Northwick Park Hospital, North West London Hospitals NHS Trust, London, UK

Correspondence to: George Garas. E-mail: garas_george@yahoo.com

DECLARATIONS

Competing interests

None declared

Funding

None

Ethical approval

Written informed consent to publication has been obtained from the patient or next of kin

Guarantor

GG

Contributorship

All authors contributed equally

Acknowledgements

We thank the patient for permitting us to publish this interesting and rare case

Reviewer

Arvind Singh

Despite its rarity, extramedullary plasmacytoma should be considered in the differential diagnosis of a base of tongue mass.

Case report

A 63-year-old man presented with a history of recurrent epistaxis. Past medical history included hypertension, diabetes mellitus and nasal polypoid. He was otherwise asymptomatic.

On presentation, fiberoptic nasendoscopy to visualize a source for his nasal bleeding, identified coincidental asymmetrical nodular soft tissue swellings in the left and right tongue base (Figure 1) and a left middle meatus polyp. The upper aerodigestive tract was otherwise unremarkable. Urgent radiological imaging of the head, neck and thorax was arranged. CT and MRI confirmed the presence of enlarged asymmetrical soft tissue masses of the tongue base. The right side was larger than the left with increased 18F-fluoro-2-deoxy-D-glucose (FDG) uptake on PET CT, indicating increased metabolic activity (Figure 2). There was no cervical lymphadenopathy or other pathology identified.

Routine blood tests, including full blood count with white cell differential, renal, bone, thyroid and liver function tests, in addition to C-reactive protein (CRP), erythrocyte sedimentation rate (ESR) and lactate dehydrogenase (LDH), were all normal.

The patient underwent panendoscopy. This included rigid nasendoscopy, pharyngoscopy, laryngoscopy and oesophagoscopy. Biopsies were obtained from the left and right tongue base, left middle meatus polyp and anterior ethmoids.

Histopathological examination of the tongue base biopsies showed polypoid squamous mucosa with a sheet-like infiltrate of plasma cells beneath the epithelium. These appeared differentiated; however, they also showed bi/multinucleation and mild atypia (Figure 3). On immunostaining, the plasma cells expressed CD79a, CD138, MUM 1 and CD56. They were negative for CD3, CD20, and cyclin D1. The cells stained with lambda but not kappa light chains. The remaining biopsies were unremarkable (allergic/inflammatory polyp and normal respiratory-type mucosa, respectively) with no evidence of dysplasia or malignancy.

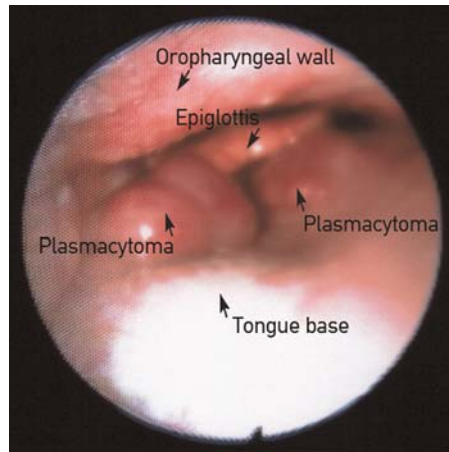
Subsequently, a skeletal survey, serum immunoglobulins, serum and urine protein electrophoresis (including urinary Bence-Jones proteins) and bone marrow trephine biopsy were performed. With the exception of lambda free light chains being markedly raised (93.9 mg/L) in the serum, all of these investigations were normal.

Following discussion in the Head and Neck Oncology multidisciplinary meeting (MDM), the extremely rare diagnosis of extramedullary plasmacytoma of the tongue base was made.¹ The patient received a 45Gy 4-week radiotherapy course to which he responded optimally. His lesions completely regressed and one year later there is no evidence of recurrence. However, the patient remains under close follow-up.

Discussion

Extramedullary plasmacytoma is a rare peripheral B-cell neoplasm comprising 1% of all head and

Figure 1
Endoscopic view of extramedullary plasmacytoma of the tongue base (structures labelled)



neck tumours. It constitutes one of three variants of plasma cell neoplasms, the other two being multiple myeloma and solitary bone plasmacytoma (also known as medullary plasmacytoma).² Extramedullary plasmacytoma accounts for 5–10% of all plasma cell neoplasms.¹ It shows a predilection towards the head and neck region with 80% of cases occurring in the upper aerodigestive tract.³ The areas most commonly involved include the nasal cavity, nasopharynx, paranasal sinuses and tonsils.⁴ It is extremely rare for this monoclonal gammopathy to involve the tongue base.¹ Extramedullary plasmacytoma more commonly affects men than women with a male:female ratio of 3:1. The median age of presentation is 55 years.⁴

Extramedullary plasmacytoma can present as either a solitary lesion or as multiple deposits outside the skeleton. In the presence of additional skeletal deposits, the diagnosis is that of multiple myeloma.⁵ However, on initial presentation multiple myeloma can also manifest as a solitary mass thereby mimicking extramedullary plasmacytoma. Multiple myeloma is the commonest plasma cell neoplasia accounting for more than 90% of cases, the remaining being extramedullary plasmacytoma or solitary bone plasmacytoma. The prognosis of multiple myeloma is poor with a mean survival of 2–3 years. Extramedullary plasmacytoma carries the best prognosis of all plasma cell neoplasms with a 70% 10-year survival.² However, the risk of progression to multiple

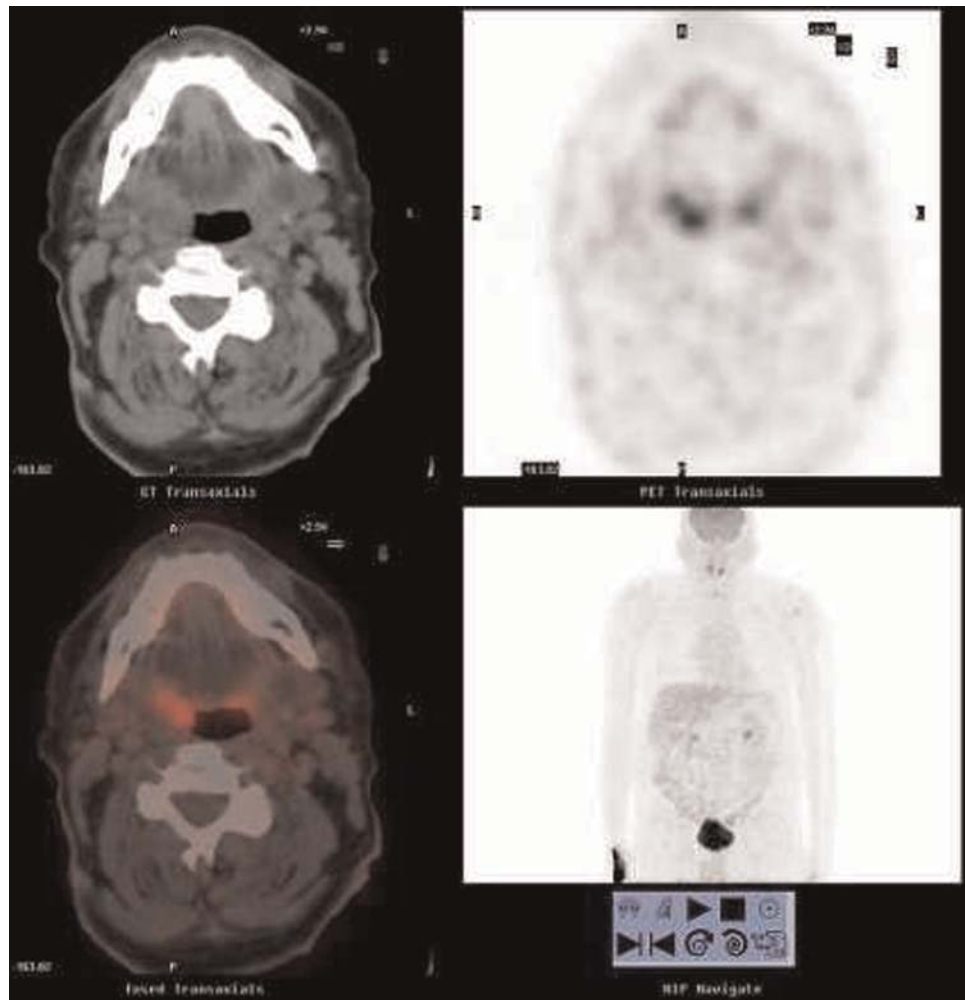
myeloma is significant with approximately 40% of patients progressing to multiple myeloma. Therefore, close follow-up following treatment for extramedullary plasmacytoma is strongly recommended.⁵

The initial diagnosis of extramedullary plasmacytoma is made from histopathological examination of biopsy specimens. It is essential to take deep biopsies, as 80% of extramedullary plasmacytomas arise from the submucosa and hence superficial biopsies alone can lead to a false-negative result with detrimental consequences for the patient.² Therefore, the threshold for repeat biopsy should be low, especially when there is strong clinical suspicion.

Histopathological diagnosis of plasma cell neoplasias requires evidence of malignant monoclonal proliferation of a plasma cell line. The plasma cells are functional producing CD138 and a monoclonal cytoplasmic light chain, either kappa or lambda.⁵ Salient histological features of extramedullary plasmacytoma include infiltration of the affected soft tissue with plasma cells. The plasma cells are typically immature and display features of malignancy such as cellular immaturity with atypical hyperchromatic nuclei and no visible nucleoli. As the plasma cell line expansion is monoclonal and the plasma cells are functional, immunohistochemistry will demonstrate light chain restriction.¹ Depending on the type of immunoglobulin and light chain type produced, plasmacytomas can be subdivided further, based on these immunohistochemical findings.^{1,5} Moreover, amyloid deposition is common in plasmacytomas and this can be detected as deposits appearing apple green under polarized light and red when the tumour is stained with Congo red stain.⁵

Once the diagnosis of a plasma cell tumour is obtained with immunohistochemistry or flow cytology (and its distinction from other haematological malignancies such as extranodal marginal zone lymphoma made), the next step is to distinguish whether this constitutes a solitary lesion consistent with a plasmacytoma or whether it is part of multiple body lesions signifying multiple myeloma.^{4,6} Haematological, biochemical and radiological investigations should be employed to screen for additional extra-skeletal or skeletal involvement.⁴

Haematological and biochemical investigations should include full blood count with white cell

Figure 2**PET CT indicating increased metabolic activity in the tongue base, more on the right side**

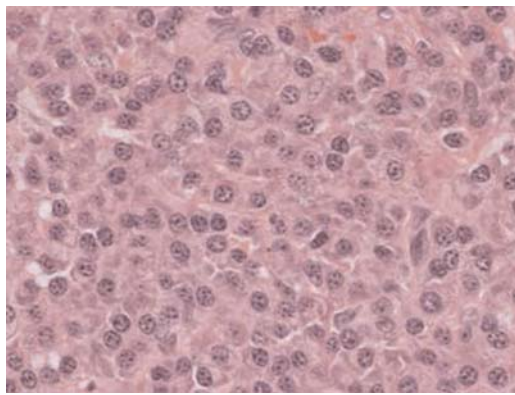
differential, serum urea, creatinine and electrolytes, CRP, ESR and beta-2 microglobulin and immunoglobulin concentrations. The skeletal survey should include serum calcium, albumin (for corrected calcium) and alkaline phosphatase. In addition, serum and urine protein electrophoresis as well as urinalysis for Bence-Jones proteins should be considered. Finally, bone marrow trephine biopsy is often needed and constitutes an important component of the diagnostic work-up.^{1,5}

Radiological investigations including CT and/or MRI are useful in staging extramedullary plasmacytoma by assessing for lymphadenopathy as well as bony involvement. Moreover, if

technetium contrast is used, CT and MRI can help distinguish between inflammatory and neoplastic tissue. Nuclear medicine modalities such as gallium scanning are useful, as the radioisotope is selectively taken up by the malignant cells as a result of their high metabolic requirements and mitotic index.⁴ More recently, positron-emission tomography (PET) scanning with FDG has been used in the diagnosis of extramedullary plasmacytoma of the tongue where the extramedullary plasmacytoma had not been visualized with any other imaging modality or endoscopy.^{7,8}

Plasmacytomas are highly radiosensitive tumours; hence the recommended treatment for

Figure 3
Photomicrograph of submucosal section of tongue base biopsy containing plasma cells exhibiting bi/multinucleation and mild atypia



extramedullary plasmacytoma is either external beam radiotherapy or surgery. These treatment modalities are equally effective with similar rates of recurrence of around 12.5%.^{4,6} Several authors recommend a combination of the two as the optimal treatment for extramedullary plasmacytoma.⁹

The decision of which treatment modality is selected depends on numerous factors and should be decided through a Head and Neck Oncology multidisciplinary team (MDT) meeting in conjunction with the patient's wishes. Surgery is usually avoided if the potential morbidity is high, such as in our case of extramedullary plasmacytoma of the tongue base; resection of the tongue base would potentially have a significant impact on the patient's quality of life by impairing speech and swallowing.⁵ In such cases, external beam radiotherapy may be the initial treatment offered to the patient with a curative intent.¹

Conversely, if the tumour is large, neoadjuvant surgical debulking can be performed increasing the chances of local control with subsequent external beam radiotherapy.²

The prognosis for extramedullary plasmacytoma depends on tumour size and involvement of lymph nodes. It is better than multiple myeloma or solitary bone plasmacytoma, with a 10-year survival in excess of 70%.^{4,10} Thus, correct diagnosis and differentiation from other tumours arising in the head and neck is of prime importance.⁴

References

- 1 Hama Y, Uematsu M, Kusano S. Solitary extramedullary plasmacytoma of the tongue. *Ulster Med J* 2004;**73**:132–4
- 2 Iseri M, Ozturk M, Ulubil SA. Synchronous presentation of extramedullary plasmacytoma in the nasopharynx and the larynx. *Ear Nose Throat J* 2009;**88**:E9–12
- 3 Galieni P, Cavo M, Pulsoni A, *et al.* Clinical outcome of extramedullary plasmacytoma. *Haematologica* 2000;**85**:47–51
- 4 Straetmans J, Stokroos R. Extramedullary plasmacytomas in the head and neck region. *Eur Arch Otorhinolaryngol* 2008;**265**:1417–23
- 5 Webb CJ, Makura ZG, Jackson SR, Helliwell T. Primary extramedullary plasmacytoma of the tongue base. Case report and review of the literature. *ORL J Otorhinolaryngol Relat Spec* 2002;**64**:278–80
- 6 Marom T, Goldfarb A, Vaknine H, Kravtsov V, Roth Y. Clinical photograph. Sinonasal extramedullary plasmacytoma. *Otolaryngol Head Neck Surg* 2009;**141**:533–4
- 7 Braams JW, Pruijm J, Kole AC, *et al.* Detection of unknown primary head and neck tumors by positron emission tomography. *Int J Oral Maxillofac Surg* 1997;**26**:112–15
- 8 Kole AC, Nieweg OE, Pruijm J, *et al.* Detection of unknown occult primary tumors using positron emission tomography. *Cancer* 1998;**82**:1160–6
- 9 Tsang RW, Gospodarowicz MK, Pintilie M, *et al.* Solitary plasmacytoma treated with radiotherapy: impact of tumor size on outcome. *Int J Radiat Oncol Biol Phys* 2001;**50**:113–20
- 10 Fraser SC, Bishop JA, Champaneri S, Tufano RP. Pathology quiz case 2: extramedullary plasmacytoma (EMP). *Arch Otolaryngol Head Neck Surg* 2010;**136**:635, 636–5, 637.v

© 2010 Royal Society of Medicine Press

This is an open-access article distributed under the terms of the Creative Commons Attribution License (<http://creativecommons.org/licenses/by-nc/2.0/>), which permits non-commercial use, distribution and reproduction in any medium, provided the original work is properly cited.