

# A case of disseminated cryptococcal disease after Bruton tyrosine kinase inhibitor therapy: A brief review in the Australian context



Nicholas Van Rooij, MD,<sup>a,b,c</sup> Jesse Johnston, MBBS, FACD,<sup>a</sup> Rohan Mortimore, MBBS, FRCPA,<sup>a</sup> and Ivan Robertson, MBBS, FACD<sup>a</sup>  
Brisbane, Southport, and St Lucia, Queensland, Australia

**Key words:** dermatology; drug reaction; eruption; hematology; ibrutinib.

## INTRODUCTION

The use of Bruton tyrosine kinase (BTK) inhibitors for the treatment of a number of hematological conditions is rapidly increasing. Ibrutinib is the most clinically advanced and common BTK inhibitor currently utilized. Its use, however, comes with increasing reports of immunosuppression and increased risk of opportunistic infections.<sup>1</sup> We present the case of a widespread papulonodular eruption secondary to disseminated cryptococcal disease after ibrutinib therapy, which the authors believe is the first reported case with widespread cutaneous involvement.

## CASE REPORT

A 75-year-old man presented with a 6-week history of papules and nodules of the face, oral mucosa, trunk, and limbs (Fig 1). The patient also reported intermittent episodes of fever, blurred vision, and progressively worsening headaches. He had a past medical history significant for lymphoplasmacytic lymphoma diagnosed in 2006 with progression to Mantle cell lymphoma stage 4A in 2017. In 2018, he had symptomatic pelvic outlet obstruction and was commenced on ibrutinib 560 mg daily, 6 months prior to the presentation of the cutaneous eruption.

An excisional biopsy was taken from a papule, which revealed a dermal infiltrate consisting of numerous budding yeasts (Fig 2). Culture subsequently positive for *Cryptococcus neoformans*. Consultation by our Neurology team resulted in a lumbar puncture, which revealed a protein concentration of 1400 mg/L (normal range, 150-450 mg/L), a glucose level of 20 mmol/L (normal range, 2.8-

### Abbreviation used:

BTK: Bruton tyrosine kinase

4.4 mmol/L), and a Gram stain, which also identified yeast cells. Ophthalmic evaluation identified numerous reflective spheres on fundoscopy consistent with chorioretinitis. The patient was subsequently diagnosed with disseminated cryptococcal infection with cryptococcal meningitis.

He was commenced on amphotericin B 300 mg daily and flucytosine 100 mg four times daily. Ibrutinib was discontinued after one week into therapy, as little clinical improvement was noted. At 2 weeks the patient was converted to fluconazole monotherapy, and over the coming months, a slow resolution of the papules and nodules was noted with clinical improvement.

## DISCUSSION

Ibrutinib is a BTK inhibitor increasingly utilized in several hematological disorders due to improved survival benefits. These disorders includes chronic lymphocytic leukemia, mantle cell lymphoma, Waldenström macroglobulinemia, and chronic graft-versus-host disease.<sup>2</sup> The recent establishment of these new targeted oral agents has advanced the treatment paradigm away from poorly tolerated traditional therapies consisting of alkylating agents. These BTK inhibitors act on B-cell proliferation and survival, subsequently playing a key role in humoral immunity.<sup>2</sup> However, in an often already immunocompromised patient cohort, the use of

From The Royal Brisbane and Women's Hospital<sup>a</sup>; School of Medicine, Griffith University, Southport<sup>b</sup>; and Faculty of Medicine, The University of Queensland, St Lucia.<sup>c</sup>

Funding sources: None.

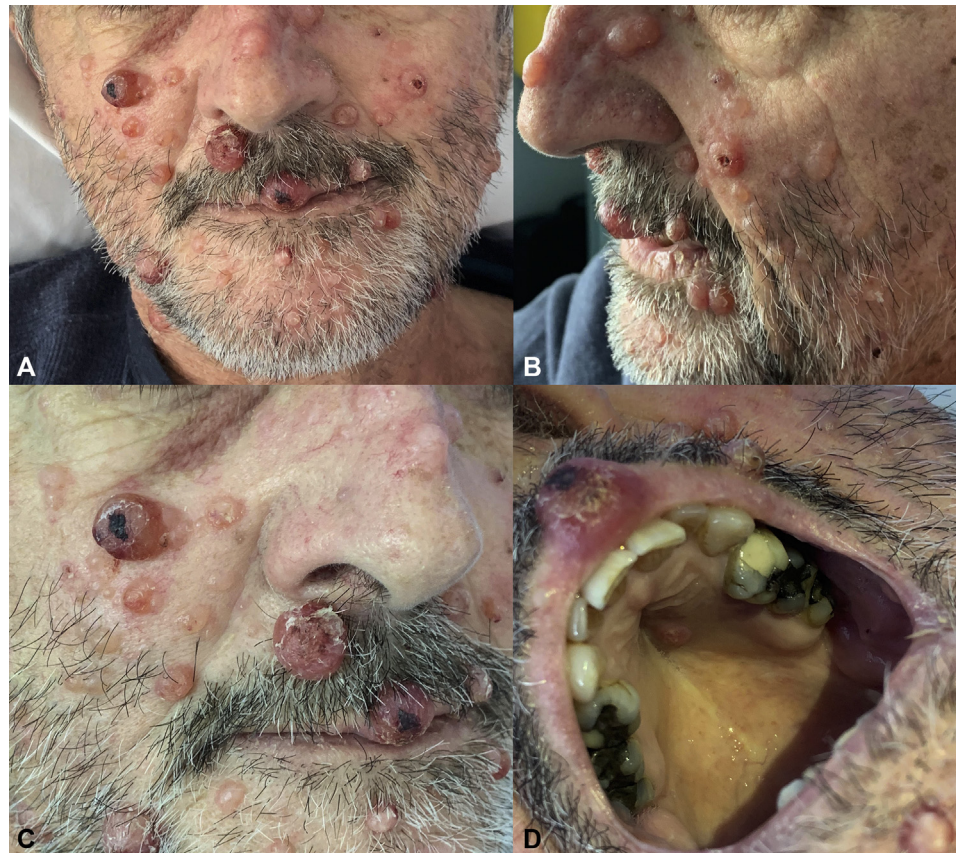Correspondence to: Nicholas Van Rooij, MD, The Royal Brisbane and Women's Hospital, Brisbane, Queensland 4006, Australia. E-mail: nicholasvanrooij@gmail.com.

JAAD Case Reports 2021;13:43-5.

2352-5126

© 2021 Published by Elsevier on behalf of the American Academy of Dermatology, Inc. This is an open access article under the CC BY-NC-ND license (<http://creativecommons.org/licenses/by-nc-nd/4.0/>).

<https://doi.org/10.1016/j.jidcr.2021.04.022>



**Fig 1. A-D,** Multiple dermal nodules and papules with oral involvement. Occasional lesions have central umbilication and central hemorrhagic crusting and peripheral hyperkeratosis.

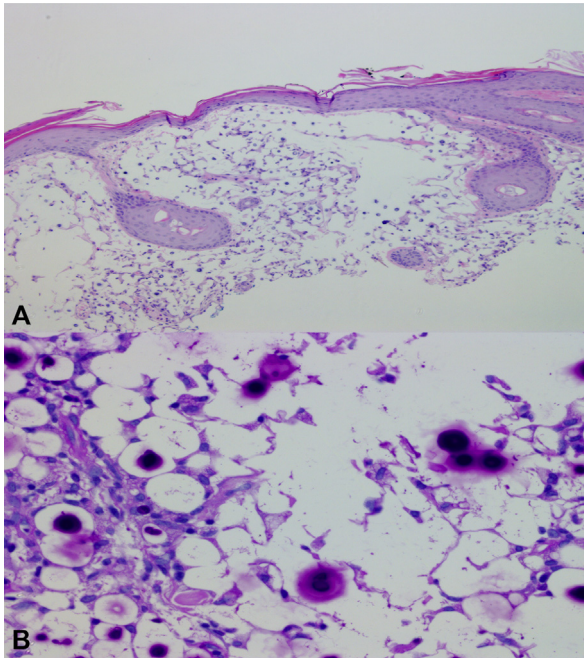
ibrutinib is resulting in a rate of serious infections of up to 11.4%.<sup>3</sup>

*Cryptococcus* sp. infection is a rare complication of ibrutinib treatment but is of significance due to its ability to develop into a potentially life-threatening infection. This encapsulated yeast may cause pneumonia and meningoencephalitis in immunocompromised patients, such as patients with HIV.<sup>2</sup> Globally, *C. neoformans* is responsible for the vast majority of human infections; however, *Cryptococcus gattii* has over the last decade gained notoriety, particularly in North America, for its ability to cause disease in immunocompetent individuals. In a local Australian context, *Cryptococcus bacillisporus* has been associated with a number of eucalypt species in tropical regions of Australia, affecting a immunocompetent, predominantly rural and Aboriginal population.<sup>4</sup> In our patient's case, *C. neoformans* was isolated, which is the species most commonly reported, and given his urban European heritage, the patient was considered a low-risk candidate for infection by local species.

A review of the literature identified recent infrequent reports of disseminated cryptococcal

infections in patients receiving ibrutinib, with the vast majority developing symptoms within 6 months of commencing treatment.<sup>5</sup> Reported cutaneous manifestations include subcutaneous collection, skin abscess and ulceration; however, all of these were findings observed throughout the patient's clinical course and not among the presenting complaints. No documented cases of generalized cutaneous eruptions have been reported with the use of ibrutinib. In the presented case, the patient's primary complaint was a generalized cutaneous eruption, which is distinctly different from other documented cases.

Dermatological features of cryptococcosis are rare; when reported, they most commonly affect the head and neck. Reported features include nodules, pustules, acneiform papules, molluscum contagiosum-like lesions, ulcerations, cellulitides, and plaques.<sup>6</sup> In immunosuppressed patients, disseminated disease is frequently reported as umbilicated papules, nodules and violaceous plaques. Most reported cases of *C. neoformans* skin findings occur in the setting of disseminated cryptococcosis, which is reported in only around 10%-15% of the presentations.<sup>7</sup> The



**Fig 2.** **A**, Thin otherwise normal epidermis with overlying regions of compact parakeratosis, dermal infiltrate faintly staining with hematoxylin-eosin. (original magnification:  $\times 10$ .) **B**, Numerous yeast organisms with prominent capsule with little staining with hematoxylin-eosin giving the dermis a vacuolated gelatinous appearance. (original magnification:  $\times 10$ .)

clinical presentation reported is consistent with cryptococcosis in immunosuppressed patients, and the authors believe this to be the first case associated with a generalized cutaneous eruption after ibrutinib therapy.

In immunocompetent patients, disease is often confined to the skin; however, in immunosuppressed individuals, cutaneous features—when present—are usually indicative of the severity of disseminated disease. Relevant investigations to distinguish primary disease from disseminated cryptococcal infection include blood culture, cerebrospinal fluid culture and cryptococcal antigen titers, urine microscopy and culture, glucuronoxylomannan antigen testing, chest computed tomography scan, and occasionally bronchoscopy.<sup>6</sup>

The presented case, along with other documented cases, suggests that clinicians should be aware that cryptococcal infections may occur in individuals treated with BTK inhibitors. Furthermore, the increasing penetrance of other kinase inhibitors, such as the Janus kinase inhibitors, in dermatological conditions including atopic dermatitis, alopecia areata, psoriasis, and vitiligo makes this of growing clinical significance. Documented cases of cryptococcal pneumonia have also been reported with the use of tofacitinib (Janus kinase inhibitor) in patients with psoriasis.<sup>8</sup>

In summary, we report a case of disseminated cryptococcal lesions, with papules and nodules, in an individual treated with a BTK inhibitor. Clinicians should be aware that cryptococcal lesions can present with widespread cutaneous involvement in individuals on tyrosine kinase inhibitors, as the use of these agents are increasingly utilized across a broad spectrum of medical specialties.

#### Conflicts of interest

None declared.

#### REFERENCES

1. Aalipour A, Advani RH. Bruton's tyrosine kinase inhibitors and their clinical potential in the treatment of B-cell malignancies: focus on ibrutinib. *Ther Adv Hematol*. 2014;5(4):121-133.
2. Stankowicz M, Banaszynski M, Crawford R. Cryptococcal infections in two patients receiving ibrutinib therapy for chronic lymphocytic leukemia. *J Oncol Pharm Pract*. 2019;25(3):710-714.
3. Varughese T, Taur Y, Cohen N, et al. Serious infections in patients receiving ibrutinib for treatment of lymphoid cancer. *Clin Infect Dis*. 2018;67(5):687-692.
4. Jenney A, Pandithage K, Fisher DA, Currie BJ. *Cryptococcus* infection in tropical Australia. *J Clin Microbiol*. 2004;42(8):3865-3868.
5. Brochard J, Morio F, Mahe J, et al. Ibrutinib, a bruton's tyrosine kinase inhibitor, a new risk factor for cryptococcosis. *Med Mal Infect*. 2020;50(8):742-745.
6. Noguchi H, Matsumoto T, Kimura U, Hiruma M, Kusuhara M, Ihn H. Cutaneous cryptococcosis. *Med Mycol J*. 2019;60(4):101-107.
7. Anderson DJ, Schmidt C, Goodman J, Pomeroy C. Cryptococcal disease presenting as cellulitis. *Clin Infect Dis*. 1992;14(3):666-672.
8. Seminario-Vidal L, Cantrell W, Elewski BE. Pulmonary cryptococcosis in the setting of tofacitinib therapy for psoriasis. *J Drugs Dermatol*. 2015;14(8):901-902.