

HOSTED BY



ELSEVIER

Contents lists available at ScienceDirect

Chinese Journal of Traumatology

journal homepage: <http://www.elsevier.com/locate/CJTEE>

Original article

A distal-lock electromagnetic targeting device for intramedullary nailing: Suggestions and clinical experience

Guido Antonini, Wilfried Stuflesser, Cornelio Crippa, Georgios Touloupakis*

Department of Orthopedics and Traumatology, San Carlo Borromeo Hospital, Milan, Italy

ARTICLE INFO

Article history:

Received 6 April 2016

Received in revised form

19 July 2016

Accepted 20 July 2016

Available online 20 September 2016

Keywords:

Intramedullary nailing

SureShot

Distal locking

Radiation exposure

Electromagnetic guidance

ABSTRACT

Purpose: To describe our clinical experience with a system named SureShot™ Distal Targeting (Smith & Nephew, Memphis, USA) based on magnetic field presence and discuss our suggestions on this technique.

Methods: We analysed prospectively 47 patients affected by humeral, tibial or femoral fractures, treated in our institution during a 3-year period of time (August 2010 to September 2013). We considered the following parameters: the time to set up, the time to position a single screw, the effectiveness of the system (drilling and screwing), the irradiation exposure time during distal locking procedure and surgical complications.

Results: A total number of 96 screws were inserted. The mean preparation time of the device was 5.1 min ± 2 min (range 3–10 min). The mean time for single screw targeting was 5.8 min ± 2.3 min (range 4–18 min). No major complications occurred. Only a few locking procedures were needed to be practiced in order to obtain the required expertise with this targeting device.

Conclusion: According to our results, this device is reliable and valid whenever the correct technique is followed. It is also user friendly, exposes to lower radiation and needs less surgical time compared to relative data from the literature. However, the surgeon should always be aware of how to use the free hand technique in case of malfunctioning of the system.

© 2016 Daping Hospital and the Research Institute of Surgery of the Third Military Medical University.

Production and hosting by Elsevier B.V. This is an open access article under the CC BY-NC-ND license (<http://creativecommons.org/licenses/by-nc-nd/4.0/>).

Introduction

Intramedullary nailing is widely considered to be the gold standard treatment for diaphyseal fractures; however, the distal locking with a “free-hand” technique still remains a challenging part of the procedure.¹ Related caveats include: the radiation exposure of both the patient and the staff, the surgical time loss, especially during the surgeon’s “learning curve” and medically-induced complications, such as misalignment due to the manoeuvres during fluoroscopy or fracture due to wrong drilling.^{2–4}

A large number of targeting devices have been proposed to address this issue but the results are controversial.^{5–8} Here, we describe our clinical experience with a system named SureShot™

Distal Targeting (Smith & Nephew, USA) based on magnetic field presence and discuss our suggestions on this technique. The main features of this system are the radiation-free technology and a three dimensional real-time feedback of position and orientation of the drilling and screwing procedures.

Materials and methods

SureShot technique and suggestions

The procedure can be summarized as follows:

1. Placing the monitor
2. Positioning of the probe inside the nail (Fig. 1A)
3. Positioning of the sleeve on the “targeter” (small or large)
4. Connection of the “targeter” and probe into the monitor and options selection (Nail type and its diameter; sleeve type) (Fig. 1B)
5. Collimation of the targets through navigation (Fig. 1C)
6. Assisted drilling (Fig. 2)
7. Assisted screwing (Fig. 3)

* Corresponding author.

E-mail address: yorgostoulou@gmail.com (G. Touloupakis).

Peer review under responsibility of Daping Hospital and the Research Institute of Surgery of the Third Military Medical University.




Fig. 1. A: Positioning of the probe inside the nail; B: Selection of nail type; C: Collimation of the targets.




Fig. 2. Assisted drilling with the “targeter” in one hand and the drill in the other one.

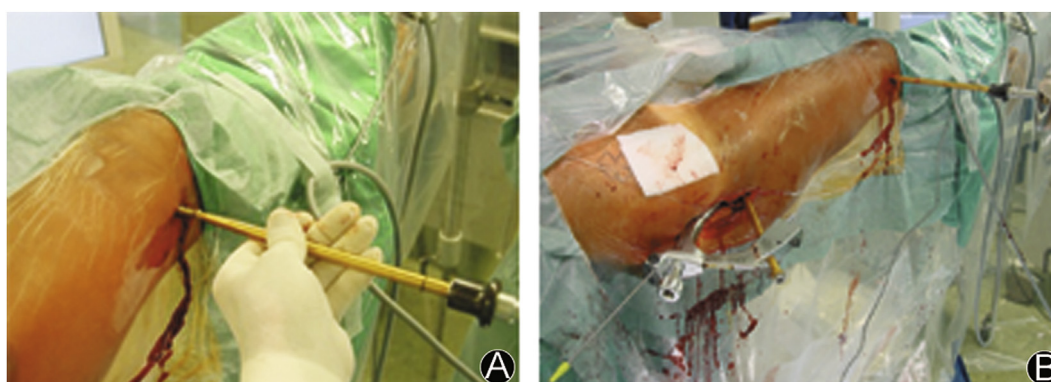


Fig. 3. A: Assisted drilling; B: Assisted screwing.

Positioning of the monitor

The monitor is positioned by the room surgery staff.

Suggestions: To our experience, the best position would be in front of the surgeon and not on the same side. This means that the monitor should be placed on the other side of the patient for femoral and tibiae nailing, or eventually, close to the head of the patient when humeral fracture is being treated. In this way, the surgeon can view both the monitor and his hands on the “targeter” for better coordination of his own movements. In case the surgeon has to move his head to the right or to the left in order to look at the monitor, his hands are not in his visual field and he is basically being guided by his own proprioceptive sensibility to coordinate his movements.

Positioning of the probe inside the nail

The probe needs to be inserted inside the nail at the right length. There is a special tool attached to the proximal part of the nail introducer that fixes the probe to the desired length and is marked on the probe.

Suggestions: The probe has to be carefully put in the right position: the surgeon has to check the marked length on the probe.

Positioning of the sleeve on the “targeter”

There are two types of sleeves depending on the depth of the soft tissue around the bone: the short sleeve, for tibia and humerus bones and the long sleeve for the femur bone. Each sleeve has to be paired with its corresponding drill. The surgeon may use the one he prefers for each case and select the option on touch-screen.

Suggestions: We recommend the use of the short one because the distance between the hands and hole nail is shorter: a short drill is run easier compared to a long drill. The soft tissue in humeral and femoral shaft will help keep the sleeve in place.

Connection of the “targeter” and probe into the monitor and options selection

These steps are made by a “non-sterile” assistant of the surgical staff. The surgeon always needs to check so as to avoid any error in the selection of the options.

Collimation of the targets through navigation

The distal locking holes are identified percutaneously by bringing closer together the “targeter” and the skin. Skin and fascia

are incised, the muscle is dissected and the guide will be positioned down to the bone cortex. The surgeon has a continuous visual feedback of the drill position on the monitor. He has to collimate the two coloured targets on the monitor. The nail position on the monitor can be rotated. This is a very important step.

Suggestions: The nail position on the monitor should be the same as the real limb in front of the surgeon's eyes at the same angle, with relation to the horizontal line. In some cases, i.e. in the case of tibiae or humeral nailing, the limb is not horizontal. The same position of the virtual and real nail facilitates the collimation of the targets.

Assisted drilling

The surgeon usually manoeuvres the “targeter” with his hands until the right position of the targets is reached. The first part is to reach the right position of the target on the bone (in front of the nail interlocking hole); the second part is to check the right direction. He leaves it with his dominant hand to hold the drill and to put it inside the sleeve. During this step, he can loosen the right position of the sleeve into the bone or the right position on the monitor.

Suggestions: We suggest collimating immediately with the “targeter” in one hand and the drill in the other while being inside the sleeve. We also recommend leaning both the sleeve and the drill against the bone during the first part, so as to avoid the gliding and the consequent loosening of the right position. This is important especially for the humeral nailing. In this case, the bone surface is not flat so the surgeon must be careful not to slide the sleeve down during targeting. As soon as the collimation is achieved, the surgeon is able to easily drill the bone.

Assisted screwing

The surgeons can tighten the screw by either using the free hand technique or by using the “targeter” for assisted navigation. Generally, the surgeon who drills with SureShot looks directly at the monitor but not at the actual direction of the drill. The use of the free hand technique in order to reach the right position of the drill step by step using fluoroscopy is necessary so as to memorize the position and in order to tighten the screw. This cannot be achieved by using the navigation system.

Suggestions: We recommend using the “targeter” to screw and at the same time to look at the position used while drilling and to memorize it in order to do a faster screwing.

Clinical experience

We analysed prospectively 47 patients affected by humeral, tibial or femoral fracture, treated in our institution during a 3-year period of time (August 2010 to September 2013). All fractures were treated with TriGen Nail (Smith&Nephew, USA) with two or three distal locking screws inserted using the SureShot™ Distal Targeting Device (Smith&Nephew, USA). We considered the following parameters: the time to set up, the time to position a single screw, the effectiveness of the system (drilling and screwing), the irradiation exposure time during distal locking procedure and surgical complications.

The time to prepare the instrumentation was recorded considering the overall time (measured in minutes): to place the monitor, to insert the probe inside the nail and to connect the probe and the targeter to the monitor. This is an additional time consuming procedure compared to the “free-hand” technique.

The time for positioning a single screw was measured starting from the collimation to the last fluoroscopic shot, in order to confirm the correct position and the length of the screw.

Any drill or screw misplacement was recorded. Failure of the technique was defined by the number of cases in which targeting the distal locking hole was impossible or the correct position of the screw was not obtained.

Results

A total number of 96 screws were inserted. The intervention was conducted by 9 surgeons. The mean preparation time of the device was (5.1 ± 2) min (range 3–10 min). The mean time for single screw targeting was (5.8 ± 2.3) min (range 4–18 min). In two of our cases the drill bit was not inserted at first shot and simply dashed into the nail: in both cases an alarm appeared on the monitor due to interference with metal. The drill was correctly executed after the nurse removed the metal table onto which the patient's foot was positioned. In one case, the probe had to be changed because of dysfunction.

All but 6 screws were perfectly inserted. In these six cases, the drilling was correct but the surgeon did not use the “targeter” to tighten the screw. The screws were then correctly positioned with the “targeter's” aim. In 5 cases the screw had to be changed because it was either too long or too short, compared to the fluoroscopic control image: the extra time consumed during this procedure was included in the study. No major complications occurred.

Discussion

Common problems of distal locking typically include time of radiation exposure and the possibility of failure. The deformation of the nail inside the intramedullary canal is the reason of failure of mechanical guides.

The use of this system helps avoid this problem by using a flexible self-adapting probe of the shape of the nail itself inserted into the bone. The probe generates an electromagnetic field which is picked up by the system and gives immediate feedback of the holes' position. The main problem of electromagnetic field in surgery rooms is its interference with metal or a magnetic field material generated by other instruments placed in surgery rooms.⁸ For this reason, the instructions suggest to remove any metal object before the procedure.

An alarm will appear on the monitor in case of interference. From our experience, there is no interference with the metal of the traction table, which is quite near to the distal part of the probe and the “targeter” but not with the lead vest. In the 2 cases of drilling failure the system displayed an intermittent alarm on the monitor due to the presence of the nurse table near the probe. The problem was solved by simply removing it.

The system assists the surgeon during the screwing process too. Some surgeons prefer doing it by free hand, but 6 cases of failure were recorded. This is probably due to the fact that the surgeon does not have to keep in mind the real position of the drilling but he just has to look at the monitor during navigation, and this typically avoids failure usually noticed during free-hand screwing manoeuvre. We suggest following the original technique and using the “targeter” both for the screwing and for the drilling. When we used the distal “targeter” we had no cases of failure.

Only a few locking procedures were needed to be practiced in order to obtain the required expertise with this targeting device. According to the literature, an average time of 6 min per screw can be considered an excellent result.^{9,10} The final outcome in all shots resulted in getting the screw into the right place.

Furthermore, the X-ray exposure is null: the only exposure is during the check of the right length and positioning of the screw. For this reason, in this study we did not have a control group treated with the standard free-hand technique. From our experience the X-ray exposure and surgery time is higher in the free hand technique but we have not reported related data.

However, the surgeon should always be aware of how to use the free hand technique in case of malfunctioning of the system. According to our results, this device is reliable and valid whenever the correct technique is followed. It is also user friendly, exposes to

lower radiation and needs less surgical time compared to related data from the literature.

Further studies are needed to investigate whether this device is also cost-effective compared to the free-hand technique. Lastly, it should be investigated whether this procedure is time-saving or not; it would be important to know if the use of the surgery room is also convenient in terms of costs.

References

1. Gugala Z, Nana A, Lindsey RW. Tibial intramedullary nail distal interlocking screw placement: comparison of the free-hand versus distally-based targeting device techniques. *Injury*. 2001;32:SD21-5.
2. Moreschini O, Petrucci V, Cannata R. Insertion of distal locking screws of tibial intramedullary nails: a comparison between the free-hand technique and the SURESHOT™ Distal Targeting System. *Injury*. 2014;45:405–407. <http://dx.doi.org/10.1016/j.injury.2013.09.023>.
3. Dursun M, Kalkan T, Aytakin MN, et al. Does the magnetic-guided intramedullary nailing technique shorten operation time and radiation exposure? *Eur J Orthop Surg Traumatol*. 2014;24:1005–1011. <http://dx.doi.org/10.1007/s00590-013-1269-z>.
4. Uruc V, Ozden R, Dogramacı Y, et al. The comparison of freehand fluoroscopic guidance and electromagnetic navigation for distal locking of intramedullary implants. *Injury*. 2013;44:863–866. <http://dx.doi.org/10.1016/j.injury.2012.12.009>.
5. Stathopoulos I, Karampinas P, Evangelopoulos DS, et al. Radiation-free distal locking of intramedullary nails: evaluation of a new electromagnetic computer-assisted guidance system. *Injury*. 2013;44:872–875. <http://dx.doi.org/10.1016/j.injury.2012.08.051>.
6. Hoffmann M, Schröder M, Lehmann W, et al. Next generation distal locking for intramedullary nails using an electromagnetic X-ray-radiation-free real-time navigation system. *J Trauma Acute Care Surg*. 2012;73:243–248. <http://dx.doi.org/10.1097/TA.0b013e31824b0088>.
7. Anastopoulos G, Ntagiopoulos PG, Chissas D, et al. Evaluation of the Stryker S2 IM Nail Distal Targeting Device for reduction of radiation exposure: a case series study. *Injury*. 2008;39:1210–1215. <http://dx.doi.org/10.1016/j.injury.2008.04.020>.
8. Tyropoulos S, Garnavos C. A new distal targeting device for closed interlocking nailing. *Injury*. 2001;32:732–735.
9. Pardiwala D, Prabhu V, Dudhniwala G, et al. The AO distal locking aiming device: an evaluation of efficacy and learning curve. *Injury*. 2001;32:713–718.
10. Chan DS, Burris RB, Erdogan M, et al. The insertion of intramedullary nail locking screws without fluoroscopy: a faster and safer technique. *J Orthop Trauma*. 2013;27:363–366. <http://dx.doi.org/10.1097/BOT.0b013e3182828e10>.