



Received: 2016.07.10
Accepted: 2016.08.10
Published: 2017.03.16

Authors' Contribution:

- A** Study Design
- B** Data Collection
- C** Statistical Analysis
- D** Data Interpretation
- E** Manuscript Preparation
- F** Literature Search
- G** Funds Collection

Ultrasonographic Diagnosis of Slipped Capital Femoral Epiphysis

Manikandan Palaniappan^{ABCDF}, Venkatraman Indiran^{ABCDEF},
Prabakaran Maduraimuthu^{DEF}

Department of Radiodiagnosis, Sree Balaji Medical College and Hospital, Chennai, India

Author's address: Venkatraman Indiran, Department of Radiodiagnosis, Sree Balaji Medical College and Hospital, Chennai, India, e-mail: ivraman31@gmail.com

Background:

Slipped capital femoral epiphysis (SCFE), a fracture through the physis with resultant slip of the epiphysis, is the most common hip abnormality in adolescents and is a major cause of early osteoarthritis. Plain radiograph is the initial modality used to evaluate patients with painful hip joints. Ultrasonography and magnetic resonance imaging (MRI), which do not involve radiation exposure, have also been used. This case report supports the view that ultrasound can be used as an initial, cost-effective and radiation-free modality for the evaluation of suspected SCFE.

Case Report:

A 15-year-old male patient presented with pain in the right hip for 5 days, following a slip and fall accident while playing soccer. The patient was referred to the Department of Radio-diagnosis for ultrasound. A posterior displacement of the femoral head epiphysis with a physeal step was seen on the longitudinal section obtained over the right hip joint region. The anterior physeal step (APS) measured ~3.8 mm on the right side. The distance between the anterior rim of the acetabulum and the metaphysis measured ~20.4 mm on the affected right side and ~23.6 mm on the left side. A plain radiograph in frog leg position showed a widening of the right proximal physis below the right femoral head, with a medial and posterior slip of the right femoral head. A frontal radiograph of the pelvis taken six months before showed a widening of the proximal right femoral physis.

Conclusions:

Although MRI appears to be the most sensitive modality for identifying slips early, ultrasound may be used as a cost-effective and radiation-free alternative before proceeding with further evaluation of suspected SCFE, especially considering the demographics of the affected population.

MeSH Keywords:

Radiography • Slipped Capital Femoral Epiphyses • Ultrasonography

PDF file:

<http://www.polradiol.com/abstract/index/idArt/900504>

Background

Slipped capital femoral epiphysis (SCFE) is one of the most important pediatric and adolescent hip disorders. SCFE represents type I Salter and Harris growth plate injury of the proximal femoral growth plate. It usually occurs due to trauma with or without associated metabolic or endocrine disturbances such as renal osteodystrophy and hypothyroidism. It usually occurs in obese and taller individuals during periods of pubertal growth spurt. SCFE has a male preponderance and is bilateral in about 25%. Patients usually present with groin pain with or without associated thigh or knee pain. Most patients will be able to bear weight and will present with a limp, as was seen in our

patient. Diagnosing slipped capital femoral epiphysis at an early stage can prevent possible complications such as osteoarthritis, chondrolysis, osteonecrosis and avascular necrosis.

Case Report

A 15-year-old male patient presented with pain in the right hip for 5 days, following a slip and fall accident while playing soccer. The pain was radiating to the right thigh with aggravation on movement. There was no fever. The pain was not relieved with analgesics. On examination, the patient had a limping gait. There was no local warmth or tenderness in the right groin. There was no other

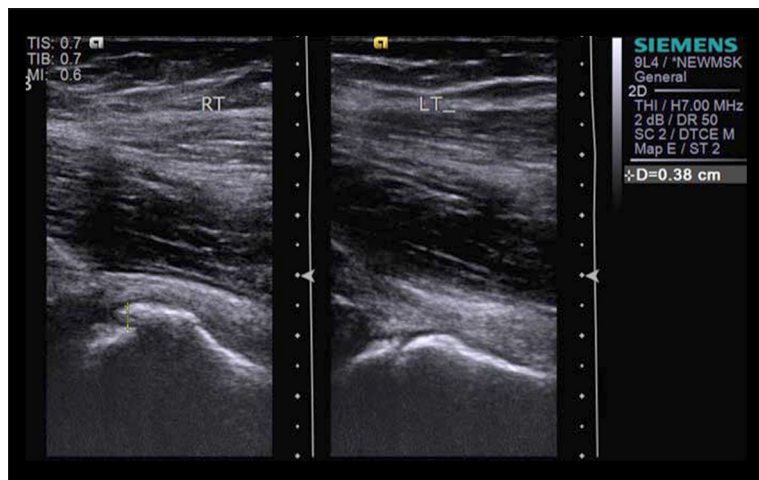


Figure 1. Longitudinal section of the hip joints showing anterior physeal step on the right side and normal appearance on the left side.

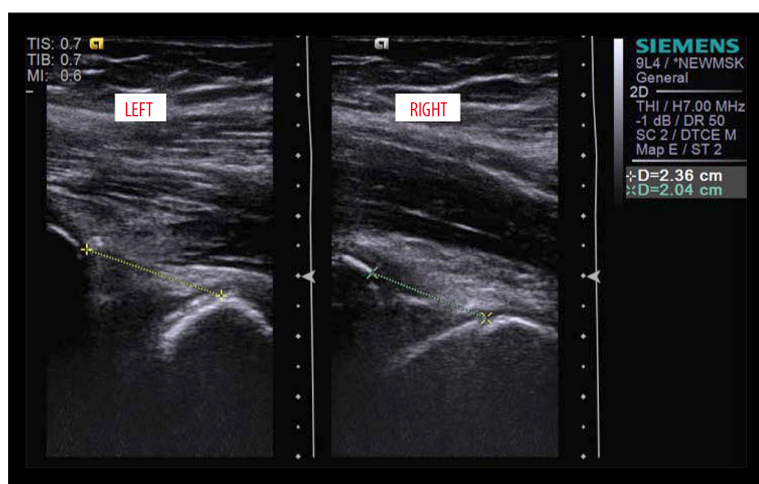


Figure 2. Longitudinal section of the hip joints showing the distance between the anterior rim of the acetabulum and the metaphysis on the affected right side and the normal left side.

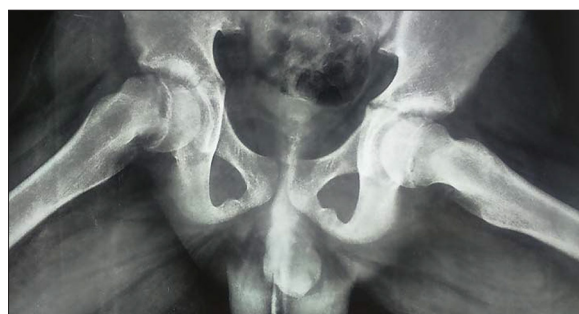

Figure 3. Plain radiograph taken in frog leg position showing a widening of the right proximal physis below the right femoral head with a medial and posterior slip of the right femoral head.

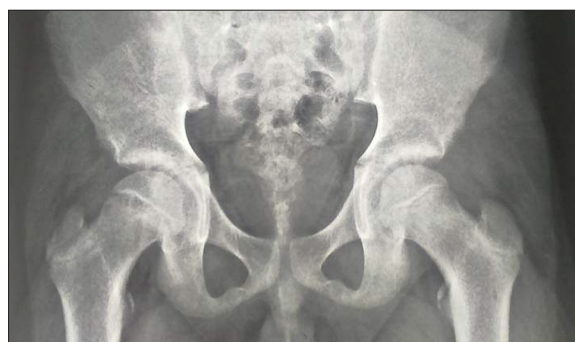

Figure 4. Frontal radiograph of the pelvis taken six months before showing a widening of the proximal right femoral physis.

significant past medical history. Routine laboratory investigations were normal. The patient was referred to the Department of Radio-diagnosis for ultrasound. Ultrasound of both hips was performed with a high frequency transducer (5–9 MHz). A posterior displacement of the femoral head epiphysis with a physeal step was seen on the longitudinal section obtained over the right hip joint region. The anterior physeal step (APS) measured ~3.8 mm on the right side (Figure 1). There was no anterior physeal step on the left side. The distance between the anterior rim of the acetabulum and the metaphysis measured ~20.4 mm on the

affected right side and ~23.6 mm on the left side (Figure 2). There was no hip joint effusion on either side. It prompted us to consider the diagnosis of chronic SCFE on the right side. A plain radiograph taken in frog leg position, following ultrasound, showed a widening of the right proximal physis below the right femoral head with a medial and posterior slip of the right femoral head (Figure 3). On further enquiry, the patient showed a frontal radiograph of the pelvis taken six months before. It showed a widening of the proximal right femoral physis (Figure 4). The patient was admitted for a pinning procedure.

Discussion

Slipped capital femoral epiphysis (SCFE) is one of the most important pediatric and adolescent hip disorders. SCFE represents type I Salter and Harris growth plate injury of the proximal femoral growth plate. It usually occurs due to trauma with or without associated metabolic or endocrine disturbances such as renal osteodystrophy and hypothyroidism [1]. It usually occurs in obese and taller individuals during periods of pubertal growth spurt [1]. SCFE has a male preponderance and is bilateral in about 25% [1,2]. Patients usually present with groin pain with or without associated thigh or knee pain. Most patients will be able to bear weight and will present with a limp, as was seen in our patient. Diagnosing slipped capital femoral epiphysis at an early stage can prevent possible complications such as osteoarthritis, chondrolysis, osteonecrosis and avascular necrosis [1,2].

Radiography is the initial modality used for the evaluation of suspected SCFE, although ultrasound, computed tomography (CT) and magnetic resonance imaging have also been used to evaluate SCFE [3]. Frontal and "frog-leg" lateral radiographs are the most important imaging studies for the diagnosis, and should include both hips, because of the high incidence of bilateral slip [4]. The earliest radiographic finding on the frontal view is a widening and irregularity of the femoral capital physis. The Klein's line, drawn on the AP view along the superior aspect of the femoral neck, does not intersect the femoral head in SCFE [4,5]. The 'metaphyseal blanch' sign may also be seen [2]. Subtle slipping is more obvious on the "frog-leg" lateral view. The pre-slip stage is radiographically occult and other modalities are necessary to identify it [2,4,5].

Ultrasonography has been used for both diagnosing and staging SCFE [6,7]. Ultrasonography findings in slipped capital femoral epiphysis include a posterior displacement of the epiphysis with a physeal step, reduced distance between the anterior rim of the acetabulum and the metaphysis, joint effusion and remodeling of the metaphysis. Severity of SCFE may be graded based on the anterior physeal slip (APS) measurement (Grade I – APS <7 mm; Grade II – APS 7–11 mm; Grade III– APS >11 mm) [6].

CT and MRI have been used to assess SCFE, with MRI appearing more sensitive in diagnosing the pre-slip stage as well as established cases [8]. MRI findings include a diffuse physeal widening, T2 hyperintense marrow edema along the physis and slip of the physis. Retroversion at the femoral capital epiphysis-metaphysis junction is better appreciated on axial and sagittal MRI images [8,9].

Ultrasonography can detect minimal slips with a better sensitivity than radiography with avoidance of radiation exposure [6,7]. Although MRI appears to be the most sensitive modality for identifying slips early [8], ultrasound may be used as a cost-effective and radiation-free alternative before proceeding with further evaluation of suspected SCFE, especially considering the demographics of the affected population.

Conclusions

Ultrasonography can detect minimal slips with a better sensitivity than radiography with avoidance of radiation exposure. Although MRI appears to be the most sensitive modality for identifying slips early, ultrasound may be used as a cost-effective and radiation-free alternative before proceeding with further evaluation of suspected SCFE, especially considering the demographics of the affected population.

References:

- Herring W: Musculoskeletal. In: Learning radiology: Recognizing the basics. (3rd ed.), Elsevier, 2007; 310–13
- Boles CA, el-Khoury GY: Slipped capital femoral epiphysis. *Radiographics*, 1997; 17(4): 809–23
- Gupta AK, Chowdhury V, Khandelwal N, Bhalla AS: Imaging of paediatric hip. In: Diagnostic radiology: Paediatric imaging. (3rd ed.), 2011; 374–376
- Causey AL, Smith ER, Donaldson JJ et al: Missed slipped capital femoral epiphysis: Illustrative cases and a review. *J Emerg Med*, 1995; 13: 175–89
- Frick SL: Evaluation of the child who has hip pain. *Orthop Clin North Am*, 2006; 37: 133–40
- Kallio PE, Lequesne GW, Paterson DC et al: Ultrasonography in slipped capital femoral epiphysis. Diagnosis and assessment of severity. *J Bone Joint Surg Br*, 1991; 73(6): 884–89
- Terjesen T: Ultrasonography for diagnosis of slipped capital femoral epiphysis. Comparison with radiography in 9 cases. *Acta Orthop Scand*, 1992; 63(6): 653–57
- Umans H, Liebling MS, Moy L et al: Slipped capital femoral epiphysis: A physeal lesion diagnosed by MRI, with radiographic and CT correlation. *Skeletal Radiol*, 1998; 27: 139–44
- Dwek J: The hip: MR imaging of uniquely pediatric disorders. *Magn Reson Imaging Clin N Am*, 2009; 17(3): 509–20