



Contents lists available at ScienceDirect

International Journal of Surgery Case Reports

journal homepage: www.casereports.com

Penile incarceration—A tight affair

Faraj O. Alkizim^{a,b}, Daniel Kanyata^{a,*}, Joseph Githaiga^a, Joseph Oliech^a^a Department of Surgery, University of Nairobi, P.O. Box 30197, Nairobi 00100, Kenya^b Department of Physiology, Jomo Kenyatta University of Agriculture and Technology, P. O. Box 62000, Nairobi 00200, Kenya

ARTICLE INFO

Article history:

Received 11 September 2015

Accepted 11 October 2015

Available online 20 October 2015

Keywords:

Penile

Incarceration

Metallic

Ring

ABSTRACT

A patient presents with penile ring incarceration after using it for penile enlargement and prolonging tumescence. We present a case study of removal of the penile ring under local anaesthesia in a setting where cutting tools were inadequate.

© 2015 The Authors. Published by Elsevier Ltd. on behalf of IJS Publishing Group Ltd. This is an open access article under the CC BY-NC-ND license (<http://creativecommons.org/licenses/by-nc-nd/4.0/>).

1. Introduction

The male penis is a sock-like organ found in the perineum. Akin to a wind sock, when blood enters the penis, it fills up and becomes erect/tumescence.

Tumescence is a delicate control of increased arteriolar blood flow, increased trapping of blood in the cavernosal sinusoids and decreased venous return.

When erect, the penis is an organ with two pressure zones, a high pressure zone, encircled by the tunica albuginea, and a low pressure zone outside it.

The high pressure zone is served by the deep/cavernosal and bulbourethral arteries and serves the tumescent function. The low pressure zone is served by the dorsal artery and is mainly nutritive to the anatomic entities that make up the penis [1].

Venous drainage of both the high pressure and low pressure zones is through the dorsal vein found in the low pressure zone.

2. Case

A twenty-six year old male patient presented to the casualty department of Kenyatta National Hospital, a tertiary hospital in Kenya, from a peripheral facility.

He complained of inability to remove a penile ring, penile pain and inability to pass urine.

The penile ring had been inserted the previous evening at 7:00 pm, 12 h before presentation. It had come as part of a penile

enhancement kit that the patient had purchased. The kit had instructions of placing the ring around the penile base for 3 h every 2 weeks. He had been successful in removing it during previous sessions. He also would use the ring to enhance his erections during coitus.

A 12 h delay to our facility had led to gradual enlargement of the penis with darkening of the glans. He was also unable to urinate and had developed abdominal pain.

The lower abdominal pain was uncomfortable requiring the patient to sit quietly and minimise movements to relieve it.

On physical examination, we found a young man seated on one of the casualty chairs, in some distress and requiring prompting to give a history.

Abdominal examination revealed a 14 week suprapubic mass that we could not get under and was tender on palpation. It was dull on percussion and fluctuant.

The perineal exam revealed a silver metallic ring, about 0.5 cm firmly embedded around the base of the penis. The penile shaft distal to the ring was swollen and the glans penis had darkened. Visible blistering was noted on his glans penis. His scrotum and testes were however normal on inspection and palpation.

Other systems and baseline investigations were normal (Fig. 1).

An attempt to remove or cut the ring in minor theatre was unsuccessful as the ring was too thick for the available cutters.

In theatre a ring block of local anaesthetic was infiltrated at the penile base. The penis and scrotum were prepped with hibitane and draped aseptically.

A sharp prick with no. 15 blade was made on the glans penis. About 100 mls of clotted, dark venous blood was milked out. No fistula was developed between glans penis and the corpora cavernosa as described by winter for priapism [2].

* Corresponding author.

E-mail addresses: faralkizim@hotmail.com (F.O. Alkizim), danielkanyata@gmail.com (D. Kanyata), jackiegithaiga@yahoo.com (J. Githaiga), oliech@uonbi.ac.ke (J. Oliech).

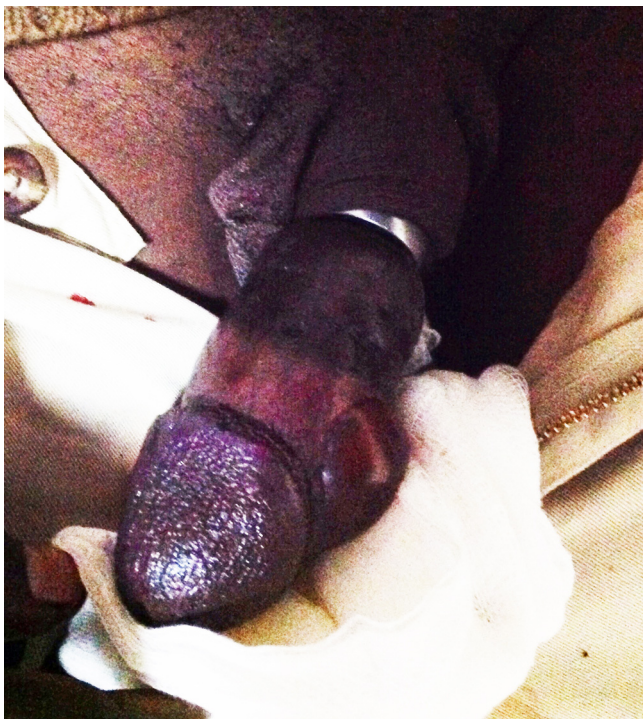

Fig. 1. Penile ring constricting the proximal penile shaft with oedema of the distal shaft.

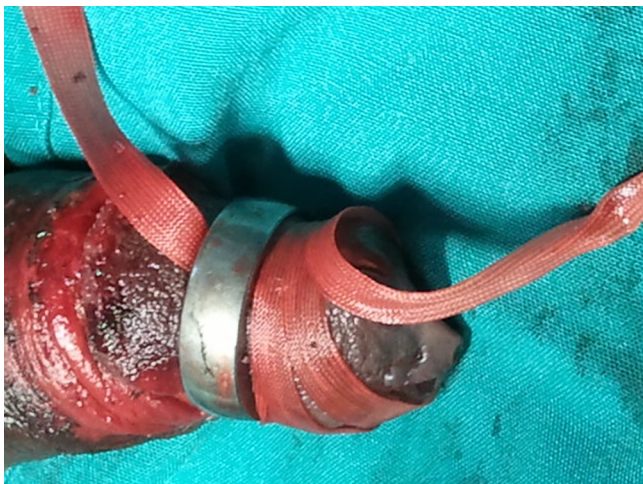


Fig. 2. Penile ring slipped progressively towards the glans penis by pulling the proximal end of the nylon tape.

This enabled a decrease in the penile circumference and nylon tape was slipped underneath the ring. The distal end of the tape was then wrapped around the penile shaft tightly.

The proximal end was then pulled circumferentially and the ring slipped progressively towards the glans penis (Fig. 2).

After an hour of repeatedly slipping the nylon tape under the ring, wrapping the distal end tightly around the penis and pulling the proximal end of the nylon tape in a circumferential manner, we were able to slip the ring off the glans.

The wound on the glans initially bled dark blood which turned to red oxygenated blood. The patient was catheterised and the wound on the glans dressed with a compression dressing.

Patient was released to the ward later complaining of mild hypoesthesia of the glans and lack of morning erections. No areas of

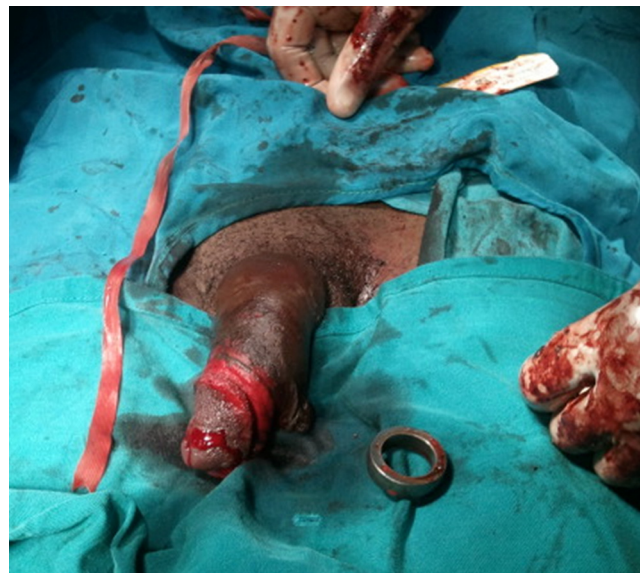

Fig. 3. Post op photo of the penile ring alongside a healthy looking penis.

necrosis were noted apart from some minor bruising on the penile shaft (Fig. 3).

3. Discussion

Tumescence is a function of increased blood flow to the penile erectile tissue and reduced venous drainage producing a physiologic congestion of the sinusoids of the erectile tissue.

The erectile tissue during tumescence is an area of high pressure. The pressure in the erectile tissue is served by the physiological blood pressure. In full erection stage the pressure in the corpus cavernosus is around 100 mmHg. Contraction of the ischiocavernosus and bulbospongiosus muscles during rigid erection stage elevates cavernosal pressures to suprasystolic levels [3].

Penile rings are used to prolong erections by reducing the venous blood flow. Thus they act as an incomplete tourniquet allowing arterial blood to flow distal to the penile ring while reducing venous return, thus causing congestion and numbness of the glans.

In our case the patient had initially used the ring as part of a penile enlargement kit before using it to enhance his sexual performance. This is the first documented case of such penile rings being used to enlarge the penis.

The patient had been instructed to insert the penile ring then stimulate an erection for duration of three hours every two weeks. This regime would increase the length and girth of his penis.

Most penile enlargement techniques attempt to enlarge the penis by enlargement of the tunica albuginea via stretching it using free weights attached to the penis or by splitting and grafting the tunica albuginea [4]. In our case, the patient, presumably, attempted to stretch the tunica albuginea via forced congestion of the corpus cavernosus and corpus spongiosum, using the ring as an incomplete tourniquet. This congestion would overcome the inherent elastic modulus of tunica albuginea and stretch it making the penis larger.

However, most of the apparent increase in size is because of oedema of the superficial tissues. This is because, cavernosal pressures are resisted by the tunica albuginea which requires up to 1500 mmHg to cause herniation [5]. These pressures are much higher than what would be considered physiological. However, this pressure can be exceeded in during sexual intercourse and penile manipulation causing rupture [6].

During tumescence the nutritive function is carried out by the dorsal artery, which runs in a low pressure (normal pressure) zone outside the tunica albuginea [1]. Penile rings turn this zone into a high pressure zone by causing venous congestion, thus reducing arterial flow and disrupting the nutritive function and if prolonged cause ischaemia of the penis. The oedema also makes it more likely for the penile ring to incarcerate. In our patient the penile ring had incarcerated due to oedema of the superficial tissues. It was prolonged and caused penile pain and blistering. Penile incarceration therefore is a urological emergency that requires prompt decompression to restore perfusion and prevent ischaemia [7].

Clinically Bhat et al. classified the penile incarceration injuries into five grades [8]:

- I. Distal oedema only.
- II. Distal oedema, skin and urethral trauma, corpus spongiosum compression, decreased penile sensation.
- III. Skin and urethral trauma, no distal sensation.
- IV. Separation of corpus spongiosum, urethral fistula, corpus cavernosum compression, no distal sensation.
- V. Gangrene, necrosis, or distal penile amputation.

Prognostically Silberstein graded the injuries into low grade and high grade. Low grade injuries did not require operative intervention after the penile ring is extricated. High grade injuries required operative intervention for the complications [9].

As per the grading above, our patient suffered a Bhatt grade II incarceration or a low grade Silberstein injury.

Most operators remove the incarcerated ring by cutting it. In some situations the ring might be too thick for the bolt cutters available.

Some operators have used multiple puncture wounds and aspiration techniques with manual compression to remove the ring whole.

Surgical techniques include removing the skin up to the tunica albuginea and removing the ring whole and then repairing the penis using split thickness skin graft [10].

Our technique is a variation of string methods, however all case reports were done under general anaesthesia. This is the first instance showing that local anaesthesia with a ring block is a viable alternative.

On the whole the string method under local anaesthesia described above is less traumatic with less risk for complications.

Conflict of interest

No conflict of interest.

Funding

No sponsors.

Ethical approval

Case report, consent given by patient.

Consent

Consent given.

Author contribution

Daniel Kanyata, Farah Alkhozim—concept of paper, writing.
Joseph Githaiga, Joseph Oliech—review, scientific input and authority to publish.

Guarantor

Daniel Kanyata, Farah Alkhozim, Joseph Githaiga, Joseph Oliech.

References

- [1] J.E. Skandalakis, L.G. Colborn, T.A. Weidman, R.S. Forster, Male genital system, in: J.E. Skandalakis (Ed.), *Skandalakis' Surgical Anatomy*, Paschalidis Medical Publications, Ltd., Athens, 2004.
- [2] C. Winter, Priapism cured by creation of fistulas between glans penis and corpora cavernosa, *J. Urol.* 119 (February (2)) (1978).
- [3] R.C. Dean, T.F. Lue, Physiology of penile erection and pathophysiology of erectile dysfunction, *Urol. Clin. North Am.* 32 (November (4)) (2005) 379–395.
- [4] E. Austoni, Penile elongation and thickening—a myth? Is there a cosmetic or medical indication? *Andrologia* 31 (July (S1)) (1999) 45–51.
- [5] M. Bitsch, The elasticity and the tensile strength of tunica albuginea of the corpora cavernosa, *J. Urol.* 143 (March (3)) (1990) 642–645.
- [6] G.B. Di Pierro, L. Iannotta, M. Innocenzi, G. Caterina, P. Grande, C. Cristini, et al., Urethral pseudodiverticulum secondary to penile fracture and complete urethra dissection, *Can. Urol. Assoc. J.* 7 (May–June) (2013) E347–E350.
- [7] S. Trivedi, A. Attam, A. Kerketa, N. Daruka, B. Behre, A. Agrawal, et al., Penile incarceration with metallic foreign bodies: management and review of literature, *Curr. Urol.* 7 (August (1)) (2013) 45–50.
- [8] A. Bhat, A. Kumar, S. Mathur, K. Gangwal, Penile strangulation, *Br. J. Urol.* 68 (1991) 618–621.
- [9] J. Silberstein, J. Grabowski, C. Lakin, I. Goldstein, Penile constriction devices: case report, review of the literature, and recommendations for extrication, *J. Sex. Med.* 5 (2008) 1747–1757.
- [10] A.O. Olajide, A.K. Eziyi, F.O. Olajide, B.K. Beyioku, Novel surgical extrication of penile constricting metal ring, *IJCRI* 9 (April) (2013) 511–514.

Open Access

This article is published Open Access at sciendo.com. It is distributed under the [IJSCR Supplemental terms and conditions](#), which permits unrestricted non commercial use, distribution, and reproduction in any medium, provided the original authors and source are credited.