

[CASE REPORT]

Tracheobronchial Obstruction Due to Blood Clots in Acute Pulmonary Embolism with Cardiac Arrest Managed with Extracorporeal Membrane Oxygenation

Kazunori Watanabe, Satoshi Oka, Takahiko Kai, Katsuomi Hoshino, Jun Nakamura, Makoto Abe and Akinori Watanabe

Abstract:

A 66-year-old Japanese woman developed pulseless electrical activity following an acute pulmonary embolism and was treated with thrombolytic therapy. She remained hemodynamically unstable and therefore underwent extracorporeal membrane oxygenation (ECMO). While receiving treatment with ECMO, blood clots induced by endobronchial hemorrhage caused tracheobronchial airway obstruction, leading to ventilatory defect. Furthermore, her cardiac function improved, resulting in cerebral hypoxemia progression. Therefore, the blood clots were removed with a Fogarty balloon catheter and endobronchial urokinase administration, resulting in improvement in her respiratory condition. Finally, ECMO was decannulated, and the patient was discharged from our hospital without difficulties in her activities of daily living.

Key words: acute pulmonary embolism, extracorporeal membrane oxygenation, tracheobronchial obstruction

(Intern Med 60: 2811-2817, 2021)

(DOI: 10.2169/internalmedicine.6856-20)

Introduction

Acute pulmonary embolism (PE) with cardiac arrest, obstructive shock, or persistent hypotension remains a significant cause of cardiovascular mortality, with in-hospital mortality rates ranging from 15% to 65% (1-4). Furthermore, definitive interventions, such as systemic thrombolysis, surgical embolectomy, or catheter embolectomy, do not consistently improve patient hemodynamics, leading to cardiac arrest in some cases.

In hemodynamically unstable patients, extracorporeal membrane oxygenation (ECMO) is one of the most effective ways of improving the hemodynamic status and allows for definitive interventions. Previous reports have found that ECMO yielded positive outcomes in acute PE with cardiac arrest; however, severe bleeding is a frequently reported complication following such treatment (5, 6). Furthermore, acute PE, thrombolytic therapy, and cardiopulmonary resuscitation have all been identified as risk factors for major bleeding; therefore, the use of anticoagulation therapy is

controversial (3-9).

We herein report a rare case of acute PE with cardiac arrest treated with ECMO in which tracheobronchial obstruction occurred due to a blood clot.

Case Report

A 66-year-old Japanese woman with no history of disease was transported to the emergency department because of a complaint of sudden dyspnea. Upon a physical examination, the following information was obtained: Glasgow coma scale score (3/15), blood pressure (97/62 mmHg), heart rate (118 beats/min), respiratory rate (30 breaths/min), and oxygen saturation in room air (80%). Upon arrival at the emergency department, her respiratory condition deteriorated; consequently, she developed cardiac arrest with pulseless electrical activity (PEA). After one cycle of cardiopulmonary resuscitation, we temporarily achieved return of spontaneous circulation. Although coarse crackles were detected in the left lung, there was no heart murmur or lower leg edema. A blood examination revealed the following findings: white

Department of Cardiology, Fujieda Municipal General Hospital, Japan

Received: December 2, 2020; Accepted: January 27, 2021; Advance Publication by J-STAGE: March 15, 2021

Correspondence to Dr. Kazunori Watanabe, wiz.doc.kznr.ij@gmail.com

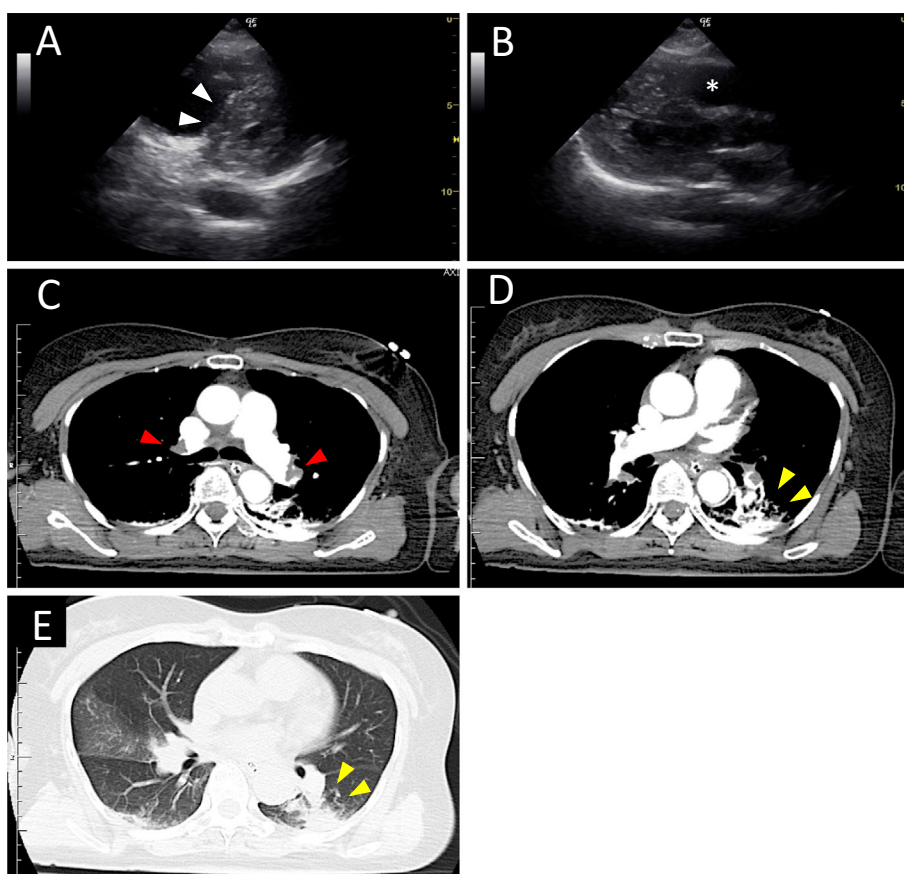


Figure 1. Echocardiography and contrast-enhanced CT images obtained at admission to the hospital (A, B). The right ventricle was significantly dilated (asterisk), resulting in flattening of the interventricular septum (arrows). (C, D, E) Emergency CT showed a thrombus in the bilateral pulmonary artery (red arrows) as well as parenchymal infarction in the left lower lobe (yellow arrows). CT: computed tomography

blood cell count, 14,800/ μ L; hemoglobin level, 13.3 g/dL; platelet count, 189,000/ μ L; troponin-I level, 0.23 ng/mL; creatine kinase level, 48 U/L; brain natriuretic peptide level, 490 pg/mL; and D-dimer level, 10.6 μ L/mL. Electrocardiography showed sinus tachycardia with right bundle branch block and T-negative waves in leads III and aVF. Transthoracic echocardiography revealed a normal left ventricular function, significant dilation of the right ventricle, and a flattened interventricular septum (Fig. 1).

Acute pulmonary embolism was suspected based on these clinical findings; therefore, 5,000 units of unfractionated heparin were administered as initial anticoagulation therapy before contrast-enhanced chest computed tomography (CT). Contrast-enhanced chest CT revealed bilateral pulmonary emboli with parenchymal infarction in the left lower lobe, albeit without deep vein thrombosis (Fig. 1). Thus, the patient was diagnosed with acute pulmonary embolism and concomitant pulmonary infarction.

During contrast-enhanced CT, her blood pressure gradually decreased. Thereafter, the PEA returned. Although she was intubated, managed with mechanical ventilation, and administered 600,000 IU (15,000 IU/kg) of tissue-type plasminogen activator (alteplase) as systemic thrombolytic therapy, her hemodynamics did not improve. Thus, VA-ECMO

was administered immediately, and she was transferred to the intensive-care unit (ICU).

After being transferred to the ICU, she was treated with VA-ECMO and continuously administered unfractionated heparin (10,000-15,000 units/day) to achieve an activated coagulation time of 180-200 seconds and an activated partial thromboplastin time of 40-50 seconds as anticoagulation therapy. However, endobronchial hemorrhage occurred, inducing concomitant thrombogenesis in the tracheobronchial airway on the second hospitalization day. We removed multiple blood clots using flexible bronchoscopy, endobronchial lavage, and suctioning; however, bleeding and respiratory secretions had to be removed from the intubation tube intermittently. Despite the presence of endobronchial hemorrhage, we were unable to interrupt the administration of unfractionated heparin, as the flow rate of the VA-ECMO treatment had to be maintained.

On the third hospitalization day, the tracheobronchial airway became obstructed by blood clots (Fig. 2). A subsequent decrease in tidal volume led to impaired ventilation. Although we suspected ECMO complications, the partial pressure of retransfusion blood oxygen did not decrease (200-300 mmHg). The mean arterial pressure gradually increased from approximately 65 mmHg to 85 mmHg. There-

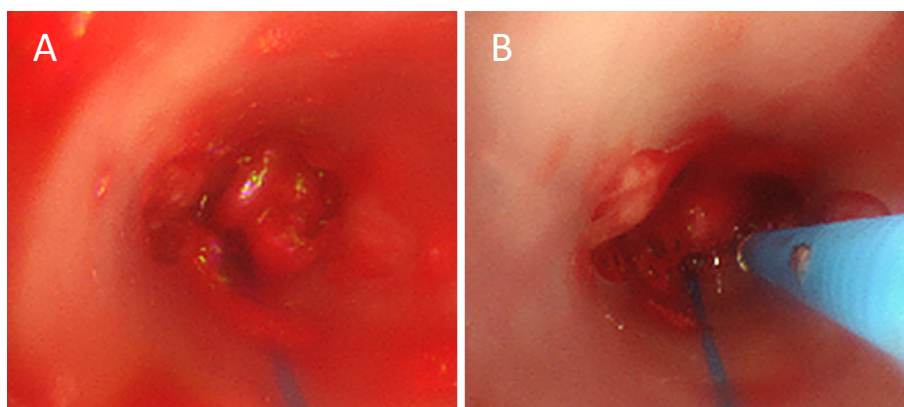


Figure 2. Bronchoscopy findings on the third hospitalization day. (A) The intubation tube was obstructed by a blood clot. (C) Unsuccessful removal of the tracheobronchial blood clot using flexible bronchoscopy, suctioning, and endobronchial forceps.

fore, we considered that improvements in the cardiac function had induced a shift of the “mixing point”, resulting in the progression of cerebral hypoxemia. While the flow rate of ECMO was low (1.5-2.0 L/min), arterial systolic blood pressure did not decrease (>90 mmHg), whereas percutaneous oxygen saturation did decrease. In addition, dilation of the right ventricle was improved, as was the left ventricular function, on transthoracic echocardiography.

Based on these findings, we considered that the cardiac function had sufficiently improved to maintain systemic circulation; however, the pulmonary function was not improved, requiring ECMO support. Therefore, we decided to switch VA-ECMO to VV-ECMO and repeated contrast-enhanced chest CT on the fifth hospitalization day. Chest CT revealed an endobronchial blood clot extending from the trachea to the bilateral main bronchi; however, active endobronchial hemorrhage was not detected (Fig. 3). Therefore, we attempted to remove the blood clots using flexible bronchoscopy, a Fogarty balloon catheter, and endobronchial urokinase administration (Fig. 4).

We successfully opened the tracheobronchial airway (Fig. 5). Upon a pathological examination, neutrophil infiltration was observed in the thrombus, but there were no malignant findings. Her condition was maintained with mechanical ventilation using a high positive end-respiratory pressure (10 cmH₂O) to clear the airway. Frequent aspiration was performed using flexible bronchoscopy without interruption of the intravenous infusion of unfractionated heparin. Although erythrocyte and platelet transfusions were required to prevent the exacerbation of anemia and thrombocytopenia, there was no recurrence of tracheobronchial airway obstruction. VV-ECMO was decannulated on the sixth hospitalization day.

After the VV-ECMO was withdrawn, a new consolidation, an abscess, and porosis were all found in the right lower lobe using chest CT imaging on the eighth hospitalization day (Fig. 6). *Klebsiella pneumoniae* was cultured from her sputum, and she was administered 3 g/day of meropenem in week 1 and 2 g/day of ceftriaxone in weeks 2 and 3. During

treatment with the antibacterial agent, tracheotomy was performed to maintain ventilation. On the 21st hospitalization day, her respiratory condition stabilized, so she was extubated and discharged from the ICU on the 23rd hospitalization day.

Although her higher-order cognitive functions were impaired, she was able to perform activities of daily living, such as oral ingestion, following long-term rehabilitation intervention. Rivaroxaban was administered orally as a replacement for unfractionated heparin. On the 76th hospitalization day, she was transferred to a recovery hospital for rehabilitation treatment. Social reintroduction took place two months after discharge from our hospital.

Discussion

In the present case, tracheobronchial obstruction, a relatively rare complication of acute PE, occurred during treatment with VA-ECMO. Previous reports have noted that the resolution of blood clots was observed within three days by expectoration or regression. Furthermore, any operation to remove the blood clots might induce rebleeding. Hence, observation might be warranted during the management of tracheobronchial obstruction due to blood clots in hemodynamically stable patients (10-12). However, in the present case, cerebral hypoxemia progressed due to tracheobronchial obstruction as the cardiac function improved. Furthermore, ECMO decannulation was deemed too difficult without a patent tracheobronchial airway. Therefore, we attempted to remove the tracheobronchial blood clot with saline lavage and suctioning; however, this was not possible due to firm adhesion between the clot and bronchial wall. Regarding the removal of blood clots in the central airway, Arney et al. reported the effectiveness of using a Fogarty catheter in addition to endobronchial forceps (12). Botnick et al. also demonstrated that endobronchial administration of urokinase was effective in dissolving blood clots secondary to massive bleeding (13). Therefore, we attempted to remove the blood clots again by combining a Fogarty catheter and endobron-

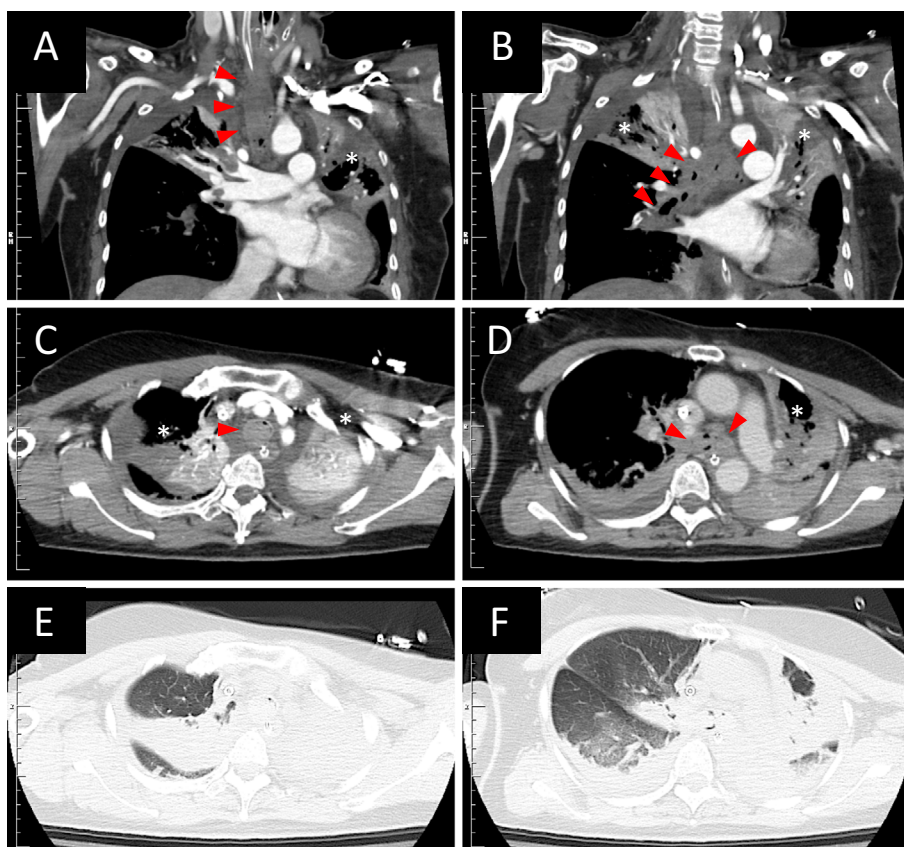


Figure 3. Contrast-enhanced CT images. Coronal (A, B) and axial (C, D, E, F) images of the chest before removal of a blood clot on the fourth hospitalization day. CT imaging revealed a blood clot obstructing the space from the trachea to the bilateral mainstem bronchi (red arrows). Atelectasis was seen in the bilateral upper lobe, but active bleeding was not found (asterisks). CT: computed tomography

chial urokinase administration. Thereafter, the tracheobronchial airway was patent.

To our knowledge, tracheobronchial obstruction complicated by acute PE is exceedingly rare. Previous reports have found that airway obstruction due to the presence of blood clots arises not only from organic pathologies, such as tuberculosis, sarcoidosis, carcinoma, pulmonary infarction, and pulmonary arteriovenous malformation, but also from iatrogenic mucosal damage (10). In this case, pulmonary infarction was detected in the left lower lobe on contrast-enhanced CT. Furthermore, flexible bronchoscopy revealed that more blood clots were discharged from the left bronchus than from the right bronchus. These findings suggested that pulmonary infarction in the left lower lobe induced alveolar hemorrhage, resulting in thrombogenesis. In addition, the pneumonia was thought to be associated with the formation of blood clots in our patient. Keshishyan et al. showed that bacterial infection could result in central airway obstruction, and the immune status of the host is considered to play an important role (14). In our case, *Klebsiella* pneumonia developed in the right lower lobe, and severe neutrophil infiltration into the blood clot was observed during a pathological examination. These findings support the existence of a relationship between the bacterial infection and tracheobron-

chial obstruction.

Whether or not systemic thrombolysis therapy should be performed once VA-ECMO is initiated remains unclear. Current guidelines advocate the use of systemic thrombolysis as a primary intervention for high-risk cases of acute PE (15). However, systemic thrombolysis with anticoagulation has been associated with severe bleeding complications in previous studies as well as in the present report (9). O'Malley et al. reported that 23.4% of acute PE patients on ECMO experienced bleeding and that 12.1% of patients treated with ECMO died from hemorrhagic shock (16). Systemic thrombolysis therapy has significantly reduced the incidence of early mortality in cases of acute PE; however, acute PE requiring ECMO was also found to significantly increase the risk of bleeding. This case of acute PE was difficult to treat due to severe bleeding complications. Systemic thrombolysis therapy may have been eschewed to avoid severe bleeding complications for the following reasons: contrast-enhanced chest CT findings, which suggested alveolar hemorrhage in the infarcted site of the left lower lobe; and a hemodynamically unstable status requiring ECMO on the admission day. These findings were indicative of high bleeding risks in this case, suggesting that systemic thrombolysis therapy may induce severe bleeding complication. It is conceivable that

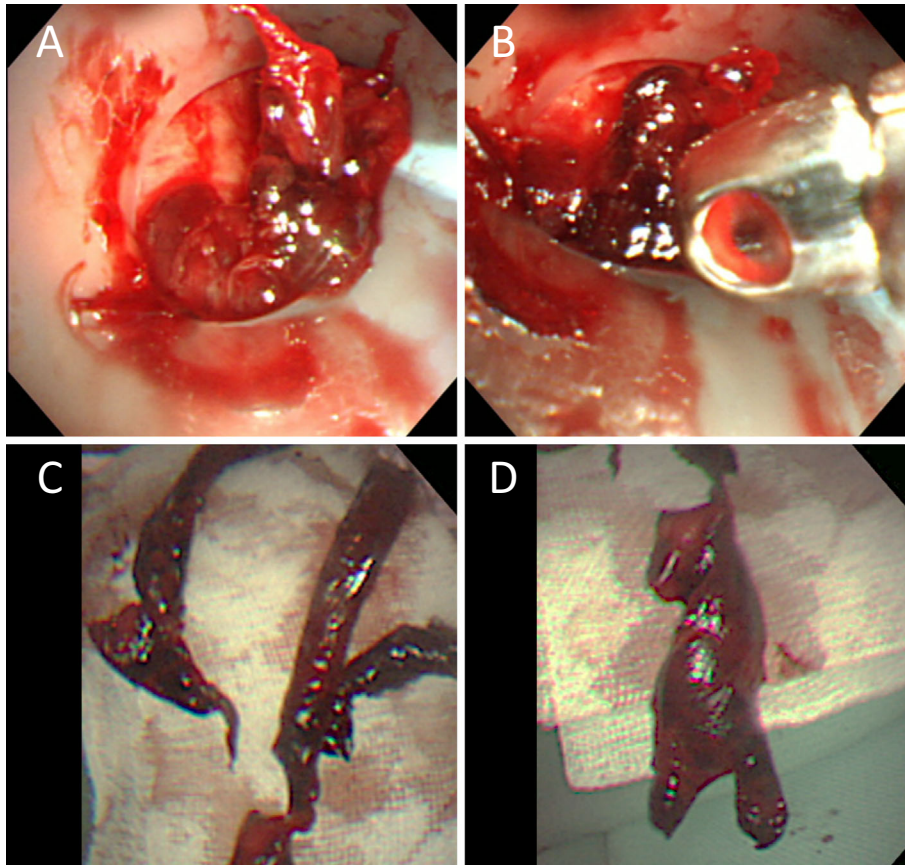


Figure 4. Bronchoscopy findings on the fifth hospitalization day. (A, B) Successful removal of the tracheobronchial blood clot using flexible bronchoscopy, endobronchial forceps, a Fogarty catheter, and urokinase. (C, D) The blood clot was extracted from the tracheobronchial airway.

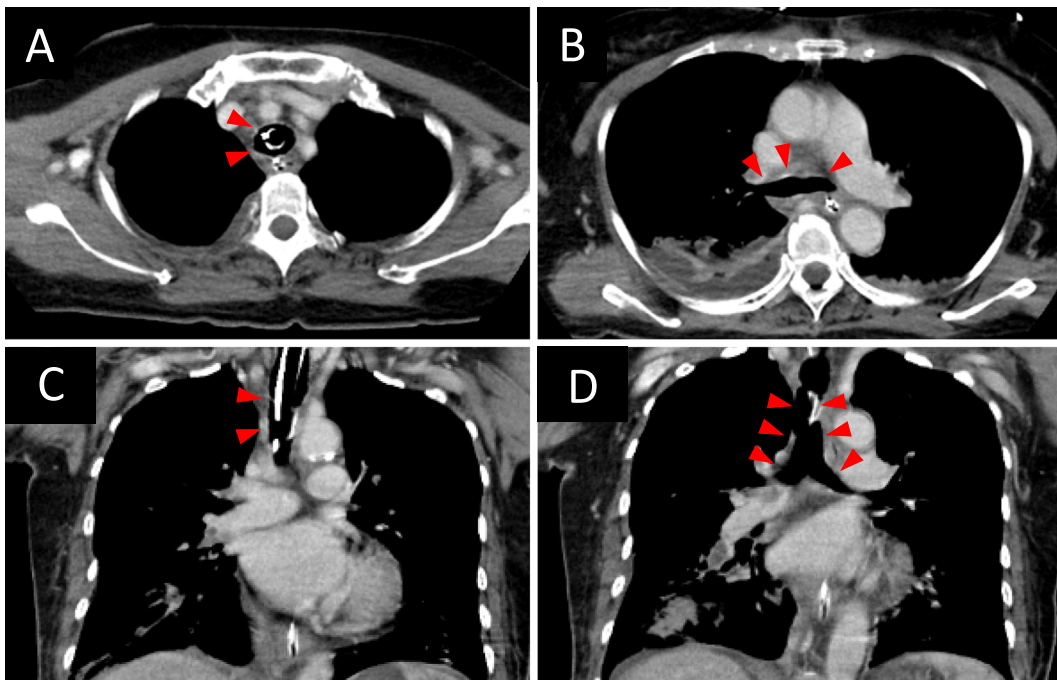


Figure 5. Contrast-enhanced CT images. Axial (A, B) and coronal (C, D) images of the chest after removal of a blood clot. After successful attempts to remove the blood clot, patency was achieved in the trachea and the bilateral mainstem bronchi (red arrows). CT: computed tomography

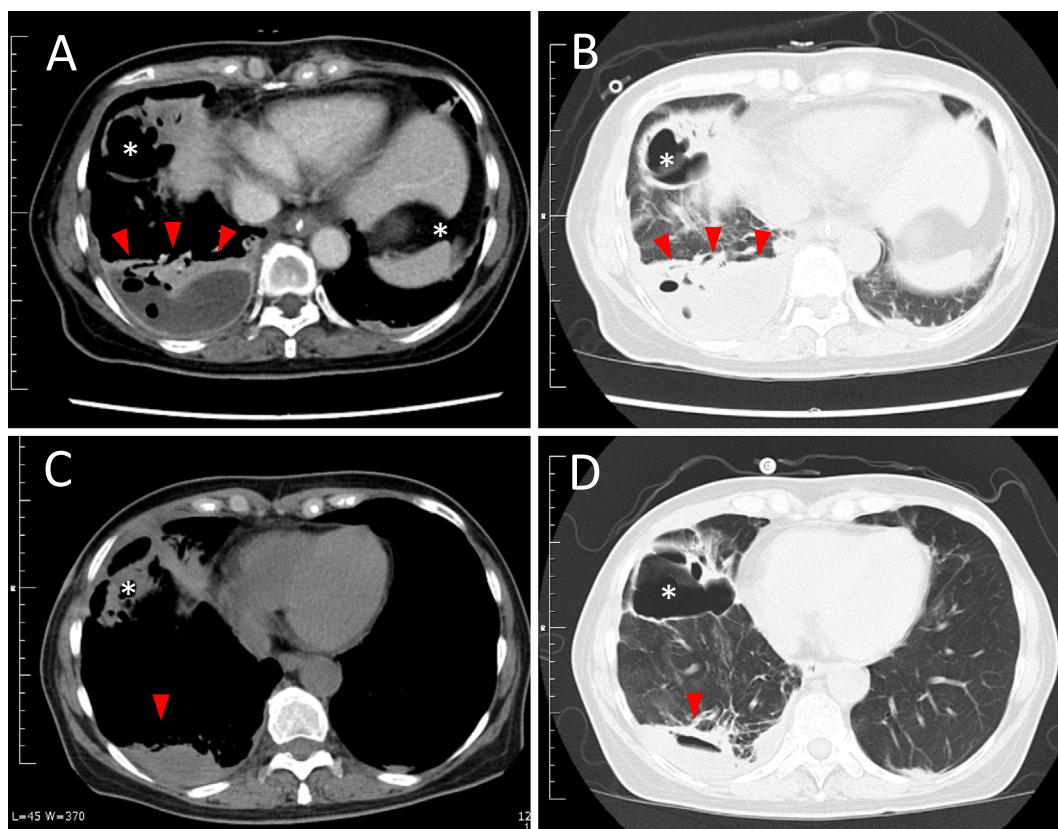


Figure 6. CT images before and after the treatment of *Klebsiella pneumonia*. (A, B) CT images taken on the eighth hospitalization day. A new consolidation, an abscess (red arrows), and porosis (asterisks) were all found in the right lower lobe, suggesting the development of *Klebsiella pneumonia*. (C, D) CT images taken after treatment with meropenem and ceftriaxone on the 39th hospitalization day. CT: computed tomography

acute PE requiring ECMO could be maintained without systemic thrombolysis therapy, a finding confirmed by the present report.

Conclusion

We herein report a patient with an unremarkable medical history who had an acute PE with severe bleeding complications. Tracheobronchial obstruction can be a lethal complication of acute PE; therefore, vigilance is warranted in patients with a high risk of bleeding. This is especially true for patients undergoing ECMO treatment.

The authors state that they have no Conflict of Interest (COI).

References

- Goldnaber SZ, Visani L, De Rosa M. Acute pulmonary embolism: clinical outcomes in the International Cooperative Pulmonary Embolism Registry (ICOPER). *Lancet* **353**: 1386-1389, 1999.
- Agnelli G, Becattini C. Acute pulmonary embolism. *N Engl J Med* **363**: 266-274, 2010.
- Kasper W, Konstantinides S, Geibel A, et al. Management strategies and determinants of outcome in acute major pulmonary embolism: results of a multicenter registry. *J Am Coll Cardiol* **30**: 1165-1171, 1997.
- Kucher N, Rossi E, De Rosa M, Goldhaber SZ. Massive pulmonary embolism. *Circulation* **113**: 577-582, 2006.
- Maggio P, Hemmila M, Haft J, Bartlett R. Extracorporeal life support for massive pulmonary embolism. *J Trauma* **62**: 570-576, 2007.
- Yusuff HO, Zochios V, Vuylsteke A. Extracorporeal membrane oxygenation in acute massive pulmonary embolism: a systematic review. *Perfusion* **30**: 611-616, 2015.
- Cengiz P, Seidel K, Rycus PT, Brogan TV, Roberts SJ. Central nervous system complications during pediatric extracorporeal life support: incidence and risk factors. *Crit Care Med* **33**: 2817-2824, 2005.
- Kasirajan V, Smedira NG, McCarthy JF, Casselman F, Boparai N, McCarthy PM. Risk factors for intracranial hemorrhage in adults on extracorporeal membrane oxygenation. *Eur J Cardiothorac Surg* **15**: 508-514, 1999.
- Marti C, John G, Konstantinides S, et al. Systemic thrombolytic therapy for acute pulmonary embolism: a systematic review and meta-analysis. *Eur Heart J* **36**: 605-614, 2015.
- Allen RP, Siefkin AD. Emergency airway blood clot removal in acute hemorrhagic respiratory failure. *Crit Care Med* **15**: 985-986, 1987.
- Skatrud J, Gilbert R, Auchincloss JH, Rana S. Blood clot cast following hemoptysis and resulting in atelectasis. *Chest* **69**: 131, 1976.
- Arney KL, Judson MA, Sahn SA. Airway obstruction arising from blood clot: three reports and a review of the literature. *Chest* **115**: 293-300, 1999.
- Botnick W, Brown H. Endobronchial urokinase for dissolution of massive clot following transbronchial biopsy. *Chest* **105**: 953-954, 1994.

- 1994.
14. Keshishyan S, DeLorenzo L, Hammoud K, Avagyan A, Assallum H, Harris K. Infections causing central airway obstruction: role of bronchoscopy in diagnosis and management. *J Thorac Dis* **9**: 1707-1724, 2017.
15. Konstantinides SV, Meyer G, Becattini C, et al. 2019 ESC guidelines for the diagnosis and management of acute pulmonary embolism developed in collaboration with the European Respiratory Society (ERS). *Eur Heart J* **41**: 543-603, 2020.
16. O'Malley TJ, Choi JH, Maynes EJ, et al. Outcomes of extracorporeal life support for the treatment of acute massive pulmonary embolism: a systematic review. *Resuscitation* **146**: 132-137, 2020.

The Internal Medicine is an Open Access journal distributed under the Creative Commons Attribution-NonCommercial-NoDerivatives 4.0 International License. To view the details of this license, please visit (<https://creativecommons.org/licenses/by-nc-nd/4.0/>).

© 2021 The Japanese Society of Internal Medicine
Intern Med 60: 2811-2817, 2021