

Discriminating Potential of Extraintestinal Systemic Manifestations and Colonoscopic Features in Chinese Patients with Intestinal Behçet's Disease and Crohn's Disease

Ji Li¹, Pan Li², Jing Bai³, Hong Lyu¹, Yue Li¹, Hong Yang¹, Bo Shen⁴, Jia-Ming Qian¹

¹Department of Gastroenterology, Peking Union Medical College Hospital, Beijing 100730, China

²Department of Gastroenterology, First Affiliated Hospital of Chongqing Medical University, Chongqing 400016, China

³Department of Intensive Care, Beijing Friendship Hospital, Capital Medical University, Beijing 100050, China

⁴Department of Gastroenterology-A31, The Cleveland Clinic Foundation, 9500 Euclid Ave, Cleveland OH 44195, USA

Ji Li and Pan Li contributed equally to this work.

Abstract

Background: The distinction between intestinal Behçet's disease (BD) and Crohn's disease (CD) is always challenging due to many overlapping clinical features. We conducted a retrospective study to reveal valuable strategies for the differential diagnosis between intestinal BD and CD in Chinese patients based on their clinical and colonoscopic features.

Methods: Thirty-five intestinal BD patients and 106 CD patients hospitalized from January 1983 to January 2010, who had ulcerative lesions in the terminal ileum or colon under colonoscopy and no history of gastrointestinal operation except appendectomy before admission, were enrolled. Univariate and multivariate logistic regression analyses were conducted to find discriminating predictors among demographic data, clinical manifestations, and colonoscopic findings.

Results: Based on univariate analysis, massive gastrointestinal hemorrhage, fever, and extraintestinal systemic manifestations were more common in intestinal BD patients ($P = 0.022$, 0.048 and 0.001 , respectively), while diarrhea, intestinal obstruction, and perianal lesions were more common in CD patients ($P = 0.002$, 0.010 , and 0.027 respectively). Based on colonoscopy, focal involvement, ileocecal valve deformity, solitary ulcers, large ulcers (ulcer size > 2 cm), and circumferential ulcers were more common in intestinal BD patients ($P = 0.003$, 0.003 , 0.014 , 0.013 , and 0.003 , respectively), while segmental involvement, longitudinal ulcers, a cobblestone or nodular appearance, and pseudo-polyps were more common in CD patients ($P = 0.003$, 0.008 , 0.023 , and 0.002 , respectively). Based on multivariate logistic regression analysis, diarrhea, extraintestinal manifestations, ulcer distribution, size, and type, and pseudo-polyps were independent discriminating predictors between the two groups ($P = 0.048$, 0.008 , 0.006 , 0.021 , 0.002 , and 0.041 , respectively). The discriminating algorithm composed of the above independent predictors had the highest area under the curve of 0.987 for distinguishing between the two diseases.

Conclusions: Extraintestinal systemic manifestations and the characteristic colonoscopic features, such as ulcer distribution, size and type, helped to distinguish intestinal BD from CD.

Key words: Behçet's Disease; Colonoscopy; Crohn's Disease; Differential Diagnosis

INTRODUCTION

Behçet's disease (BD) is a chronic, multisystemic, relapsing inflammatory disorder, characterized by recurrent oral ulcers, genital ulcers, uveitis, and skin lesions. It also attacks other systems involving the musculoskeletal system, blood vessels, nervous system, and gastrointestinal tract. BD is predominantly found in eastern Mediterranean countries and the eastern rim of Asia, including China.^[1,2] When BD

patients have predominantly gastrointestinal symptoms and show gastrointestinal lesions with certain objective measures, the disease is defined as intestinal BD.^[3] The prevalence of intestinal BD varies from 0% to 60% of all BD patients with geographic and ethnic differences. The ileocecal region is the most commonly involved region, and abdominal pain, diarrhea, and gastrointestinal bleeding are common symptoms.^[4-6]

Crohn's disease (CD) is a relapsing and transmural inflammatory disease which can affect the entire gastrointestinal tract. Typical presentations include the presence of longitudinal ulcers with a cobblestone appearance,

Access this article online

Quick Response Code:



Website:
www.cmj.org

DOI:
10.4103/0366-6999.149213

Address for correspondence: Prof. Jia-Ming Qian,
Department of Gastroenterology, Peking Union Medical College Hospital,
Beijing 100730, China
E-Mail: qianjiaming1957@126.com

skip lesions, and the development of complications such as strictures and fistulas. CD also has extraintestinal manifestations, such as oral ulcers, arthralgia, erythema nodosum, and autoimmune hepatic diseases.^[7,8]

Intestinal BD often mimics CD. Both diseases commonly have a young age of onset, nonspecific gastrointestinal symptoms, similar extraintestinal manifestations, and chronic, waxing, and waning course.^[9] Distinguishing between them is clinically challenging. There are only a few comparative studies regarding the differential diagnosis, which were conducted in Korean patients,^[10,11] and no comparative study has been done in Chinese patients. We carried out this retrospective study to elucidate the clinical and colonoscopic features in Chinese patients with intestinal BD or CD, and to identify valuable strategies for the differential diagnosis.

METHODS

Patients

From January 1983 to January 2010, 50 intestinal BD patients and 219 CD patients were hospitalized in Peking Union Medical College Hospital, a tertiary academic hospital, in Beijing, China. Among them, patients (35 intestinal BD patients and 106 CD patients) who had ulcerative lesions in the terminal ileum or colon under colonoscopy and had no history of gastrointestinal operation except appendectomy were enrolled in this study. All patients were Chinese Han and received at least 1-year follow-up. Patients diagnosed with ulcerative colitis, celiac disease, intestinal tuberculosis, malignancy, or other recognized causes of intestinal inflammation were excluded. The study was approved by the Ethical Committee of Peking Union Medical College Hospital.

Diagnostic criteria

Behçet's disease was diagnosed based on the criteria from the BD Research committee of Japan in 1987.^[10] Briefly, the criteria include four major features (recurrent oral aphthous ulcers, eye lesions, genital lesions, and skin lesions including erythema nodosum, subcutaneous thrombophlebitis, acne-like lesions, and cutaneous hypersensitivity) and five minor features (arthritis, gastrointestinal lesions characterized by ileocecal ulcers, epididymitis, vascular lesions, and lesions of the central nervous system). Diagnosis of complete type BD requires all four major features. The incomplete type needs three major features, or two major plus two minor features, or typical ocular symptoms plus one major or two minor features. The suspected type needs two major features, or one major plus two minor features. When patients with BD had predominantly gastrointestinal symptoms with endoscopic, histologic, and/or radiographic evidence of gastrointestinal lesions, they were diagnosed as intestinal BD. In this study, 3 (8.6%), 26 (74.3%), and 6 (17.1%) patients were diagnosed as complete, incomplete, and suspected BD, respectively.

Diagnosis of CD was based comprehensively on both morphological and pathological features. Morphological features include: (1) Discontinuous and asymmetrical

mucosal involvement; (2) deep mucosal longitudinal ulcers; (3) transmural inflammation; (4) a rigid intestinal wall; and (5) presence of an enterocutaneous or entero-enteric fistula and/or chronic perianal disease. Pathological features include: (1) Normal mucus content in the goblet cells of the inflamed region; (2) lymphocyte aggregation in the mucosa and submucosa; (3) noncaseating granulomas; (4) longitudinal ulcers; and (5) transmural inflammation. For definite diagnosis of CD, the following criteria were used: The presence of at least three different histologic features; or the presence of noncaseating granulomas on histology with at least one other feature; or the resolution of symptoms and morphologic features after 3–12 months' treatment.^[11]

Clinical and colonoscopic features

Data were collected including demographics (gender, age and disease duration), clinical manifestations (disease distribution, gastrointestinal symptoms, extraintestinal manifestations, and gastrointestinal complications), and colonoscopic findings. The disease distribution was determined by endoscopic and radiologic examinations. Gastrointestinal complications included perforation, fistulae, intestinal obstruction and massive gastrointestinal hemorrhage which were associated with hemodynamic instability, acute anemia, and/or the need for blood transfusion. Colonoscopic features included the ulcer distribution (focal involvement, segmental involvement), the number of ulcers in a local segment (1, or ≥ 2), ulcer type (longitudinal ulcer, circumferential ulcer, aphthous ulcer or irregular ulcer), cobblestone appearance, pseudo-polyps, and stricture. Focal involvement was defined as one local area with ulcerative lesions or two adjacent areas involved by continuous ulcerative lesions. Segmental involvement meant more than two areas with discontinuous ulcerative lesions. A circumferential ulcer was defined as a round or transverse, deep and well-demarcated ulcer. An aphthous ulcer was defined as a small (<1 cm), punched out, raised or a flat lesion with a white center [Figure 1a-c]. The

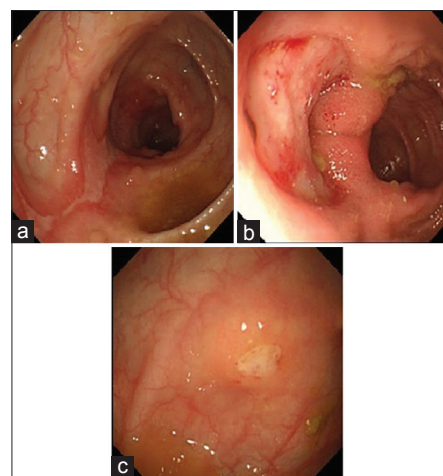


Figure 1: (a) A longitudinal ulcer in a patient with Crohn's disease (CD). (b) A circumferential ulcer in a patient with intestinal Behçet's disease. (c) An aphthous ulcer in a patient with CD.

cobblestone appearance was defined as a mucosal pattern with raised nodules, resembling the paving of the “Roman” road. Pseudo-polyps are defined as polypoid lesions which are usually small and isolated or multiple and scattered, though they can sometimes be giant in size. All images of colonoscopic examinations were reviewed by an expert endoscopist who was blinded from other information. Histologic features of biopsy specimens, which were paraffin-embedded and stained with hematoxylin and eosin, were evaluated for the presence of epithelioid granulomas and the appearance of vasculitis.

Statistical analysis

The continuous variables were presented as mean ± standard deviation (SD). Differences in quantitative data between the two groups were examined statistically through univariate analysis using an independent *t*-test and chi-squared test for continuous and categorical variables, respectively. *P* values were two-tailed, and the significance level was set at *P* < 0.05. For multivariate logistic regression analysis, predictors with a *P* < 0.3 were entered to select independent discriminating predictors. Receiver operating characteristic (ROC) curves were constructed to evaluate the discriminating ability of predictors. Statistical analyses were performed using Statistical Package for the Social Sciences (SPSS) 19.0 statistical software (SPSS Inc., Chicago, IL, USA).

RESULTS

Demographics and clinical features

Table 1 shows the differences in demographics and clinical features between intestinal BD patients and CD patients. There were a higher prevalence of females and a slightly earlier onset in intestinal BD patients compared to CD patients (*P* = 0.010 and 0.136, respectively). There was no significant difference in the duration from the onset of gastrointestinal symptoms to diagnosis between two groups (*P* = 0.738).

Although the involvement of both the ileum and colon was most common in both intestinal BD patients (91.4%) and CD patients (82.1%), there was still a significant difference in the disease distribution between two groups (*P* = 0.005). There was an increased tendency for intestinal BD patients to have involvement of the upper gastrointestinal tract (17.1%) compared to CD patients (5.7%) (*P* = 0.073).

The most frequent gastrointestinal symptom of both diseases was abdominal pain (*P* = 0.517). Massive gastrointestinal hemorrhage and fever were more frequent in intestinal BD patients (*P* = 0.022 and 0.048, respectively), while diarrhea, intestinal obstruction, and perianal lesions including perianal abscesses, fistula, and/or anal fissure were more common in CD patients (*P* = 0.002, 0.010, and 0.027, respectively).

Intestinal BD, as a multisystemic disease, involved more extraintestinal symptoms compared to CD (*P* = 0.001). For example, genital ulcers and skin lesions were very common in intestinal BD patients, while they were rare in CD patients (*P* < 0.001). Furthermore, 52.0% of intestinal BD

Table 1: Comparison of the demographic and clinical manifestations between intestinal BD and CD

| Characteristics | Intestinal BD | CD | P | |
|--|---------------|-------------|---------------------|-----------------------|
| | | | Univariate analysis | Multivariate analysis |
| Number of patients | 35 | 106 | | |
| Demographics | | | | |
| Gender (male:female) | 15:20 | 72:34 | 0.010 | 0.131 |
| Age at onset (years, mean±SD) | 26.6 ± 10.5 | 30.5 ± 15.3 | 0.136 | 0.756 |
| Duration from gastrointestinal symptom onset to diagnosis (years, mean±SD) | 3.8 ± 4.2 | 4.2 ± 4.2 | 0.738 | |
| Disease distribution (n (%)) | | | 0.005 | 0.539 |
| Isolated ileum | 0 (0.0) | 8 (7.5) | | |
| Isolated colon | 3 (8.6) | 11 (10.4) | | |
| Both ileum and colon | 32 (91.4) | 87 (82.1) | | |
| Upper gastrointestinal tract | 6 (17.1) | 6 (5.7) | | |
| Clinical manifestations (n (%)) | | | | |
| Abdominal pain | 33 (94.3) | 94 (88.7) | 0.517 | |
| Diarrhea | 11 (31.4) | 66 (62.3) | 0.002 | 0.048 |
| Melena or hematochezia | 12 (34.3) | 18 (17.0) | 0.054 | 0.383 |
| Abdominal mass | 9 (25.7) | 34 (32.1) | 0.532 | |
| Perianal lesions | 4 (11.1) | 32 (30.2) | 0.027 | 0.141 |
| Fever | 26 (74.3) | 58 (54.7) | 0.048 | 0.805 |
| Extraintestinal manifestations (n (%)) | | | <0.001 | 0.008 |
| Oral ulcers | 35 (100.0) | 46 (43.4) | | |
| Genital ulcers | 30 (85.7) | 6 (5.7) | | |
| Skin lesions | 27 (77.1) | 7 (6.6) | | |
| Ocular lesions | 6 (17.1) | 2 (1.9) | | |
| Musculoskeletal lesions | 14 (40.0) | 18 (17.0) | | |
| Vascular lesions | 5 (14.3) | 0 (0.0) | | |
| Neurologic lesions | 3 (8.6) | 0 (0.0) | | |
| Hepatobiliary lesions | 0 (0.0) | 1 (0.9) | | |
| Intestinal complications (n (%)) | | | | |
| Massive gastrointestinal hemorrhage | 9 (25.7) | 10 (9.4) | 0.022 | 0.243 |
| Perforation | 5 (14.3) | 7 (6.6) | 0.172 | 0.931 |
| Intestinal obstruction | 11 (22.0) | 91 (41.6) | 0.010 | 0.905 |
| Fistula | 6 (17.1) | 19 (17.9) | 1.000 | |
| History of appendectomy (n (%)) | 4 (11.4) | 12 (11.3) | 1.000 | |

BD: Behçet's disease; CD: Crohn's disease; SD: Standard deviation.

patients had a positive pathology test. No record of pathology testing in CD patients was found.

Based on multivariate logistic regression analysis of demographics and clinical features, diarrhea and extraintestinal manifestations were found to be two independent discriminating predictors (*P* = 0.048 and 0.008, respectively).

Colonoscopic features

Based on colonoscopy, there were significant differences in the ulcer distribution ($P < 0.001$), ulcer size ($P = 0.017$), ulcer type ($P < 0.001$), and ulcer number ($P = 0.014$) in a local area between the two groups [Table 2]. Focal involvement, ileocecal valve deformity, solitary ulcer, large ulcers (ulcer size > 2 cm), and circumferential ulcers were more common in intestinal BD patients ($P = 0.003, 0.003, 0.014, 0.013,$ and 0.003 , respectively), while segmental involvement, longitudinal ulcers, a cobblestone or nodular appearance, and pseudo-polyps were more common in CD patients ($P = 0.003, 0.008, 0.023,$ and 0.002 , respectively). There was no significant difference in the frequency of aphthous ulcers between the two groups ($P = 0.679$).

According to multivariate logistic regression analysis of colonoscopic features, the ulcer distribution, ulcer size, ulcer type and pseudo-polyps were independent discriminating predictors ($P = 0.006, 0.021, 0.002,$ and 0.041 , respectively).

The histology of mucosa biopsies in 11.4% CD patients revealed noncaseating epithelioid granulomas. Neither the appearance of vasculitis nor granulomas was found in the mucosa biopsies of intestinal BD patients. No dysplasia or cancer was found in the mucosa biopsies of any patient.

The discriminating potential of independent predictors

Among the independent discriminating predictors, seven predictors were selected for evaluation of their discriminating ability by using the ROC analysis [Table 3]. For the diagnosis of intestinal BD, genital ulcers and skin lesions had a higher area under the ROC curve (AUC) (0.900 and 0.853, respectively) with high specificity (94.3% and 93.4%, respectively). Circumferential ulcers had a high specificity (92.5%), but very low sensitivity (28.9%). The classification algorithm composed of seven predictors had the highest AUC of 0.987, and high sensitivity (94.3%) and specificity (97.2%).

DISCUSSION

The differential diagnosis of intestinal BD and CD is challenging due to their similarities in mucocutaneous and gastrointestinal manifestations. Both diseases have variable epidemiological and clinical manifestations among different ethnicities.^[6,8,12-14] As the first comparative study in Chinese intestinal BD and CD patients, this study revealed that diarrhea, extraintestinal systemic manifestations, and certain colonoscopic features including ulcer distribution, ulcer type, ulcer size, and pseudo-polyps were independent discriminating predictors.

Consistent with other studies,^[9,15-17] this study showed the following similarities between two diseases: (1) Both diseases had a young age of onset (20–40 years) and long disease duration from symptom onset to diagnosis. (2) The ileocecal region was the most commonly involved site, and multiple gastrointestinal tract sites could be involved. (3) Abdominal pain was the most common gastrointestinal symptom, and severe complications including perforation, fistulae, and massive gastrointestinal bleeding were not rare in either disease. (4) Both diseases could have extraintestinal

Table 2: Comparison of the colonoscopic features between intestinal BD and CD (n (%))

| Characteristics | Intestinal BD | CD | P | |
|------------------------------------|---------------|-----------|---------------------|-----------------------|
| | | | Univariate analysis | Multivariate analysis |
| Ulcer distribution | | | <0.001 | 0.006 |
| Ileocecal region* | 32 (91.4) | 85 (80.2) | | |
| Ascending colon | 6 (17.1) | 43 (40.6) | | |
| Transverse colon | 5 (14.3) | 41 (38.7) | | |
| Descending colon | 6 (17.1) | 33 (33.1) | | |
| Sigmoid colon | 6 (17.1) | 32 (30.2) | | |
| Rectum | 3 (8.6) | 23 (21.7) | | |
| Perianal | 1 (2.9) | 7 (6.6) | | |
| Focal involvement | 27 (77.1) | 50 (47.2) | | |
| Segmental involvement | 8 (22.9) | 56 (52.8) | | |
| Ulcer size (cm) | | | 0.017 | 0.021 |
| >2 | 23 (65.7) | 47 (44.3) | | |
| 0.5–2.0 | 3 (8.6) | 23 (21.7) | | |
| <0.5 | 6 (17.1) | 22 (20.8) | | |
| Number of ulcers in the local area | | | 0.014 | 0.648 |
| 1 | 19 (54.3) | 32 (30.2) | | |
| ≥2 | 16 (45.7) | 74 (69.8) | | |
| Ulcer type | | | <0.001 | 0.002 |
| Circumferential | 10 (28.6) | 8 (7.5) | | |
| Longitudinal | 2 (5.7) | 29 (27.4) | | |
| Aphthous | 1 (2.9) | 7 (6.6) | | |
| Irregular | 24 (68.6) | 71 (67) | | |
| Cobblestone or nodular appearance | 6 (17.1) | 41 (38.7) | 0.023 | 0.105 |
| Pseudo-polyps | 2 (5.7) | 33 (31.1) | 0.002 | 0.041 |
| Stricture | 4 (11.4) | 31 (29.2) | 0.042 | 0.110 |
| Ileocecal valve deformity | 16 (45.7) | 19 (17.9) | 0.003 | 0.078 |

*Ileocecal region represents terminal ileum and/or cecum. BD: Behçet's disease; CD: Crohn's disease.

Table 3: Discriminating potential of independent factors for the diagnosis of intestinal BD

| Items | AUC | Sensitivity, % | Specificity, % |
|-------------------------------|-------|----------------|----------------|
| Absence of diarrhea | 0.654 | 68.6 | 62.3 |
| Genital ulcers | 0.900 | 85.7 | 94.3 |
| Skin lesions | 0.853 | 77.1 | 93.4 |
| Focal involvement | 0.650 | 77.1 | 52.8 |
| Ulcer size >2 cm | 0.607 | 65.7 | 55.7 |
| Circumferential ulcers | 0.605 | 28.6 | 92.5 |
| Absence of pseudo-polyps | 0.627 | 94.3 | 31.1 |
| Combination of above factors* | 0.987 | 94.3 | 97.2 |

*The sensitivity and specificity were obtained with the conventional cut-off value of 0.5. AUC: Area under the receiver operator characteristic curve; BD: Behçet's disease.

systemic manifestations such as recurrent oral ulcers, musculoskeletal lesions, and skin lesions.

Beyond the similarities, there were many differences between two diseases. Intestinal BD patients were more likely to be

female while CD patients were more likely to be male. More upper gastrointestinal tract involvement occurred in intestinal BD patients while more perianal lesions occurred in CD patients. Gastrointestinal bleeding, especially massive hemorrhage, and fever were more common in intestinal BD, while diarrhea and intestinal obstruction were more common in CD. Extraintestinal systemic manifestations were the most powerful discriminating factors between two diseases, especially genital ulcers and skin lesions.^[9,16]

The diagnostic value of endoscopic features for both diseases has always been promising. In 2009, Kim *et al.* compared the colonoscopic findings between 115 intestinal BD patients and 135 CD patients, and found that ulcer shape, ulcer distribution, ulcer number, absence of aphthous lesions, and a cobblestone appearance were independent discriminating predictors.^[18] Our study confirmed that there were significant differences with respect to these five predictors except the presence of aphthous lesions. We also found that ulcer size and pseudo-polyps were two additional independent discriminating predictors. In the Korean study, aphthous lesions occurred in 74.7% of CD patients, and in 11.3% of intestinal BD patients, while aphthous ulcers were rare in the intestinal BD and CD patients from our study. Aphthous ulcers may be the earliest lesions which then become larger and deeper following the disease progression.^[19,20] All patients in our cohort were hospitalized due to advanced and complicated illness, so these early stage aphthous ulcers might have been missed. Korman *et al.* found that the prevalence of aphthous ulcers in BD patients was 83.3% based on enteroclysis, which is contrary to the results of the former study and our findings based on colonoscopy.^[21] Thus, the discriminating value of aphthous lesions between both diseases is still unresolved. Kim *et al.* also developed a simple decision tree by classification and regression tree analysis which was based on the ulcer shape and distribution. This was validated in the Korean cohort and proved to have high sensitivity (94.3%) and specificity (90.0%). However, when this same decision tree was applied to our cohort, the sensitivity for the diagnosis of intestinal BD was 85.7%, while the specificity was only 60.3%. The difference in the diagnostic accuracy of the decision tree may be due to these factors: (1) Different definitions of ulcer type. In our study, we defined a circumferential ulcer as a deep round ulcer with a discrete margin, but in the Korean study round ulcers were only defined by shape. (2) Different disease phenotype of CD patients between the two studies. The prevalence of focal involvement in CD patients was only 23.1% in the Korean study, while it was 47.2% in our study. As mentioned above, the patients in our cohort had advanced disease, which could be indicated by the high incidence of operation (58%) over the course of their follow-ups. (3) In our study, circumferential ulcers and longitudinal ulcers were both present in 5 patients, which made it difficult to categorize them according to the decision tree.

Until now, no worldwide consensus has been established for the diagnosis of intestinal BD. In 2009, Kim *et al.* developed a

novel set of diagnostic criteria for intestinal BD and validated it in Korean patients with ileocolonic ulcers.^[22] The criteria have two aspects: Extraintestinal systemic manifestations and “typical ulcers” upon colonoscopy, defined as <5 deep ulcers with an oval shape, discrete borders and locations in the ileocecal area. In their cohort, 86.2% intestinal BD patients had “typical ulcers,” compared to only 1.5% of nonintestinal BD patients. Using the criteria, the overall sensitivity was 98.6%, the specificity was 83%, and the accuracy was 91.1%. According to the criteria, 35 intestinal BD patients in our study would be classified as definite intestinal BD (30) or suspected intestinal BD (5), while 106 CD patients would be classified as probable intestinal BD (2), suspected intestinal BD (33), or nonintestinal BD (71). Thus, when we apply these criteria for the differential diagnosis of patients with ileocecal ulcers, the suspected intestinal BD patients should be carefully examined by regular check-ups.

There were several limitations in our study. First, since this study was a retrospective cohort study in a single center, and all patients enrolled were hospitalized, there was definite selection bias. Intestinal BD is still rare, and only patients with ulcerative lesions based on colonoscopy and without any history of operation on the gastrointestinal tract except appendectomy were enrolled in the study, which also contributed to the selection biases. Second, data from serological and radiologic examinations were not analyzed in this study. Third, intestinal BD and CD patients were most often diagnosed and treated by rheumatologists and gastroenterologists, respectively. Due to their different perspectives, some valuable information might have been missed. For example, a gastroenterologist might have paid more attention to the gastrointestinal manifestations and ignored extraintestinal manifestations. Further large prospective multi-center or population-based studies are needed to explore the differential markers between these two diseases and develop a worldwide consensus on the diagnosis of intestinal BD.

CONCLUSION

Extraintestinal systemic manifestations and some colonoscopic features including focal involvement, large ulcers, and circumferential ulcers favored the diagnosis of intestinal BD. On the contrary, diarrhea and the endoscopic features, longitudinal ulcers, and pseudo-polyps favored the diagnosis of CD.

REFERENCES

1. Kaklamani VG, Vaiopoulos G, Kaklamani PG. Behçet's disease. *Semin Arthritis Rheum* 1998;27:197-217.
2. Sakane T, Takeno M, Suzuki N, Inaba G. Behçet's disease. *N Engl J Med* 1999;341:1284-91.
3. Bayraktar Y, Ozaslan E, Van Thiel DH. Gastrointestinal manifestations of Behçet's disease. *J Clin Gastroenterol* 2000;30:144-54.
4. Kasahara Y, Tanaka S, Nishino M, Umemura H, Shiraha S, Kuyama T. Intestinal involvement in Behçet's disease: Review of 136 surgical cases in the Japanese literature. *Dis Colon Rectum* 1981;24:103-6.
5. Ideguchi H, Suda A, Takeno M, Miyagi R, Ueda A, Ohno S, *et al.*

- Gastrointestinal manifestations of Behçet's disease in Japan: A study of 43 patients. *Rheumatol Int* 2014;34:851-6.
6. Ebert EC. Gastrointestinal manifestations of Behçet's disease. *Dig Dis Sci* 2009;54:201-7.
 7. Podolsky DK. Inflammatory bowel disease. *N Engl J Med* 2002;347:417-29.
 8. Baumgart DC, Sandborn WJ. Crohn's disease. *Lancet* 2012;380:1590-605.
 9. Grigg EL, Kane S, Katz S. Mimicry and deception in inflammatory bowel disease and intestinal behçet disease. *Gastroenterol Hepatol (N Y)* 2012;8:103-12.
 10. Mizushima Y, Inaba G, Mimura Y. Diagnostic criteria for Behçet's disease in 1987, and guideline for treating Behçet's disease in 1987, and guideline for treating Behçet's disease. *Saishin Igaku* 1988;43:391-3.
 11. Amarapurkar DN, Patel ND, Rane PS. Diagnosis of Crohn's disease in India where tuberculosis is widely prevalent. *World J Gastroenterol* 2008;14:741-6.
 12. Krause I, Yankevich A, Fraser A, Rosner I, Mader R, Zisman D, *et al*. Prevalence and clinical aspects of Behçet's disease in the north of Israel. *Clin Rheumatol* 2007;26:555-60.
 13. Jiang L, Xia B, Li J, Ye M, Yan W, Deng C, *et al*. Retrospective survey of 452 patients with inflammatory bowel disease in Wuhan city, central China. *Inflamm Bowel Dis* 2006;12:212-7.
 14. Sands BE. From symptom to diagnosis: Clinical distinctions among various forms of intestinal inflammation. *Gastroenterology* 2004;126:1518-32.
 15. Jung YS, Cheon JH, Park SJ, Hong SP, Kim TI, Kim WH. Clinical course of intestinal Behçet's disease during the first five years. *Dig Dis Sci* 2013;58:496-503.
 16. Jung YS, Cheon JH, Park SJ, Hong SP, Kim TI, Kim WH. Long-term clinical outcomes of Crohn's disease and intestinal Behçet's disease. *Inflamm Bowel Dis* 2013;19:99-105.
 17. Cao Q, Si JM, Gao M, Zhou G, Hu WL, Li JH. Clinical presentation of inflammatory bowel disease: A hospital based retrospective study of 379 patients in eastern China. *Chin Med J* 2005;118:747-52.
 18. Lee SK, Kim BK, Kim TI, Kim WH. Differential diagnosis of intestinal Behçet's disease and Crohn's disease by colonoscopic findings. *Endoscopy* 2009;41:9-16.
 19. Rutgeerts PJ. From aphthous ulcer to full-blown Crohn's disease. *Dig Dis* 2011;29:211-4.
 20. Hizawa K, Iida M, Kohrogi N, Kuroki F, Yao T, Sakamoto K, *et al*. Crohn disease: Early recognition and progress of aphthous lesions. *Radiology* 1994;190:451-4.
 21. Korman U, Cantasdemir M, Kurugoglu S, Mihmanli I, Soylu N, Hamuryudan V, *et al*. Enteroclysis findings of intestinal Behçet disease: A comparative study with Crohn disease. *Abdom Imaging* 2003;28:308-12.
 22. Cheon JH, Kim ES, Shin SJ, Kim TI, Lee KM, Kim SW, *et al*. Development and validation of novel diagnostic criteria for intestinal Behçet's disease in Korean patients with ileocolonic ulcers. *Am J Gastroenterol* 2009;104:2492-9.

Received: 04-06-2014 **Edited by:** Yuan-yuan Ji

How to cite this article: Li J, Li P, Bai J, Lyu H, Li Y, Yang H, Shen B, Qian JM. Discriminating Potential of Extraintestinal Systemic Manifestations and Colonoscopic Features in Chinese Patients with Intestinal Behçet's Disease and Crohn's disease. *Chin Med J* 2015;128:233-8.

Source of Support: This work was supported by grants from Health Research & Special Projects (No. 201002020) and Programs Foundation of Ministry of Education of China (No. 20111106110009).

Conflict of Interest: None declared.