

Scanning electron microscopy of a blister roof in dystrophic epidermolysis bullosa*

Microscopia eletrônica de varredura do teto de uma bolha de epidermólise bolhosa distrófica

Hiram Larangeira de Almeida Jr.¹
Nara Moreira Rocha⁴

Luciane Monteiro²
Hans Scheffer⁵

Ricardo Marques e Silva³

DOI: <http://dx.doi.org/10.1590/abd1806-4841.20131743>

Abstract: In dystrophic epidermolysis bullosa the genetic defect of anchoring fibrils leads to cleavage beneath the basement membrane, with its consequent loss. We performed scanning electron microscopy of an inverted blister roof of a case of dystrophic epidermolysis bullosa, confirmed by immunomapping and gene sequencing. With a magnification of 2000 times a net attached to the blister roof could be easily identified. This net was composed of intertwined flat fibers. With higher magnifications, different fiber sizes could be observed, some thin fibers measuring around 80 nm and thicker ones measuring between 200 and 300 nm.

Keywords: Basement membrane; Epidermolysis bullosa dystrophica; Microscopy, electron, scanning; Skin diseases, vesiculobullous

Resumo: Na epidermólise bolhosa distrófica, o defeito genético das fibrilas ancorantes leva à clivagem abaixo da membrana basal, com sua consequente perda. Realizamos microscopia eletrônica de varredura do teto invertido de uma bolha de um caso de epidermólise bolhosa distrófica, cujo diagnóstico foi confirmado com imunomapeamento e com sequenciamento gênico. Com uma ampliação de 2.000 vezes, pôde ser facilmente identificada uma rede ligada ao teto da bolha. Essa rede era composta por fibras achatadas e entrelaçadas. Com grandes aumentos, fibras de diferentes tamanhos puderam ser observadas: algumas finas, medindo cerca de 80 nm, e outras mais largas, medindo entre 200 nm e 300 nm.

Palavras-chave: Dermatopatias vesiculobolhosas; Epidermólise bolhosa distrófica; Membrana basal; Microscopia eletrônica de varredura

INTRODUCTION

The basement membrane is an important structure involved in dermal-epidermal adherence. In Dystrophic Epidermolysis Bullosa (DEB), a well-defined subset of EB, the epidermal loss includes the basement membrane, which remains attached to the blister roof. This level of cleavage can be easily demonstrated with monoclonal antibodies against collagen IV (the basement membrane), in so-called immunomapping.¹⁻³ DEB is secondary to inherited dysfunction of collagen VII, the protein that forms the anchoring fibrils, which adhere the basement membrane to the dermal collagen.^{4,5}

We performed scanning electron microscopy (SEM) of an inverted blister from a case of DEB in order to examine the basement membrane, which is normally found in the blister roof. The diagnosis was confirmed with immunomapping and DNA sequencing. The first showed collagen IV in the roof of the blister. It was also positive for collagen VII, ruling out recessive DEB. DNA sequencing identified in exon 75 of COL7A1 gene a pathologic mutation: c.6235G>A (p.Gly2079Arg), establishing the diagnosis of dominant DEB, in accordance with the heredogram, with 3 affected members in this family.

Received on 02.03.2012.

Approved by the Advisory Board and accepted for publication on 20.06.2012.

* Work performed at the Catholic University of Pelotas, the Federal University of Pelotas and the Empresa Brasileira de Pesquisa Agropecuária (EMBRAPA-CPA-CT) - Pelotas (RS), Brazil.

Conflict of interest: None

Financial funding: None

¹ PhD, Assistant Professor of Dermatology - Federal University of Pelotas and Catholic University of Pelotas (UFPel) - Pelotas (RS), Brazil.

² Postgraduate Program in Health, Catholic University of Pelotas (UCPel) - Pelotas (RS), Brazil.

³ Laboratory for Electron Microscopy, Federal University of Pelotas (UFPel) - Pelotas (RS), Brazil.

⁴ Electron Microscopy Laboratory, Empresa Brasileira de Pesquisa Agropecuária (EMBRAPA-CPA-CT) - Pelotas (RS), Brazil.

⁵ PhD - Human Genetics Department, DNA Diagnostics Division, Radboud University Nijmegen Medical Center, Netherlands.

RESULTS

With very low magnification (x 300) the stratum corneum can be seen, and above it the solid aspect of the epidermis (Figure 1A). With a magnification of 2000 times a net attached to the blister roof could be easily identified (Figure 1B). This net was composed of intertwined flat fibers; with higher magnifications (x 20,000) different fiber sizes could be observed, some thin fibers measuring around 80 nm and thicker fibers which measured between 200 and 300 nm (Figure 2).

The membrane of basal keratinocytes could be seen on the border of the examined fragment, where in some areas the net was detached (data not shown) or behind some areas, where this net was thinner (Figure 3), the cell membrane looked like a “solid wall”. Interestingly, solid cellular projections were observed in some examined fields, and with high magnifications of these projections the adherence of the net to the cell membrane was observed (Figure 4).

For comparison purposes dermal collagen was examined, which had a cylindrical form and was not net-arranged (Figure 5). In addition, as control, the epidermis of a case of bullous pemphigoid was examined, with SEM showing only the “solid” aspect of the cell membrane (article in press). This net was also not found in the blister roof of acantholytic blistering diseases.⁶

DISCUSSION

Dystrophic Epidermolysis Bullosa is a subset of EB, resulting in basement membrane loss, hence the dystrophic aspect of the lesions. It is due to a collagen VII inherited dysfunction, the protein that adheres the basement membrane to the dermis. This was confirmed in this case with gene sequencing.^{4,5}

We could not find any report in the literature on the use of scanning electron microscopy in DEB. The examination of an inverted blister with this technique identifies a net, probably a collagen one, attached to the epidermis, similar to the immunomapping findings,

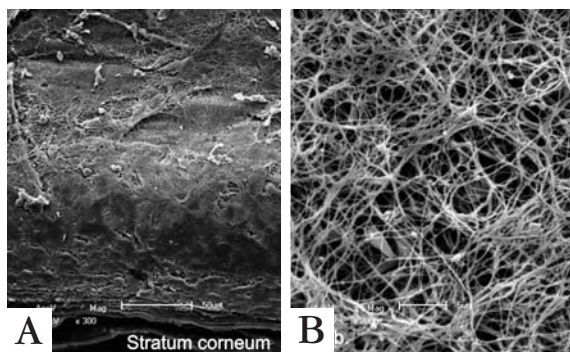


FIGURE 1: Scanning electron microscopy – A. lower magnification with identification of the stratum corneum (x 300); B. Detail of a net attached to the blister roof (x 2.000)




FIGURE 2: Scanning electron microscopy – High magnification showing different diameters of fibers (x 20.000)




FIGURE 3: Scanning electron microscopy – Area with thinner net, with the cell membrane behind it (x 5.000)

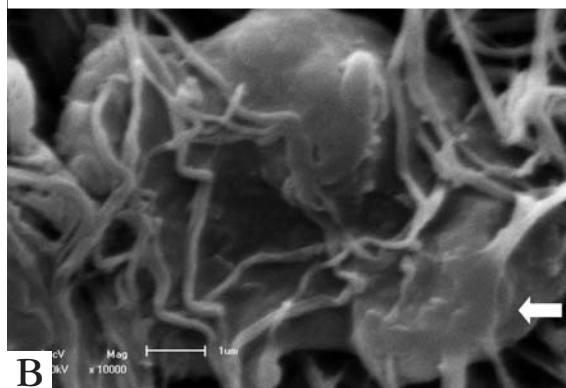
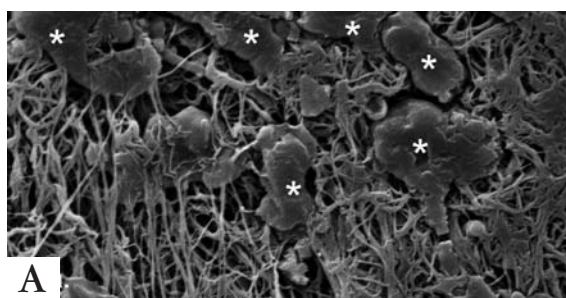


FIGURE 4: Scanning electron microscopy – A. Projections from the cell membrane (asterisks), (x 2.000). B. Adherence of the net to the cell membrane, (arrow) (x 10.000)




FIGURE 5: Scanning electron microscopy—dermal collagen with cylindrical fibers with a parallel arrangement and not reticular (x 10.000)

which also demonstrated collagen IV in the blister roof, the reason why a fibrin net seems to be unlikely.

Collagen IV forms the human cutaneous basement membrane, which is classified as a net-forming collagen.^{7,8} These findings with SEM provide, due to collagen VII dysfunction, possibly a unique documen-

tation, although under pathologic conditions, on the tridimensional morphology of this important dermoepidermal structure, which was reported only after artificial induction in oral mucosa.⁹

Collagen IV final trimeric structure is formed by the fusion of smaller fibrils, which could explain the different sizes found with high magnifications.⁷ In some fields the net was thicker, which could be a consequence of repeated cicatricial processes of DEB. Similarly, “duplication” of the basement membrane was already described in Kindler Syndrome.

Of great interest were the solid cellular projections found, on which the collagen net was attached. It could be the ultrastructural documentation of hemidesmosomes function, located behind the cellular membrane and responsible, due to transmembranous proteins, for adhering the hemidesmosomal plaque to collagen IV - in other words the basal keratinocyte to the basement membrane.□

Acknowledgements

The authors want to thank Dr. Ingrid Haußer-Siller, Institute of Pathology, Heidelberg University for the discussion about the electron microscopy findings.

REFERENCES

1. Horn HM, Tidman MJ. The clinical spectrum of dystrophic epidermolysis bullosa. *Br J Dermatol.* 2002;146:267-74.
2. Fine JD, Eady RAJ, Bauer EA, Bauer JW, Bruckner-Tuderman L, Heagerty A, *et al.* The classification of inherited epidermolysis bullosa (EB): Report of the Third International Consensus Meeting on Diagnosis and Classification of EB. *J Am Acad Dermatol.* 2008;58:931-50.
3. Oliveira ZNP, Périgo AM, Fukumori MI, Aoki V. Immunological mapping in hereditary epidermolysis bullosa. *An Bras Dermatol.* 2010;85:856-61.
4. Nakamura H, Sawamura D, Goto M, Sato-Matsumura KC, LaDucaJ, Lee JY, *et al.* The G2028R glycine substitution mutation in COL7A1 leads to marked inter-familial clinical heterogeneity in dominant dystrophic epidermolysis bullosa. *J Dermatol Sci.* 2004;34:195-200.
5. Dang N, Murrell DF. Mutation analysis and characterization of COL7A1 mutations in dystrophic epidermolysis bullosa. *Exp Dermatol.* 2008;17:553-68.
6. de Almeida HL Jr, Leitão AH, Rossi G, Rocha NM, e Silva RM. Scanning electron microscopy of acantholysis in pemphigus foliaceus. *An Bras Dermatol.* 2013;88:456-8.
7. Gordon MK, Hahn RA. Collagens. *CellTissue Res.* 2010;339:247-57.
8. Shoulders MD, Raines RT. Collagen structure and stability. *Annu Rev Biochem.* 2009;78:929-58.
9. Abe M, Osawa T. The structure of the interstitial surfaces of the epithelial basement membranes of mouse oral mucosa, gingiva and tongue. *Arch Oral Biol.* 1999;44:587-94.

MAILING ADDRESS:

Hiram Larangeira de Almeida Jr.
 Faculdade de Medicina - UFPEL
 Av. Duque de Caxias, 250
 96030-000- Pelotas - RS
 Brazil
 E-mail: hiramalmeidajr@hotmail.com

How to cite this article: Almeida Jr HL, Monteiro L, Marques e Silva R, Moreira Rocha N, Scheffer H. Scanning electron microscopy of a blister roof in dystrophic epidermolysis bullosa. *An Bras Dermatol.* 2013;88(6):966-8.