

Exam 1 Questions

Wherever the art of medicine is loved, there is also a love of humanity.

Hippocrates of Kos
(ca 460 BC–ca 370 BC)

1. Which of the following is the most common form of incomplete spinal cord injury?
 - A. Central cord syndrome
 - B. Cauda equina syndrome
 - C. Anterior spinal cord syndrome
 - D. Posterior spinal cord syndrome
 - E. Brown-Sequard lesion

2. A 64-year-old male with a history of chronic alcohol abuse and congestive heart failure is currently recovering from excision of a large right shoulder lesion suspicious for melanoma. Postoperatively, he is experiencing bleeding and oozing from his surgical site that has persisted despite suture repair and direct pressure for an extended period of time. His labs are drawn, and are as follows: platelets $141 \times 10^3/\text{mL}$, INR 1.2, fibrinogen 90 mg/dL. Which of the following blood products should be administered next?
 - A. Fresh frozen plasma
 - B. Cryoprecipitate
 - C. Prothrombin complex concentrate
 - D. Recombinant activated factor VII
 - E. Aminocaproic acid

3. A 75-year-old, 90 kg male with a history of peripheral vascular disease, coronary artery disease, and epilepsy following a recent cerebral infarction presents to the emergency department after having three witnessed seizures at home. He was intubated at the scene by the paramedics, and received 8 mg of intravenous lorazepam and 1 g of phenytoin. While you are evaluating him, he has another generalized tonic-clonic seizure, and the nurse asks if you would like to initiate a continuous propofol infusion. His blood pressure is 94/42 mmHg, and he is having numerous premature ventricular contractions (PVCs) on the electrocardiographic monitor. He has no history of platelet or liver dysfunction. Which of the following should be performed next?
- A. Complete the phenytoin load to attain 20 mg/kg, then start propofol infusion
 - B. Complete the phenytoin load to attain 20 mg/kg only
 - C. Administer valproate, 30 mg/kg over 10 min, as well as midazolam 0.2 mg/kg
 - D. Start immediate midazolam infusion at 2 mg/kg/h
 - E. Give a 1 L normal saline bolus, and start a norepinephrine infusion to normalize blood pressure
4. A 38-year-old male is brought to the emergency department after a motor vehicle accident. He is found to have significant ecchymoses on his chest and face, with multiple apparent rib fractures. He is in mild respiratory distress, with an oxygen saturation of 89% on room air, and hypotensive, with a systolic blood pressure of 88 mmHg. He has absent breath sounds on the right side. There is currently a delay in obtain a bedside portable chest x-ray. Which of the following should be performed next?
- A. 28-French chest tube placement
 - B. 16-French chest tube placement
 - C. Obtain computed tomography (CT) of the chest
 - D. Administer 30 cc/kg crystalloid
 - E. Obtain urgent cardiothoracic surgery consult
5. Stress ulcer prophylaxis is often undertaken to prevent clinically important upper gastrointestinal (GI) bleeding. Which of the following factors puts patients at highest risk for such bleeding episodes?
- A. Respiratory failure
 - B. History of alcohol abuse
 - C. NPO status
 - D. Diverticulitis
 - E. All of the above
6. In an intact heart, the Frank-Starling mechanism describes contractility increases in responses to:
- A. Decreased preload
 - B. Increased afterload
 - C. Decreased left ventricular end-diastolic pressure

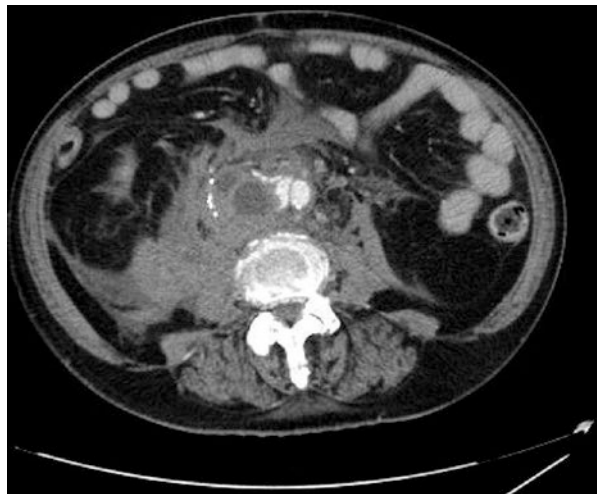- D. Increased left ventricular end-diastolic volume
 - E. Increased pulmonary vascular resistance
7. A 68-year-old female with a history of hyperlipidemia, hypothyroidism, and gastric cancer on total parenteral nutrition is currently in the ICU following a small traumatic subdural hemorrhage. On hospital day 5, the patient begins to spike fevers that persist despite broad spectrum antibiotic coverage with vancomycin and piperacillin-tazobactam. She is otherwise hemodynamically stable. The lab calls you to notify you that multiple sets of blood cultures display budding yeast forms and pseudohyphae. Which of the following should be administered next?
- A. Fluconazole
 - B. Posaconazole
 - C. Anidulafungin
 - D. Caspofungin
 - E. Amphotericin B
8. A 56-year-old male with a past medical history of hypertension, hyperlipidemia, and morbid obesity is currently intubated in the ICU following a left middle cerebral artery infarct. The respiratory therapist alerts you the fact that the patient has become markedly dysynchronous with the ventilator, including breath holding episodes, breath stacking, and resisting ventilator-delivered breaths. A variety of pressure- and volume-regulated ventilator modes have been attempted without improvement, as well as boluses of both fentanyl and midazolam. The most recent arterial blood gas is as follows: pH 7.19, PaCO₂ 78 mmHg, PaO₂ 61 mmHg. The patient is now hypotensive to 91/66 mmHg with sinus tachycardia at 117 beats/min. A recent bedside chest x-ray shows no consolidation or pneumothorax. Which of the following should be performed next?
- A. Prone the patient
 - B. Administer nitric oxide at 10 parts per million
 - C. Administer 10 mg of cisatracurium
 - D. Administer a mixture of 60% helium/40% oxygen
 - E. Administer a continuous infusion of phenobarbital
9. Compared to lactulose for the treatment of hepatic encephalopathy, polyethylene glycol (PEG) has been shown to:
- A. Decrease in-hospital mortality
 - B. More rapidly improve symptoms
 - C. Increase the rate of gastrointestinal complications
 - D. Increase the incidence of major electrolyte abnormalities
 - E. None of the above
10. Which of the following neurologic insults is the least likely to cause central (non-infectious) fever in the ICU?
- A. Intracranial neoplasm
 - B. Intraventricular hemorrhage

- C. Normal pressure hydrocephalus
 - D. Subarachnoid hemorrhage
 - E. Traumatic brain injury
11. A 57-year-old male with a history of epilepsy and medication noncompliance is admitted to a small community hospital after a brief tonic-clonic seizure. A non-contrast head CT on admission is normal. On the second hospital day, the patient begins to complain of severe substernal chest pressure, and an urgent bedside EKG shows evidence of an acute inferior myocardial infarction (MI). The nearest percutaneous coronary intervention (PCI) capable center is approximately 150 min away by the fastest transport method available. Which of the following is the most appropriate next step in this patient's care?
- A. Arrange for transport to the closest PCI center with anticipated balloon time within 30 min of arrival
 - B. Prepare to administer fibrinolytic therapy
 - C. Consult cardiothoracic surgery for possible coronary artery bypass grafting (CABG)
 - D. Place the patient on a continuous nitroglycerine infusion and administer aspirin, clopidogrel, and heparin
 - E. Await serum cardiac biomarkers and repeat EKG in 1 h
12. A 62-year-old male with unknown past medical history who recently immigrated from El Salvador is currently in the stroke unit after suffering from an acute left middle cerebral artery infarction. The patient is aphasic; his wife states that he been in his usual state of health lately, and denies any recent weakness, dizziness, chest pain, cough, shortness of breath, or fevers. On reviewing this patient's belongings, the nurse discovers a bottle of isoniazid, as well as paperwork demonstrating a positive quantiferon gold test performed at a local clinic approximately 3 weeks ago. He does not appear to be on any other medications. A bedside portable chest x-ray is performed, which preliminarily appears normal. Which of the following should be performed next?
- A. Move the patient to a negative pressure isolation room, continue isoniazid
 - B. Isolate the patient, continue isoniazid, add rifampin
 - C. Isolate the patient, continue isoniazid, add rifampin and pyrazinamide
 - D. Isolate the patient, continue isoniazid, add rifampin, pyrazinamide and ethambutol
 - E. None of the above
13. A 56-year-old, 70 kg female patient in oliguric renal failure would be expected to have a daily urine output of:
- A. No more than 50 mL
 - B. No more than 400 mL
 - C. No more than 800 mL
 - D. Less than 70 mL/h
 - E. Less than 35 mL/h

14. A 37-year-old female with a history of epilepsy is admitted to the ICU with status epilepticus. She required several doses of lorazepam in the emergency department in addition to fosphenytoin, intubation, and a continuous propofol infusion. There was concern for aspiration in the prehospital setting. Approximately 3 days after being admitted to the hospital, her respiratory status has worsened; she is increasingly hypoxic, and her chest x-ray demonstrates diffuse bilateral interstitial infiltrates. The patient is afebrile with minimal secretions. Her most recent arterial blood gas is as follows: pH 7.21, PaO₂ 107 mmHg, PCO₂ 55 mmHg, 100% FiO₂, and a positive end-expiratory pressure (PEEP) of 8 cm H₂O. According to the Berlin criteria, how would you categorize this patient's acute respiratory distress syndrome (ARDS)?
- A. Acute lung injury (ALI)
 - B. Mild ARDS
 - C. Moderate ARDS
 - D. Severe ARDS
 - E. None of the above
15. An 80-year-old male presents to the emergency department with multiple episodes of bright red blood per rectum. He is on aspirin and clopidogrel for a history of coronary artery disease and a previous transient ischemic attack. He underwent aortic graft surgery for repair of an abdominal aortic aneurysm 2 years ago. A complete blood count and coagulation profile are all within normal limits. His vital signs are as follows: blood pressure 102/58 mmHg, heart rate 98 beats/min, respiratory rate 18 breaths/min, oxygen saturation 98% on room air, and temperature 98.3 °F. Which of the following is the next best step in the care of this patient?
- A. Transfuse platelets, fresh frozen plasma, and recombinant factor VIIa
 - B. Consult gastroenterology for emergent upper endoscopy
 - C. Consult gastroenterology for emergent colonoscopy
 - D. CT angiogram of the abdomen and pelvis
 - E. Expectant management with fluids and blood transfusions
16. A thrombus in which of the following veins would not be considered a deep vein thrombosis (DVT)?
- A. Popliteal vein
 - B. Soleal vein
 - C. Femoral vein
 - D. Gastrocnemius vein
 - E. Greater saphenous vein
17. After partial resection of the pituitary stalk, secretion of which of the following hormones will be most affected?
- A. Oxytocin
 - B. Adrenocorticotrophic hormone

- C. Melanocyte-stimulating hormone
 - D. Thyroid-stimulating hormone
 - E. All will be equally affected
18. A 58-year-old female with a history of hypertension, rheumatoid arthritis, metastatic ovarian cancer, and bilateral deep venous thrombosis status post recent inferior vena cava filter placement presents to the emergency department with right flank pain. She states the pain began approximately 1 h ago when bending down to pick something off the floor, and that it is constant and severe in nature. She denies dysuria or hematuria. Her vital signs are as follows: blood pressure 108/62 mmHg, heart rate 121 beats/min, respiratory rate 20 breaths/min, oxygen saturation 99% on room air, and temperature 99.6 °F. A CT scan of the abdomen is obtained (see Image 1). Which of the following is the next best step in this patient's management?
- A. Administer vancomycin and cefepime, and draw two sets of blood cultures
 - B. Urgent vascular surgery consult
 - C. Immediately place the patient on her left side
 - D. Rapid sequence intubation with mechanical ventilation
 - E. Perform bedside diagnostic peritoneal lavage

Image 1 CT scan of the abdomen



19. Which of the following antiepileptic medications undergoes both hepatic metabolism and renal elimination?
- A. Phenytoin
 - B. Levetiracetam
 - C. Valproate
 - D. Pentobarbital
 - E. Lacosamide

20. A 65-year-old male is brought to the emergency department by his family with several months of progressive behavioral changes and lethargy. On exam, he appears confused, and is minimally verbal. An MRI of the brain is performed, demonstrating a large homogeneously enhancing lesion with a dural tail in the right frontal lobe with significant surrounding edema. The patient undergoes a right frontal craniotomy with gross total resection of the lesion. Surgical pathology is consistent with a World Health Organization (WHO) grade I lesion. All of the following are true regarding this patient's pathology except:
- A. This is the most common primary brain tumor in adults
 - B. This lesion is more common in men versus women (2:1 ratio)
 - C. This lesion often expresses progesterone and estrogen receptors
 - D. Risk factors for the development of this lesion include ionizing radiation exposure
 - E. Greater than 90% of these lesions are supratentorial
21. A 69-year-old male with a history of hypertension, diabetes, and a recent left middle cerebral artery infarct is found to have a significant left internal carotid artery stenosis on further work-up. Which of the following represents the threshold amount of carotid stenosis to recommend this patient be evaluated for carotid endarterectomy?
- A. >10%
 - B. >40%
 - C. >70%
 - D. >90%
 - E. >99%
22. "Massive" pulmonary embolism (PE) is best described as PE in the presence of:
- A. Any single mean arterial pressure (MAP) less than 65 mmHg
 - B. Heart rate greater than 100 beats/min regardless of blood pressure
 - C. Systolic pressure less than 90 mmHg for greater than 15 min
 - D. Abnormal bowing of the interventricular septum on bedside echocardiography
 - E. Any single elevated serum troponin
23. A 51-year-old male has been admitted to the ICU for a traumatic brain injury. The patient received a kidney transplant 3 years ago, and is on immunosuppression with mycophenolate mofetil and cyclosporine. On hospital day 3, the patient suffers a generalized tonic-clonic seizure which abates after administration of lorazepam, and you are now considering future seizure prophylaxis. Which of the following medications is not expected to interfere with this patient's serum cyclosporine levels?
- A. Fosphenytoin
 - B. Carbamazepine
 - C. Phenobarbital
 - D. Levetiracetam
 - E. All of the above

24. According to the three column theory of spinal cord stability, the spinal cord can be divided into three segments that each contribute to cord stability in a different manner. All of the following are true regarding the three column theory except:
- A. The anterior column consists of the anterior vertebral body, anterior annulus fibrosus, and anterior longitudinal ligament
 - B. The middle column includes the posterior longitudinal ligament, posterior annulus fibrosus, and posterior wall of the vertebral body
 - C. The posterior column comprises the pedicles, the facet joints, and the supraspinous ligaments
 - D. All three columns must be disrupted for the spine to be considered unstable
 - E. Spinal trauma is classified as minor or major depending on the ability of the injury to cause instability
25. A 22-year-old female was admitted to the psychiatry service after presenting with 10 days of bizarre and disinhibited behavior, as well as auditory and visual hallucinations. While on the psychiatry service, she had a prolonged generalized tonic-clonic seizure requiring intubation and transfer to the ICU. Lumbar puncture was performed, and N-Methyl-D-aspartate (NMDA) receptor antibodies were positive in the spinal fluid. All of the following are accepted first-line treatments for this patient except:
- A. Intravenous immunoglobulin (IVIG)
 - B. Tumor resection, if applicable
 - C. Corticosteroids
 - D. Plasma exchange
 - E. Rituximab
26. A 54-year-old male is currently recovering from transphenoidal resection of a pituitary mass. A serum cortisol level is drawn the next morning. A value below which cutoff is associated with a significant risk of long-term hypothalamic-pituitary-adrenal (HPA) dysfunction?
- A. 1 $\mu\text{g}/\text{dL}$
 - B. 15 $\mu\text{g}/\text{dL}$
 - C. 75 $\mu\text{g}/\text{dL}$
 - D. 300 $\mu\text{g}/\text{dL}$
 - E. 600 $\mu\text{g}/\text{dL}$
27. A 71-year-old female in the ICU with an acute-on-chronic subdural hemorrhage develops acute kidney injury, and requires hemodialysis. Upon consultation with the nephrology service, the decision is made to initiate continuous renal replacement therapy (CRRT). Which of the following is an advantage of CRRT compared to intermittent hemodialysis?
- A. CRRT has a lower overall cost of disposables
 - B. CRRT is easier to implement without the use of anticoagulation
 - C. Rapid adjustments can be made to accommodate evolving patient needs

- D. CRRT is more widely available
 - E. Nursing staff may be more familiar with the CRRT modality
28. An irregular group of breaths followed by apneic periods of variable duration in a patient with a lesion in the pneumotaxic center of the upper medulla would be classified as which of the following?
- A. Cheyne-Stokes respiration
 - B. Central neurogenic hyperventilation
 - C. Cluster breathing
 - D. Kussmaul respirations
 - E. Apneustic breathing
29. Which of the following echocardiography findings is most consistent with Takotsubo cardiomyopathy?
- A. Apical ballooning
 - B. Bowing of the ventricular septum into the left ventricle
 - C. Hypoechoic area surrounding the pericardium
 - D. Enlargement of the left ventricular outflow tract
 - E. Hyperdynamic left ventricle
30. A 27-year-old female with no prior medical history at 37 weeks gestation presents with hypertension and a dull frontal headache, and is admitted for the management of preeclampsia. A continuous magnesium infusion is started. Which of the following additional medications would be contraindicated in the treatment of this patient's blood pressure?
- A. Labetalol
 - B. Hydralazine
 - C. Hydrochlorothiazide
 - D. Captopril
 - E. Nicardipine
31. A 28-year-old 50 kg female is currently hospitalized with a myasthenic crisis. While you are evaluating her, you note her to be mildly tachypneic with some accessory muscle use. Her oxygen saturation is 97% on room air. You obtain the following respiratory parameters: vital capacity 890 mL, peak inspiratory pressure 44 cm H₂O, peak expiratory pressure 61 cm H₂O. Which of the following is the next best step in management?
- A. Intubate the patient
 - B. Place the patient on noninvasive positive pressure ventilation
 - C. Place the patient on 4 L supplemental oxygen
 - D. Check the patient's rapid shallow breathing index
 - E. Check the patient's carbon dioxide level
32. A 62-year-old male with a history of cirrhosis, ascites, and prior spontaneous bacterial peritonitis is admitted to the ICU with worsening encephalopathy. Despite home therapy with rifaximin and lactulose, his mental status has been

declining steadily, and he requires intubation for airway protection. A non-contrast head CT demonstrates mild diffuse cerebral edema. All of the following are reasonable strategies to reduce this patient's cerebral edema except:

- A. Elevate the head of the bed 30°
 - B. Intravenous mannitol
 - C. Intravenous hypertonic saline
 - D. Intravenous dexamethasone
 - E. Induced hypothermia
33. Which of the following would lead you to incorrectly conclude that a patient with no prior medical history, based on their hemoglobin A1c, was actually a diabetic?
- A. Surreptitious alcohol abuse
 - B. Severely elevated triglycerides
 - C. Recent blood transfusion
 - D. Erythropoietin administration
 - E. Hemolytic anemia
34. A 77-year-old male from the nursing home has been admitted to the ICU for lethargy. The patient weighed 58 kg on admission, and the serum sodium was noted to be 177 mEq/L. About how much would you expect 1 L of 0.225% sodium chloride to reduce the serum sodium?
- A. 1.6 mEq/L
 - B. 4.6 mEq/L
 - C. 8.6 mEq/L
 - D. 16.6 mEq/L
 - E. 32.6 mEq/L
35. A 52-year-old female is admitted to the ICU after an anterior cervical discectomy and fusion surgery. On day 5 of her hospital stay, the patient was found to have a proximal deep venous thrombosis (DVT) in her left leg. Treatment was initiated with a continuous heparin infusion with target aPTT 1.5–2 times baseline. Her platelet count this morning was $130 \times 10^3/\mu\text{L}$; it was $280 \times 10^3/\mu\text{L}$ on admission. Her 4T score was 6, and a heparin PF4 immunoassay is pending. What is the next best step in this patient's management?
- A. Discontinue unfractionated heparin infusion, initiate argatroban infusion
 - B. Discontinue unfractionated heparin infusion, initiate warfarin therapy
 - C. Discontinue unfractionated heparin infusion, initiate low-molecular weight heparin therapy
 - D. Continue unfractionated heparin infusion while awaiting PF4 immunoassay result
 - E. Continue unfractionated heparin infusion, initiate argatroban infusion

36. Which of the following vasculitides may present with central nervous system involvement?
- A. Wegner's granulomatosis
 - B. Polyarteritis nodosa
 - C. Churg-Strauss syndrome
 - D. Behcet's syndrome
 - E. All of the above
37. Which of the following describes correctly the radiologic findings in a developmental venous anomaly of the brain?
- A. MRI shows medullary veins converging on a dilated transcerebral vein with a characteristic "sunburst" pattern on enhanced T1 weighted images
 - B. Cerebral angiography shows a faint blush with an associated venous channel in the late arterial or early capillary phases
 - C. Cerebral angiography is normal, as these lesions are "angiographically occult" with minimal blood flow
 - D. MRI shows a "popcorn" pattern of variable image intensities in T1 and T2-weighted images consistent with evolving blood products
 - E. CT scan without contrast shows flow voids demonstrating enlarged tangled vessels with curvilinear or speckled calcification
38. Which of the following definitions accurately describes renal "loss" based on the RIFLE (Risk, Injury, Failure, Loss, End-stage) classification scheme for acute kidney injury?
- A. Tripling of serum creatinine
 - B. Serum creatinine ≥ 4 mg/dL
 - C. Urine output < 0.3 mL/kg/h $\times 24$ h or anuria $\times 12$ h
 - D. Renal failure > 4 weeks
 - E. Urine output < 0.5 mL/kg/h $\times 12$ h
39. A 27-year-old female with a history of chronic migraines presents to the emergency department with new onset weakness in her right leg over the past several days. A non-contrast CT of the head is performed, demonstrating evidence of a large left frontal lesion. Which of the following will conclusively differentiate Marburg variant multiple sclerosis (MVMS) from an acute neoplastic process?
- A. Contrast-enhanced CT scan
 - B. Contrast-enhanced MRI
 - C. Positron emission tomography
 - D. Craniotomy and biopsy
 - E. Diffusion tensor imaging

40. A 52-year-old male is currently intubated in the ICU after suffering an aneurysm-related subarachnoid hemorrhage (SAH). He is intubated and on mechanical ventilation; his height is 72 in. and he weighs 320 kg. He is placed on assist-control, rate of 16, tidal volume 650 cc, positive end-expiratory pressure (PEEP) of 5, and FiO₂ 40%. Post-intubation chest x-ray shows an opacity in the right lower lobe. On the second ICU day, his FiO₂ requirements have increased to 80% to maintain an O₂ saturation of >90%, and his CXR now shows bilateral alveolar opacities. His plateau pressure is 30. He is on piperacillin-tazobactam for antibiotic coverage, with a negative endotracheal aspirate gram stain. Which of the following should be performed next?
- A. Prone the patient
 - B. Decrease the tidal volume to 500 and increase PEEP to 8
 - C. Add vancomycin and azithromycin
 - D. Start inhaled nitric oxide therapy
 - E. Place the patient on extracorporeal membrane oxygenation (ECMO)
41. Which of the following is the definition of Mallory-Weiss syndrome?
- A. Linear mucosal lacerations of the esophagus at the gastroesophageal junction
 - B. Full thickness tears of the esophagus due to retching at the gastroesophageal junction
 - C. Esophageal variceal bleeding at the gastroesophageal junction
 - D. Esophageal metaplasia at the gastroesophageal junction due to chronic exposure to acid reflux
 - E. Peptic ulcer disease resulting in gastrointestinal bleeding
42. A 19-year-old male with no significant past medical history presents to the emergency department with fever, confusion, and lethargy. The parents report that he had been complaining of headaches and nausea for several days before decompensating prior to arriving at the hospital. They also report that he has spent the last 6 weeks at an outdoor summer camp, and had not been ill recently otherwise. A lumbar puncture is performed, and while awaiting the results, the patient is started on ceftriaxone, vancomycin and acyclovir. Several hours later, the laboratory calls you urgently to report the presence of motile amebae in the cerebrospinal fluid (CSF) sample that was sent. Which of the following should be administered next?
- A. Mebendazole
 - B. Miltefosine
 - C. Doripenem
 - D. Fidamoxicin
 - E. Rifampin
43. A 71-year-old male with a history of peripheral vascular disease and hypertension is currently hospitalized while recovering from a transient ischemic attack when he begins to complain of several hours of severe generalized abdominal

pain. Surprisingly, his abdominal exam is relatively benign considering how uncomfortable he appears. His lab work is notable for a white blood cell count of $26.6 \times 10^9/L$ with 17% bands, along with a lactate of 11.6 mmol/L. Which of the following is the gold standard for the diagnosis of the most likely etiology?

- A. Duplex ultrasound
 - B. Flexible endoscopy and tissue biopsy
 - C. Contrast-enhanced MRI
 - D. CT arteriography
 - E. Plain abdominal radiography
44. Which of the following is true regarding the use of nimodipine in critically ill patients?
- A. It is widely used for antihypertensive purposes
 - B. It has been proven to be equally effective versus magnesium in the treatment of preeclampsia
 - C. It may be used to attempt to preserve cochlear nerve function following schwannoma surgery
 - D. It is used as a continuous intravenous infusion for the prevention of delayed cerebral ischemia (DCI)
 - E. None of the above
45. A 21-year-old man presents to the emergency department with 1 day of abdominal pain, nausea and vomiting. His past medical history was unremarkable up until a few months ago, when he started to develop transient weakness in his extremities, and has been hospitalized twice since then with generalized tonic-clonic seizures. He has one sibling, who has also experienced similar episodes. His vital signs are as follows: temperature 36.6 °C, blood pressure 136/66 mmHg, pulse rate 96 beats/min, respiratory rate 14 breaths/minute. His abdomen is distended on exam, and a CT scan of the abdomen and pelvis demonstrates distended loops of bowel without any overt mechanical obstruction. Blood work demonstrates a normal leukocyte count with a markedly elevated serum lactate. All of the following are true about the patient's condition except:
- A. This patient would be unlikely to pass this condition on to his children
 - B. The majority of cases are caused by mutations in the MT-TL1 gene
 - C. Half of all cases appear to be due to spontaneous mutations, without prior family history
 - D. The patient's condition is uniformly progressive and fatal
 - E. The disease is frequently misdiagnosed, due to both rarity and heterogeneous presentations
46. A 50-year-old male with a 100 pack-year smoking history presents to the emergency department with shortness of breath. He was diagnosed with primary lung adenocarcinoma 1 week ago. Computed tomography (CT) imaging of the chest shows extrinsic compression of the trachea by a left lung mass. The

patient is able to speak in full sentences, though becomes short of breath while doing so. He is afebrile, with the following vital signs: heart rate 99 beats/min, blood pressure 140/90 mmHg, respiratory rate 20 breaths/min, and oxygen saturation of 97% on 2 L nasal cannula. On exam, there is intermittent inspiratory wheezing auscultated on the neck with otherwise clear lung fields. What is the best immediate treatment to alleviate the patient's symptoms?

- A. Racemic epinephrine
 - B. Helium-oxygen mixture
 - C. Intravenous corticosteroids
 - D. Surgical intervention of the lung mass
 - E. Inhaled bronchodilators
47. A 64-year-old male with a history of congestive heart failure is currently admitted to the hospital for work-up of a suspected transient ischemic attack. He is also complaining of urinary frequency and dysuria, and his urinalysis indicates the presence of a urinary tract infection on admission. Approximately 24 h later, urine cultures indicate the presence of *Escherichia coli* with the following minimum inhibitory concentration (MIC) susceptibilities (see Table 1 below). According to the susceptibility chart alone, which of the following antibiotics is most likely to result in eradication of this patient's infection?
- A. Ceftriaxone
 - B. Cefepime
 - C. Cefoxitin
 - D. Piperacillin/tazobactam
 - E. None of the above

Table 1 MIC susceptibilities

Ampicillin	R > 16
Ceftriaxone	S < 1
Cefepime	S < 4
Cefoxitin	S < 8
Piperacillin/tazobactam	S < 16

48. An excess of all of the following may result in severe metabolic alkalosis except:
- A. Vomiting
 - B. Nasogastric suctioning
 - C. Diuretic use
 - D. Mineralocorticoid administration
 - E. Blood loss

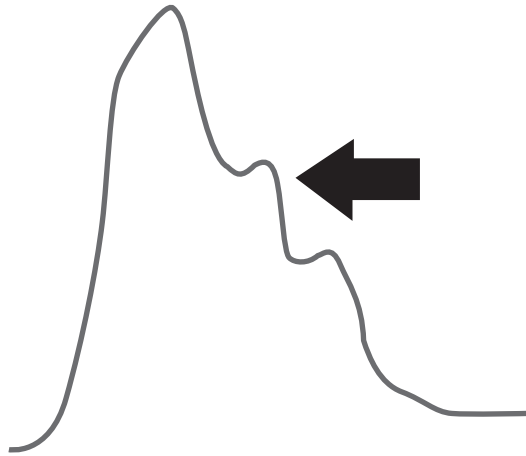
49. In the setting of traumatic brain injury (TBI), pretreatment with which of the following agents has been proven prevent elevation of intracranial pressure (ICP) associated with endotracheal intubation?
- A. Lidocaine
 - B. Fentanyl
 - C. Succinylcholine
 - D. Etomidate
 - E. None of the above
50. A 61-year-old male is currently admitted to the ICU following 18 months of progressive gait dysfunction, memory loss, and intermittent episodes of urinary incontinence. A non-contrast head CT performed on admission demonstrates moderate hydrocephalus, and a lumbar drain trial is being performed. 5 cc/h of spinal fluid is being drained. 48 h after lumbar drain insertion, the patient is being evaluated by the physical therapy and neurocognitive teams, who report no significant change from their initial evaluations on admission. Which of the following should be performed next?
- A. Continue lumbar drainage at current rate for an additional 72 h, reassess
 - B. Increase drainage rate to 10 cc/h, continue for an additional 48 h, reassess
 - C. Discontinue lumbar drain, schedule the patient for ventriculoperitoneal (VP) shunt placement, reassess the patient 3 months post-operatively
 - D. Discontinue lumbar drain, as the patient is not a candidate for a VP shunt
 - E. Discontinue lumbar drain and repeat lumbar drain trial in 3 months
51. All of the following brain metastases are at a high risk for intracranial hemorrhage except:
- A. Melanoma
 - B. Renal cell carcinoma
 - C. Choriocarcinoma
 - D. Thyroid carcinoma
 - E. Breast carcinoma
52. A 61-year-old female with a history of heparin-induced thrombocytopenia (HIT), polycythemia vera, and multiple prior thrombotic events including bilateral pulmonary emboli, is currently being evaluated for 4 weeks of chronic daily headaches. She is currently on daily aspirin and rivaroxaban for maintenance therapy. Her hemoglobin is 16.1 g/dL and her hematocrit is 48%. A CT venogram of the head is performed, demonstrating an acute superior sagittal sinus thrombus. Which of the following should be administered at this time?
- A. Fondaparinux
 - B. Low molecular weight heparin

- C. Unfractionated heparin infusion
 - D. Apixaban
 - E. Eptifibatide
53. During endotracheal intubation, in the absence of a view of the vocal cords, optimal bougie technique involves:
- A. Using the upturned end to put pressure on the vallecula and lift the epiglottis
 - B. Inserting the bougie at the corner of the mouth and sweeping the tongue out of the way
 - C. Blindly inserting the bougie into the mouth advancing until resistance is felt
 - D. Sliding the bougie under the visualized epiglottis and feeling for the tracheal rings
 - E. Advancing the bougie under ultrasound guidance with the probe on the trachea
54. A 44-year-old female with a history of metastatic breast cancer is currently being treated in the ICU for leptomeningeal disease, and her prognosis is grave. The patient asks that you do not discuss any aspect of her care with her family, as she does not believe they are emotionally equipped to handle the news, and you promise to uphold her wish. Your promise aligns with which of the following ethical principles?
- A. Beneficence
 - B. Non-maleficence
 - C. Autonomy
 - D. Fidelity
 - E. Justice
55. Which of the following has been associated with a decreased risk of ventriculitis in patients with indwelling ventriculostomy catheters?
- A. Cerebrospinal fluid (CSF) surveillance daily
 - B. CSF surveillance every third day
 - C. Catheter exchange every 5 days
 - D. Silver-impregnated catheters
 - E. Insertion site antibiotic wafers
56. A 62-year-old male with a history of myasthenia gravis is currently being evaluated for aspiration pneumonia in the setting of a myasthenic crisis, with evidence of a developing empyema on chest x-ray. Which of the following would be appropriate empiric antibiotic coverage in this setting?
- A. Cefepime and azithromycin
 - B. Levofloxacin
 - C. Piperacillin-tazobactam and ciprofloxacin
 - D. Clindamycin and moxifloxacin
 - E. Ampicillin-sulbactam

57. A 23-year-old female presents to the emergency department with headache, lethargy and confusion. A non-contrast head CT demonstrates diffuse subarachnoid hemorrhage, and the patient subsequently undergoes clipping of an anterior choroidal artery aneurysm. Despite treatment, the patient continues to decline in the ICU, and her neurologic status is poor. The family decides (based on prior discussion with the patient) to withdraw life-sustaining treatment and undergo donation after cardiac death (DCD). You will be accompanying the patient to the operating room. Which of the following medications would not be reasonable to bring with you?
- A. Glycopyrrolate
 - B. Cisatracurium
 - C. Morphine
 - D. Lorazepam
 - E. It is inappropriate to administer any medications that may hasten death in patients undergoing DCD
58. Which of the following cranial nerve (CN) reflex sequences is correct?
- A. Oculocephalic reflex: sensory input from CN VIII, motor output from CN III/IV/VI
 - B. Corneal reflex: sensory input from CN VII, motor output from CN V
 - C. Gag reflex: sensory input from CN X, motor output from CN IX
 - D. Pupillary light reflex: sensory input from CN III, motor output from CN II
 - E. All of the above are correct
59. A 35-year-old male with severe traumatic brain injury (TBI) and isolated traumatic subarachnoid hemorrhage experiences a sudden neurologic deterioration on post-injury day 2. An emergent non-contrast head CT demonstrates no significant changes from admission imaging. The patient is afebrile and normotensive; standard mechanical ventilation with volume assist control is being performed at 6 mL/kg, a rate of 12 breaths/min, and a positive end-expiratory pressure (PEEP) of 5 cm H₂O. A recent arterial blood gas shows a PaO₂ of 120 mmHg and PaCO₂ of 40 mmHg with a pH of 7.37. Continuous EEG shows no epileptiform activity. Which of the following is the most likely cause of this patient's deterioration?
- A. Ventilator associated pneumonia
 - B. Myocardial dysfunction from the subarachnoid hemorrhage
 - C. Hypercapnea-induced increase in cerebral blood volume
 - D. Severe metabolic acidosis with respiratory compensation
 - E. Cerebral vasospasm

60. Which of the following is the most common hereditary stroke disorder?
- A. Hereditary hemorrhagic telangiectasia (HHT)
 - B. Mitochondrial encephalopathy, lactic acidosis, and stroke-like episodes (MELAS)
 - C. Cerebral autosomal-dominant arteriopathy with subcortical infarcts and leukoencephalopathy (CADASIL)
 - D. Giant cell arteritis (GCA)
 - E. Moyamoya disease
61. Which of the following is true regarding amyotrophic lateral sclerosis (ALS)?
- A. The average age of onset is in the sixth through seventh decades of life
 - B. The average life expectancy from time of diagnosis is 10 years
 - C. Riluzole increases life expectancy by 3–5 years, on average
 - D. Approximately 50% of cases are hereditary
 - E. Positive pressure ventilation plays no role in disease management
62. Which of the following patients intracranial pressure (ICP) waveform with intracerebral hemorrhage (ICH) is at highest risk for the development of late/long-term seizure activity?
- A. An 83-year-old male with a noncortical 8 mL hemorrhage
 - B. A 44-year-old female with a cortical 12 mL hemorrhage
 - C. A 68-year-old male with a cortical 21 mL hemorrhage
 - D. A 50-year-old female with a noncortical 5 mL hemorrhage who seizes twice within the first 3 days of ictus
 - E. All of the above are equally likely
63. Which of the following has been prospectively demonstrated regarding very early (<4 days) versus late (>10 days) tracheostomy for patients unlikely to be weaned from mechanical ventilation?
- A. Decreased 30-day mortality
 - B. Decreased 2-year mortality
 - C. Decreased ICU length-of-stay
 - D. Decreased rate of tracheostomy-related complications
 - E. None of the above
64. In the intracranial pressure (ICP) waveform shown (see Image 2), which of the following is represented by the black arrow?
- A. Arterial pulsation
 - B. Intracranial compliance
 - C. Aortic valve closure
 - D. Pulmonic valve closure
 - E. None of the above

Image 2 ICP waveform tracing



65. Which of the following patients with cerebellar hemorrhage has the best chances of a good functional outcome?
- A patient with a GCS of 9, no ventricular compression, moderate intraventricular extension but CSF visible in the fourth ventricle
 - A patient with a GCS of 13, a totally compressed fourth ventricle, and no intraventricular extension
 - A patient with a GCS of 11 and a noncompressed fourth ventricle completely casted with hematoma
 - A patient with a GCS of 12, a partially compressed fourth ventricle, and no intraventricular extension
 - A patient with a GCS of 7 and a compressed fourth ventricle that is completely casted
66. What is the maximum amount of time that hyperventilation-induced hypocarbia may be expected to last before the PCO_2 begins to normalize?
- 2 h
 - 4 h
 - 6 h
 - 8 h
 - 24 h
67. A 52-year-old female presents to the emergency department with a severe, sudden onset headache concerning for subarachnoid hemorrhage that started 3 days ago. A non-contrast head CT is unremarkable. Which of the following MRI sequences may be most useful in this scenario?
- T1 weighted images
 - T2 weighted images
 - Gradient echo
 - Apparent diffusion coefficient mapping
 - Diffusion-weighted imaging

68. A 29-year-old, 84 kg male is in the ICU recovering from Guillain-Barre syndrome. He is currently intubated and undergoing a spontaneous breathing trial at a continuous positive airway pressure of 5 cm H₂O with 30% inspired oxygen. His respirations are currently 20 breaths/min with an average tidal volume of 500 mL. He has not had any apneic episodes. What is this patient's rapid shallow breathing index?
- A. 40
 - B. 80
 - C. 105
 - D. 0.04
 - E. 0.08
69. All of the following are true regarding Herpes simplex encephalitis (HSE) except:
- A. The majority of asymptomatic adults are seropositive for Herpes simplex virus
 - B. There are no seasonal variations of disease incidence
 - C. Generalized seizure activity is common
 - D. It is the most common sporadic viral encephalitis in the Western world
 - E. Patients who are immunocompromised are more prone to developing HSE
70. A 50-year-old female presents to the emergency department after a fall at home. On further questioning, she endorses several months of worsening back pain and progressive paraplegia, as well as the recent onset of urinary retention. An MRI of the spine reveals an enhancing intradural extramedullary spinal cord lesion extending from the T1-T4 spinal cord level with spinal cord compression. Emergency surgical resection is performed. Which of the following is the least likely pathology of this patient's lesion?
- A. Paraganglioma
 - B. Ependymoma
 - C. Schwannoma
 - D. Neurofibroma
 - E. Meningioma
71. A 70 year-old female is intubated 5 days after hospital admission for hypoxemic respiratory failure after a witnessed aspiration event. Prior to admission, the patient lived in a nursing home, and recently was treated for left leg cellulitis with a short course of intravenous antibiotics. Her medications include metoprolol, metformin, glyburide, atorvastatin, and baby aspirin. Three days after intubation, the patient is noted to have a temperature of 102.5 °F, a blood pressure of 70/50 mmHg, a white blood cell count of $20.0 \times 10^9/L$, with purulent secretions suctioned from the endotracheal tube. You decide to initiate antibiotic therapy. Which of the following is the best antibiotic regimen to initiate at this time?
- A. Ceftriaxone and ertapenem
 - B. Imipenem, levofloxacin and vancomycin
 - C. Meropenem, cefepime, and piperacillin-tazobactam
 - D. Cefepime and daptomycin
 - E. Ceftriaxone and azithromycin

72. In patients suffering from severe traumatic brain injury (TBI) with cerebral contusions, the addition of which of the following medications has been shown to cause harm in human studies?
- A. Progesterone
 - B. Haloperidol
 - C. Corticosteroids
 - D. Furosemide
 - E. Mannitol
73. Assuming the peripheral white blood cell (WBC) count is normal, approximately how many WBCs should be expected from a suspected traumatic spinal tap in which 15,000 red blood cells (RBCs) are seen?
- A. 20–30
 - B. 100–150
 - C. 200–300
 - D. 500–750
 - E. 1000–1500
74. A 79-year-old male with a history of hypertension and hyperlipidemia presents to the emergency department with acute atraumatic bilateral lower extremity weakness over the past hour. He denies any recent illness and denies any prior difficulty with ambulation or urination. He is also complaining of severe low back pain. On exam, he has profound symmetric weakness of the bilateral lower extremities with intact vibratory sense and proprioception. He has not undergone any recent surgical procedures. Which of the following is the most likely cause of this patient's pathology?
- A. Anterior spinal artery infarction
 - B. Guillain-Barré syndrome
 - C. Transverse myelitis
 - D. Spinal epidural abscess
 - E. Spinal cord neoplasm with mass effect on the cord
75. Which of the following are accepted indications for veno-venous extracorporeal membrane oxygenation (ECMO) lung support in adults with hypoxemic respiratory failure?
- A. $\text{PaO}_2/\text{FiO}_2 < 150$ mmHg on $\text{FiO}_2 > 0.9$ and Murray Score of 1
 - B. $\text{PaO}_2/\text{FiO}_2 < 100$ mmHg on $\text{FiO}_2 0.7$ and Murray Score of 3
 - C. $\text{PaO}_2/\text{FiO}_2 < 200$ mmHg on $\text{FiO}_2 0.9$ and Murray Score of 2
 - D. $\text{PaO}_2/\text{FiO}_2 < 100$ mmHg on $\text{FiO}_2 > 0.9$ and Murray Score of 3
 - E. Oxygenation index of 29 on $\text{FiO}_2 0.8$ and Murray Score of 3
76. A 56-year-old female presents to the emergency department with new onset severe headache, visual disturbance and diplopia. Her past medical history is remarkable only for hypertension, but she is noted to be relatively hypotensive on arrival. On examination, she has a bitemporal hemianopsia, partial right

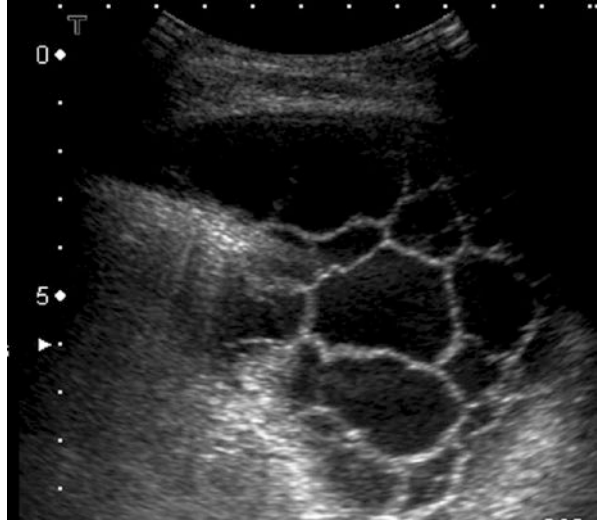- sided ptosis and limited right eye movements. Which of the following statements is true regarding the most likely diagnosis?
- A. The underlying lesion is most likely a posterior communicating artery aneurysm
 - B. This is a common presentation for the underlying lesion
 - C. This presentation is more common in men than women
 - D. Hormonal dysfunction is commonly seen
 - E. Headache is infrequently reported
77. Which of the following is true regarding primary brainstem hemorrhage?
- A. They nearly always carry a very poor prognosis
 - B. Hypertension is not a risk factor
 - C. Arteriovenous malformations (AVMs) are a frequent cause
 - D. The prognosis is better if an underlying cavernous malformation is responsible
 - E. Patients usually present with a GCS <5
78. A 55-year-old male with no past medical history presents to the emergency department with worsening dyspnea and cough for the last week. He has also been experiencing low grade fevers and diffuse arthralgias. On examination, he is in severe distress, with a respiratory rate of 30 breaths/min and an oxygen saturation of 86% on room air. Computed tomography (CT) of the chest shows diffuse ground glass opacities. The patient improves briefly with non-invasive positive pressure ventilation, but eventually requires intubation. An urgent bronchoscopy is performed, which yields progressively bloody bronchoalveolar lavage specimens. Considering the most likely diagnosis, which of the following conditions is least likely responsible for this patient's presentation?
- A. Microscopic polyangiitis
 - B. Granulomatosis with polyangiitis
 - C. Churg-Strauss syndrome
 - D. Goodpasture's syndrome
 - E. Osler-Weber-Rendu disease
79. A 51-year-old female is admitted to the ICU with a Hunt-Hess 3 subarachnoid hemorrhage secondary to a basilar tip aneurysm. She had experienced approximately 3 h of headache, nausea and vomiting prior to presenting to the hospital. 18 h after admission, she experiences a sudden deterioration and is intubated for airway protection. A non-contrast CT of the head is ordered. Which of the following would be the least likely explanation of the patient's decline in mental status?
- A. Rebleed
 - B. Hydrocephalus
 - C. Seizure
 - D. Cerebral vasospasm
 - E. All of the above are reasonable explanations

80. A 35-year-old male is currently in the ICU with a small traumatic subarachnoid hemorrhage when he begins to complain of severe epigastric abdominal pain. Laboratory evaluation demonstrates an elevated lipase, ten times the upper limit of normal, along with elevated total and direct bilirubin levels. Ultrasound demonstrates gallbladder sludge and a severely dilated common bile duct. The next most appropriate course of action is:
- A. Endoscopic retrograde cholangiopancreatography (ERCP)
 - B. Laparoscopic cholecystectomy
 - C. Percutaneous cholecystectomy
 - D. Broad spectrum antibiotics and NPO status
 - E. Transjugular intrahepatic portosystemic shunt (TIPS) procedure
81. A 63-year-old female with a history of atrial fibrillation and recent acute ischemic infarct is recovering in the ICU following the placement of a percutaneous left atrial appendage filter. Approximately 12 h post-procedure, the patient begins to complain of chest pain and shortness of breath. The most recent blood pressure is 88/45 mmHg, and an EKG is notable only for generalized low voltage without any acute ST segment abnormalities. Which of the following should be performed next?
- A. Portable chest x-ray
 - B. CT angiogram of the chest, abdomen, and pelvis
 - C. Ventilation-perfusion scan of the chest
 - D. Bedside echocardiography
 - E. Serum cardiac enzymes
82. Osborne J waves are EKG abnormalities that may be present in all of the following except:
- A. Hypothermia
 - B. Hypercalcemia
 - C. Hyponatremia
 - D. Subarachnoid hemorrhage
 - E. Idiopathic ventricular fibrillation
83. A 44-year-old female is currently hospitalized with a right subcortical intracranial hemorrhage. On MRI, the bleed appears isointense on T1 sequences and dark on T2 sequences. Based on this information, how old would you estimate the bleed to be?
- A. 2 h
 - B. 24 h
 - C. 96 h
 - D. 7 days
 - E. 21 days
84. An ambulance is en route to your ED with a 32-year-old male bull-rider who was thrown off and kicked in the chest by the bull he was riding. Per report, he was initially unconscious with a thready pulse and rapid respirations; an 18

gauge IV was placed and fluids were started. Approximately 7 min prior to arrival to the ED, he became pulseless, and CPR was started in the ambulance. On arrival, chest compressions are in progress. As he is transferred to the trauma bay stretcher, he is noted to still be unresponsive, pulseless and apneic. The cardiac monitor shows narrow complex tachycardia. Compressions are restarted. Which statement is true regarding emergent thoracotomy in this patient?

- A. ED thoracotomy has an extremely low likelihood of providing benefit to this patient
 - B. ED thoracotomy is not indicated in trauma patients presenting with cardiac arrest
 - C. ED thoracotomy should only be performed if standard protocol-driven resuscitation fails
 - D. Patients with cardiac arrest following blunt chest trauma have better outcomes with ED thoracotomy that do those following penetrating chest trauma
 - E. None of the above
85. An 80-year-old male with a history of benign prostatic hypertrophy (BPH) and coronary artery disease (CAD) is currently in the ICU in decompensated heart failure, and you decide to place a foley to closely monitor urine output. After three failed attempts by two different nurses, the staff inform you that they are unable to pass a 16 Fr Foley catheter. Which of the following should be performed next?
- A. Attempt to place a 22 Fr Foley catheter
 - B. Attempt to place a 16 Fr coude catheter
 - C. Attempt to place a 14 Fr suprapubic catheter
 - D. Attempt to place a 16 Fr catheter again following urethral lidocaine instillation
 - E. Defer foley placement
86. A 55 year-old male is admitted to the ICU with septic shock and evidence of a right lower lobe opacity on portable chest x-ray. The patient is initiated on broad spectrum empiric antibiotics for pneumonia, intravenous fluids, and vasopressors. Bedside ultrasonography of the lung is performed (see Image 3). Which of the following should be performed next?
- A. Continue current therapy
 - B. Initiate diuresis with furosemide or torsemide
 - C. Postural drainage three times daily
 - D. Tube thoracostomy
 - E. Paracentesis

Image 3 Bedside lung ultrasonography



87. Which of the following is the reference standard for the diagnosis of cerebral arteriovenous malformations?
- Conventional CT of the brain
 - Conventional MRI of the brain
 - CT angiography
 - MR angiography
 - Conventional cerebral angiography
88. A 65-year-old male presents to the emergency room after being found on the ground. His past medical history is remarkable for hypertension and hyperthyroidism. His family is unsure what medications he takes. On examination, he has a lid lag, tremor, aphasia, and dense right hemiparesis. He undergoes a non-contrast head CT and CT angiogram as part of a stroke work-up, which reveals a left holohemispheric acute subdural hematoma. After scan, he becomes more lethargic, requiring intubation. He is taken to the operating room emergently for a craniotomy for evacuation of the subdural hematoma. He undergoes uncomplicated surgery and is extubated postoperatively. A few hours after surgery, he develops sudden confusion, diarrhea, tachycardia, and is febrile to 41 °C. Which of the following may have contributed to this patient's condition?
- Subdural evacuation
 - Initial physical trauma
 - Irregular home medication use
 - CT angiography
 - All of the above
89. Slowing of neuronal activity as seen on electroencephalography (EEG) is evident when cerebral blood flow drops below which of the following values?
- 65 mL/100 g/min
 - 40 mL/100 g/min
 - 20 mL/100 g/min

- D. 10 mL/100 g/min
E. 6 mL/100 g/min
90. Which factor is not predictive of the need for intubation and mechanical ventilation in a patient with Guillain-Barre syndrome?
- A. Presence of facial palsy
B. Difficulty lifting the head off of the bed
C. Duration of time from onset of symptoms to presentation
D. Inability to stand
E. Ineffective cough
91. Patients with severe traumatic brain injury and critically elevated intracranial pressure (ICP > 25 mmHg) with accompanying respiratory failure and persistent life-threatening hypoxia can be managed by all of the following methods except:
- A. Airway pressure release ventilation (APRV)
B. Aggressive recruitment maneuvers
C. Venovenous extracorporeal membrane oxygenation (ECMO)
D. Inhaled nitric oxide
E. Prone positioning
92. A 23-year-old female presents to the emergency department with altered mental status at work for several hours. CT of the head without contrast reveals a left-sided intraparenchymal hemorrhage with significant intraventricular extension, and a CT angiogram reveals a 5 mm left anterior choroidal aneurysm. The patient undergoes a decompressive craniectomy, external ventricular drain (EVD) placement, and eventual surgical clipping of her aneurysm. Two days postoperatively, a follow-up conventional angiogram reveals no residual aneurysm. Repeat non-contrast head CT shows a stable left tempoparietal lobe hemorrhage with increased surrounding hypoattenuation, concerning for increased edema versus developing ischemia. There is persistent diffuse intraventricular hemorrhage (IVH) and ventriculomegaly. The decision is made to proceed with intrathecal tPA. Which of the following statements regarding intrathecal tPA is true?
- A. There is longstanding evidence that use of intrathecal tPA in IVH is both safe and feasible
B. There is no evidence that intrathecal tPA improves outcomes in patients with significant intraventricular hemorrhage
C. After administration of intrathecal tPA, the EVD is usually clamped for 8 h to allow circulation of the drug around the clot
D. The usual dose for IVH clot lysis is 0.9 mg/kg
E. Intrathecal tPA is currently the standard of care for the treatment of significant IVH
93. A 43-year-old female currently hospitalized with a systemic lupus erythematosus (SLE) flare has had progressive dyspnea and hemoptysis for the last 5 days. She has had low grade fevers, but no chest pain. On examination, she is in moderate respiratory distress, with an oxygen saturation of 88% on room air. Her lungs have diffuse inspiratory crackles, and chest x-ray from earlier today reveals bilateral opacities. The patient's respiratory status continues to deteriorate.

- rate, and she is intubated and transferred to the ICU. Which of the following should be performed next?
- A. Computed tomography angiography (CTA) of the chest
 - B. Bronchoscopy with bronchoalveolar lavage
 - C. Bedside echocardiogram
 - D. Tracheal aspirate and culture
 - E. Serial measurement of pulmonary plateau pressures
94. A 27-year-old male presents to the emergency department complaining of acute onset headache and vomiting over the past 3 h. He has severe neck pain on exam and complains of nausea, but is otherwise neurologically intact. A non-contrast CT of the head is performed, demonstrating thin, diffuse subarachnoid hemorrhage without ventricular involvement. What would be the correct way to characterize this patient's Hunt-Hess and modified Fisher scores?
- A. Hunt-Hess 1, modified Fisher 1
 - B. Hunt-Hess 1, modified Fisher 2
 - C. Hunt-Hess 2, modified Fisher 1
 - D. Hunt-Hess 2, modified Fisher 2
 - E. Hunt-Hess 3, modified Fisher 1
95. A 65-year-old male unrestrained driver is being evaluated after being involved in a rollover motor vehicle accident. Vital signs are as follows: heart rate 102 beats/min, blood pressure 190/100 mmHg, respiratory rate 26 breaths/min, oxygen saturation 98% (on 5L venturi mask). You notice that on inspiration, his left chest rises while his lower right chest collapses, and vice-versa on expiration. A bedside chest x-ray is performed (see Image 4). What is the most appropriate initial step in management?
- A. IV analgesia
 - B. Right-sided chest tube placement
 - C. Endotracheal intubation
 - D. Chest wall binding
 - E. Thoracotomy

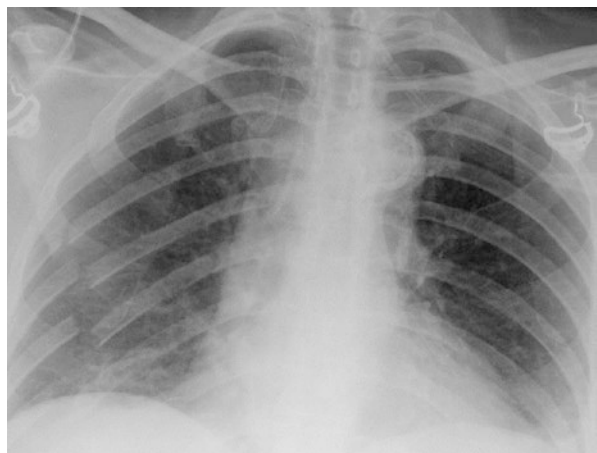


Image 4 X-ray of the chest

96. A 25-year-old female with known myasthenia gravis presents complaining of a sore throat and difficulty swallowing. Physical examination reveals severe tonsillitis, and a rapid strep test is positive. The patient is started on oral penicillin. Two days later, she returns complaining of shortness of breath and worsening difficulty swallowing. Her repeat exam demonstrates a fever of 39 °C, a peritonsillar abscess, and a negative inspiratory force (NIF) of 18. She has no bulbar weakness, no significant airway obstruction, and her voice is normal. The abscess is drained, and she is admitted to the ICU for close monitoring of respiratory status and consideration of BiPAP initiation. Her latest arterial blood gas shows no evidence of hypercarbia. What changes in her medical management would be appropriate at this time?
- A. Broaden antibiotic coverage to piperacillin-tazobactam
 - B. Proceed with endotracheal intubation
 - C. Administer systemic corticosteroids
 - D. Administer azathioprine
 - E. Initiate plasma exchange
97. An 80-year-old male with history of Parkinsonism and episodes of agitation requiring daily haloperidol presents to the emergency department during a heat wave with confusion, diaphoresis, tachypnea at 25/min and fever to 40 °C. Which of the following can be used to distinguish neuroleptic malignant syndrome from malignant hyperthermia in this patient?
- A. Testing for hallucinations and checking ionized calcium
 - B. Testing muscular tone and checking creatine phosphokinase
 - C. Testing orientation and checking arterial PCO₂
 - D. Testing judgment and checking thyroid stimulating hormone
 - E. Testing deep tendon reflexes and checking serotonin level
98. A 59-year-old female with a history of hypertension, type 2 diabetes, and prior renal transplant on immunosuppressive therapy presents to the emergency department with fever and altered mental status. A contrast-enhanced head CT demonstrates a large rim-enhancing lesion with a thick capsule and a hypodense center. Which of the following is the most likely causative organism?
- A. *Streptococcus pneumoniae*
 - B. *Staphylococcus aureus*
 - C. *Staphylococcus epidermidis*
 - D. Group B strep
 - E. *Aspergillus fumigatus*
99. You are currently in the planning stages of a new dedicated stroke unit at your hospital when the subject of capital budget items is raised. Which of the following represents a capital budget item?
- A. A dedicated MRI machine for the unit
 - B. Salaries for new stroke nursing staff

- C. Utility bills for the planned unit
 - D. Healthcare benefits for the new employees
 - E. Cost of intravenous supplies
100. A 69-year-old female presents to the emergency department with approximately 15 h of lethargy, dysarthria, and right sided weakness. She has an NIH Stroke Scale of 28 on admission, and a large hypodensity is present in the left middle cerebral artery territory on a non-contrast head CT. She is 5'4", and you calculate her predicted body weight as 55 kg. She is intubated for airway protection, with the following ventilator settings: volume control, tidal volume 480 mL, 100% FiO₂, a positive end expiratory pressure (PEEP) of 10 cmH₂O, and a rate of 14. Her venous blood gas shows a CO₂ of 32 mmHg, and her bedside oxygen saturation is 100%. To prevent the development of acute respiratory distress syndrome (ARDS), the most significant change you can make to her ventilator would be:
- A. Reduce her fraction of inspired oxygen to 0.4
 - B. Reduce her PEEP to 5 cm H₂O
 - C. Reduce her tidal volume to 360 mL
 - D. Increase her minute ventilation by 50%
 - E. Add inhaled nitric oxide to the ventilator circuit

Exam 1 Answers

Teach thy tongue to say 'I do not know', and thou shalt progress.

Moses Maimonides
(1135–1204)

1. **The correct answer is A.** Central cord syndrome is the most common form of incomplete spinal cord injury, and is usually the result of hyperextension of the cervical spine. It is seen more often in older patients, and result in weakness more pronounced in the upper extremities as compared to the lower extremities [1].
2. **The correct answer is B.** This patient presents with postoperative oozing and a markedly low fibrinogen, likely secondary to chronic alcohol abuse (fibrinogen is synthesized in the liver). Of all the answer choices, cryoprecipitate is the most appropriate option, as it contains large amounts of fibrinogen, von Willebrand factor, and factor VII. Fresh frozen plasma also contains fibrinogen, although in smaller quantities, and would require a much larger transfusion volume in order to replete this patient's fibrinogen appropriately (which may be deleterious in this patient with congestive heart failure). Additionally, this patient's INR is not likely contributing to his ongoing bleeding, so the additional factors present in plasma would be unnecessary.
3. **The correct answer is C.** This patient is in convulsive status epilepticus after having received a significant load of lorazepam but incomplete load of phenytoin. While completion of the phenytoin load is usually a judicious step, this patient has cardiovascular instability as evidence by his hypotension and frequent PVCs, and so continued phenytoin or high dose midazolam is relatively contraindicated. Blood pressure correction with fluid repletion is certainly reasonable, but eradication of his status epilepticus is paramount, and fast escalation in hemodynamic augmentation may lead to flash pulmonary edema or cardiac ischemia in this frail vasculopathic patient.
4. **The correct answer is A.** Given the presentation, this patient likely has a traumatic hemothorax, and requires large bore tube thoracostomy. 16-French is too small, as it will be more likely to clot off (compared to a 28-French tube). Surgical intervention may be necessary if there is immediate bloody drainage of >20 mL/kg or 1500 mL. The patient's airway and respiratory compromise should be addressed first before continuing the assessment and resuscitation..
5. **The correct answer is A.** Overall, respiratory failure and coagulopathy are the two risk factors most convincingly linked to stress ulceration and upper GI bleeding. Some studies suggest that enteral feeding may reduce clinically important bleeding, but there is insufficient evidence to recommend this practice across patient populations [2].
6. **The correct answer is D.** The Frank-Starling mechanism describes increases in cardiac contractility and stroke volume as a result of increases in left-ventricular end-diastolic volume (i.e., an increase in preload). Increased volume (up to a point) results in more forceful contraction by optimizing actin-myosin cross-bridging.

7. **The correct answer is A.** Total parenteral nutrition is an independent risk factor for the development of fungemia, particularly with *Candida albicans*. Frontline therapy includes 400 mg of fluconazole daily for 14 days after the first negative blood culture is obtained, and this has been shown to be as effective as amphotericin B in this setting (with far fewer side effects). The echinocandins (anidulafungin or caspofungin) are more effective against azole-resistant strains such as *Candida glabrata* and *Candida krusei* [3].
8. **The correct answer is C.** This patient has significant patient-ventilator dyssynchrony with signs of worsening respiratory failure and hemodynamic instability despite different modes of ventilation and multiple sedative agents. It is appropriate in this situation to paralyze the patient, at least temporarily, in order to restore patient-ventilator synchrony and improve the arterial blood gas. Once the patient improves, different ventilation strategies and sedatives can be explored, as well as whether or not the patient is ready for extubation.
9. **The correct answer is B.** The HELP study was a randomized trial comparing lactulose to PEG for the treatment of hepatic encephalopathy. Patients in the PEG group had better objective improvement of their encephalopathy, and over a shorter period of time. Adverse events were not reported to be significantly different in either group [4].
10. **The correct answer is C.** Central fever is a relatively common occurrence in ICU patients with neurologic insults. Central fever is more likely to present in younger patients, and to develop within the first few days after ICU admission. Conditions commonly associated with central fever include intraventricular and subarachnoid hemorrhage, intracranial neoplasms, and traumatic brain injury. Normal pressure hydrocephalus is not a typical cause of central fever [5].
11. **The correct answer is B.** Per the American Heart Association and the American College of Cardiology, PCI is the treatment of choice in the setting of acute MI with a first medical contact (FMC)-to-device time goal of less than 120 min. If this is expected to take significantly longer than 120 min, fibrinolytic therapy should be administered, provided there are no contraindications [6]. CABG is not an appropriate first-line treatment for an acute MI, nor is simply awaiting serum biomarkers and repeating the EKG at a later time. Nitroglycerine is relatively contraindicated in patients with inferior MIs due to the high rate of right ventricular infarct in these patients, who subsequently become preload dependent in order to maintain adequate systemic pressures.
12. **The correct answer is E.** This patient presents with a positive quantiferon gold test, no infectious symptoms per his family, a normal chest x-ray, and on isoniazid monotherapy as an outpatient. This is consistent with the treatment of latent tuberculosis (TB). These patients do not require negative pressure isolation (they are not contagious), nor do they require the escalation of care reserved for active TB infections.
13. **The correct answer is B.** In adults, oliguric renal failure is defined as urine output less than 400 mL in a 24 h period. The 0.5 mL/kg/h formula is used for children, while the 1 mL/kg/h formula is used for infants. Less than 50 mL in 24 h generally defined anuria.

14. **The correct answer is C.** The Berlin severity categories are based on the $\text{PaO}_2/\text{FiO}_2$ ratio on a positive end-expiratory pressure (PEEP) of ≥ 5 . Mild ARDS is defined by a $\text{PaO}_2/\text{FiO}_2$ ratio >200 but <300 ; moderate is defined by a $\text{PaO}_2/\text{FiO}_2$ ratio >100 but <200 ; and severe ARDS is defined by a $\text{PaO}_2/\text{FiO}_2$ ratio <100 . This patient's $\text{PaO}_2/\text{FiO}_2$ ratio is 107 (PaO_2 107 divided by 1.0 for 100% FiO_2). Acute lung injury is an outdated term from the older American European Consensus Conference (AECC) on ARDS and is no longer used [7].
15. **The correct answer is D.** Given this patient's history of aortic graft surgery in the setting of bright red blood per rectum, an aorto-enteric fistula must be considered, as treatment would be dramatically different than other causes of gastrointestinal bleeding. Only after this entity is ruled out might you consider GI consultation or expectant management. Given the patient is on antiplatelet agents, platelet transfusion might be reasonable, but FFP and factor VIIa have no role in the setting of otherwise normal blood work.
16. **The correct answer is E.** The femoral, popliteal, soleal and gastrocnemius veins are all considered deep veins, and a thrombus in any of these vessels would be appropriately called a deep venous thrombosis (DVT). Isolated saphenous and gastrocnemius thromboses are considered to be at a lower risk for progression and embolism, and may not require anticoagulation, but they are still considered to be DVTs. The greater and lesser saphenous veins, on the other hand, are superficial, and not part of the deep venous system.
17. **The correct answer is A.** The axons of posterior pituitary neurons are contained in the pituitary stalk. Destruction of the stalk leads to atrophy and loss of neuron function, thus affecting secretion of the posterior pituitary hormones oxytocin and vasopressin. The anterior pituitary does not have a major direct arterial blood supply; it receives blood flow from a dense capillary network. A resection of the stalk would deprive the anterior pituitary from blood flow from the median eminence, but it would continue to receive arterial input from the inferior hypophyseal artery. If the peripheral blood concentration of hypothalamic hormones is high enough, the anterior pituitary will continue to respond to them.
18. **The correct answer is B.** This patient's scan shows evidence of an intramural IVC hematoma, a laterally displaced and collapsed IVC filter, and contrast extravasation, consistent with IVC rupture likely secondary to filter placement. This patient needs urgent vascular surgery and interventional radiology consultations, in addition to blood product administration as needed. Left sided positioning may be necessary to relieve pressure on the IVC in pregnant patients, but will be of no benefit in this scenario.
19. **The correct answer is E.** Among antiepileptic medications, only phenobarbital and lacosamide are both metabolized by the liver and eliminated through the kidneys. Phenytoin, valproate and pentobarbital undergo hepatic metabolism, while levetiracetam is eliminated via the kidneys.
20. **The correct answer is B.** Meningiomas are the most common primary brain tumor in adults accounting for 1/3 of all primary brain tumors. Some meningiomas express progesterone/estrogen receptors. Meningiomas are far more

common in women, at approximately a 2:1 ratio. Ionizing radiation has been identified as an environmental risk factor. The great majority of meningiomas are located in supratentorial space [8].

21. **The correct answer is C.** According to the landmark NASCET trial data, carotid endarterectomy is clearly beneficial in symptomatic patients when the amount of stenosis exceeds 70%. Patients with 50–69% stenosis may be considered for treatment as well, although the risk/benefit analysis is more equivocal [9].
22. **The correct answer is C.** The American Heart Association guidelines on the management of massive PE define “massive” as PE in the presence of systolic pressures less than 90 mmHg for greater than 15 min, or requiring inotropic support, not due to a cause other than PE (such as hypovolemia, arrhythmia, etc.) [10].
23. **The correct answer is D.** Medications used often in the ICU setting can affect the metabolism of cyclosporine. Phenobarbital, phenytoin, carbamazepine, and modafinil increase the metabolism of cyclosporine and lead to a decrease in serum concentration. Levetiracetam does not affect serum cyclosporine levels.
24. **The correct answer is D.** In the three column theory, the anterior column is made up of the anterior vertebral body, anterior annulus fibrosus, and anterior longitudinal ligament. The middle column includes the posterior longitudinal ligament, posterior annulus fibrosus, and posterior wall of the vertebral body. Finally, the posterior column includes the posterior longitudinal ligament, posterior annulus fibrosus, and posterior wall of the vertebral body. In general, the spine is considered unstable if at least two columns are injured [11].
25. **The correct answer is E.** Rituximab (usually combined with cyclophosphamide) is considered a second line treatment for anti-NMDA encephalitis, and should be considered when there is no response to first line therapy (which includes IVIG, corticosteroids, plasma exchange, and tumor resection, if applicable) [12].
26. **The correct answer is B.** Resection of pituitary adenomas is associated with a risk of long-term HPA axis dysfunction. A morning serum cortisol level below 15 µg/dL the next day after surgery is associated with a significantly increased risk of requiring long-term glucocorticoid therapy [13].
27. **The correct answer is C.** Advantages of CRRT over intermittent hemodialysis includes a greater hemodynamic tolerability, and the ability to rapidly adjust the prescription to evolving patient needs. Disadvantages of CRRT include the higher cost of disposables, greater logistic complexity, and the difficulty of administering this type of dialysis without anticoagulation. Intermittent hemodialysis is more available and likely more familiar to nursing staff.
28. **The correct answer is C.** Many patients with acute neurologic injury will have an abnormal pattern at some point during their hospitalization. This patient has cluster breathing, which was defined in 1982 by Plum and Posner as irregular clusters of breaths followed by apneic periods of variable duration. This typically results from a lesion in the pneumotaxic center in the

upper medulla or lower pons [14]. Cheyne-Stokes respiration is a regular crescendo-decrescendo breathing pattern followed by a period of apnea. Central neurogenic hyperventilation would be sustained hyperventilation, with associated significant respiratory alkalosis. Kussmaul breathing is a deep and labored breathing pattern often secondary to metabolic acidosis, particularly diabetic ketoacidosis or renal failure. Apneustic breathing is sustained deep inspiration lasting for a few seconds followed by rapid exhalation and a brief post expiratory pause.

29. **The correct answer is A.** Apical ballooning is a characteristic feature of Takotsubo cardiomyopathy, which takes its name, tako tsubo (literally “octopus pot” in Japanese) from the abnormal appearance of the left ventricle. Bowing of the septum may be seen in cases of pulmonary embolism and right heart strain. A hypochoic area surrounding the pericardium usually denotes an effusion. Enlargement of the outflow tract is seen in patients with ascending aortic aneurysms and bicuspid aortic valves. Contrary to the diminished systolic function seen in Takotsubo cardiomyopathy, a hyperdynamic left ventricle is defined as an ejection fraction $>70\%$.
30. **The correct answer is D.** The use of angiotensin converting enzymes (ACE) inhibitors is contraindicated in pregnancy. Specifically, administration of ACE inhibitors during the third trimester is associated with a significantly increased risk of fetal renal abnormalities.
31. **The correct answer is E.** The 20/30/40 rule is traditionally used to evaluate for need for intubation in patients with Guillain Barre syndrome (GBS) and myasthenia gravis (vital capacity >20 mL/kg, peak inspiratory pressure >30 cm H₂O, peak expiratory pressure >40 cm H₂O). While this is still a good guideline for patients with GBS, there is evidence to suggest that myasthenic patients who do not have hypercarbia may be trialed on noninvasive positive pressure ventilation first, and that this may be associated with improved in-hospital outcomes [15]. Therefore, it makes sense to check this patient’s CO₂ before deciding whether to intubate her, particularly with normal oxygenation and only mild respiratory distress. The rapid shallow breathing index is one parameter used to determine extubation readiness in patients who are already intubated.
32. **The correct answer is D.** Simple head elevation is an easy maneuver that promotes venous drainage in order to reduce intracranial pressure (ICP). Mannitol and hypertonic saline also have established roles in treating cerebral edema and reducing ICP. Hypothermia, while controversial, has been shown to reduce levels of inflammatory mediators and subsequently reduce ICP. Use of hypothermia may be limited by coagulopathy and cardiac arrhythmias. Dexamethasone has no proven benefit in treating ICP in this setting and may predispose to infectious and metabolic complications [16].
33. **The correct answer is A.** One must be careful when using a hemoglobin A1c alone to diagnose diabetes. Several factors may cause an elevated A1c, including alcohol abuse (interferes with assay), chronic kidney disease (decreased erythropoiesis), and prior splenectomy (increased red cell lifespan), in which case one might erroneously conclude a patient is diabetic. On the other hand,

the A1c may be low in patients with severe hypertriglyceridemia (interferes with assay), recent blood transfusion, prior erythropoietin administration, or hemolytic anemia (decreased red cell lifespan), in which case one might erroneously conclude a patient is not a diabetic.

34. **The correct answer is B.** To calculate the estimate change in serum sodium from the infusion of 1 L of any replacement fluid, the following formula can be used: change in serum Na = (replacement fluid Na – serum Na)/(total body water + 1). Total body water (TBW) usually accounts for 60% of lean body weight for men and 50% in women. The proportion of TBW decreases with age, becoming 50% in elderly men and 45% in elderly women. Therefore, in this patient, total body water can be calculated as 50% of his weight (58 kg) which is equal to 29 L. A liter of 0.225% sodium chloride solution contains 1/4 of the amount of sodium in normal saline (i.e. $154/4 = 38.5$ mmol/L). The change in serum sodium as calculated from the formula will be $(38.5 - 177)/(29 + 1)$, which equals -4.6 mEq/L.
35. **The correct answer is A.** HIT is a serious medical condition, and needs to be treated as soon as possible once diagnosed. Although laboratory tests have not yet confirmed the presence of HIT, the suspicion of HIT is high based on her 4T score. The patient should therefore be initiated on a direct thrombin inhibitor (such as argatroban) for treatment of suspected HIT while awaiting further testing. Fondaparinux is an acceptable alternative. Warfarin therapy can be initiated after 5 days of treatment, with overlap therapy, and when platelet count is above $150 \times 10^3/\mu\text{L}$. Switching to enoxaparin therapy is not an option because of cross-reactivity between heparin antibodies and low-molecular weight heparin.
36. **The correct answer is E.** The vasculitides are a broad class of diseases that involve the inflammatory destruction of both arterial and venous blood vessels. All of the disease listed may present with central nervous system involvement.
37. **The correct answer is A.** Developmental venous anomalies are usually not demonstrated in non-enhanced CT scans, but the enlarged veins are identified after administration of contrast. MRI shows medullary veins converging on the dilated transcerebral vein and a characteristic “sunburst” pattern is seen on enhanced T1 weighted images. Cerebral angiographic findings are pathognomonic, with a “caput medusa” appearance of the radially arranged small medullary veins found during the late capillary or venous phase. Capillary telangiectasias appear as low signal intensity “black dots” on T1 and T2 weighted imaging, but are not diagnostic of these lesions. With cerebral angiography, telangiectasias can be identified in the late arterial/early capillary phase as a faint blush with an associated venous channel. Cavernous malformations have minimal blood flow and thus may not be seen on angiography, often referred to as being “angiographically occult.” Characteristic findings on T1 and T2-weighted images include a “popcorn” pattern of variable image intensities consistent with evolving blood products. A dark hemosiderin ring on T2 or gradient echo sequences at the periphery of the lesion is suggestive of remote hemorrhage.

38. **The correct answer is D.** The RIFLE classification scheme for acute kidney injury includes separate criteria for creatinine and urine output. Renal failure is defined as an increase in serum creatinine threefold, a GFR decrease by 75% or serum creatinine ≥ 4 mg/dL; a urine output < 0.3 mL/kg/h $\times 24$ h or anuria $\times 12$ h. Renal loss is defined as persistent acute renal failure or complete loss of kidney function > 4 weeks.
39. **The correct answer is D.** MVMS is an acute, rapidly progressive form of MS that usually presents in younger patients, and may be fatal within months from the time of diagnosis. When MVMS presents as a large, single brain lesion, it may be indistinguishable from a neoplastic process on conventional imaging. In these cases, craniotomy and biopsy is required to make the definitive diagnosis.
40. **The correct answer is B.** This patient is likely developing ARDS secondary to an acute aspiration related to his SAH. He would benefit most from low tidal volume ventilation, one of the few interventions proven to decrease mortality in ARDS. His ideal body weight is 80 kg; decreasing his tidal volume to 6 cc/kg yields a tidal volume of 500. Additionally, his PEEP needs to be increased in an attempt to decrease his FiO₂ requirements. If the patient does not improve with these initial measures, PEEP could be further increased and proning could be considered.
41. **The correct answer is A.** Mallory-Weiss tears are mucosal or submucosal lacerations that occur at the gastroesophageal junction, and usually extend distally into a hiatal hernia. Patients generally present with initial nonbloody vomiting followed by hematemesis. Although approximately 50% of patients hospitalized with upper GI bleeding from a Mallory-Weiss tear receive blood transfusions, the hematemesis is often mild and self-limited in patients who do not seek medical care. Occasionally, patients with continued active bleeding require endoscopic therapy and repair [17].
42. **The correct answer is B.** Primary amebic meningoencephalitis by *Naegleria fowleri* occurs after the parasite gains access to the central nervous system via the cribriform plate, typically after an individual goes swimming in a freshwater lake. Several days of a vague prodrome (including headaches, nausea and vomiting) eventually lead to confusion, coma, and within 1–2 weeks, death for the majority of individuals. Miltefosine, an antiparasitic agent originally approved for the treatment of leishmaniasis, is currently stockpiled by the Center for Disease Control (CDC) for the emergent treatment of suspected or confirmed *Naegleria* meningoencephalitis.
43. **The correct answer is B.** This vasculopathic patient presents with severe abdominal pain out of proportion to exam and a significantly elevated serum lactate, which is the classic description of ischemic colitis. Although CT arteriography is highly sensitive and often the first investigation performed in the emergency department, flexible endoscopy with tissue biopsies remains the diagnostic gold standard [18].
44. **The correct answer is C.** Nimodipine, initially developed as an antihypertensive, is rarely used for this purpose. Instead, it is primarily used to prevent DCI

in the setting of subarachnoid hemorrhage, administered enterally every 4 h. It was previously studied in the setting of preeclampsia, but proved inferior to magnesium [19]. It has also been used to preserve facial and cochlear nerve function following schwannoma surgery, with mixed results in several studies [20].

45. **The correct answer is C.** Mitochondrial encephalopathy, lactic acidosis, and stroke-like episodes (MELAS) is a rare mitochondrial disorder characterized by headaches, muscle weakness, seizures, vomiting, and altered mental status. The majority of cases are caused by mutations in the MT-TL1 gene, and there is usually a family history of similar symptoms (though rare spontaneous cases are reported in the literature). Like other mitochondrial cytopathies, the inheritance pattern is maternal. Unfortunately, there is no cure, and the disease is both progressive and fatal. Because MELAS is so rare, and the clinical presentation is so varied, it is often misdiagnosed.
46. **The correct answer is B.** The patient has a partial central airway obstruction secondary to the compressive tumor. Although he is hemodynamically stable and is able to maintain his airway at this time, the patient should be admitted to an intensive care unit for aggressive monitoring as decompensation can happen quickly and unpredictably. Racemic epinephrine works both by stimulating alpha adrenergic receptors, resulting in mucosal vasoconstriction and by stimulating beta adrenergic receptors, resulting in relaxation of the bronchial smooth muscle. Racemic epinephrine has been proven to be most beneficial in treating laryngotracheobronchitis (croup) in the pediatric population, as well as laryngeal edema. Heliox is a 70:30 mixture of helium and oxygen, and is effective in reducing the work of breathing by decreasing airway resistance to turbulent flow generated across an airway obstruction. It has been used in post extubation laryngeal edema, tracheal stenosis, extrinsic compression, and acute severe asthma attacks [21]. Corticosteroids work by reducing airway edema, but this patient does not have any suggestion of airway edema; he has an airway obstruction secondary to mass effect. Also, they take several hours to take effect, and therefore steroid administration is not the most appropriate for the immediate relief of symptoms. The patient has lung adenocarcinoma that involves a mediastinal structure, and is unlikely to be a candidate for resection. Also, regardless of the resectability of this patient's mass, surgery is not an immediate solution to the patient's symptoms. Inhaled β_2 agonists will not provide relief, as the patient has a central airway obstruction.
47. **The correct answer is E.** MICs are used to report the sensitivity of an organism to various antimicrobial agents. Each agent has its own reference cutoff to determine whether the organism will be reported as sensitive, intermediate, or resistant to that agent. MICs cutoffs are not meant to be used to compare antimicrobial agents, and the absolute MIC does not take into account several other factors such as pharmacodynamics and the site of infection. Based only on a chart of antibiotic susceptibilities, none of the antibiotics listed can be considered "most likely" to be effective.

48. **The correct answer is E.** Vomiting, nasogastric suction, diuretic use, or mineralocorticoid excess may all result in the development of metabolic alkalosis. Blood loss, on the other hand, may result in a metabolic acidosis if it is significant enough to impair oxygen delivery.
49. **The correct answer is E.** When intubating a patient with TBI, the primary goals are to avoid causing or worsening secondary brain injury. As such, avoidance of hypoxia, hypotension, spikes in blood pressure, and elevated ICP are important. Lidocaine has often been used as pretreatment for the purposes of preventing ICP spikes during intubation; however, no direct evidence supports this approach in the setting of traumatic brain injury, nor is there evidence of any significant effect on patient outcomes [22].
50. **The correct answer is D.** Treatment for normal pressure hydrocephalus may include a lumbar drain trial, which involves lumbar drain placement and spinal fluid drainage for approximately 2–3 days. This is followed by physical therapy and neuropsychiatric testing to determine if there is any improvement in the patient's clinical status compared to baseline. This patient did not benefit from lumbar drain placement; therefore, the correct answer is to discontinue the drain. The patient is unlikely to benefit from additional drainage, or from a repeat trial in 3 months.
51. **The correct answer is E.** It has long been recognized that brain metastases from certain malignancies are at a higher risk of bleeding episodes [23]. These include melanoma, renal cell carcinoma, choriocarcinoma, and thyroid carcinoma. Breast metastases are not considered high-risk lesions.
52. **The correct answer is A.** This patient presents with a cerebral venous sinus thrombosis in the face of antiplatelet and anticoagulation therapy, likely the result of her polycythemia vera. Given the history of HIT, it would be inappropriate to give this patient low molecular weight or unfractionated heparin; fonaparinux is an appropriate alternative. Apixaban and eptifibatide are not used in this setting.
53. **The correct answer is C.** Bougie-guided intubation may be necessary in the absence of an adequate view of the vocal cords. The upturned end is slid under the epiglottis, feeling for the tracheal rings and eventual resistance when the bougie hits the carina. The laryngoscope blade can then be removed, and an endotracheal tube can be advanced along the bougie into the trachea.
54. **The correct answer is D.** Autonomy involves a respect for a patient's wishes regarding their care, while the distinct (but closely related) principle of fidelity involves the concept that physicians and nurses will stay true to their promises and agreements. Beneficence refers to acts of compassion or healing, while non-maleficence refers to avoiding acts which may cause a patient harm. Justice refers to the fair and equal distribution of healthcare resources.
55. **The correct answer is D.** Many interventions have been studied in an attempt to reduce rates of iatrogenic ventriculitis. Routine CSF surveillance has not been demonstrated to be effective, either on a daily or 3-day interval basis. Similarly, routine catheter exchange has also failed to show benefit. Insertion site antibiotic wafers have been used in the setting of indwelling vascular

- catheters, but not ventriculostomy catheters. There is evidence that both antibiotic-coated and silver-coated catheters may reduce rates of ventriculitis [24], along with bundled protocols regarding catheter insertion and maintenance.
56. **The correct answer is E.** Treatment of aspiration pneumonia should include coverage of anaerobes and typical oral flora. Certain antibiotics, including aminoglycosides, fluoroquinolones, erythromycin, and tetracycline can aggravate weakness in myasthenic crisis, and should be avoided. Cefepime and azithromycin may be an effective regimen for community acquired pneumonia, but probably do not provide adequate anaerobic coverage.
57. **The correct answer is B.** Following withdrawal of life support, it is appropriate to administer any medications you would otherwise administer to a patient for purposes of palliation. This includes pre-extubation glycopyrrolate to dry secretions, as well as benzodiazepines or opiates titrated to patient comfort (or surrogates of possible discomfort, such as significant hypertension or tachycardia). These drugs should never be administered solely for the purposes of hastening death and facilitating organ transplantation. Accordingly, paralytics serve no purpose other than inducing respiratory arrest, and may mask signs of patient discomfort.
58. **The correct answer is A.** The oculocephalic reflex involves sensory input from CN VIII and motor output from CN III/IV/VI. The corneal reflex involves sensory input from CN V and motor output from CN VII. The gag reflex involves sensory input from CN IX and motor output from CN X. Finally, the pupillary light reflex involves sensory input from CN II and motor output from CN III.
59. **The correct answer is E.** Up to one third of patients with traumatic subarachnoid hemorrhage may develop post-injury cerebral vasospasm. Unlike aneurysmal subarachnoid hemorrhage, TBI-induced cerebral vasospasm often occurs earlier, and can be seen as early as post-injury day 2 [25].
60. **The correct answer is C.** There are numerous hereditary disorders that predispose patients to developing strokes, particularly at younger ages than typical atherosclerotic or embolic processes. The most common of these is CADASIL, in which a defect in the NOTCH3 gene causes abnormal protein build-up in vascular smooth muscle cells. HHT, MELAS, Moyamoya, and GCA are less common hereditary stroke disorders [26].
61. **The correct answer is A.** ALS is a chronic disease characterized by motor neuron degeneration that affects patients in the sixth and seventh decade of life, on average. Unfortunately, most patient will die within 5 years of diagnosis. The majority of cases are sporadic, not hereditary. Disease management is largely supportive, including positive pressure ventilation and the use of riluzole (which may delay ventilator dependence and prolong survival by 2–3 months [27]).
62. **The correct answer is C.** The CAVE score may predict which ICH patients are at risk for the development of late seizures. Patients get 1 point for each of the following: age >65, hemorrhage volume >10 mL, cortical location, and

- seizure activity in the first 7 days following ictus. A higher score denotes a progressively higher risk of developing late seizures [28].
63. **The correct answer is E.** The TracMan study was a large, prospective, randomized, multicenter trial of very early (<4 days) versus late (>10 days, if still indicated) tracheostomy among ICU patients identified by the treating physician as likely to require >7 days of mechanical ventilation. The study did not demonstrate any significant differences in 30-day or 2-year mortality, nor were there any differences in ICU length-of-stay or the rate of tracheostomy-related complications [29]. It is noteworthy, however, that a recent Cochrane review using a much broader and more liberal definition of early vs. late tracheostomy (<10 days versus >10 days) found moderate quality evidence for a mortality benefit in the former group [30].
 64. **The correct answer is B.** A normal ICP waveform has three peaks of descending amplitude. The first represents arterial pulsation, the second represents intracranial compliance, and the third represents aortic valve closure. Pulmonic valve closure is not indicated in the waveform.
 65. **The correct answer is A.** A study by Kiriollos developed a risk-stratification schema for cerebellar hemorrhages based on the appearance of the fourth ventricle. Grade I patients had a fourth ventricle that was midline, non-compressed, and contained visible CSF. These patients uniformly had good long-term outcomes. Grade II patients had fourth ventricles that were partially compressed or displaced, with intermediate prognoses depending on further details of their presentation. In the published protocol those with GCS > 13 were monitored, and with worsening GCS were either given an EVD (if they had hydrocephalus) or decompression (if no hydrocephalus or persistent poor GCS after EVD placement). Grade III patients had either complete obliteration of the fourth ventricle or partial obliteration with compression of the pons and prepontine cistern, and had the worst prognoses with 38% good outcomes if GCS > 8 and 17% chance of good outcome with GCS < 8. Patient A is the only patient described with a Grade I ventricle and therefore has the best prognosis [31].
 66. **The correct answer is E.** Induced hyperventilation results in hypocarbia that may last anywhere up to 24 h before PCO₂ levels normalize. This phenomenon is a result of extensive bicarbonate buffering, as the brain attempts to return the intracellular and extracellular pH back to baseline levels [32].
 67. **The correct answer is C.** Noncontrast head CT is the initial test of choice for the evaluation of acute subarachnoid hemorrhage, but becomes less sensitive over time, particularly several days out from the ictus. In this setting, evidence of hemorrhage may still be seen on MRI gradient echo sequences.
 68. **The correct answer is A.** The rapid shallow breathing index (RSBI) is one parameter used to determine extubation readiness. In general, a cutoff of less than 105 is used to identify patients who are more likely to be extubated successfully. The formula is f/V_t , or respiratory rate divided by tidal volume. In this case, the RSBI is 40 (20/0.5 L).
 69. **The correct answer is E.** Although immunocompromised patients may present with more atypical and aggressive variants of the disease, HSE is not more

common in these patients, and it is not considered an opportunistic infection. All of the other answer choices are correct [33].

70. **The correct answer is B.** The most common intradural extramedullary tumors include meningiomas, schwannoma, and neurofibromas. Paragangliomas may also occur, though are less common. Intradural extramedullary ependymomas are very rare, existing in only a handful of case reports [34].
71. **The correct answer is B.** Healthcare associated infections are almost routine in today's critical care units, and the increasing rates of multi-drug resistant (MDR) organisms is taking a toll on our clinical and economic systems. Ventilator associated pneumonia (VAP) is a subtype of healthcare associated infection, and is defined by the diagnosis of clinical pneumonia 48–72 h after intubation. Duration of mechanical ventilation, antibiotic use history, geography, co-morbidities, and the epidemiology of the ICU population all determine the etiology of a nosocomial pneumonia. Aerobic gram negative bacilli are the most common pathogens causing VAP. These include *Klebsiella*, *Escherichia coli*, *Pseudomonas*, *Acinetobacter*, *Stenotrophomonas*, *Enterobacter*, *Citrobacter*, *Proteus*, and *Serratia* species. *Pseudomonas* is the most prevalent pathogen recovered in VAP. With the emergence of MDR organisms, *Methicillin resistant Staphylococcus aureus* (MRSA) is also an important etiology of VAP, as well as anaerobes such as *Bacteroides* species. Community acquired pathogens, including *Streptococcus* and *Haemophilus* species are less likely to cause VAP. The antibiotic regimen that should be initiated depends on the suspicion that a patient harbors MDR pathogens. Usually, if a patient is hospitalized for more than 5 days, the possibility of MDR pathogens is high, particularly if a patient has been on intravenous antibiotic therapy recently. The first line treatment would include an antipseudomonal cephalosporin *or* an antipseudomonal carbapenem *or* an antipseudomonal penicillin with Beta lactamase inhibitor, *plus* an antipseudomonal fluoroquinolone *or* aminoglycoside, *plus* an anti-MRSA agent [35]. Azithromycin should be considered for atypical coverage if *Legionella* is high on the differential and in severely ill patients. If an MDR pathogen is not suspected, a third-generation cephalosporin *or* respiratory fluoroquinolone *or* non-antipseudomonal carbapenem should be considered. Daptomycin is not appropriate to use for pulmonary infections, as it is inactivated by surfactant.
72. **The correct answer is C.** Data from the CRASH TBI trial clearly demonstrated harm with the use of corticosteroids after blunt TBI [36]. The PROTECT III trial was stopped early for futility, but no harm was detected in patients receiving progesterone [37]. Furosemide and mannitol are common therapies for the management of intracranial pressure.
73. **The correct answer is A.** Assuming the peripheral WBC is normal, one would expect a ratio of RBC:WBC between 500:1 and 750:1. Therefore, if a suspected traumatic tap results in 15,000 RBCs in the sample, one should expect approximately 20–30 WBCs to be present as well.
74. **The correct answer is A.** An anterior spinal artery infarction usually presents as sudden onset severe low back pain with bilateral lower extremity weakness

and preserved proprioception and vibratory sense. The other answer choices listed usually have a more insidious onset, or are preceded by an infectious process (i.e. Guillain-Barré syndrome and transverse myelitis). Spontaneous spinal epidural abscess is rare, and is usually the result of recent surgery/manipulation, intravenous drug use, or systemic infection.

75. **The correct answer is D.** Extracorporeal Life Support Organization (ELSO) guidelines suggest that consideration for ECMO support be given to adult patients with predicted mortality exceeding 50% (i.e. $\text{PaO}_2/\text{FiO}_2 < 150$ mm Hg on a $\text{FiO}_2 > 0.9$ and Murray Score of 2 or 3) [38].
76. **The correct answer is C.** This patient has pituitary apoplexy. Though a subarachnoid hemorrhage from a right posterior communicating aneurysm may give similar findings, it would not give the patient bitemporal hemianopsia. Pituitary apoplexy is a rare neurosurgical and endocrine emergency and is more commonly seen in men than women. Though the patient in this vignette may have central adrenal insufficiency, clinical hormonal deficiency is uncommon. Headache is the most common symptom [39].
77. **The correct answer is D.** In a large case series examining patients with primary brainstem hemorrhage, individuals with underlying cavernous malformations had a 95% chance of having a good functional outcome ($\text{mRS} \leq 2$ at 3 month follow-up), as opposed to patients with hypertensive hemorrhages (who had only a 38% chance of a good functional outcome). Each group formed roughly 40% of the population. AVM was an infrequent cause, accounting for only 4% of cases. The mean GCS at presentation was 13, although a wide range was noted [40].
78. **The correct answer is E.** This patient has diffuse alveolar hemorrhage, characterized by diffuse ground glass opacities on chest CT coupled with progressively bloody bronchoalveolar lavage specimens. Autoimmune processes and vasculitides are high on the differential diagnosis. Osler-Weber-Rendu, also known as hereditary hemorrhagic telangiectasis, may present with pulmonary arteriovenous malformations, but these typically present with dyspnea and cyanosis, not DAH [41].
79. **The correct answer is D.** This patient has experienced an aneurismal subarachnoid hemorrhage, and is within the first 24 h of symptom onset. Rebleed, hydrocephalus and seizures are all reasonable explanations for her decline. The risk of vasospasm, on the other hand, generally does not occur until at least 3 days after ictus, peaks around 7 days, and fades around day 14. Hyperacute vasospasm has been described in both animal models and case series of intraoperative aneurysm rupture, but this occurs within minutes of ictus, not 18 h later [42].
80. **The correct answer is A.** The patient presents with likely gallstone pancreatitis and biliary obstruction. Although somewhat controversial, patients with severe pancreatitis and overt biliary obstruction may benefit from early ERCP. Conservative approaches may be more appropriate for patients with milder disease. Once resolution of this initial attack is achieved, it may then be appropriate to perform a cholecystectomy to prevent recurrent attacks [43].

81. **The correct answer is D.** The most common overall complication of percutaneous left atrial appendage filter placement is the development of a pericardial effusion, which usually occurs in the first 24 h after the procedure. Shortness of breath, hypotension, and low voltage on the EKG are suggestive of the diagnosis, with echocardiography being the simplest and most effective diagnostic modality.
82. **The correct answer is C.** J waves are seen on EKG as positive deflections at the J point, and are classically associated with severe hypothermia. However, J waves may be present in a number of other conditions. These include hypercalcemia, significant neurologic injuries (including subarachnoid hemorrhage), and cases of idiopathic ventricular fibrillation. Hyponatremia is not associated with J wave formation.
83. **The correct answer is B.** The simplified mnemonic “iddy bidy baby doo-doo” is often used when estimating the age of bleeding as seen on MRI T1 and T2 sequences. Isointense on T1 and dark on T2 (iddy) is usually 7 h to 3 days old. Bright on T1 and dark on T2 (bidy) is usually 3–7 days old. Bright on both T1 and T2 (baby) is usually 7 days to 3 weeks. Dark on both T1 and T2 (doodoo) is usually >3 weeks old. Hyperacute bleeds (<7 h) are isointense on T1 and bright on T2.
84. **The correct answer is A.** The cornerstone of management for patients with trauma-related cardiopulmonary arrest is emergent thoracotomy performed in the ED. The goal is to rapidly identify and intervene on intrathoracic hemorrhage. However, the procedure has the highest outcome yield in patients with penetrating trauma with onset of cardiac arrest in the ED. Patients presenting to the hospital already in cardiopulmonary arrest, particularly following blunt thoracic trauma, have a very low likelihood of survival, with or without emergent thoracotomy. The likelihood of favorable neurologic outcomes in this patient population is even more dismal. A systematic review of the literature performed by Eastern Society for the Surgery of Trauma (EAST) for their Clinical Practice Guidelines revealed 1.4% hospital survival and 0.1% survival neurologically intact after emergent thoracotomy for patients with blunt trauma presenting to the hospital without signs of life [44].
85. **The correct answer is B.** Difficulty passing a foley catheter is common in patients with a history of BPH. Coude tip catheters are specifically designed to allow the catheter to more easily pass the enlarged prostate. Repeatedly attempting to pass the same catheter, or a larger non-coude catheter, would be less likely to succeed, and would expose the patient to an increased risk of urethral trauma. Suprapubic catheterization is reserved for long term use, and in emergent cases of urinary retention recalcitrant to other remedies.
86. **The correct answer is D.** This patient has a complicated parapneumonic pleural effusion seen as multiple fibrinous septations within the anechoic pleural effusion, and requires placement of a chest tube for drainage. Point-of-care ultrasound (POCUS) allows the distinction between effusion and lung consolidation, and is more accurate at detecting pleural effusion in comparison with bedside chest X-rays. Sensitivity of chest x-ray decreases in more supine

positioning, while POCUS can detect effusions as small as 20 mL. Although definitive distinction between transudative and exudative pleural effusion requires thoracentesis, POCUS can suggest the nature of pleural effusion. The effusion can appear as anechoic (black), complex non-septated (black with white strands), complex septated (black with white septae), or homogeneously echogenic (white). In general, the presence of a complex pleural effusion suggests exudative effusion, whereas an anechogenic effusion is likely transudative; however, clinical correlation is warranted since exudative effusions may be anechoic, while longstanding transudative effusion may appear as complex non-septated [45]. Continuing only medical therapy with antibiotics or diuresis would not be appropriate, since this complex pleural effusion requires drainage.

87. **The correct answer is E.** Conventional cerebral angiography with catheter is considered the reference standard for the diagnosis of arteriovenous malformations. However, non-invasive vascular imaging (such as CT or MR angiography) is appropriate as an initial screening tool, or in cases where conventional angiography is unavailable.
88. **The correct answer is E.** This patient has a history of hyperthyroidism, and is now exhibiting symptoms consistent with thyroid storm. Surgery, trauma, irregular use of antithyroid medication, or iodine load (in the form of contrast material) may all be precipitating factors.
89. **The correct answer is C.** Cerebral blood flow is normal at 50 mL/100 g/min. Once it drops below 20 mL/100 g/min, slowing is evident on EEG, and the EEG may be isoelectric below 15 mL/100 g/min. Neuronal cell death will occur when CBF drops below 6 mL/100 g/min.
90. **The correct answer is A.** In a retrospective study analyzing 43 different clinical variables in GBS patients, the only ones which were found to have independent predictive value for need for mechanical ventilation were: inability to stand, inability to lift the head off the bed, inability to lift the elbows off the bed, duration from symptom onset to presentation <7 days, ineffective cough, and elevated liver enzymes. Other studies have also found bulbar dysfunction to be a predictor of need for intubation [46].
91. **The correct answer is E.** Case reports have demonstrated the feasibility of APRV in patients with increased ICP. Recruitment maneuvers improve alveolar ventilation, improve compliance, and may lessen ICP when effective. Venovenous ECMO can be performed without the use of anticoagulation, and is therefore considered a possibility as a rescue technique in severe TBI. Nitric oxide does not increase ICP, and may improve ventilation/perfusion matching in severe lung injury. Prone positioning may lead to significant increases in ICP and a critical decrease in CPP, making it the least safe option in a patient with elevated ICP [47].
92. **The correct answer is A.** There have been multiple cases series and reports over the past 20 years demonstrating the safety and feasibility of intrathecal tPA for the treatment of IVH. The CLEAR-III trial, a large randomized multicenter prospective trial evaluating the effect of intrathecal tPA on outcomes in

IVH, has already finished enrolling patients, and results are pending. After administration of tPA, the EVD is usually clamped for 1 h to allow the drug to circulate (not 8 h). 0.9 mg/kg is the intravenous tPA dose given for acute ischemic stroke, not IVH. Finally, although preliminary results are promising, tPA cannot be described as the current standard of care [48, 49].

93. **The correct answer is B.** In an SLE patient with hemoptysis, worsening hypoxemia, and bilateral infiltrates on chest x-ray, it is important to rule out diffuse alveolar hemorrhage (DAH). DAH affects the majority of the alveolar capillary surface, and is a medical emergency that often leads to acute respiratory failure. Progressively bloody return is seen on bronchoalveolar lavage. It is imperative that DAH is differentiated from other causes of hemoptysis in SLE patients, such as acute lupus pneumonitis, and bronchoscopy with bronchoalveolar lavage is the only way to confirm this. CT pulmonary angiography would be ideal for diagnosing pulmonary embolism, but hemoptysis with diffuse bilateral infiltrates makes DAH more likely. Echocardiogram may help diagnose heart failure, which may present with diffuse infiltrates and pink, frothy sputum, but it would not help rule out DAH.
94. **The correct answer is C.** The Hunt-Hess scoring system classifies the severity of subarachnoid hemorrhage based on the clinical exam, from 1 (least severe) to 5 (most severe). Hunt-Hess 1 is defined by either no symptoms, or mild headache/neck pain; Hunt-Hess 2 is defined by severe headache/neck pain, with or without cranial nerve palsies, but no other neurologic deficit; Hunt-Hess 3 is defined drowsiness/confusion, with mild focal deficits; Hunt-Hess 4 is defined by stupor, with moderate to severe hemiparesis; and Hunt-Hess 5 is defined by coma and decerebrate posturing. The modified Fisher scale, on the other hand, is based entirely on the thickness of subarachnoid blood and the presence or absence of blood in the lateral ventricles. The modified Fisher score is as follows: modified Fisher 0, no subarachnoid blood or IVH; modified Fisher 1, thin (<1 mm) subarachnoid blood, no IVH; modified Fisher 2, thick subarachnoid blood, no IVH; modified Fisher 3, thin subarachnoid blood with IVH; and modified Fisher 4, thick subarachnoid blood with IVH [50].
95. **The correct answer is A.** The chest x-ray shows multiple right sided rib fracture, with three consecutive ribs fractured in two places, known as “flail chest”. Primary management includes analgesia and incentive spirometry to prevent atelectasis and pneumonia. There is no role for chest wall binding or thoracotomy, and the need for intubation is rare.
96. **The correct answer is E.** As evidenced by her significantly decreased NIF, this patient is having a myasthenic crisis, likely exacerbated by infection, and requires emergent therapy (plasmapheresis or IVIG) to decrease her chances of requiring intubation. Given her absence of bulbar weakness, she does not require intubation, but may benefit from BiPAP if she develops ongoing respiratory insufficiency. Broadening her antibiotic coverage is unnecessary; group A strep has not demonstrated significant penicillin resistance and the reason for failure is likely inadequate source control of her abscess, which has now

been remedied. Corticosteroids may be helpful for symptom control for strep throat and for longer-term myasthenia control, but does not directly address the most immediately life-threatening issue. Azathioprine may be useful in chronic disease management, but is not the best choice for this acute, life-threatening decompensation.

97. **The correct answer is B.** Neuroleptic malignant syndrome and malignant hyperthermia may both present with fever, diaphoresis, confusion, and tachypnea. Muscular rigidity and an elevation in serum creatine phosphokinase make neuroleptic malignant syndrome the more likely diagnosis.
98. **The correct answer is E.** Although bacterial infections, particularly *Streptococcus pneumoniae*, are common causes of cerebral abscesses overall, fungal pathogens account for the overwhelming majority of cases in patients who have received solid organ transplants. These include primarily aspergillus and candida species [51].
99. **The correct answer is A.** Capital budgeting covers investment in fixed assets. This may include machinery, technology, building space, or safety upgrades. Salaries, benefits, and ongoing utilities and supplies are not capital budget items.
100. **The correct answer is C.** Even brief exposures to excessive tidal volumes have been shown to be related to the development of ventilator associated lung injury and ARDS; this patient is currently hypocarbic, and is receiving >8 cc/mL tidal volume. While it would certainly be reasonable to examine , whether her fraction of inspired oxygen or PEEP should be titrated down, the most important first step would be to adjust her tidal volume appropriately [52].

References

1. Nowak DD, Lee JK, Gelb DE, Poelstra KA, Ludwig SC. Central cord syndrome. *J Am Acad Orthop Surg.* 2009;17(12):756–65.
2. Barletta J, Bruno J, Buckley M, Cook D. Stress ulcer prophylaxis. *Crit Care Med.* 2016;44(7):1395–405.
3. Mermel LA, Allon M, Bouza E, et al. Clinical practice guidelines for the diagnosis and management of intravascular catheter-related infection: 2009 update by the Infectious Diseases Society of America. *Clin Infect Dis.* 2009;49(1):1–45.
4. Rahimi RS, Singal AG, Cuthbert JA, Rockey DC. Lactulose vs polyethylene glycol 3350—electrolyte solution for treatment of overt hepatic encephalopathy: the HELP randomized clinical trial. *JAMA Intern Med.* 2014;174(11):1727–33.
5. Hocker SE, Tian L, Li G, Steckelberg JM, Mandrekar JN, Rabinstein AA. Indicators of central fever in the neurologic intensive care unit. *JAMA Neurol.* 2013;70(12):1499–504.
6. O'gara PT, Kushner FG, Ascheim DD, et al. 2013 ACCF/AHA guideline for the management of ST-elevation myocardial infarction: a report of the American College of Cardiology Foundation/American Heart Association Task Force on Practice Guidelines. *J Am Coll Cardiol.* 2013;61(4):e78–140.
7. Ranieri VM, Rubenfeld GD, Thompson BT, et al. Acute respiratory distress syndrome: the Berlin definition. *JAMA.* 2012;307(23):2526–33.
8. Wiemels J, Wrensch M, Claus EB. Epidemiology and etiology of meningioma. *J Neuro-Oncol.* 2010;99(3):307–14.

9. Barnett HJ, Taylor DW, Eliasziw M, et al. Benefit of carotid endarterectomy in patients with symptomatic moderate or severe stenosis. North American Symptomatic Carotid Endarterectomy Trial Collaborators. *N Engl J Med*. 1998;339(20):1415–25.
10. Jaff MR, Mcmurtry MS, Archer SL, et al. Management of massive and submassive pulmonary embolism, iliofemoral deep vein thrombosis, and chronic thromboembolic pulmonary hypertension: a scientific statement from the American Heart Association. *Circulation*. 2011;123(16):1788–830.
11. Denis F. The three column spine and its significance in the classification of acute thoracolumbar spinal injuries. *Spine*. 1983;8(8):817–31.
12. Dalmau J, Lancaster E, Martinez-hernandez E, Rosenfeld MR, Balice-gordon R. Clinical experience and laboratory investigations in patients with anti-NMDAR encephalitis. *Lancet Neurol*. 2011;10(1):63–74.
13. Marko NF, Gonugunta VA, Hamrahian AH, Usmani A, Mayberg MR, Weil RJ. Use of morning serum cortisol level after transsphenoidal resection of pituitary adenoma to predict the need for long-term glucocorticoid supplementation. *J Neurosurg*. 2009;111(3):540–4.
14. Freeman WD, Sen S, Roy TK, Wijdicks EF. Cluster breathing associated with bihemispheric infarction and sparing of the brainstem. *Arch Neurol*. 2006;63(10):1487–90.
15. Seneviratne J, Mandrekar J, Wijdicks EF, Rabinstein AA. Noninvasive ventilation in myasthenic crisis. *Arch Neurol*. 2008;65(1):54–8.
16. Polson J, Lee WM. AASLD position paper: the management of acute liver failure. *Hepatology*. 2005;41(5):1179–97.
17. Kim HS. Endoscopic management of Mallory-Weiss tearing. *Clin Endosc*. 2015;48(2):102–5.
18. Washington C, Carmichael JC. Management of ischemic colitis. *Clin Colon Rectal Surg*. 2012;25(4):228–35.
19. Belfort MA, Anthony J, Saade GR, Allen JC. A comparison of magnesium sulfate and nimodipine for the prevention of eclampsia. *N Engl J Med*. 2003;348(4):304–11.
20. Scheller C, Wienke A, Tatagiba M, et al. Prophylactic nimodipine treatment for cochlear and facial nerve preservation after vestibular schwannoma surgery: a randomized multicenter Phase III trial. *J Neurosurg*. 2016;124(3):657–64.
21. Diehl JL, Peigne V, Guérot E, Faisy C, Lecourt L, Mercat A. Helium in the adult critical care setting. *Ann Intensive Care*. 2011;1(1):24.
22. Robinson N, Clancy M. In patients with head injury undergoing rapid sequence intubation, does pretreatment with intravenous lignocaine/lidocaine lead to an improved neurological outcome? A review of the literature. *Emerg Med J*. 2001;18(6):453–7.
23. Mandybur TI. Intracranial hemorrhage caused by metastatic tumors. *Neurology*. 1977;27(7):650–5.
24. Cui Z, Wang B, Zhong Z, et al. Impact of antibiotic- and silver-impregnated external ventricular drains on the risk of infections: a systematic review and meta-analysis. *Am J Infect Control*. 2015;43(7):e23–32.
25. Armin SS, Colohan AR, Zhang JH. Vasospasm in traumatic brain injury. *Acta Neurochir Suppl*. 2008;104(13):421–5.
26. Ruten-jacobs LC, Traylor M, Adib-samii P, et al. Common NOTCH3 variants and cerebral small-vessel disease. *Stroke*. 2015;46(6):1482–7.
27. Miller RG, Mitchell JD, Moore DH. Riluzole for amyotrophic lateral sclerosis (ALS)/motor neuron disease (MND). *Cochrane Database Syst Rev*. 2012;3:CD001447.
28. Haapaniemi E, Strbian D, Rossi C, et al. The CAVE score for predicting late seizures after intracerebral hemorrhage. *Stroke*. 2014;45(7):1971–6.
29. Young D, Harrison DA, Cuthbertson BH, Rowan K. Effect of early vs late tracheostomy placement on survival in patients receiving mechanical ventilation: the TracMan randomized trial. *JAMA*. 2013;309(20):2121–9.
30. Andriolo BN, Andriolo RB, Saconato H, Atallah ÁN, Valente O. Early versus late tracheostomy for critically ill patients. *Cochrane Database Syst Rev*. 2015;1:CD007271.
31. Yanaka K, Matsumaru Y, Nose T. Management of spontaneous cerebellar hematomas: a prospective treatment protocol. *Neurosurgery*. 2002;51(2):524–5.

32. Pickard JD, Czosnyka M. Management of raised intracranial pressure. *J Neurol Neurosurg Psychiatry*. 1993;56(8):845–58.
33. Tan IL, McArthur JC, Venkatesan A, Nath A. Atypical manifestations and poor outcome of herpes simplex encephalitis in the immunocompromised. *Neurology*. 2012;79(21):2125–32.
34. Weinstein GM, Arkun K, Kryzanski J, Lanfranchi M, Gupta GK, Bedi H. Spinal intradural extramedullary ependymoma with astrocytoma component: a case report and review of the literature. *Case Rep Pathol*. 2016;2016:3534791.
35. Kalil AC, Metersky ML, Klompas M, et al. Management of Adults With Hospital-acquired and Ventilator-associated Pneumonia: 2016 Clinical practice guidelines by the Infectious Diseases Society of America and the American Thoracic Society. *Clin Infect Dis*. 2016;63(5):e61–e111.
36. Roberts I, Yates D, Sandercock P, et al. Effect of intravenous corticosteroids on death within 14 days in 10008 adults with clinically significant head injury (MRC CRASH trial): randomised placebo-controlled trial. *Lancet*. 2004;364(9442):1321–8.
37. Wright DW, Yeatts SD, Silbergleit R, et al. Very early administration of progesterone for acute traumatic brain injury. *N Engl J Med*. 2014;371(26):2457–66.
38. Turner DA, Cheifetz IM. Extracorporeal membrane oxygenation for adult respiratory failure. *Respir Care*. 2013;58(6):1038–52.
39. Dubuisson AS, Beckers A, Stevenaert A. Classical pituitary tumour apoplexy: clinical features, management and outcomes in a series of 24 patients. *Clin Neurol Neurosurg*. 2007;109(1):63–70.
40. Rabinstein AA, Tisch SH, McClelland RL, Wijdicks EF. Cause is the main predictor of outcome in patients with pontine hemorrhage. *Cerebrovasc Dis*. 2004;17(1):66–71.
41. Lacombe P, Lagrange C, Beauchet A, El Hajjam M, Chinot T, Pelage JP. Diffuse pulmonary arteriovenous malformations in hereditary hemorrhagic telangiectasia: long-term results of embolization according to the extent of lung involvement. *Chest*. 2009;135(4):1031–7.
42. Bar B, Mackenzie L, Hurst RW, et al. Hyperacute vasospasm after aneurysmal subarachnoid hemorrhage. *Neurocrit Care*. 2016;24(2):180–8.
43. Behrns KE, Ashley SW, Hunter JG, Carr-locke D. Early ERCP for gallstone pancreatitis: for whom and when? *J Gastrointest Surg*. 2008;12(4):629–33.
44. Seamon MJ, Haut ER, Van Arendonk K, et al. An evidence-based approach to patient selection for emergency department thoracotomy: a practice management guideline from the Eastern Association for the Surgery of Trauma. *J Trauma Acute Care Surg*. 2015;79(1):159–73.
45. Lomas DJ, Padley SG, Flower CD. The sonographic appearances of pleural fluid. *Br J Radiol*. 1993;66(787):619–24.
46. Sharshar T, Chevret S, Bourdain F, Raphaël JC. Early predictors of mechanical ventilation in Guillain-Barré syndrome. *Crit Care Med*. 2003;31(1):278–83.
47. Roth C, Ferbert A, Deinsberger W, et al. Does prone positioning increase intracranial pressure? A retrospective analysis of patients with acute brain injury and acute respiratory failure. *Neurocrit Care*. 2014;21(2):186–91.
48. Naff N, Williams MA, Keyl PM, et al. Low-dose recombinant tissue-type plasminogen activator enhances clot resolution in brain hemorrhage: the intraventricular hemorrhage thrombolysis trial. *Stroke*. 2011;42(11):3009–16.
49. Hanley D. Clot lysis: evaluating accelerated resolution of intraventricular hemorrhage phase III (CLEAR-III). *ClinicalTrials.gov identifier*. NCT00784134.
50. Frontera JA, Claassen J, Schmidt JM, et al. Prediction of symptomatic vasospasm after subarachnoid hemorrhage: the modified fisher scale. *Neurosurgery*. 2006;59(1):21–7.
51. Brouwer MC, Tunkel AR, Mckhann GM, Van de Beek D. Brain abscess. *N Engl J Med*. 2014;371(5):447–56.
52. Fuller BM, Mohr NM, Miller CN, et al. Mechanical ventilation and ARDS in the ED: a multi-center, observational, prospective, cross-sectional study. *Chest*. 2015;148(2):365–74.