



Contents lists available at ScienceDirect

International Journal of Surgery Case Reports

journal homepage: www.casereports.com

Entirely endoscopic resection of a complicated juvenile psammomatoid ossifying fibroma of the paranasal sinusitis: Case report and review of the literature

Mouna Lyoubi, Mohamed Beghdad*, Yassir Hammouda, Youssef Oukessou, Sami Rouadi, Mohamed Mahtar

ENT Head and Neck Surgery Department, Ibn Rochd University Hospital, Faculty of Medicine and Pharmacy, Hassan II University, 20000, Casablanca, Morocco

ARTICLE INFO

Article history:

Received 5 February 2021
Received in revised form 5 March 2021
Accepted 5 March 2021
Available online 13 March 2021

Keywords:

Juvenile ossifying fibroma
Young woman
Paranasal sinuses
Exophthalmos
Endoscopic transnasal resection

ABSTRACT

INTRODUCTION: Juvenile ossifying fibroma (OF) is a benign fibro-osseous tumor, affecting the bones of the face. It's locally very aggressive, with a strong tendency to recur. We report a case of a juvenile psammomatoid ossifying fibroma (JPOF) complicated with exophthalmos undergoing an entirely endoscopic resection.

CLINICAL PRESENTATION: A 14-years-old, young woman presented with a 7 months history of headache and right chronic tearing complicated with exophthalmos. Nasal endoscopy revealed a polylobed mass filling the right nasal cavity, the ophthalmic examination showed an isolated exophthalmos. CT scan revealed a well-limited benign mass covered by a thick shell of bone, pushing out the orbital lamina papyracea responsible for a grade 1 exophthalmos. On the facial MRI, we excluded intracranial or intraorbital involvement. A biopsy of the mass describes a psammomatoid juvenile ossifying fibroma. The patient underwent endoscopic transnasal approach with image-guided neuro-navigation system.

CLINICAL DISCUSSION: JPOF is an aggressive variant of ossifying fibroma occurring predominantly in children with a predilection for the paranasal sinuses. CT scan images show a characteristic well-limited benign expansile mass covered by a thick shell of bone, but sometimes it's mistaken for a mucocele. MRI helps with excluding intracranial or intraorbital involvement. Endonasal endoscopic approaches have been increasingly used and it tends to become the new standard of care.

CONCLUSION: Treatment consists of complete surgical removal; incomplete resection is associated with a high local recurrence rate. Clinician should keep in mind the need for clinical and radiological follow-up for many years.

© 2021 Published by Elsevier Ltd on behalf of IJS Publishing Group Ltd. This is an open access article under the CC BY-NC-ND license (<http://creativecommons.org/licenses/by-nc-nd/4.0/>).

1. Introduction

Juvenile ossifying fibroma (OF) is an uncommon fibro-osseous tumor, affecting the bones of the face. It is a benign tumor, locally very aggressive, with a strong tendency to recur (Thankappan 2009). This benign facial tumor classically develops in the nasosinus cavities and can present orbital and endocranial extensions [1]. It can present in two histological forms, psammomatoid and trabecular, each one is characterized by its location, its age of onset and its aggressiveness. We report a case of a complicated JPOF with exophthalmos operated for the first time at our ENT Department of

Ibn Rochd University Hospital in Morocco by entirely endoscopic resection. This work has been reported in line with the SCARE 2020 criteria [2].

2. Case presentation

A 14- years-old young woman, without any particular medical history, was presented to our ENT department with a 7 months history of headache and right chronic tearing without rhinological symptomatology. Nasal endoscopy revealed a polylobed mass filling the right nasal cavity and arriving at the inner turbinate, the ophthalmic examination revealed an isolated proptosis without diplopia or visual loss.

3. Investigations

CT imaging showed a well limited mass covered by a shell of bone delimiting areas of necrosis measuring 37 mm × 27 mm × 42

* Corresponding author.

E-mail addresses: mounalyoubi03@gmail.com (M. Lyoubi), mohamedbeghdad13@gmail.com (M. Beghdad), mohamedali9347587@gmail.com (Y. Hammouda), youssef.chucasa@gmail.com (Y. Oukessou), samichu1234@gmail.com (S. Rouadi), mohammed.m.chu1234@gmail.com (M. Mahtar).

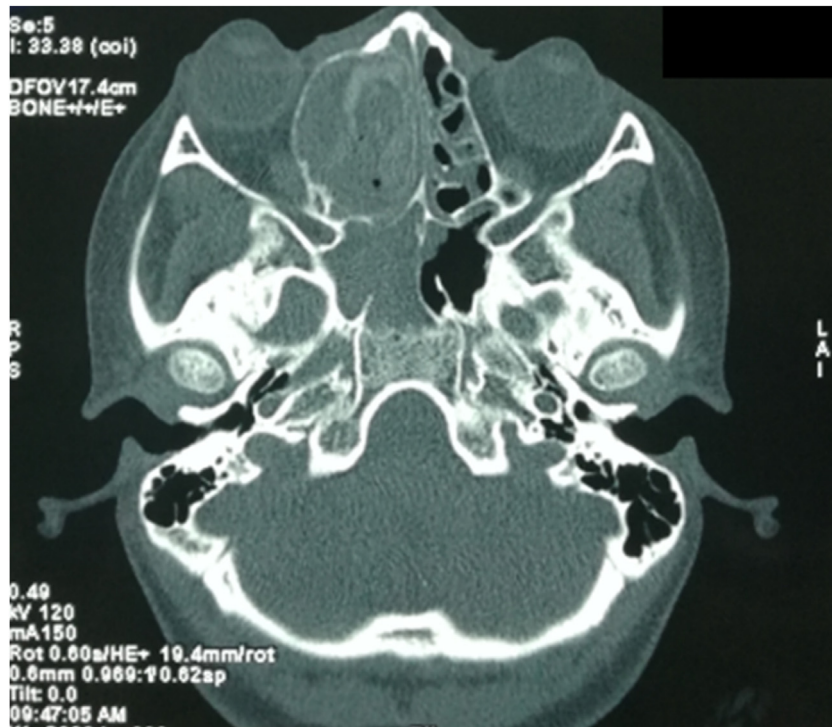


Fig. 1. Axial CT scan showing ossifying fibroma arising in the right nasal cavity but also extending into the right orbit.

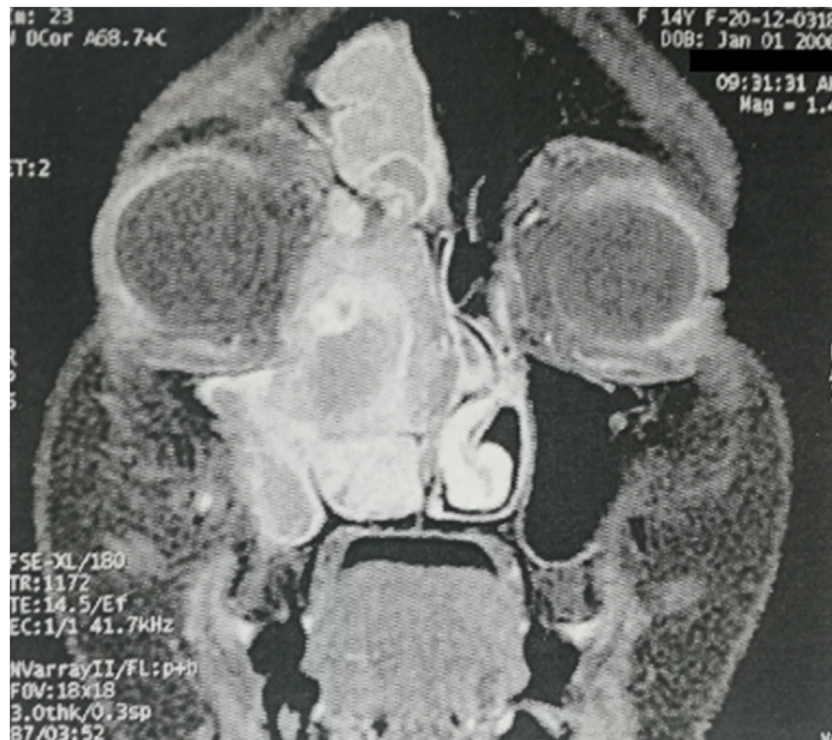


Fig. 2. Coronal MRI in the same patient showing heterogeneous signal from the ossifying fibroma.

mm (Fig. 1). The mass appeared to derive from the right ethmoid sinus pushing back the nasal septum with its partial lysis, pushing out the orbital lamina papyracea responsible for a grade 1 exophthalmos, with extension to the maxillary sinus and to the skull base with a bone defect without intracranial invasion. On facial MRI, we excluded intracranial or intraorbital involvement (Fig. 2). The first diagnosis suggested was a mucocele.

4. Treatment

The patient underwent endonasal surgical exploration in order to excise the mucocele, but the appearance of the mass during the operation cast doubt on the diagnosis and the decision was to take a simple biopsy of the mass. Anatomopathological examination has described a psammomatoid juvenile ossifying fibroma

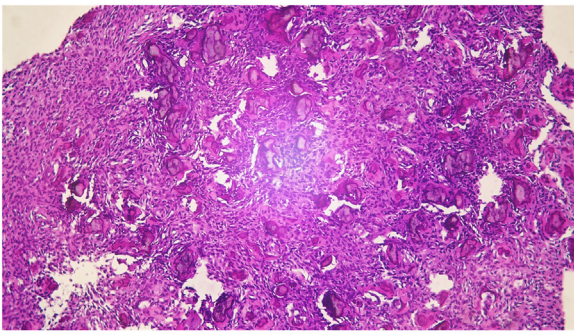


Fig. 3. HEX100: Psammomatoid bodies within a cellular stroma.

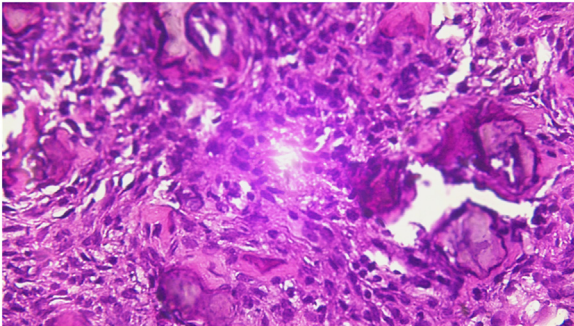


Fig. 4. HEX400: Stromal cells are spindle shaped without atypia nor mitosis.

(Figs. 3 and 4). Afterward, the patient underwent, through an endoscopic transnasal approach with image-guided neuro-navigation system, a complete tumor resection and decompression of the eyeball by rupture of the papery lamina and invagination of the periorbital fat performed by a senior ENT professor with a 15 years' experience in endonasal approaches. Intraoperatively, we noted a bone lysis of the posterior wall of the maxillary sinus communicating the latter with the infra-temporal fossa, as well as a partial lysis of the anterior level of the skull base without encephalocele. Post-operatively, the patient was hospitalized in our ENT department. The immediate post-intervention evolution was marked by an acute anemia at 7.2 g / dl requiring transfusion of 2 units of red blood cells and a clinical regression of proptosis. The follow up after 7 months showed no clinical sign of recurrence. The patient was satisfied with the clinical outcome as well as the good quality of life and sleep after surgery.

5. Discussion

Ossifying fibroma (OF) is a true benign encapsulated tumor composed of bone, fibrous tissue, calcification, and cementum [3–5]. It can be divided into the conventional form of ossifying fibroma, also called cemento-ossifying fibroma, and juvenile ossifying fibromas (JOF) which is an aggressive variant of OF. It starts at an earlier age and was defined by Reed and Hagy as a localized actively growing destructive lesion occurring predominantly in children and teenagers [6]. We distinguish juvenile trabecular ossifying fibroma (JTOF) and juvenile psammomatoid ossifying fibroma (JPOF), which are most commonly seen in the younger age group. JTOF usually occurs in the maxilla and JPOF has a predilection for the paranasal sinuses [7]. Depending on its extent, it can lead to swelling, facial pain, nasal obstruction, rhinosinusitis, and ocular symptoms such as proptosis, diplopia, and epiphora with extension of the tumor to the skull base and orbit [8–10]. CT images show a characteristic well-demarcated benign expansile mass covered by a thick shell of bone, sometimes with a multiloculated internal appearance

and a content of varying density [11,12]. and as a consequence is sometimes mistaken for a mucocele. There may be areas of low density or scattered calcification. The mass expands, thins, and destroys adjacent bone, displacing structures such as nasal septum, the orbital contents, and the skull base. On MRI, the lesion is heterogeneous in hypersignal T1 and hyposignal T2. Histologically, the juvenile OF is characteristically composed of ossicles, a stroma, and chondricles in myxomatous areas. The treatment depends on the location but in general requires complete surgical resection. The lesion will regrow if not completely removed, so total extirpation should be undertaken whenever possible. Due to its rarity, there are few large series in the literature that include a wide range of surgical approaches including craniofacial resection, midfacial degloving, and lateral rhinotomy as well as some case reports of entirely endoscopic resection. Draf et al. reported on endonasal microendoscopic resection of four OFs without any complications. In two cases the surgery was done for optic nerve decompression. In OF with significant intracranial extension, most authors recommend a combined approach including craniofacial resection [13–15]. Recurrence after surgery is directly related to the thoroughness of excision, but up to one-third of patients with the juvenile OF have recurrence despite repeated operations.

6. Conclusion

The use of an intraoperative image-guided navigation system may help in confidently recognizing where the boundaries of the tumor are, especially in an obscured, bloody operative field. Orbital extensions, as illustrated in our case, and endocranial remain exceptional. The frequency of recurrence justifies long-term clinical and radiological surveillance.

Conflicts of interest

No conflicts of interest.

Funding

Personnal funding sources.

Ethical approval

Ethical approval has been exempted by my institution.

Consent

Written informed consent was obtained from the patient's family for publication of this case report and accompanying images. A copy of the written consent is available for review by the Editor-in-Chief of this journal on request.

Author contribution

All the authors worked in coordination to ensure the best management of the disease from diagnosis to the hospitalization. The authors wrote this article together.

Registration of research studies

- 1 Name of the registry:
- 2 Unique identifying number or registration ID:
- 3 Hyperlink to your specific registration (must be publicly accessible and will be checked): This study is not "First in Men"

Guarantor

Beghdad mohamed.

Provenance and peer review

Not commissioned, externally peer-reviewed.

Acknowledgments

We are indebted to the nursing staff of the ENT Department 20 August Hospital, Ibn Rochd Teaching Hospital, Casablanca Morocco for their invaluable contributions to this work.

References

- [1] B. Khademi, N. Niknejad, J. Mahmoudi, An aggressive psammomatoid ossifying fibroma of the sinonasal tract: report of a case, *Ear Nose Throat J.* 86 (2007), 400-1.
- [2] R.A. Agha, T. Franchi, C. Sohrabi, G. Mathew, for the SCARE Group, The SCARE 2020 Guideline: Updating Consensus Surgical CAse REport (SCARE) Guidelines, *Int. J. Surg.* 84 (2020) 226–230.
- [3] J.M. Van Buren, A.K. Om maya, A.S. Ketcham, Ten years' experience with radical combined craniofacial resection of malignant tumors of the paranasal sinuses, *J. Neurosurg.* 28 (4) (1968) 341–350.
- [4] C.P. Wilson, Observations on the surgery of the nasopharynx, *Ann. Otol. Rhinol. Laryngol. Suppl.* 66 (1) (1957) 5–40.
- [5] J.R. Belmont, The Le Fort I osteotomy approach for naso-pharyngeal and nasal fossa tumors, *Arch. Otolaryngol. Head Neck Surg.* 114 (7) (1988) 751–754.
- [6] R.J. Reed, D.M. Hagy, Benign nonodontogenic fibro-osseous lesions of the skull; Report of two cases, *Oral Surg. Oral Med. Oral Pathol.* 19 (1965) 214–227.
- [7] B.R. Chrcanovic, R.S. Gomez, Juvenile ossifying fibroma of the jaws and paranasal sinuses: a systematic review of the cases reported in the literature, *Int. J. Oral Maxillofac. Surg.* (2019).
- [8] I. Yilmaz, N. Bal, L.N. Ozluoglu, Isolated cementoossifying fibroma of the ethmoid bulla: a case report, *Ear Nose Throat* 85 (5) (2006) 322–324.
- [9] V.F. Chong, L.H. Tan, Maxillary sinus ossifying fibroma, *Am. J. Otolaryngol.* 18 (6) (1997) 419–424.
- [10] N.J. Khoury, L.N. Naffaa, N.S. Shabb, M.C. Haddad, Juvenile ossifying fibroma: CT and MR findings, *Eur. Radiol.* 12 (Suppl 3) (2002) S109–S113.
- [11] P.A. Levine, R. Wiggins, R.W. Archibald, R. Britt, Ossifying fibroma of the head and neck: involvement of the temporal bone- and unusual and challenging site, *Laryngoscope* 91 (5) (1981) 720–725.
- [12] Y.C. Choi, E.J. Jeon, Y.S. Park, Ossifying fibroma arising in the right ethmoid sinus and nasal cavity, *Int. J. Pediatr. Otorhinolaryngol. Extra* 54 (2–3) (2000) 159–162.
- [13] V.J. Lund, D.J. Howard, W.I. Wei, A.D. Cheesman, Craniofacial resection for tumors of the nasal cavity and paranasal sinuses—a 17-year experience, *Head Neck* 20 (2) (1998) 97–105.
- [14] D.J. Howard, V.J. Lund, W.I. Wei, Craniofacial resection for tumors of the nasal cavity and paranasal sinuses: a 25-year experience, *Head Neck* 28 (10) (2006) 867–873.
- [15] D. Mehta, N. Clifton, L. McClelland, N.S. Jones, Paediatric fibro-osseous lesions of the nose and paranasal sinuses, *Int. J. Pediatr. Otorhinolaryngol.* 70 (2) (2006) 193–199.

Open Access

This article is published Open Access at [sciencedirect.com](https://www.sciencedirect.com). It is distributed under the [IJSCR Supplemental terms and conditions](#), which permits unrestricted non commercial use, distribution, and reproduction in any medium, provided the original authors and source are credited.