

Endoscopic management of foreign bodies in the upper gastrointestinal tract: An analysis of 846 cases in China

FANGFANG YUAN^{1,2}, XIAOWEI TANG¹, WEI GONG¹, LEI SU^{2*} and YALI ZHANG^{1*}

¹Department of Gastroenterology, Nanfang Hospital, Southern Medical University, Guangzhou, Guangdong 510515; ²Department of Intensive Care Unit, General Hospital of Guangzhou Military Command, Guangzhou, Guangdong 510010, P.R. China

Received February 13, 2016; Accepted September 29, 2017

DOI: 10.3892/etm.2017.5561

Abstract. Foreign body ingestion is a relatively common occurrence, which may lead to morbidity and mortality. The aim of the present study was to report the experience of management of upper gastrointestinal foreign bodies by endoscopy in a large center. All patients who presented at the Department of Gastroenterology at Nanfang Hospital (Guangzhou, China) with complaints regarding upper gastrointestinal (GI) foreign body ingestion from December 1987 to December 2013. Hospital medical charts and endoscopic records were examined to evaluate etiology, treatment, and outcomes for these patients. A total of 846 patients were enrolled in the present study, from which foreign bodies were detected in 737 (87.1%) patients via X-ray or endoscopy. The objects most frequently ingested were bones (n=395, 53.6%). The detected foreign bodies were predominantly located in the cervical esophagus (n=325, 44.1%). Endoscopic foreign body extraction was successful in 92.5% of cases, whereas surgery was required in 6 patients. The most frequently used endoscopic accessory devices were retrieval forceps (n=480, 65.1%). The complication rate was 6.9%, including mucosal laceration (n=10) and others, all of which were managed conservatively. Associated GI diseases were reported in 74 (10.0%) patients, including postesophagectomy (n=34) and others. In conclusion, the endoscopic procedure was safe and effective for the removal

of foreign bodies from the upper gastrointestinal tract, with a high success rate and low complication rate.

Introduction

Foreign body ingestion and food bolus impaction is a common occurrence that may lead to morbidity and mortality. It is estimated that 1,500-1,600 patients succumb to mortality in the United States each year due to complications associated with the ingestion of foreign bodies into the gastrointestinal (GI) tract (1).

The majority of ingested foreign bodies are able to pass spontaneously through the GI duct without complication, however ~20% require endoscopic or surgical treatment (2,3). The incidence of foreign body ingestion varies significantly with age and health condition. The majority of foreign body ingestions occur in the pediatric population, with a peak incidence between the ages of 6 months and 6 years (4,5). In adults, the majority of ingestions may be purely accidental; however, there are a number of contributory factors including mental or psychiatric disorders, developmental delay and alcohol intoxication amongst others (6-8). Edentulous adults are also at a greater risk for foreign body ingestion, including the ingestion of their dental prosthesis (9). Patients who have undergone previous GI duct surgery or have gut malformations are at an increased risk of complications caused by foreign body ingestion, such as perforation or obstruction (10,11).

With the advancement of endoscopic technique, the majority of ingested foreign bodies in the upper GI tract are best treated with flexible endoscopes, with a high successful removal rate of >95% (12-15). At present, foreign body ingestion remains a common clinical problem in China, it can be found in 78-90% patients (13,14). However, to the best of our knowledge, only a few reports have investigated the endoscopic management of foreign bodies of the upper-GI tract (13,14,16). The aim of the present study was to conduct a retrospective analysis of Chinese patients who presented at the Department of Gastroenterology, Nanfang Hospital, Southern Medical University (Guangzhou, China) with foreign body ingestion.

Patients and methods

Patients. The present retrospective study was conducted in the Endoscopy Center of Nanfang Hospital. A total of

Correspondence to: Dr Yali Zhang, Department of Gastroenterology, Nanfang Hospital, Southern Medical University, 1838 Guangzhou North Avenue, Guangzhou, Guangdong 510515, P.R. China

E-mail: ylnfyk@sina.com

Dr Lei Su, Department of Intensive Care Unit, General Hospital of Guangzhou Military Command, 111 Liuhua Road, Guangzhou, Guangdong 510010, P.R. China

E-mail: 563625231@qq.com

*Contributed equally

Key words: endoscopy, foreign body, upper gastrointestinal tract

846 consecutive patients (male:female, 455:282; age range, 9 months-92 years) who presented at the Department of Gastroenterology at Nanfang Hospital with suspected foreign body ingestion and food bolus impaction in the upper GI tract from December 1987 to December 2013 were retrospectively identified. Furthermore, those patients with incomplete records were excluded. Foreign bodies were only detected in 737 patients via X-ray or endoscopy. Written informed consent was obtained from the subjects and/or, in the case of minors, guardians.

Endoscopic procedure. Following patient admission, plain radiographs were routinely performed in the initial investigation of suspected foreign body ingestion. In the majority 92.1% (779/846) of cases, the plain film radiography was performed in two projections in the region of the neck, thorax or abdomen, as required. Esophagograms with barium or computed topography scan were performed in patients who had ingested sharp foreign bodies or when the extraction procedure seemed to be challenging. Each patient underwent an upper endoscopy under local pharyngeal anesthesia with Pontocaine mucilage. Flexible endoscopes (GIF-XQ240, GIF-Q260, GIF-Q260J, GIF-N230; Olympus Corporation, Tokyo, Japan) were used for all patients. A number of endoscopic accessories, including rat-tooth forceps, V-shaped forceps, retrieval and Dormia baskets, polypectomy snares and transparent caps, were used depending on the nature and location of the foreign body. For some food boluses, the push technique was applied to move it to the gastric cavity was also often used. An overtube was electively used to protect the airway and facilitate passage of the endoscope during retrieval of foreign bodies. Patients with objects that were difficult to remove, including multiple objects received sedation with midazolam, and pediatric patients usually required general anesthesia with propofol. All adult patients and the parents of child patients gave informed consent prior to the procedure.

Following enrollment, the hospital medical charts and endoscopic records of patients were examined. The following information was recorded: Demographic characteristics, previous medical history, underlying disorders, type and location of the foreign body, methods of management and any associated complications.

Results

Demographic characteristics of the patients. Foreign bodies were detected in 737 of the 846 patients (87.1%) suspected of ingestion of foreign bodies. Among these patients, there were 455 (61.7%) males and 282 (38.3%) females, ranging in age from 9 months-92 years (mean, 44.3 years; Table I). Children aged ≤ 14 years accounted for 7.7% of the patients, 68.9% were adult patients (15-59 years), and 23.3% were elderly patients (≥ 60 years). Psychiatric disorder (n=4, 0.5%), intellectual impairment (n=7, 0.9%) and drug misuse (n=6, 0.8%) were the most common associated psychosocial problems. A total of 74 patients (10.0%) had the following associated upper GI diseases: Esophageal cancer (n=16, 2.2%), esophageal stricture (n=10, 1.4%), postesophagectomy (n=34, 4.6%), postgastrectomy (n=2, 0.3%), hiatal hernia (n=7, 0.9%) and achalasia (n=5, 0.7%).

Table I. Basic demographic data of the study population (n=737).

Parameters	Patients (n, %)
Age, years	
≤ 14	57 (7.7)
15-59	508 (68.9)
≥ 60	172 (23.3)
Sex	
Female	282 (38.3)
Male	455 (61.7)
Associated psychosocial disorder	
Psychiatric disorder	4 (0.5)
Intellectual impairment	7 (0.9)
Drug abuser	6 (0.8)
Associated upper gastrointestinal diseases	
Esophageal cancer	16 (2.2)
Esophageal stricture	10 (1.4)
Postesophagectomy	34 (4.6)
Postgastrectomy	2 (0.3)
Hiatal hernia	7 (0.9)
Achalasia	5 (0.7)

Type and locations of foreign bodies. As shown in Table II, the type of foreign bodies detected varied greatly: The most prevalent were fish bones (n=180, 24.4%), followed by chicken bone (n=128, 17.4%). Other categories included the following: Food bolus (n=117, 15.9%), metallic foreign bodies (n=41, 5.6%), fruit seed (n=13, 1.8%), coin (n=22, 3.0%), toothpick (n=17, 2.3%), denture (n=10, 1.4%). A number of such examples are presented in Fig. 1. The prevalence of different types of foreign body varied between the different age groups. Coins (n=20, 35.1%) were the most prevalent foreign bodies in children, whereas fish bones were the most prevalent in adults (n=156, 30.7%) and elderly (n=20, 11.6%).

The individual characteristics of the ingested foreign bodies also determined their lodgment site (Table III). Fish bones were typically detected in the pharynx and cervical esophagus, food boluses were typically lodged in the surgical anastomosis site and metallic foreign bodies were most frequently detected in the stomach. Of the 737 foreign bodies, 60 (8.1%) were located in the pharynx, 545 (73.9%) in the esophagus, 87 (11.8%) in the stomach, 26 (3.5%) in the duodenum and 19 (2.6%) were in the surgical anastomosis site. In the esophagus, 325 (44.1%) were located in the cervical esophagus, 209 (28.4%) in the thoracic esophagus, and 11 (1.5%) in the distal esophagus.

Endoscopic management of foreign bodies. The chosen endoscopic method varied according to the type and location of the foreign objects (Table IV). The most frequently used accessory devices were retrieval forceps (n=480, 65.1%), polypectomy snare or Dormia basket (n=120, 16.3%), and transparent cap (n=82, 11.1%). For food boluses (n=41, 5.6%), pushing to move it to the gastric cavity was often used. Conversely, some food boluses (n=14, 1.9%) were pulled and fragmented. Furthermore,

Table II. Types of ingested foreign bodies among children, adults and elderly patients.

Type of foreign body (n, %)	Children (n, %)	Adults (n, %)	Elderly (n, %)
Fish bone (180, 24.4)	4 (7.0)	156 (30.7)	20 (11.6)
Chicken bone (128, 17.4)	1 (1.8)	107 (21.1)	20 (11.6)
Other bone (87, 11.8)	0 (0)	56 (11.0)	31 (18.0)
Food bolus (117, 15.9)	10 (17.5)	58 (11.4)	49 (28.5)
Fruits seed (13, 1.8)	1 (1.8)	5 (1.0)	7 (4.1)
Metallic (41, 5.6)	10 (17.5)	29 (5.7)	2 (1.2)
Coin (22, 3.0%)	20 (35.1)	1 (0.2)	1 (0.6)
Denture (10, 1.4)	0 (0)	7 (1.4)	3 (1.7)
Drug package (7, 0.9)	1 (1.8)	4 (0.8)	2 (1.2)
Toothpick (17, 2.3)	2 (3.5)	13 (2.6)	2 (1.2)
Lighter (8, 1.1)	0 (0)	8 (1.6)	0 (0)
Toothbrush (6, 0.8)	0 (0)	4 (0.8)	2 (1.2)
Miscellaneous (101, 13.7)	8 (14.0)	60 (11.8)	33 (19.2)
Total (737, 100)	57 (7.7)	508 (68.9)	172 (23.3)

Children, ≤14 years; adults, 15-59 years; elderly, ≥60 years.

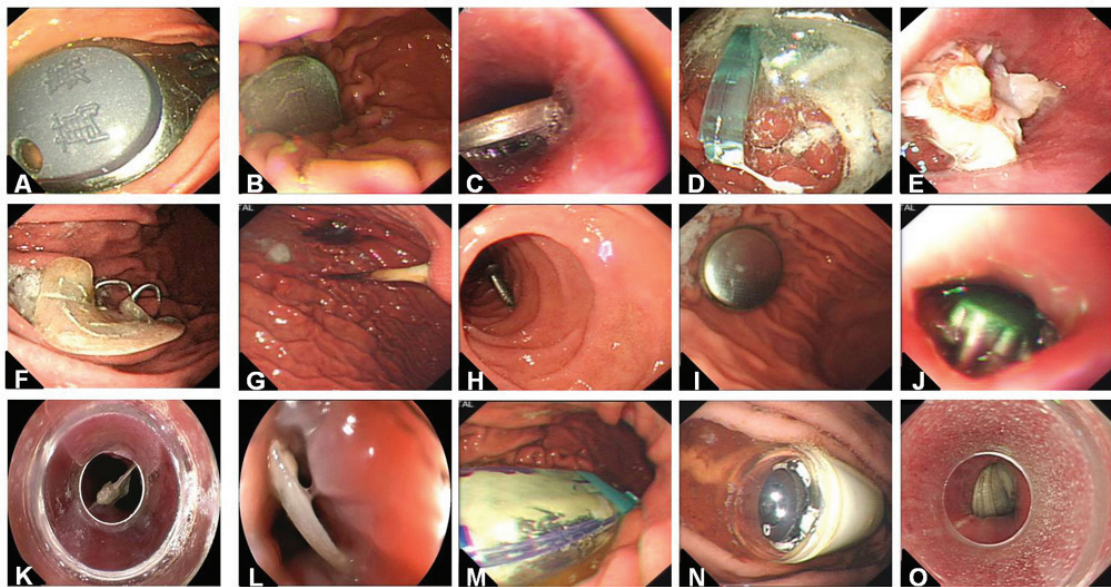


Figure 1. Endoscopic views of various impacted foreign bodies in the upper gastrointestinal duct (magnification, x2). (A) Key; (B and C) coins; (D) toothbrush; (E) food bolus; (F) denture; (G) toothpick; (H) screw spike; (I) lithium battery; (J) bottle cap; (K and L) fish bones; (M) lighter; (N) capsule endoscope; and (O) seashell.

8 patients required a protective system, an overtube, to remove blunted or sharp foreign bodies. Initial endoscopic retrieval failed in 13 patients (13/737 1.76%), and a second endoscopic procedure was performed by a more experience endoscopist.

In 55 patients (7.5%), it was impossible to remove the foreign body as the majority of foreign bodies in these cases were located in the cervical esophagus (n=32, 58.2%), which is one of the narrowest portion of the alimentary canal. Furthermore, fish bones, which are a type of sharp foreign body, were the most prevalent (n=24, 43.6%) in these cases. As sharp foreign bodies always result in painful symptoms and a high risk of complications (16), these types of foreign body were not

removed. These patients underwent further treatment, and 6 patients required surgery. In 1 patient who presented with steel wire ingestion, plain radiographs of the neck revealed a 4-cm long radio-opaque foreign body in the soft tissues of the neck at the level of the C5-6 vertebrae. However, endoscopy was unable to identify any foreign bodies in the pharynx or upper GI duct. Pharyngeal surgery revealed that the steel wire had perforated the oropharynx and was subsequently pushed through the soft tissues of the neck into the mediastinum.

Complications. There was no mortality associated with the endoscopic procedures of removing foreign bodies in

Table III. Locations of foreign body.

Location (n, %)	Most common foreign bodies (n/total, %)
Pharynx (60, 8.1)	Fish bone (36/60, 60)
Cervical esophagus (325, 44.1)	Fish bone (123/325, 37.8)
	Chicken bone (84/325, 25.8)
Thoracic esophagus (209, 28.4)	Chicken bone (40/209, 19.1)
	Food bolus (34/209, 16.3)
Distal esophagus (11, 1.5)	Food bolus (9/11, 81.8)
Stomach (87, 11.8)	Metallic (19/87, 21.8)
	Lighter (7/87, 8.0)
Duodenum (26, 3.5)	Toothpick (10/26, 38.5)
Surgical anastomosis (19, 2.6)	Food bolus (11/19, 57.9)

Table IV. Endoscopic methods used during the 737 procedures.

Method	Cases (n, %)
Transparent cap	82 (11.1)
Pull and fragmentation	14 (1.9)
Pull with retrieval forceps	480 (65.1)
Pull with polypectomy snare or Dormia basket	120 (16.3)
Push into stomach	41 (5.6)

the present cohort. A total of 16 patients (2.2%) developed secondary complications following the endoscopic removal procedures, including mucosal laceration (n=10, 1.4%), bleeding (n=5, 0.7%) and suspected perforation (n=1, 0.1%). All 16 patients were successfully managed by conservative means.

Discussion

The lodging of foreign bodies in the upper GI tract has become a relatively common occurrence (78-90%) in clinical endoscopic practice (13,14). Some studies have suggested that the majority of foreign bodies, including food boluses, that reach the GI duct will pass spontaneously without complications, although 10-20% require endoscopic surgery (2,3). However, the ingestion of foreign bodies may lead to morbidity and/or mortality. Vesna *et al* (17) previously reported cardiac tamponade induced by an ingested sewing needle. Following the first report on the removal of a foreign body with a flexible endoscope by McKechnie (18), there have been an increasing number of studies reporting the application of this method. The present study details experience of endoscopic management of foreign bodies in the upper GI tract.

In the present study, foreign bodies and food bolus impactions were detected in 737 of the 846 patients (87.1%) suspected of ingestion of foreign bodies, which is consistent with a number of eastern and western reported series (13,19,20). The endoscopic intervention was successful in 92.5% of the present cases, including long or sharp foreign bodies such as bones, food boluses and dentures, and failed

Table V. Cases with failed endoscopic procedures.

Criteria	Cases (n, %)
Age group	
Children	3 (5.5)
Adults	31 (56.4)
Elderly	21 (38.1)
Type of foreign bodies	
Fish bone	24 (43.6)
Chicken bone	15 (27.3)
Denture	3 (5.5)
Metallic	5 (9.1)
Food bolus	3 (5.5)
Seed of fruit	3 (5.5)
Plastic package	1 (1.8)
Trichobezoar	1 (1.8)
Locations of foreign bodies	
Pharynx	3 (5.5)
Cervical esophagus	32 (58.2)
Thoracic esophagus	14 (25.5)
Stomach	5 (9.1)
Duodenum	1 (1.8)
Total	55

Children, ≤14 years; adults, 15-59 years; elderly, ≥60 years.

in 55 patients. This success rate was in accordance with a number of previous studies (14,20,21). Regarding the various foreign bodies retrieved, this seemed to be associated with the local cuisine and dietary habits of different regions. In the United States, meat, particularly beef, chicken or hot dogs, are the most common causes of food impaction (22). In Asia and coastal countries, fish is the most common food to lead to impaction and mucosal trauma in either the esophagus or the oropharynx (23). Zhang *et al* (13) revealed that fish bones (60.4%) and chicken bones (16.4%) were the most common types of foreign bodies detected in the upper GI tract in South China. Consistent with this finding, in the present cohort, bones, including fish bones and chicken bone, were the most common.

In the present study, coin ingestion with esophageal impaction was observed in 20 of 57 pediatric patients (35.1%). A previous study indicated that ~80% of swallowed foreign bodies were coins in the pediatric population (24). It has previously been suggested to wait as long as several weeks without taking action if coins have passed into the stomach, or even to take no action at all if coins are already in the stomach (25). However, this was in contrast with reports of toxicity following coin ingestion. Bennett *et al* (26) previously reported toxicity in humans and in animals living in zoos following excessive ingestion of zinc-based coins. In the present study, coins were promptly removed via endoscopy, thereby avoiding their potential toxic effects.

'Push technique' has been reported as a widely-used endoscopic method to treat esophageal food bolus impaction (27,28).

And this approach is only taken in cases where food boluses were lodged, particularly for acute esophageal food impaction. In the present study, this method was used in 41 cases (5.6%). Specifically, a gentle pressure was applied with the tip of the endoscope to the esophageal food bolus following air insufflation. If gentle pressure was unable to remove the bolus, fragmentation was subsequently attempted. However, in cases where obstructive esophageal pathology was underlying the impacted food bolus, this technique was avoided to prevent the risk of perforation or rupture to the esophagus.

Endoscopic retrieval forceps were most often used for removing foreign bodies in the present series. A number of other instruments, including polypectomy snares, retrieval baskets and transparent caps, were also used. In the cases of sharp objects or those requiring repeated scope insertions, the overtube was used to provide protection to the upper aerodigestive structures and avoid aspiration. The application of the overtube during endoscopy allowed the endoscopist to maintain the object within the tube until the scope was completely withdrawn from the patient's mouth. This method was applied in 8 patients, and all foreign bodies were successfully taken out, without any notable complications.

For foreign bodies located at pharynx or the entrance of the esophagus, particularly those firmly impacted into the lumen, conventional endoscopic methods may have great difficulty to remove them successfully due to the narrow lumen of this area, which may limit working space and produce inadequate visual field (13). With a transparent cap attached to the tip of a gastroscope, the narrow physiological area may be widened to allow a clear view of the impacted foreign bodies and enlarge the working space for endoscopy. In a previous randomized controlled trial, Zhang *et al* (16) revealed that transparent cap-assisted endoscopy was safe and effective in the management of foreign bodies in the upper esophagus, with a shorter operation time and clearer visual field. In the present study, 82 foreign bodies were extracted successfully with the assistance of transparent cap, of which 50% were located at the pharynx and 45% were located at the upper esophagus. During the extraction of foreign bodies, they were partly captured inside the transparent cap, with the longitudinal axis approximately parallel to the endoscope, thus avoiding direct contact with the lumen. Therefore, the transparent cap method exhibited the advantage of protecting the esophageal mucosa from injury from sharp foreign bodies during removal.

An associated upper GI disease was reported in 10.4% (n=77) of the present patients with foreign body impaction; predominantly postesophagectomy (n=34) and esophageal cancer (n=16), but also hiatal hernia (n=7). As hiatal hernia may increase in incidence with increasing severity of esophageal contraction abnormalities (29), it was reported as the most common underlying pathology in cases with foreign body ingestion (23). Generally, underlying esophageal pathology increases the risk of food bolus impaction due to the disturbed esophageal peristalsis and narrowed cannal diameter (30).

Radiologic procedures may have an important role in helping determine the presence, location and type of an ingested foreign body, thus helping identify the most appropriate therapeutic approach (31-33). The majority of patients in the present study with suspected foreign body ingestion had anteroposterior and lateral radiographs of the neck, chest, or

abdomen. This was useful for detection of radiopaque foreign body ingestion. However, fish bones and some food bolus are difficult to detect because of their radiolucency. In a previous report by Chiu *et al* (31), only 47.1% patients with suspected foreign bodies had positive radiographic findings. Therefore, radiographic findings may not be beneficial in identifying cases of radiolucent foreign bodies (15).

In conclusion, ingestion of foreign bodies is a common clinical problem in China. Fish bones and chicken bones were identified as the most common foreign bodies encountered in the present study. Furthermore, the results suggest that endoscopic procedures may achieve a high success rate and efficacy in the management of foreign bodies in the upper GI tract without significant complications. However, different methods of endoscopic management should be applied according to the type and location of the foreign bodies.

References

- Schwartz GF and Polsky HS: Ingested foreign bodies of the gastrointestinal tract. *Am Surg* 42: 236-238, 1976.
- Anderson KL and Dean AJ: Foreign bodies in the gastrointestinal tract and anorectal emergencies. *Emerg Med Clin North Am* 29: 369-400, 2011.
- Ginsberg GG: Management of ingested foreign objects and food bolus impactions. *Gastrointest Endosc* 41: 33-38, 1995.
- Cheng W and Tam PK: Foreign-body ingestion in children: Experience with 1,265 cases. *J Pediatr Surg* 34: 1472-1476, 1999.
- Hachimi-Idrissi S, Come L and Vandenpias Y: Management of ingested foreign bodies in childhood: Our experience and review of the literature. *Eur J Emerg Med* 5: 319-323, 1998.
- Palta R, Sahota A, Bemarki A, Salama P, Simpson N and Laine L: Foreign-body ingestion: Characteristics and outcomes in a lower socioeconomic population with predominantly intentional ingestion. *Gastrointest Endosc* 69: 426-433, 2009.
- Weiland ST and Schurr MJ: Conservative management of ingested foreign bodies. *J Gastrointest Surg* 6: 496-500, 2002.
- Kamal I, Thompson J and Paquette OM: The hazards of vinyl glove ingestion in the mentally retarded patient with pica: New implications for surgical management. *Can J Surg* 42: 201-204, 1999.
- Abdullah BJ, Teong LK, Mahadevan J and Jalaludin A: Dental prosthesis ingested and impacted in the esophagus and orolaryngopharynx. *J Otolaryngol* 27: 190-194, 1998.
- Macmanus JE: Perforation of the intestine by ingested foreign bodies. *Am J Surg* 53: 393-402, 1941.
- Benjamin SB: Small bowel obstruction and the Garren-Edwards gastric bubble: An iatrogenic bezoar. *Gastrointest Endosc* 34: 463-467, 1988.
- ASGE Standards of Practice Committee; Ikenberry SO, Jue TL, Anderson MA, Appalaneeni V, Banerjee S, Ben-Menachem T, Decker GA, Fanelli RD, Fisher LR, *et al*: Management of ingested foreign bodies and food impactions. *Gastrointest Endosc* 73: 1085-1091, 2011.
- Zhang S, Cui Y, Gong X, Gu F, Chen M and Zhong B: Endoscopic management of foreign bodies in the upper gastrointestinal tract in South China: A retrospective study of 561 cases. *Dig Dis Sci* 55: 1305-1312, 2010.
- Li ZS, Sun ZX, Zou DW, Xu GM, Wu RP and Liao Z: Endoscopic management of foreign bodies in the upper-GI tract: Experience with 1088 cases in China. *Gastrointest Endosc* 64: 485-492, 2006.
- Webb WA: Management of foreign bodies of the upper gastrointestinal tract: Update. *Gastrointest Endosc* 41: 39-51, 1995.
- Zhang S, Wang J, Wang J, Zhong B, Chen M and Cui Y: Transparent cap-assisted endoscopic management of foreign bodies in the upper esophagus: A randomized, controlled trial. *J Gastroenterol Hepatol* 28: 1339-1342, 2013.
- Vesna D, Tatjana A, Slobodan S and Slobodan N: Cardiac tamponade caused by migration of a swallowed sewing needle. *Forensic Sci Int* 139: 237-239, 2004.
- McKechnie JC: Gastroscopic removal of a phytobezoar. *Gastroenterology* 62: 1047-1051, 1972.
- Conway WC, Sugawa C, Ono H and Lucas CE: Upper GI foreign body: An adult urban emergency hospital experience. *Surg Endosc* 21: 455-460, 2007.

20. Velitchkov NG, Grigorov GI, Losanoff JE and Kjossev KT: Ingested foreign bodies of the gastrointestinal tract: Retrospective analysis of 542 cases. *World J Surg* 20: 1001-1005, 1996.
21. Mosca S, Manes G, Martino R, Amitrano L, Bottino V, Bove A, Camera A, De Nucci C, Di Costanzo G, Guardascione M, *et al*: Endoscopic management of foreign bodies in the upper gastrointestinal tract: Report on a series of 414 adult patients. *Endoscopy* 33: 692-696, 2001.
22. Longstreth GF, Longstreth KJ and Yao JF: Esophageal food impaction: Epidemiology and therapy. A retrospective, observational study. *Gastrointest Endosc* 53: 193-198, 2001.
23. Stack LB and Munter DW: Foreign bodies in the gastrointestinal tract. *Emerg Med Clin North Am* 14: 493-521, 1996.
24. Vyas K, Sawant P, Rathi P, Das HS and Borse N: Foreign bodies in gut. *J Assoc Physicians India* 48: 394-396, 2000.
25. Cheng W and Tam PK: Foreign-body ingestion in children: Experience with 1,265 cases. *J Pediatr Surg* 34: 1472-1476, 1999.
26. Bennett DR, Baird CJ, Chan KM, Crookes PF, Bremner CG, Gottlieb MM and Naritoku WY: Zinc toxicity following massive coin ingestion. *Am J Forensic Med Pathol* 18: 148-153, 1997.
27. Weinstock LB, Shatz BA and Thyssen SE: Esophageal food bolus obstruction: Evaluation of extraction and modified push techniques in 75 cases. *Endoscopy* 31: 421-425, 1999.
28. Vicari JJ, Johanson JF and Frakes JT: Outcomes of acute esophageal food impaction: Success of the push technique. *Gastrointest Endosc* 53: 178-181, 2001.
29. Clouse RE, Eckert TC and Staiano A: Hiatus hernia and esophageal contraction abnormalities. *Am J Med* 81: 447-450, 1986.
30. Lyons MF II and Tsuchida AM: Foreign bodies of the gastrointestinal tract. *Med Clin North Am* 77: 1101-1114, 1993.
31. Chiu YH, Hou SK, Chen SC, How CK, Lam C, Kao WF, Yen DH and Huang MS: Diagnosis and endoscopic management of upper gastrointestinal foreign bodies. *Am J Med Sci* 343: 192-195, 2012.
32. Morioka WT, Maisel RH, Smith TW and Cantrell RW: Unexpected radiographic findings related to foreign bodies. *Ann Otol Rhinol Laryngol* 84: 627-630, 1975.
33. Handler SD, Beaugard ME, Canalis RF and Fee WE Jr: Unsuspected esophageal foreign bodies in adults with upper airway obstruction. *Chest* 80: 234-237, 1981.



This work is licensed under a Creative Commons Attribution-NonCommercial-NoDerivatives 4.0 International (CC BY-NC-ND 4.0) License.