

# Use of diaphragmatic compound motor action potential monitoring to prevent right phrenic nerve palsy during atrial tachycardia ablation



Jasen L. Gilge, MD, Eric N. Prystowsky, MD, FHRS, Benzy J. Padanilam, MD, FHRS, Bradley A. Clark, DO, Ankur Shah, DO, Leonard A. Steinberg, MD, Girish V. Nair, MD, Parin J. Patel, MD, FHRS

*From the Division of Cardiology, Ascension Medical Group, Indianapolis, Indiana.*

## Introduction

The right phrenic nerve (PN) travels along the lateral superior vena cava and right atrial wall and may be at risk of injury during endocardial catheter ablation around the right pulmonary veins or crista terminalis.<sup>1–3</sup> Several epicardial techniques have been employed to separate the PN from the myocardium, allowing successful catheter ablation without PN palsy (PNP).<sup>4–6</sup> However, the complexity of epicardial access increases the procedural risks and thus is not routinely used as first-line therapy. Diaphragmatic compound motor action potential (CMAP) monitoring is routinely used in many centers during right pulmonary vein isolation with cryothermal balloon ablation. The right atrial crista terminalis can be a site of atrial tachycardia (AT), and the PN course along this area could risk PNP during ablation. We report a novel use of diaphragmatic CMAP to prevent PNP in a case of crista terminalis AT ablation.

## Case report

A 28-year-old woman with little past medical history presented with palpitations consistent with supraventricular tachycardia, confirmed by monitoring. She failed conventional medical therapy and was referred for electrophysiologic testing, which revealed AT originating from the crista terminalis. However, sites of earliest activation also had PN capture during pacing. Because of the risk of PNP, no ablation was performed and an antiarrhythmic drug therapy strategy using flecainide was favored. But after failing medical therapy, the patient was referred for a second procedure using advanced management techniques for prevention of PNP.

**KEYWORDS** Atrial tachycardia; Catheter ablation; Compound motor action potential; Phrenic nerve palsy; Supraventricular tachycardia (Heart Rhythm Case Reports 2021;7:739–742)

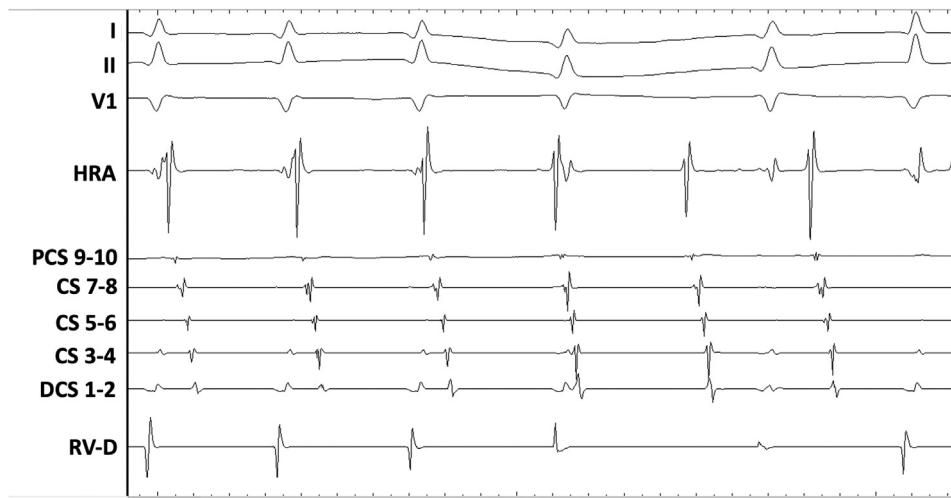All authors have no conflicts of interest or financial disclosures. This research did not receive any specific grant from funding agencies in the public, commercial, or not-for-profit sectors. **Address reprint requests and correspondence:** Dr Jasen L. Gilge, Ascension Medical Group, 8333 Naab Road, #420, Indianapolis, IN 46260. E-mail address: [jasen.gilge@ascension.org](mailto:jasen.gilge@ascension.org).

## KEY TEACHING POINTS

- Atrial tachycardias frequently occur in the right atrium along the crista terminalis, and phrenic nerve injury is a potential complication during catheter ablation.
- Several epicardial techniques have been developed to allow for catheter ablation of atrial tachycardias without injuring the phrenic nerve.
- Compound motor action potential monitoring of the phrenic nerve during atrial tachycardia ablations is another strategy to avoid phrenic nerve injury.

Multiple options were discussed with the patient, including waiting for newer technologies such as pulsed field electroporation; epicardial access and balloon inflation and/or saline injection to lift the PN off the right atrial wall; and a novel strategy to employ diaphragmatic CMAP during ablation to minimize risk of phrenic injury.

The patient preferred the last option, with a backup plan of epicardial access for advanced phrenic management if necessary. The patient was placed under conscious sedation in the electrophysiology laboratory and burst atrial pacing during epinephrine infusion (0.1 mcg/kg/min) easily induced tachycardia (Figure 1). AT was confirmed by standard diagnostic maneuvers. Activation mapping with a multipolar catheter (DECANAV®) using the CARTO® 3, v7 mapping system (Biosense Webster Inc, Diamond Bar, CA) localized the AT to the crista terminalis based on earliest site of activation (Figure 2A and 2B) and 3-D electroanatomic activation map (Supplemental video 1). Given the anatomic location, a PN map was created to identify the PN course by pacing at both 25 mA and 10 mA (at 2 ms pulse width) (Figure 2C).<sup>7</sup> Unfortunately, the PN was juxtaposed to the AT source at all early sites. Therefore,

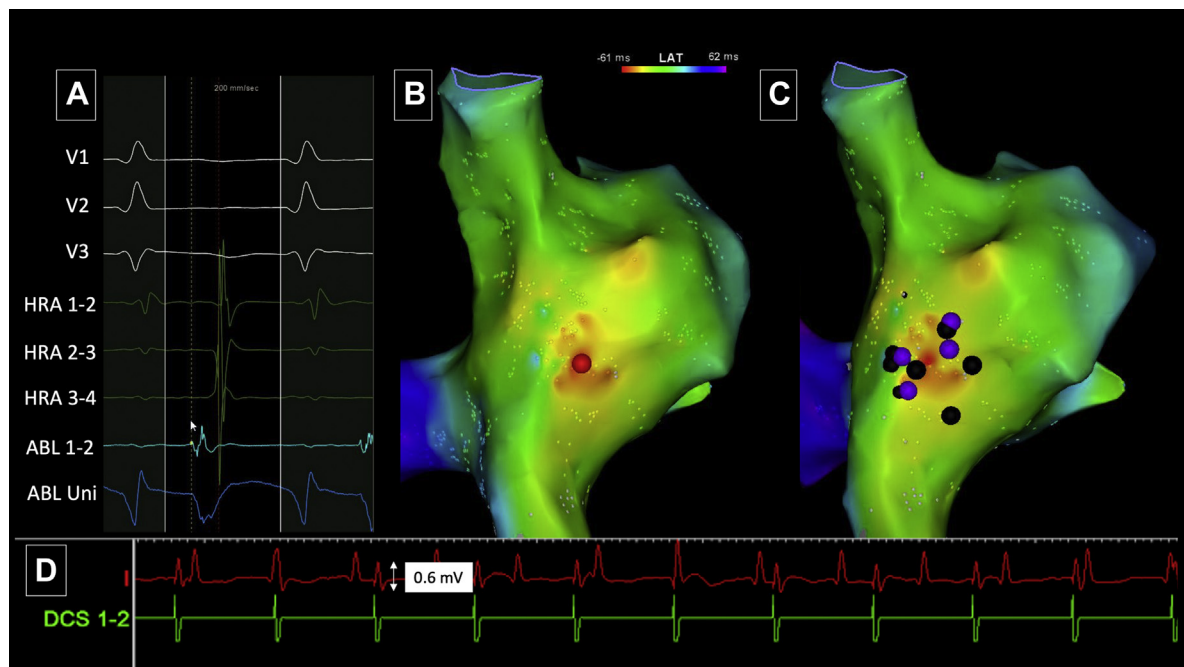


**Figure 1** Atrial tachycardia. Intracardiac electrograms during atrial tachycardia revealed atrial and ventricular dissociation. Atrial activation was concentric with cranial-to-caudal activation. CS = coronary sinus; DCS = distal coronary sinus; HRA = high right atrium; PCS = proximal coronary sinus; RV-D = right ventricle distal.

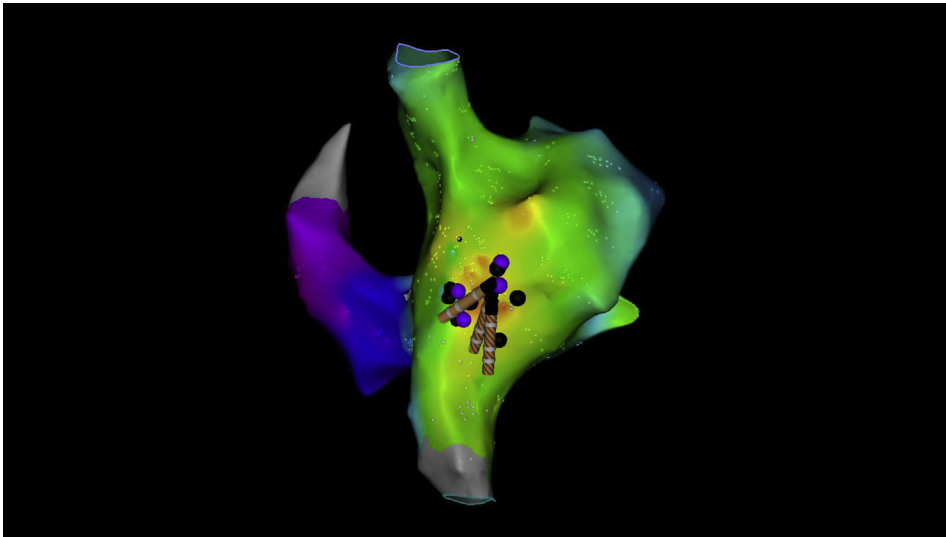
advanced PN management was employed by utilizing diaphragmatic CMAP monitoring.

The DECANAV catheter was positioned in the right brachiocephalic vein where pacing consistently captured the right PN. Right hemidiaphragmatic excursion was assessed by abdominal palpation and monitoring the diaphragmatic CMAP signal. A modified lead I, with the left-arm electrode

placed 16 cm from the xiphoid along the right costal margin and right-arm electrode positioned 5 cm above the xiphoid, was continuously recorded to measure the diaphragmatic CMAP signal amplitude. A 55 mm Medtronic Freezor Xtra ablation catheter (Medtronic, Minneapolis, MN) was advanced into the right atrium and mapped the site of earliest activation. However, continuous PN pacing did result in



**Figure 2** Atrial tachycardia map. **A:** Intracardiac electrogram of the earliest site with a corresponding bipolar and unipolar signal on the ablation catheter. **B:** Activation map revealing focal activation of the right atrium viewed from a posterior lateral projection. The red dot indicates the site of earliest activation and corresponds to the electrograms depicted in panel A. **C:** Phrenic nerve mapping with the black dots indicating phrenic nerve capture at 25 mA while the purple dots indicate capture at 10 mA. Capture of the phrenic nerve at 10 mA suggests the nerve is within 1 cm.<sup>7</sup> **D:** Compound motor action potential monitoring with a 0.6 mV signal that was clear and consistent while pacing the phrenic nerve in the superior vena cava with the coronary sinus catheter. ABL = ablation; Uni = unipolar. Remaining abbreviations are consistent with Figure 1.



**Figure 3** Ablation lesions. The catheter shadow indicates the sites of cryothermal ablation. In a similar posterior lateral projection of the right atrium as in Figure 2, one can appreciate that the early site of activation is surrounded by areas of phrenic nerve capture and required ablation at these sites.

significant patient discomfort, so deeper sedation was obtained using propofol infusion. This rendered the AT noninducible. An anatomic cryoablation, which included 4 adjacent 4-minute freezes at the site of earliest activation, was then performed during PN pacing while continuously monitoring CMAP signals and palpating the abdomen. CMAP signal amplitudes consistently ranged from 0.6 to 0.8 mV (Figure 2D) without significant attenuation. Figure 3 depicts the site of ablation overlaid on the activation and PN map, which demonstrates the close proximity of ablation to the PN. Sedation was weaned and resulted in AT recurrence, but with slower cycle length. This was further mapped and localized approximately 1 cm cranial to the initial site of earliest activation. Deep sedation was administered again, rendering the AT noninducible, and a second anatomic ablation was performed with 4 more adjacent 4-minute lesions during PN pacing. Right hemidiaphragmatic function remained intact, as assessed by abdominal palpation and monitoring of the CMAP signal amplitude. Postablation, sedation was weaned, and AT was no longer inducible despite epinephrine infusion (up to 0.3 mcg/kg/min). During follow-up, the patient initially had palpitations different from her clinical symptoms, which diminished over time without antiarrhythmics, and has no evidence of PNP.

## Discussion

Catheter ablation of AT originating from the lateral right atrial wall can be complicated by its proximity to the right PN, as in our case. We were able to successfully eliminate the tachycardia without causing any injury to the PN, borrowing a technique used in atrial fibrillation cryotherapy ablations. This demonstrates how technical advances in one field can help patients with a different condition.

Several advanced epicardial techniques have successfully allowed for catheter ablation by creating separation between

the atrial myocardium and the PN. However, these techniques require epicardial access followed by balloon inflation or injection of air or saline to distance the PN from the atrium.<sup>4,5</sup> Performing epicardial access can be challenging, with associated increased procedural risks and patient discomfort.<sup>8</sup> Furthermore, this requires general anesthesia, which increases complications and often renders tachycardia noninducible. Though epicardial access techniques are getting safer, routine epicardial procedures are currently only performed at high-volume centers with backup surgical options. Here we describe an approach that allows for endocardial ablation while performing diaphragmatic CMAP monitoring, obviating epicardial access.

CMAP monitoring has gained popularity for its use during atrial fibrillation cryoablation as a way to decrease incidence of right PNP. Franceschi<sup>9</sup> initially described that CMAP was feasible in 88% of patients and resulted in no cases of PNP when used for atrial fibrillation cryoablation. Similarly, Miyazaki<sup>10,11</sup> used this technique while isolating the superior vena cava during atrial fibrillation ablations to prevent PNP. In our case, we employed the same technique to closely monitor the diaphragm CMAP while ablating along the lateral right atrium. Monitoring was technically simple and only required advancing a catheter into the right brachiocephalic vein and adjusting the right- and left-arm electrodes to create a modified lead I.

There were some drawbacks to using CMAP in our case. We were unable to perform ablation during tachycardia because we elected for deep sedation, given the patient's discomfort with continuous PN pacing. The inability to observe the tachycardia termination during ablation could reduce the success rates and may have implications for long-term success. Yet, deep sedation would also be required for epicardial access and would be fraught with the same obstacle. We chose cryothermal ablation in this case to follow the protocol used in atrial fibrillation ablations with CMAP.

Performing cryoablation along the lateral right atrial wall may not have as durable a success as radiofrequency ablation. Finally, the CMAP technique does not completely eliminate the risk of PNP and is merely an added tool to reduce the risk.

## Conclusion

Atrial tachycardias in the absence of prior ablation or cardiac surgery are an infrequent cause of supraventricular tachycardia but frequently occur along the crista terminalis in the right atrium. Catheter ablation of AT is an effective treatment strategy with a good safety profile. One potential complication that can occur is PNP if the PN courses along the origin of the AT focus. Advanced techniques using epicardial access to cause mechanical separation between the PN and atrial myocardium can be technically difficult. Our case demonstrates another possible solution to minimize PNP during AT ablation using diaphragm CMAP monitoring during cryoablation.

## Appendix Supplementary data

Supplementary data associated with this article can be found in the online version at <https://doi.org/10.1016/j.hrcr.2021.08.001>.

## References

1. Porter MJ, Morton JB, Denman R, et al. Influence of age and gender on the mechanism of supraventricular tachycardia. *Heart Rhythm* 2004;1:393–396.
2. Morton JB, Sanders P, Das A, et al. Focal atrial tachycardia arising from the tricuspid annulus: electrophysiologic and electrocardiographic characteristics. *J Cardiovasc Electrophysiol* 2001;12:653–659.
3. Bai R, Patel D, Di Biase L. Phrenic nerve injury after catheter ablation: should we worry about this complication. *J Cardiovasc Electrophysiol* 2006;17:944–948.
4. Buch E, Vaseghi M, Cesario DA, Shivkumar K. A novel method for preventing phrenic nerve injury during catheter ablation. *Heart Rhythm* 2007;4:95–98.
5. Matsuo S, Jais P, Knecht S, et al. Images in cardiovascular medicine: novel technique to prevent left phrenic nerve injury during epicardial catheter ablation. *Circulation* 2008;117:e471.
6. Di Biase L, Burkhardt JD, Pelargonio G. Prevention of phrenic nerve injury during epicardial ablation: comparison of methods for separating the phrenic nerve from the epicardial surface. *Heart Rhythm* 2009;6:957–961.
7. Squara F, Desjardins B, Marchlinski FE, et al. Prospective 3-dimensional computed tomographic segmentation of the pericardiac right phrenic nerve in the setting of atrial fibrillation ablation. *Circ Arrhythm Electrophysiol* 2014;7:561–562.
8. Sacher F, Roberts-Thomas K, Maury P, et al. Epicardial ventricular tachycardia ablation. A multicenter safety study. *J Am Coll Cardiol* 2010;55:2366–2372.
9. Franceschi F, Koutbi L, Mancini J, et al. Novel electromyographic monitoring technique for prevention of right phrenic nerve palsy during cryoballoon ablation. *Circ Arrhythm Electrophysiol* 2013;1:109–114.
10. Miyazaki S, Kusa S, Hachiya H, et al. Electrical superior vena cava isolation using a novel pace-and-ablate technique under diaphragmatic electromyography monitoring. *Heart Rhythm* 2017;14:678–684.
11. Miyazaki S, Ichihara N, Nakamura H, et al. Prospective evaluation of electromyography-guided phrenic nerve monitoring during superior vena cava isolation to anticipate phrenic nerve injury. *J Cardiovasc Electrophysiol* 2016;27:390–395.