

ORIGINAL RESEARCH ARTICLE

Incidence and risk factor of outlet obstruction after construction of ileostomy

Gaku Ohira, Hideaki Miyauchi, Koichi Hayano, Akiko Kagaya, Shunsuke Imanishi, Toru Tochigi,
Tetsuro Maruyama and Hisahiro Matsubara

Department of Frontier Surgery, Graduate School of Medicine, Chiba University

Abstract:

There are several reports on the usefulness of diverting ileostomy for decreasing the incidence of anastomotic leakage and the severity of pelvic peritonitis. However, a number of complications induced by ileostomy itself have also been reported, including a special condition induced by obstruction at the outlet of the stoma known as “outlet obstruction.” In this study, we examined the frequency and risk factors of this complication based on the data of ileostomy cases in our institution. Methods: One hundred and seven patients who received ileostomy creation at our department from January 2010 to December 2015 were included. The incidence of outlet obstruction and risk factors were analyzed. Results: Outlet obstruction occurred in 18 cases (16.8%). The incidence was significantly higher in total colectomy or proctocolectomy cases as well as in those with left side construction and laparoscopic surgery than in other patients in a univariate analysis. However, in a multivariate analysis, no risk factors were extracted. Conclusions: To determine the true cause of this disease, a prospective study with a large number of cases is needed. Since multiple terms are used for this condition, resulting in confusion, a consensus on the appropriate terms is also important.

Keywords:

outlet obstruction, ileostomy, risk factor, ulcerative colitis, rectal cancer

J Anus Rectum Colon 2018; 2(1): 25-30

Introduction

Anastomotic leakage is one of the most severe and life-threatening complications that may occur after restorative proctocolectomy for ulcerative colitis or familial colonic polyposis or after low anterior resection for rectal cancer. There are many reports concerning the effect of diverting ileostomy on reducing the incidence of anastomotic leakage and the severity of pelvic peritonitis¹⁻³. However, a number of complications induced by ileostomy itself have also been reported, including peristoma dermatitis, stoma ischemia, stoma retraction, high-output stoma, and bowel obstruction as early complications and parastomal hernia, stenosis, and prolapse as late complication^{4,5}.

Bowel obstruction includes a special condition induced by

obstruction at the outlet of the stoma called “outlet obstruction.” However, a consensus has yet to be reached regarding the designation and naming of this complication, and the cause and risk factors also vary among reports⁶⁻¹⁰.

In the present study, we examined the incidence and risk factors of this complication based on the data of ileostomy cases at our institution. We used the term “outlet obstruction” for this complication in our report.

Methods

Method of ileostomy construction at our institution

- *Stoma site*

In all cases planned to construct ileostomy, the stoma site

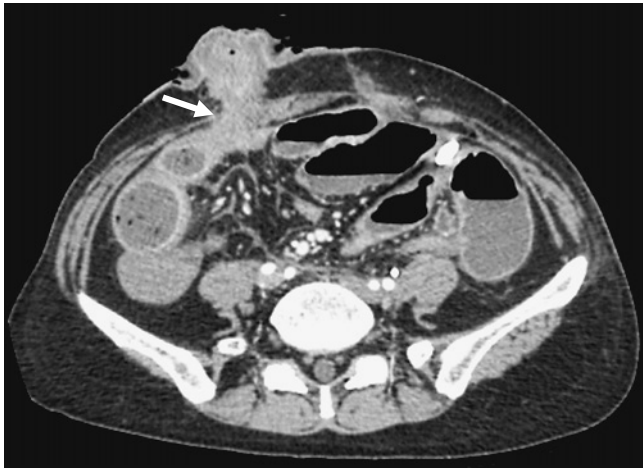


Figure 1. Computed tomography image of the case who develop outlet obstruction. The ileum just before the outlet site of ileostomy is dilated (arrow).

was marked before surgery, mainly according to the principle of Cleveland clinic. When prepared as a diverting stoma for rectal cancer or sigmoid colon cancer, it was shifted to the lower right quadrant. In other cases, sidedness was decided intraoperatively according to the ease of lifting without difficulty. The ileum to be raised was set about 30 cm orally from the Bauhin valve or the anastomotic portion.

- *Stoma direction*

Attention was focused on achieving natural lifting without torsion, regardless of turning the mouth side towards the anus side.

- *Stoma form*

A loop ileostomy was constructed orally from the anastomotic site. In cases in which anastomosis was not performed, end ileostomy or a double-barrel type stoma was constructed.

- *Fasciotomy*

A cross incision was made at the anterior sheath, and a longitudinal incision was made at the posterior sheath of the rectus abdominis.

- *Fixation to the abdominal wall*

The serosa and muscle layer of the intestine were fixed to the anterior sheath of the rectus abdominis with four to eight stitches using absorbable suture materials.

Diagnosis of outlet obstruction

The occurrence of outlet obstruction was defined as intestinal obstruction after ileostomy with the part penetrating the abdominal wall proven to be the cause of obstruction on computed tomography (CT) (Figure 1).

Study items

The patients who underwent ileostomy creation at our department from January 2010 to December 2015 were in-

cluded.

The incidence of CTCAE (Common Terminology Criteria for Adverse Events) grade 3 or higher outlet obstruction, period of occurrence after surgery, treatment, and post-treatment course were examined. The clinical factors were compared between cases with and without outlet obstruction. As background factors, the age, gender, height, weight, body mass index (BMI), emergency or elective surgery, amount of bleeding, operation time, surgical procedure, and receipt of laparoscope assistance or open surgery were examined. For the ileostomy, its position, direction, form, and permanence were examined. In addition, the thickness of the rectus abdominis and abdominal wall based on a slice from the part of the ileostomy penetrating the abdominal wall in 100 cases examined with CT before closure of the ileostomy was measured and compared between cases with and without outlet obstruction.

This study was performed with the permission of the Ethics Committee of our institution.

Statistical analyses

To compare categorical variables such as gender, the chi-squared test or Fisher's accuracy test was used. The Mann-Whitney U test was used to compare continuous variables. A logistic regression analysis was used for the multivariate analysis. The JMP software program, ver. 12 (SAS Institute of Japan, Tokyo, Japan) was used for all statistical analyses.

Results

Patients' background

A total of 107 patients were included in this study, and the patient background data are shown in Table 1. There were 38 patients with colorectal cancer and 30 with ulcerative colitis. Emergency surgery was performed in 39 cases (36.4%). Temporary stoma was performed in the majority of cases (n = 92), 9 of which were unclosed.

Incidence of outlet obstruction

Outlet obstruction occurred in 18 cases (16.8%). The median number of days until occurrence after construction of ileostomy was 5.5 (range: 2-96 days). There were 15 cases requiring interventional radiology (IVR) after onset, and 8 of them did not improve and were forced to have their stoma closed earlier than scheduled. Three patients recovered by simply stopping meals and replacement fluid.

Among cases of total colectomy or proctocolectomy, the incidence of outlet obstruction was 27.8%, whereas the incidence in other cases was 11.3%.

Risk factors for the occurrence of outlet obstruction

In the univariate analysis, the incidence was significantly

Table 1. Patient Background.

		61 y.o. (17-83)
Age		61 y.o. (17-83)
Sex	Male	60 (56.1 %)
	Female	47 (43.9 %)
Disease (overlap exist)	Ulcerative colitis	30 (28.0 %)
	Rectal cancer	29 (27.1 %)
	Anastomotic leakage	10 (9.3 %)
	Colonic cancer	9 (8.4 %)
	Familial adenomatous polyposis	3 (2.8 %)
	Others	32 (29.9 %)
	Elective or emergency	Elective
Emergency		39 (36.4 %)
Surgical procedure	Total colectomy or proctocolectomy	36 (33.6 %)
	Others	71 (66.4 %)
Laparoscopic	Open surgery	86 (80.4 %)
	Laparoscopic surgery	21 (19.6 %)
Temporary or permanent	Temporary	92 (86.0 %) (83 already closed)
	Permanent	15 (14.0 %)
Stoma site	Right side	71 (66.4 %)
	Left side	36 (33.6 %)
Stoma form	Loop stoma	88 (82.2 %)
	End stoma	19 (17.8 %)
Stoma direction	Oral-cranial	60 (56.1 %)
	Oral-caudal	22 (20.6 %)
	Unclear	25 (23.4 %)

Ulcerative colitis and rectal cancer accounted for about one-third of the total. Temporary stoma was performed in the majority of cases (n = 92), 9 of which were unclosed.

higher among those receiving total colectomy or proctocolectomy, left side construction, or laparoscopic surgery than among others. A multivariate analysis was performed on factors with P value < 0.2, but none were extracted as independent risk factors for the occurrence of this disease (Table 2).

No significant risk factors were extracted in total colectomy or proctocolectomy cases nor in rectal cancer cases by a univariate analysis (Table 3).

Discussion

Obstruction at the portion of an ileostomy penetrating the abdominal wall has been recognized. Several reports about this phenomenon, named “ileostomy dysfunction” and accompanied by abdominal pain and high output intestinal fluid excretion, were published in the 1950s, and this phenomenon was suspected at the time of being caused by partial obstruction at the ileostomy outlet^{11,12}. It was reported that obstruction was reduced by inserting a tube into the oral side of the ileostomy for several days, and its excretion also decreased. Recently, “ileostomy dysfunction” has been described as a complication developed by the creation of an ileostomy without inverting the mucosa and is a rare occur-

rence now¹³. However, since this complication is improved by tube insertion from a stoma, the concept of “ileostomy dysfunction” may include outlet obstruction. Hughes et al.¹⁴ reported occlusion at the outlet of stoma, and subsequently, outlet obstruction came to be cited as a cause of intestinal obstruction after ileostomy construction. However, there have been few reports focused on outlet obstruction, and in recent years, it has only been mainly reported from Japan^{7-10,15}.

Regarding the designation of this disease, the CTACAE v4.0 describes it as intestinal stoma obstruction¹⁶, but in the literature, it is called outlet obstruction⁶⁻⁹, stoma-related obstruction¹⁰, or ileostomy obstruction⁵, among other terms. There is substantial confusion regarding the name of this condition. In the present report, we adopted the term “outlet obstruction,” which is the most commonly reported term. “Outlet obstruction” was first used in a report by Oliveria et al.⁶ and later by Uchino et al.⁷, Fujii et al.⁸, and Munakata et al.⁹.

The incidence of this disease varies among reports. Warren et al. described the incidence of ileostomy dysfunction in the ulcerative colitis patients as 62%¹¹, but this value is not accurate, as ileostomy dysfunction is a concept including high-output stoma, as mentioned above. The incidence after

Table 2. Result of the Univariate and Multivariate Analysis in All Cases.

		Univariate analysis			Multivariate analysis		
		OO † (-) N = 89	OO (+) N = 18	P value	Odd ratio	P value	95%CI
Age (y.o.)		62 (17-83)	60 (18-74)	0.3114			
Sex	Male	52	8				
	Female	37	10	0.2756			
Disease	Benign	38	6				
	Malignant	51	12	0.3208			
Body weight (kg)		54 (33.8-82)	49 (38-78.4)	0.2507			
Height (cm)		162 (140-180)	161 (142-174.2)	0.5728			
Body mass index (kg/m ²)		21 (14.2-32.9)	21 (16-29.1)	0.4071			
Elective or emergency	Elective	57	11				
	Emergency	32	7	0.8135			
Surgical procedure	Total colectomy or proctocolectomy	26	10		1.34	0.0859	0.21-8.17
	Others	63	8	0.0310			
Laparoscopic surgery	Yes	13	8		2.97	0.0859	0.85-10.4
	No	76	10	0.0072			
Post-operative complication (without OO)	Yes	63	13				
	No	26	5	0.9025			
Stoma site	Right side	63	8				
	Left side	26	10	0.0310	1.57	0.6152	0.26-8.78
Stoma form	Loop stoma	71	17		2.54	0.3442	0.42-48.9
	End stoma	18	1	0.1375			
Stoma direction	Oral-cranial	49	11				
	Oral-caudal	17	5	0.6564			
Operation time (min)		258 (58-795)	312 (59-570)	0.2470			
Blood loss (g)		430 (0-7240)	253 (0-4090)	0.4142			
Thickness of abdominal wall (cm)		26 (10-48)	27 (16-34)	0.6861			
Thickness of RAM ‡ (cm)		10 (4-17)	9 (4-14)	0.9743			
Distance from Bauhin's valve or anastomosis (cm)		30 (15-60)	33 (20-60)	0.2692			

†: Outlet obstruction. ‡: Rectus abdominal muscle

The incidence of outlet obstruction was significantly higher among those receiving total colectomy or proctocolectomy, left side construction, or laparoscopic surgery than among others. A multivariate analysis performed on factors with P value < 0.2 extracted no independent risk factors for the occurrence of outlet obstruction.

total colectomy or proctocolectomy has been reported to be about 25%^{7,10}, which is roughly the same as that noted in this study (27.8%). In other cases, such as low anterior resection with ileostomy, the incidence is reported to be relatively low (10.6% by Munakata et al.⁹), and a similar result was also obtained in this study (11.3%). The total colectomy or proctocolectomy procedure itself may in fact be a risk factor for outlet obstruction.

Although the etiology of this disease has been reported as torsion or adhesion just below the abdominal wall penetrating part of the ileostomy¹⁷⁻¹⁹, a definite cause has yet to be determined. As risk factors for this disease, Uchino et al. reported cross incision of the rectus abdominis muscle sheath and torsion of the mesentery⁷, Okita et al. reported a young age and low BMI¹⁰, and Kanazawa et al. reported a thick-

ness of the rectus abdominis muscle ≥ 10 mm¹⁵. As mentioned above, total colectomy or proctocolectomy may also be risk factors.

In the present study, the incidence rate was significantly higher in laparoscopic cases, cases with left-sided stoma, and total colectomy or proctocolectomy cases than others in a univariate analysis. After resection of the large bowel, the movable area of the small intestine increases, suggesting that the risk of torsion may increase. Dolejs et al. reported that torsion and kinking around the stoma are likely to occur after laparoscopic surgery because of less adhesion than with open surgery²⁰, which may explain the results of the present study. The high incidence in left-sided stoma cases may be due to our surgical procedure: we often make ileostomy at the left side of the abdominal wall after total colectomy or

Table 3. Result of the Univariate and Multivariate Analysis in Total Colectomy or Proctocolectomy Cases.

		Univariate analysis		
		OO † (-) N = 26	OO (+) N = 10	P value
Age (y.o.)		50 (17-69)	44 (18-70)	0.4164
Sex	Male	13	4	0.8679
	Female	13	6	
Disease	Benign	21	8	1.0
	Malignant	5	2	
Body weight (kg)		53 (39-77.6)	43 (38-63.5)	0.3140
Height (cm)		161 (143-175.8)	160 (142-174.2)	1.0
Body mass index (kg/m ²)		20 (15-30)	17 (16-23.4)	0.1574
Elective or emergency	Elective	18	6	0.7004
	Emergency	8	4	
Laparoscopic surgery	Yes	9	6	0.1681
	No	17	4	
Post-operative complication (without OO)	Yes	18	8	0.6895
	No	8	2	
Stoma site	Right side	6	8	0.6454
	Left side	20	10	
Stoma form	Loop stoma	22	17	0.5586
	End stoma	4	1	
Stoma direction	Oral-cranial	19	11	1.0
	Oral-caudal	2	5	
Operation time (min)		328 (99-795)	308 (160-570)	0.8460
Blood loss (g)		323 (0-6540)	235 (130-1180)	0.6335
Thickness of abdominal wall (cm)		30 (11-44)	23 (19-31)	0.1826
Thickness of RAM ‡ (cm)		12 (5-16)	11 (5-14)	0.3815
Distance from Bauhin's valve or anastomosis (cm)		40 (30-60)	43 (30-50)	0.8738

†: Outlet obstruction. ‡: Rectus abdominal muscle

No significant risk factors were extracted in total colectomy or proctocolectomy cases by a univariate analysis.

proctocolectomy, which might have affected the results.

In the examination of the intraluminal pressure of the small bowel, Sasabe et al. reported that the typical intraluminal pressure of 9 to 10 cmH₂O rises to about 15 cmH₂O in cases of obstructive²¹⁾. In contrast, however, Yamato et al. reported that the average intraluminal pressure during the peristaltic movement of the colon is 120.4 mmHg²²⁾, and the intraluminal pressure of the colon is much higher than that of the small intestine. When outlet obstruction occurs, a finger or a tube can usually be inserted easily via the ileostomy with almost no resistance. It is therefore undeniable that the low pressure in the small intestine may cause obstruction at such a low pressure of the stoma outlet.

In this study, the incidence rate of outlet obstruction was significantly higher in laparoscopic cases and total colectomy or proctocolectomy cases than others in a univariate analysis, which may be because the movable area of the small intestine increases after resection of the large bowel with less adhesion due to laparoscopic surgery. However,

these conditions are usually unpreventable, especially in laparoscopic total colectomy or proctocolectomy. Therefore, our current strategy to avoid outlet obstruction is not to make ileostomy for patients who are less likely to be anastomotic leakage, such as those who were performed restorative proctocolectomy with tension free ileal-pouch anal anastomosis. With use of preoperative CT, we are trying to predict leakage risk of ileal-pouch anal anastomosis²³⁾.

A limitation associated with this study warrants mention. This is a retrospective study with a small number of cases in a single institution, which may explain why no significant risk factors could be extracted by a multivariate analysis. To determine the true cause of this disease and prophylaxis measures, a prospective study with a large number of cases is needed. In addition, a consensus on the appropriate term for this disease is also important in order to investigate the pathology.

Conflicts of Interest

There are no conflicts of interest.

References

1. Tan WS, Tang CL, Shi L, et al. Meta-analysis of defunctioning stomas in low anterior resection for rectal cancer. *Br J Surg*. 2009; 96: 462-72.
2. Matthiessen P, Hallböök O, Rutegard J, et al. Defunctioning stoma reduces symptomatic anastomotic leakage after low anterior resection of the rectum for cancer: a randomized multicenter trial. *Ann Surg*. 2007 Aug; 246(2): 207-14.
3. Weston-Petrides GK, Lovegrove RE, Tilney HS, et al. Comparison of outcomes after restorative proctocolectomy with or without defunctioning ileostomy. *Arch Surg*. 2008 April; 143(4): 406-12.
4. Shabbir J, Britton DC. Stoma complications: a literature overview. *Colorectal Dis* 2010; 12: 958-64.
5. Steele SR, Hull TL, Read TE, et al, editors. *The ASCRS Text Book of Colon and Rectal Surgery*. 3rd edition. Springer; 2016. Chapter 55, McGee MF, Cataldo PA. Intestinal stomas, 971-1013.
6. Oliveria L, Reissman P, Noguera J, et al. Laparoscopic creation of stomas. *Surg Endosc*. 1997 Jan; 11(1): 19-23.
7. Uchino M, Ikeuchi H, Bando T, et al. Efficacy of a Cross Incision at the Rectal Muscle Fascia and Ileostomy Rotation for Prevention of Outlet Obstruction at the Ostomy Site in Restorative Proctocolectomy for Ulcerative Colitis. *Nippon Daicho Komonbyo Gakkai Zasshi* 2011; 64: 73-7.
8. Fujii T, Morita H, Sutoh T, et al. Outlet obstruction of temporary loop diverting ileostomy. *Hepatogastroenterology*. 2015 May; 62(1): 602-5.
9. Munakata S, Kawai M, Takehara K, et al. Postoperative Outlet Obstruction in Rectal Cancer Patients with Ileostomy. *Nippon Gekakei Rengou Gakkai Zasshi* 2015; 40: 20-4.
10. Okita Y, Araki T, Kondo S, et al. Clinical Characteristics of Stoma-Related Obstruction after Ileal Pouch-Anal Anastomosis for Ulcerative Colitis. *J Gastrointest Surg*. 2017 Mar; 21(3): 554-9.
11. Warren R, McKittrick LS. Ileostomy for ulcerative colitis; technique, complications and management. *Surgery Gynecol Obstet*. 1951 Nov; 93(5): 555-67.
12. Crile G Jr, Turnbull RB Jr. The mechanism and prevention of ileostomy dysfunction. *Ann Surg* 1954 Oct; 140(4): 459-66.
13. Wolff BG, Fleshman JW, Beck DE, et al. editors. *The ASCRS Textbook of Colon and Rectal Surgery*. Springer; 2007. Chapter 44. Orkin BA, Cataldo PA. Intestinal Stomas. 622-42.
14. Hughes ES, McDermott FT, Masterton JP. Intestinal obstruction following operation for inflammatory disease of the bowel. *Dis Colon Rectum*. 1979; 22: 469-71.
15. Kanazawa A, Shiozawa M, Inagaki D, et al. A Study on Postoperative Ileus in Patients with Ileostomy as a Diverting Stoma after Low Anterior Resection. *Nippon Daicho Komonbyo Gakkai Zasshi* 2009; 62: 497-501.
16. Common Terminology Criteria for Adverse Events (CTCAE) Version 4.0 [internet]. U. S. Department of Health and Human Services National Institutes of Health [Published May 28, 2009 (v4. 03: June 14, 2010)]. Available from <https://www.cancer.gov/>
17. Marcello PW, Roberts PL, Schoetz DJ, et al. Obstruction after ileal pouch-anal anastomosis: a preventable complication? *Dis Colon Rectum*. 1993 Dec; 36(12): 1105-11.
18. Anderson DN, Driver CP, Park KG, et al. Loop ileostomy fixation: a simple technique to minimize the risk of stomal volvulus. *Int J Colorectal Dis*. 1994 Aug; 9(3): 138-40.
19. Ng KH, Ng DC, Cheung HY, et al. Obstructive complications of laparoscopically created defunctioning ileostomy. *Dis Colon Rectum*. 2008 Nov; 51(11): 1164-8.
20. Dolejs S, Kennedy G, Heise CP. Small bowel obstruction following restorative proctocolectomy: affected by laparoscopic approach? *J Surg Research*. 2011 Oct; 170(2): 202-8.
21. Sasabe H, Onda M, Tanaka N, et al. Significance of Selective Small Bowel Intraluminal Pressure for the Management of Adhesive Small Bowel Obstruction. *Jpn J Gastroenterol Surg*. 2000; 33: 1473-82.
22. Yamato S, Matsueda K, Akiyama J, et al. Methods for Studying Colonic Motility in Man: Infusion System vs Micro-transducer System. *Therapeutic Research* 1997; 18 sup 2: 215-6.
23. Ohira G, Miyauchi H, Narushima K, et al. Predicting difficulty in extending the ileal pouch to the anus in restorative proctocolectomy: investigation of a simple predictive method using computed tomography. *Colorectal Disease* 2016 Jan; 19(1): 34-8.

Journal of the Anus, Rectum and Colon is an Open Access article distributed under the Creative Commons Attribution-NonCommercial-NoDerivatives 4.0 International License. To view the details of this license, please visit (<https://creativecommons.org/licenses/by-nc-nd/4.0/>).