



Case report

Rapid anterior capsular phimosis after cataract surgery in a patient with chronic angle closure glaucoma



Pei-Yao Chang^{a, b, *}, Shu-Wen Chang^{a, b}

^a Department of Ophthalmology, Far Eastern Memorial Hospital, Ban-Chiao, Taipei, Taiwan

^b Department of Ophthalmology, National Taiwan University Hospital, Taipei, Taiwan

ARTICLE INFO

Article history:

Received 22 August 2014

Received in revised form

8 October 2014

Accepted 9 October 2014

Available online 2 December 2014

Keywords:

anterior capsular contraction syndrome
continuous curvilinear capsulorrhexis
hydrophilic intraocular lens

ABSTRACT

We report a case of complete occlusion of capsulorrhexis opening in a patient with chronic angle closure glaucoma with fixed–dilated pupil in the following 2 weeks after an uneventful cataract surgery. The capsulorrhexis diameter was intended to make between 5.0 mm and 5.5 mm, to prevent photophobia afterward. There was no evidence of zonular weakness on preoperative examination or during the surgery. Nd:YAG anterior capsulotomy was performed for capsular phimosis and to enlarge capsulorrhexis. The patient regained her visual acuity 3 days after laser treatment, and no pseudophakodonesis, intraocular lens decentration, and re-phimosis were noted at the 3-month follow-up.

Copyright © 2014, The Ophthalmologic Society of Taiwan. Published by Elsevier Taiwan LLC. All rights reserved.

1. Introduction

Complications of an uneventful cataract surgery with continuous curvilinear capsulorrhexis (CCC) are usually related to the remaining capsule, including capsule opacification and subsequent fibrosis. Even though fibrosis is more frequent in the posterior capsule, it may still involve the anterior part. Anterior capsular contraction syndrome (ACCS) or capsule phimosis is an exaggerated fibrotic response reducing the size of the anterior capsulotomy and capsular bag diameter.¹ It often results in clinically significant reduction in vision secondary to not only central opacification, but also intraocular lens (IOL) decentration and tilt. Maximal rate of contraction appears to occur within the first 6 weeks following surgery.² We report a case of complete anterior capsular phimosis occurring in the following 2 weeks after implantation of a hydrophilic acrylic aspheric monofocal IOL (C flex 970C; Rayner, Hove, East Sussex, United Kingdom) in a patient with chronic angle closure glaucoma.

2. Case Report

A 65-year-old woman had an acute attack of angle closure glaucoma with pupillary block of both eyes in March 2011. The

intraocular pressure (IOP) of both eyes was over 60 mmHg at emergency room. Bilateral IOP was maintained below 21 mmHg with antiglaucoma medications; however, bilateral pupil was fixed–dilated even under topical 2% pilocarpine four times per day. Laser iridotomy was performed in bilateral eyes 3 days after the attack. Her cup-to-disc ratio was 80% in the right eye and 60% in the left eye. The anterior chamber depth was 2.05 mm in the right eye and 2.16 mm in the left eye, and the axial lengths were 21.34 mm (right) and 21.09 mm (left). Bilateral IOP was controlled around 12–18 mmHg under regular Cosopt and 2% pilocarpine treatment; however, the pupil was still fixed–dilated. She complained that vision deteriorated during these years. Her best corrected visual acuity was 20/60 in the right eye and 10/60 in the left eye. Cataract with nuclear sclerosis was noted in both eyes. Fundus examination was unremarkable. There was no evidence of zonular weakness on preoperative examination or during the surgery. She denied any history of systemic disease except hypertension, and ophthalmic history was negative for uveitis and pseudoexfoliation.

She underwent uncomplicated phacoemulsification with implantation of a foldable hydrophilic acrylic aspheric monofocal IOL (C flex 970C; Rayner) through a temporal corneal tunnel in the left eye in May 2014. The capsulorrhexis diameter was between 5.0 mm and 5.5 mm. The cortex was completely removed, and we did not perform anterior capsule polishing as our routine surgery. She made a good recovery, achieving an unaided visual acuity of 40/60 1 week after the surgery. The anterior chamber showed 1+ cells, and the IOL was centered. By Postoperative Day 14, the patient presented complaining of worsening blurry vision (20/60 in the left

Conflicts of interest: No author has a financial or proprietary interest in any material or methods mentioned.

* Corresponding author. Department of Ophthalmology, Far Eastern Memorial Hospital, No.21, Sec. 2, Nanya S. Rd., Banciao Dist., New Taipei City 220, Taiwan.

E-mail address: peiyao@seed.net.tw (P.-Y. Chang).

eye). The patient was found to have marked anterior capsular contracture with complete occlusion of the anterior capsulotomy. The anterior chamber was almost silent. Nd:YAG anterior capsulotomy was performed (total energy: 31.5 mJ) for occluded capsulorrhexis opening and to enlarge capsulorrhexis (Fig. 1). Three days after laser treatment, she regained her visual acuity of 40/60 (Fig. 2). Three months later, the refractive error was stabilized within 0.5 D, and no pseudophakodonesis was noted. Re-phimosis did not occur. The diameter of CCC was 4.6 mm (vertical) \times 4.0 mm (horizontal) by slit-lamp measurement 5 months later.

3. Discussion

Although the exact etiology of ACCS is unknown, there are three major risk factors: (1) pre-existing conditions; (2) the initial size of CCC; and (3) the IOL material and design.³ ACCS has been reported in patients with diabetes mellitus,³ uveitis,⁴ pseudoexfoliation,¹ and retinitis pigmentosa.⁵ Zonular dehiscence has also been a predisposing risk factor.⁴ However, our patient did not have these conditions.

The decreases in the anterior capsulotomy aperture and the equatorial diameter of the capsular bag occur more quickly in the first 6 weeks following phacoemulsification surgery, but continue slowly thereafter.² Rapid capsular phimosis was reported in a patient with retinitis pigmentosa 17 days after the implantation of a single piece acrylic AcrySof IOL (Alcon Laboratories) with a 4.5–5 mm CCC.⁵ This case demonstrated that capsular phimosis could develop as soon as 14 days following IOL implantation. Because the contraction was symmetrical and no decentration or tilting of the IOL was noted, zonule dehiscence did not seem to be the risk factor in our patient. The anterior chamber reaction was important to differentiate ACCS from postoperative inflammation-associated membrane formation. The anterior chamber reaction was 1+ 1 week postoperatively and almost silent 2 weeks postoperatively. The inflammatory response was relative within normal range, which could not account for the early ACCS. This case was unusual in that complete occlusion of the capsulorrhexis opening was achieved in a patient with no predisposing risk factor. However, the size of the capsulorrhexis matters because the risk of anterior capsular phimosis may be increased with a smaller capsulorrhexis diameter independently of the IOL biomaterial.² In this case, the possible risk factor might be the smaller-than-ideal-sized

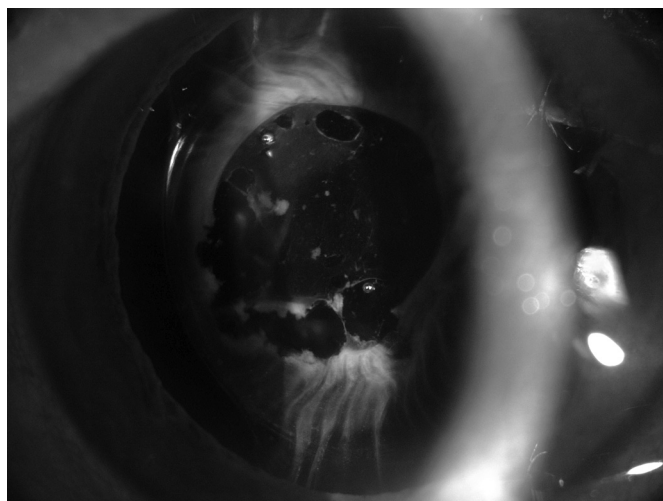


Fig. 1. Slit-lamp biomicroscopy showed anterior capsule phimosis with capsule wrinkle. Nd:YAG anterior capsulotomy was performed for occluded capsulorrhexis opening and to enlarge capsulorrhexis.

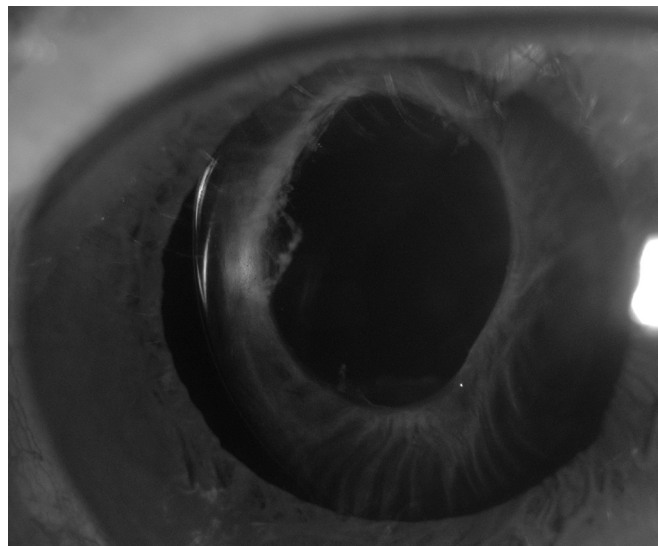


Fig. 2. Slit-lamp biomicroscopy showed enlarged capsulorrhexis 3 days after anterior capsulotomy with Nd:YAG laser.

capsulorrhexis (5.0–5.5 mm), which we intended to make to prevent photophobia after cataract surgery, especially in patients with fixed-dilated pupil. Large CCC (diameter $>$ 5.5 mm) has been found to be related to less capsule contraction.⁶ The interplay between retained lens epithelial cells, capsulorrhexis size, and IOL optic position in relation to capsulorrhexis may be associated with ACCS.⁷ Our case demonstrated that in patients with relatively smaller capsulorrhexis, careful removal of anterior lens epithelial cells, using acrylic IOLs with a square edge design or using capsular tension rings, should be considered to prevent anterior capsular phimosis.

Capsular contraction syndrome has been described following implantation with a variety of types of IOLs, including silicone,² polymethylmethacrylate (PMMA),^{2,4} and more rarely acrylic lenses.⁸ The rate of anterior capsular opacification is lowest with acrylic lenses and higher with plate-haptic silicone lenses.⁹ In acrylic lens, the incidence of ACCS was significantly higher when implanting hydrophilic compared to hydrophobic IOLs.¹⁰ Hydrophobic IOL material may prevent attachment of migrating epithelial cells on the optic and haptic surfaces, and therefore demonstrate a smaller incidence of ACCS formation. This case indicated that implantation of hydrophobic IOL in patients with relatively smaller CCC might be a better choice, considering the risk of ACCS.

The occluded capsule may be cut safely with a YAG laser⁷ or surgically with the use of microscissors.⁴ Since we detected the anterior capsular phimosis soon after it occurred and the occluded capsule was not very thick, we decided to use Nd:YAG laser to treat the phimosis. The timing for capsulotomy remained a point of discussion. Deokule et al⁷ found a higher success rate in eyes undergoing capsulotomy within 6 months compared to those with a delay of $>$ 6 months, although the difference was not statistically significant. We initiated laser treatment soon after we detected the capsular phimosis, because we thought interrupting the pathologic process at an early stage may prevent the severe complication of IOL decentration. Our case illustrated that YAG capsulotomy was effective and safe in treating anterior capsular phimosis in patients with hydrophilic IOL as an early intervention. Further randomized trials are necessary to explore the efficacy, safety, and appropriate timing of Nd:YAG laser treatment for anterior capsular phimosis.

A fixed-dilated pupil was not unusual in patients after an acute attack of angle closure glaucoma; even the IOP was controlled within the normal range. Photophobia after cataract surgery was a

common complaint in these patients. This case reminded us that anterior capsular phimosis may occur soon after IOL implantation in patients with relatively smaller capsulorrhexis. When we make a relatively smaller capsulorrhexis, whether unintentionally or to prevent photophobia, in patients with fixed–dilated pupil, complete removal of anterior lens epithelial cells, using hydrophobic acrylic IOLs with a square edge design or using capsular tension rings, should be considered to prevent anterior capsular phimosis.

Funding/support

This case study was not supported by any grants.

References

1. Davison JA. Capsule contraction syndrome. *J Cataract Refract Surg.* 1993;19:582–589.
2. Zambarakji HJ, Rauz S, Reynolds A, Joshi N, Simcock PR, Kinnear PE. Capsulorrhexis phimosis following uncomplicated phacoemulsification surgery. *Eye.* 1997;11:635–638.
3. Kim EC, Hwang HS, Kim MS. Anterior capsular phimosis occluding the capsulorrhexis opening after cataract surgery in a diabetic patient with high hemoglobin A1c. *Semin Ophthalmol.* 2013;28:68–71.
4. Spang KM, Rohrbach JM, Weidle EG. Complete occlusion of the anterior capsular opening after intact capsulorrhexis: clinicopathologic correlation. *Am J Ophthalmol.* 1999;127:343–345.
5. Nikpoor N, Stone DU. Rapid capsular phimosis in retinitis pigmentosa. *Ophthalmic Surg Lasers Imaging.* 2010;41. <http://dx.doi.org/10.3928/15428877-20100726-12>.
6. Joo CK, Shin JA, Kim JH. Capsular opening contraction after continuous curvilinear capsulorrhexis and intraocular lens implantation. *J Cataract Refract Surg.* 1996;22:585–590.
7. Deokule SP, Mukherjee SS, Chew CK. Neodymium:Yag laser anterior capsulotomy for capsular contraction syndrome. *Ophthalmic Surg Lasers Imaging.* 2006;37:99–105.
8. Sciscio A, Liu C. Anterior capsular phimosis following Acrysof lens insertion. *Br J Ophthalmol.* 1999;83:989–990.
9. Werner L, Pandey SK, Apple DJ, Escobar-Gomez M, McLendon L, Macky TA. Anterior capsule opacification: correlation of pathologic findings with clinical sequelae. *Ophthalmology.* 2001;108:1675–1681.
10. Tsinopoulos IT, Tsaousis KT, Kymionis GD. Comparison of anterior capsule contraction between hydrophobic and hydrophilic intraocular lens models. *Graefes Arch Clin Exp Ophthalmol.* 2010;248:1155–1158.