

Case Report

A Case of Prostatic Carcinoma Manifesting as Cutaneous Facial Nodule

Israel Antonio Esquivel-Pinto, Bertha Torres-Alvarez,
Ramiro Jetzabel Gómez-Villa, and Juan Pablo Castanedo-Cázares 

Department of Dermatology, Hospital Central Dr. Ignacio Morones Prieto, Universidad Autónoma de San Luis Potosí, San Luis, SLP, Mexico

Correspondence should be addressed to Juan Pablo Castanedo-Cázares; castanju@yahoo.com

Received 7 December 2017; Accepted 14 January 2018; Published 26 February 2018

Academic Editor: Giorgio Carmignani

Copyright © 2018 Israel Antonio Esquivel-Pinto et al. This is an open access article distributed under the Creative Commons Attribution License, which permits unrestricted use, distribution, and reproduction in any medium, provided the original work is properly cited.

Prostate cancer is the second most frequently diagnosed cancer worldwide and the fifth most common cause of cancer deaths among men. Cutaneous metastasis is an uncommon phenomenon in prostatic cancer, occurring in 0.06–0.3% of cases. *Case Presentation.* A 56-year-old man presented to our outpatient clinic with a one-month history of a 1.5 cm in diameter, solitary, asymptomatic, purple nodule located on his upper right cheek. After biopsy, prostatic cancer metastasis was diagnosed. *Discussion.* A literature review revealed 59 articles documenting 71 cases of this diagnosis. The review recorded epidemiological data, including age, duration, morphology, location, and outcome of patients. *Conclusions.* The skin is an uncommon site for metastasis of prostate cancer, and the review showed that its presence is associated with a poor prognosis (approximately 10 months from diagnosis).

1. Introduction

Prostate cancer is the second most frequently diagnosed cancer worldwide and the fifth most common cause of cancer deaths among men. In 2012, 1.1 million new cases were diagnosed globally, and more than 300,000 deaths were related to this disease [1]. Its incidence is directly related to the aging population and their socioeconomic development. In developing countries like Mexico, the annual incidence is approximately 6–13 cases per 100,000 inhabitants [2]. Prostate carcinoma may present skin metastases in 0.06–0.3% of cases [3–5]. A cutaneous lesion manifesting a tumor without urologic symptoms is a rare event.

2. Case Report

A 56-year-old man, who was a farmer without relevant medical history, presented to our outpatient clinic with a one-month history of a 1.5 cm in diameter, solitary, asymptomatic, purple nodule located on his upper right cheek. It had a firm consistency, an ulceration in its center, and slightly raised edges surrounded by hematic crusts (Figure 1). He did not refer malaise or unusual osteomuscular pain but

alleged an unintentional loss of weight of approximately 8 kg in the last 10 months without seeking medical attention. Upon further interrogation, the patient mentioned that he had experienced transitory urinary symptoms, including dysuria, frequency, urgency, and urinary retention, one year earlier, but they had resolved spontaneously. Examination of his oral cavity, neck, regional lymph nodes, and the rest of his skin was unremarkable. During urologic exploration, a manual examination of the prostate determined its size to be 40 × 55 mm, with an indurated mass inside without tenderness.

Based on the clinical history and physical examination, diagnoses considered were pyogenic granuloma, amelanotic melanoma, clear cell acanthoma, and basal cell carcinoma. An excisional biopsy was performed. During the 24 hours after surgery, there was continuous bleeding at the biopsy site, so conservative treatment by compression of the site was indicated. After 48 hours, mild hemorrhaging persisted, so the stitches were removed and the wound was explored for the origin of the blood loss. No underlying vessel was found, so vertical mattress sutures were applied to stop the bleeding. We requested blood tests, which evidenced normal coagulation parameters but a low platelet count of 67,000/mm³ and an alkaline phosphatase level of 721 UI/L were found.

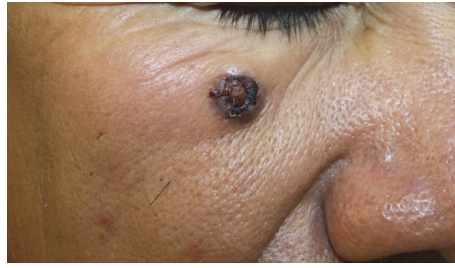

FIGURE 1: Clinical image of lesion. A purple nodule, located on the right cheek, with a diameter of 1.5 cm and an ulcerated center and surrounded by hematic crust having slightly raised edges and a firm consistency.

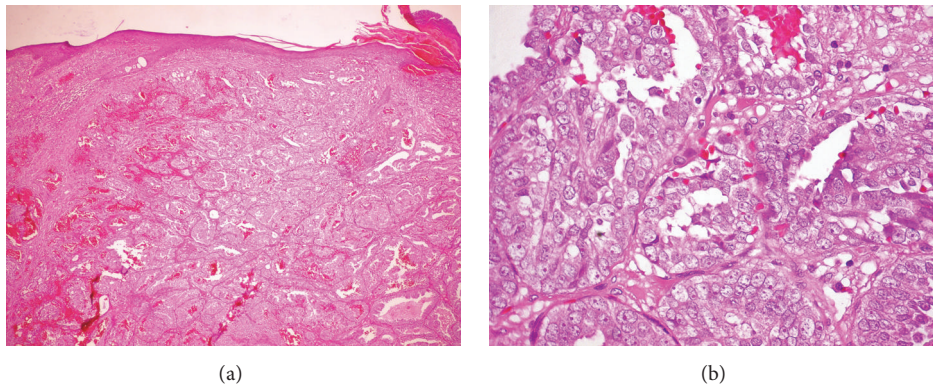


FIGURE 2: (a) The skin biopsy showed abundant hematic crust and ulcerated areas in the epidermis. Ectatic abundant vessels were observed at the entire thickness of the papillary and reticular dermis. (b) Cells with broad, abundant, clear cytoplasm in ductal arrangement were observed. This aspect was suggestive of skin metastases of glandular neoplasia, including prostate or thyroid (hematoxylin-eosin stain; original magnifications: 40x (a); 400x (a, b)).

The biopsy of the skin nodule showed that the papillary and reticular dermis were infiltrated by abundant cells having broad, clear cytoplasm, a ductal arrangement, and ectatic vessels (Figures 2(a) and 2(b)). The aspect was suggestive of metastases from glandular neoplasia, probably thyroid or prostate. The thyroid function profile was normal, but the prostate specific antigen (PSA) was 1124 ng/ml (normal: 4 ng/ml for age group). Immunohistochemistry examination found neoplastic cells positive for PSA (Figures 3(a) and 3(b)), Ki-67, and CD10 in a diffuse and >10% expression, while thyroid transcription, calponin, and thrombomodulin were negative.

Computer tomography (CT) was performed to assess the extent of the neoplasia. Sections of the head showed no further evidence of metastatic lesions. However, abdominal and pelvic segments evidenced a prostate gland size of 40 × 55 mm, in addition to osteolytic lesions in the lumbar vertebral bodies. Therefore, the diagnosis of metastatic prostate ductal adenocarcinoma to the skin was established with a stage of T4, N1, and M1c, which corresponded to a disseminated cancer with poor prognosis at 6 months. The patient was referred to another institution for treatment, where he was treated with hormonal therapy and died after 8 months due to disseminated disease.

3. Discussion

Varied presentations of cutaneous metastases resulting from internal malignancies have been reported and described as diagnostic challenges for clinicians [2]. A review of the literature that searched the PubMed database for “skin cutaneous metastases OR or AND prostatic cancer metastasis prostate cancer” retrieved 59 articles documenting 71 cases of this diagnosis. The mean age was 67 years, with a range of 50–81 years. In 63% of cases, the diagnosis was already known, but it was not specified in 21%. In approximately only 15% of cases, skin lesions helped to establish the initial diagnosis of prostatic cancer [3–60].

The sites of metastasis included the pelvic region in 20 cases, the thorax in 10 cases, the face and neck in 8 cases, the scalp in 8 cases, the limbs in 6 cases, and unspecified sites in 9 cases. The clinical appearances of these cutaneous metastases of prostate cancer were extremely variable, as 31 presented as nodules, 8 as infiltrated plaques, 5 as Sister Mary Joseph’s nodules (a palpable nodule bulging into the umbilicus), 3 as sclerodermiform lesions, 3 as vascular proliferations, 3 as abscesses, 2 as cystic, 2 as zosteriform, and 14 as undescribed. Most cases (65%) presented 2 or more cutaneous lesions at the time of diagnosis [3–61].

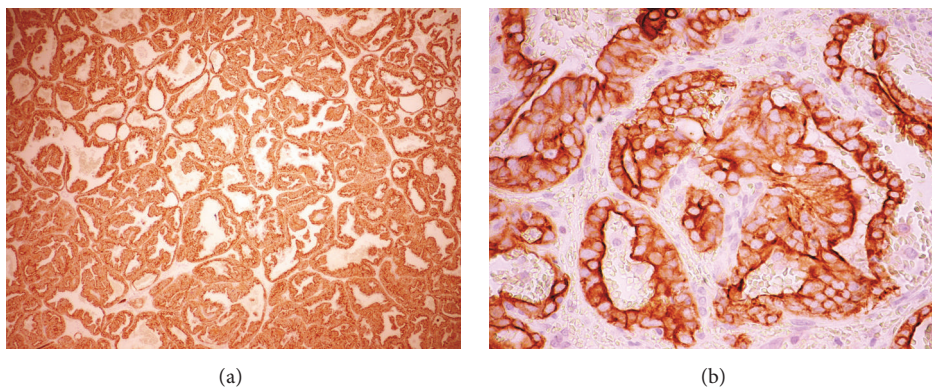


FIGURE 3: Dermal infiltrate positive for prostate specific antigen (PSA). This marker is usually positive in prostatic carcinoma (avidin-biotin-peroxidase complex staining). Original magnifications: 100x (a), and 400x (b).

The histopathologic features of the cutaneous metastatic prostate carcinomas usually were similar to the primary tumor and helped establish the diagnosis. Some features included sheets of undifferentiated cells diffusely infiltrating the dermis, often with a conspicuous Grenz zone; gland-like structures if the primary tumor was of the adenocarcinoma type; and subtle, nuclear atypia characterized by hyperchromasia and prominent eosinophilic nucleoli, although adnexal structures may likewise be infiltrated by malignant cells [3, 9]. Immunohistochemistry was useful to confirm the etiology of the primary tumor in equivocal cases. PSA is a protein produced by cells of the prostate gland and was the most commonly employed stain, as nearly 97% of metastatic prostate carcinomas are positive for this protein [62]. The expression of human Ki-67 protein and CD10 are helpful to the study of suspected metastatic lesions because they are strictly associated with cell proliferation, aggressive migration, and advanced disease [63, 64].

We consider our case important, as the cutaneous expression of a prostatic carcinoma is an infrequent phenomenon, occurring in only 0.06–0.3% of cases. The patient we describe presented an isolated nodule on his face. This was an uncommon morphology and an uncommon site for this metastasis, as only 11% of cases are situated in this area, and the most implicated skin site, accounting for up to 35% of these events, is close to the inguinal region [2]. In addition, this lesion on the cutaneous area of the right cheek was accompanied by no current urologic symptoms, but only by a low platelet count and high levels of alkaline phosphatase. These abnormal parameters were promptly explained by the bone invasion documented by CT, as platelet-count alterations and blood release of alkaline phosphatase may be manifestations of osseous and/or liver metastatic disease [65].

Skin metastasis is a complex process whereby tumor cells acquire the necessary biological properties enabling them to invade it from the primary lesion. These cells spread by lymphatics and/or the bloodstream, survive in the circulation, and extravasate into the dermis to proliferate at the new site [2]. Although the dispersion mechanism in our patient, from genital area to face, is uncertain, it could be explained by its access through the Batson's plexus, a venous system that connects from the vertebral to supradiaphragmatic, cervical, and

head veins [66]. Chymotrypsins, including the human tissue kallikrein 7 (hK7), a secreted serine protease that catalyzes the degradation of intercellular adhesive structures in the cornified layer of the skin, may be involved in the cutaneous manifestation of this neoplasm [66, 67]. Other selectin and receptors may be implied, including the cytosolic R1881 and androgen receptors, although further studies are needed to discern the cutaneous metastatic prostate process [68, 69].

Therapeutic options reported for similar cases of prostatic carcinoma with cutaneous metastasis are primarily palliative and include tumor excision, radiation, intralesional chemotherapy (i.e., leuprolide), and treatment of the primary neoplasia (i.e., chemotherapy, hormonal, or surgical) [3–60]. Such therapies must be carefully selected on a case-by-case basis, but it is notable that treatment of the primary malignancy results in partial improvement of cutaneous metastases in 65% of cases in a period of 4–8 weeks after treatment is begun [3–60].

Although cutaneous metastasis is an uncommon presentation of prostate cancer, it remains an important diagnostic consideration in patients with unrecognized, advanced disease. It should always be considered in cases of rapidly growing cutaneous nodules, especially if they are associated with past or current urologic symptoms and particularly if they are accompanied by persistent bleeding such as that which occurred in our patient. Thus, the suspicions of early interventions by dermatologists, assisted by further histologic studies of cutaneous lesions, play an important role in diagnosis and establishing early treatment, as the mean survival time for the reviewed cases of prostate cancer was approximately 10 months after the onset of skin involvement [3–60].

Conflicts of Interest

All authors declare that they have no conflicts of interest.

References

- [1] International Agency for Research on Cancer and World Health Organization, *Cancer Incidence in Five Continents, Vol 10*, D. Forman, F. Bray, D. H. Brewster et al., Eds., IARC Scientific Publications No. 164, 2014.

- [2] D. P. Lookingbill, N. Spangler, and F. M. Sexton, "Skin involvement as the presenting sign of internal carcinoma. A retrospective study of 7316 cancer patients," *Journal of the American Academy of Dermatology*, vol. 22, no. 1, pp. 19–26, 1990.
- [3] N. Abrol, A. Seth, and P. Chatterjee, "Cutaneous metastasis of prostate carcinoma to neck and upper chest," *Indian Journal of Pathology and Microbiology*, vol. 54, no. 2, pp. 394–395, 2011.
- [4] J. M. Azaña, R. F. de Misa, M. I. Gomez, J. F. del Hoyo, and A. Ledo, "Cutaneous Metastases from Prostatic Cancer," *The Journal of Dermatology*, vol. 20, no. 12, pp. 786–788, 1993.
- [5] C. Bailey and A. Broadbent, "Cutaneous metastases of prostate cancer," *Journal of Palliative Medicine*, vol. 10, no. 4, pp. 980–982, 2007.
- [6] M. Abdelmalek, J. Han, and H. Allen, "Diffuse cutaneous nodules. Arch Dermatol," in *Allen H. Diffuse cutaneous nodules. Arch Dermatol*, pp. 143–937, 143, 937–42, 2007.
- [7] C. H. Bangma, W. J. Kirkels, S. Chadha, and F. H. Schroder, "Cutaneous metastasis following laparoscopic pelvic lymphadenectomy for prostatic carcinoma," *The Journal of Urology*, vol. 153, no. 5, pp. 1635–1636, 1995.
- [8] J. S. Boswell and M. D. P. Davis, "Violaceous plaque on the forehead clinically resembling angiosarcoma: Cutaneous metastasis in a patient with prostatic adenocarcinoma [7]," *Journal of the American Academy of Dermatology*, vol. 53, no. 4, pp. 744–745, 2005.
- [9] G. Brown, D. Kurtzman, F. Lian, and J. Sligh, "Eruptive nodules of the head and neck: A case report of metastatic prostate cancer," *Dermatology Online Journal*, vol. 20, no. 2, article no. 11, 2014.
- [10] G. T. Brown, V. Patel, and C.-C. R. Lee, "Cutaneous metastasis of prostate cancer: a case report and review of the literature with bioinformatics analysis of multiple healthcare delivery networks," *Journal of Cutaneous Pathology*, vol. 41, no. 6, pp. 524–528, 2014.
- [11] J. M. Castillo Jimeno, I. Querol Nasarre, E. Urbiola Marcilla et al., "Lethality of prostatic origin," *Archivos Españoles de Urología*, vol. 47, no. 10, pp. 1026–1028, 1994.
- [12] K. Cecen, M. A. Karadag, A. Demir, and R. Kocaaslan, "Small cell carcinoma of the prostate presenting with skin metastasis: A case report," *Journal of Medical Case Reports*, vol. 8, no. 1, article no. 146, 2014.
- [13] MS. Doutre, C. Beylot, P. Bioulac, M. Conte, and A. De Mascarel, "Cutaneous metastases of a prostatic cancer. Apropos of a case. Ann Pathol," in *De Mascarel A. Cutaneous metastases of a prostatic cancer. Apropos of a case. Ann Pathol*, p. 234, 7, 234–6, 1987.
- [14] R. L. Fiorelli, L. H. Finkelstein, and J. J. Fernandes, "Metastasis of prostate gland adenocarcinoma to penile and scrotal cutaneous tissues," *The Journal of the American Osteopathic Association*, vol. 89, no. 3, pp. 349–352, 1989.
- [15] H. Fukuda and R. Saito, "A case of Sister Mary Joseph's nodule from prostatic cancer," *The Journal of Dermatology*, vol. 33, no. 1, pp. 46–51, 2006.
- [16] P. L. G. Martinez-Valls, A. R. Tardido, B. H. Vilchez et al., "Frontal mass simulating lipoma as a clinical presentation of prostatic adenocarcinoma," *Archivos Españoles de Urología*, vol. 62, no. 1, pp. 66–69, 2009.
- [17] D. He, J. Zeng, X. Li et al., "Priapism as the initial manifestation of a penile and lower limb cutaneous metastasis of prostate adenocarcinoma with low serum PSA level," *Journal of Andrology*, vol. 33, no. 6, pp. 1160–1164, 2012.
- [18] F. Herranz Amo, M. Lecona Echevarría, C. Hernández Fernández, F. Verdú Tartajo, J. M. Díez Cordero, and J. Díez Yanguas, "Cutaneous metastasis of a prostatic adenocarcinoma," *Archivos Españoles de Urología*, vol. 41, no. 5, pp. 393–395, 1988.
- [19] M. A. Keen and I. Hassan, "Cutaneous metastasis of an advanced prostate cancer," *Indian Journal of Dermatology, Venereology and Leprology*, vol. 79, no. 6, pp. 828–829, 2013.
- [20] G. Mak, M. Chin, N. Nahar, and P. De Souza, "Cutaneous metastasis of prostate carcinoma treated with radiotherapy: A case presentation," *BMC Research Notes*, vol. 7, no. 1, article no. 505, 2014.
- [21] J. D. D. S. de Menezes, P. F. M. Cappellari, M. M. Capelari et al., "Mandibular metastasis of adenocarcinoma from prostate cancer: Case report according to epidemiology and current therapeutical trends of the advanced prostate cancer," *Journal of Applied Oral Science*, vol. 21, no. 5, pp. 490–495, 2013.
- [22] A. O. Ogunmola, O. B. Shittu, and E. O. Olapade-Olaopa, "Cutaneous metastasis from prostate cancer in a nigerian: a case report and literature review. Afr J Med Med Sci," in *Olapade-Olaopa EO. Cutaneous metastasis from prostate cancer in a nigerian: a case report and literature review. Afr J Med Med Sci*, pp. 42–283, 42, 283–6, 2013.
- [23] D. Pal, V. Talwar, D. C. Doval, Y. P. Jalpota, and N. Kumar, "Cutaneous metastasis in prostatic carcinoma," *Indian Journal of Dermatology, Venereology and Leprology*, vol. 75, no. 3, pp. 311–312, 2009.
- [24] S. C. U. Patne, B. Naik, P. Patnaik, and S. Trivedi, "Cutaneous metastases of prostatic adenocarcinoma," *Journal of Cytology*, vol. 32, no. 2, pp. 121–123, 2015.
- [25] N. Pervaiz, M. J. Fellner, and J. E. Davis, "Cutaneous metastases from prostatic carcinoma," *Urology*, vol. 11, no. 4, pp. 403–405, 1978.
- [26] E. P. Duran, A. Paradela, M. C. Fariña et al., "Cutaneous metastases from prostatic carcinoma," *Journal of Surgical Oncology*, vol. 62, no. 2, pp. 144–147, 1996.
- [27] F. C. Powell, P. Y. Venencie, and R. K. Winkelmann, "Metastatic Prostate Carcinoma Manifesting as Penile Nodules," *JAMA Dermatology*, vol. 120, no. 12, pp. 1604–1606, 1984.
- [28] A. Rattanasirivilai, A. Kurban, Y. M. Lenzy, and R. Yaar, "Cutaneous metastasis of prostatic adenocarcinoma: a cautionary tale," *Journal of Cutaneous Pathology*, vol. 38, no. 6, pp. 521–524, 2011.
- [29] S. Reddy, R. H. Bang, and M. E. Contreras, "Telangiectatic cutaneous metastasis from carcinoma of the prostate [14]," *British Journal of Dermatology*, vol. 156, no. 3, pp. 598–600, 2007.
- [30] A. Roca Edreira, C. Aguilera Tubet, A. Villanueva Peña, R. Ballesterro Diego, and S. Zubillaga Guerrero, "Mediastinal lymph nodes during the course of a metastatic prostate cancer," *Actas Urológicas Españolas*, vol. 31, no. 6, pp. 693–695, 2007.
- [31] J. J. Rodríguez Martínez, M. E. Cerrato Rodríguez, F. J. García Pérez, F. J. Martínez Gómez, and A. E. Sánchez Trilla, "Skin metastases of primary transitional cell carcinoma of the prostate. Apropos of a case," in *Archivos Españoles de Urología*, vol. 52, pp. 52–885, 887, 885, 1999.
- [32] R. B. Rossetti, C. M. Villaca Neto, L. H. C. Paschoal, and M. Burnler, "Cutaneous Metastasis Originating from Prostate Adenocarcinoma," *International Journal of Dermatology*, vol. 30, no. 5, pp. 363–363, 1991.
- [33] HW. Seifert, R. Stiens, H. Wirtler, and N. Jaeger, "Unusual cutaneous metastasis of a prostatic cancer. MMW Munch Med

- Wochenschr,” in Jaeger N. *Unusual cutaneous metastasis of a prostatic cancer. MMW Munch Med Wochenschr*, pp. 123–1713, 123, 1713–4, 1981.
- [34] E. Tejada Báñez, C. Argüello Valentín, F. Romero Rodríguez, and T. Casanueva Luis, “Cutaneous metastasis of prostatic cancer,” *Archivos Españoles de Urología*, vol. 36, no. 3, pp. 217–220, 1983.
- [35] J. G. Valdivia Uría, J. A. López López, J. M. Aranda Lassa, and M. Moros García, “Cutaneous metastasis in prostatic carcinoma. Apropos of 2 cases,” *Arch españoles Urol*, vol. 39, pp. 669–672, Jan 1986.
- [36] S. Q. Wang, P. S. Mecca, P. L. Myskowski, and S. F. Slovin, “Scrotal and penile papules and plaques as the initial manifestation of a cutaneous metastasis of adenocarcinoma of the prostate: case report and review of the literature,” *Journal of Cutaneous Pathology*, vol. 35, no. 7, pp. 681–684, 2008.
- [37] J. J. Wu, D. B. Huang, K. R. Pang, and S. K. Tying, “Cutaneous metastasis to the chest wall from prostate cancer,” *International Journal of Dermatology*, vol. 45, no. 8, pp. 946–948, 2006.
- [38] R. K. Rovere, A. S. D. de Lima, and K. P. Casemiro, “A case of small-cell prostate cancer with a metastasis to the scalp,” *Japanese Journal of Clinical Oncology*, vol. 43, no. 11, Article ID ht165, p. 1156, 2013.
- [39] Y. Yildirim, Y. Akcay, O. Ozyilkan, and B. Celasun, “Prostate small cell carcinoma and skin metastases: a rare entity,” *Medical Principles and Practice*, vol. 17, no. 3, pp. 250–252, 2008.
- [40] N. Ali, S. Ur-Rehman, M. Ali, I. Sabir, R. Azhar, and S. Mansoor, “Skin metastasis from prostate adenocarcinoma,” *J Coll Physicians Surg Pak*, pp. 13–53, 2003.
- [41] C. S. Ng, “Carcinoma erysipeloides from prostate cancer presenting as cellulitis,” *Cutis; Cutaneous Medicine for the Practitioner*, vol. 65, no. 4, pp. 215–216, 2000.
- [42] D. Pascual Regueiro, V. Andrés Lázaro, A. Borque Fernando, C. Allepuz Losa, J. Azua, and L. A. Rioja Sanz, “Skin metastasis of long-course prostatic cancer,” *Actas Urológicas Españolas*, vol. 25, no. 3, pp. 218–221, 2001.
- [43] J. Herrera Puerto, J. Pierna Manzano, L. M. Gómez Tejada, and I. Isusquiza Garro, “Subcutaneous supramammary metastasis of prostatic carcinoma,” *Actas Urológicas Españolas*, vol. 23, no. 4, pp. 367–369, 1999.
- [44] T. Soda, H. Onishi, T. Terachi, K. Oishi, H. Takeuchi, and O. Yoshida, “Bilateral breast metastases from prostatic carcinoma: a case report,” *Hinyokika Kyo: Acta Urologica Japonica*, vol. 45, no. 4, pp. 269–271, 1999.
- [45] J. A. Gallego Sánchez, A. Astobieta Odriozola, J. Alvarez Martínez, J. G. Ibarlucea González, J. Larrinaga Simón, and C. Bernuy Malfaz, “Skin metastasis as first manifestation of prostatic adenocarcinoma,” *Actas Urológicas Españolas*, vol. 22, no. 9, pp. 770–772, 1998.
- [46] K. Krishna and M. B. Gharpuray, “Skin metastasis from prostatic carcinoma,” *Journal of the Indian Medical Association*, vol. 95, no. 7, p. 435, 1997.
- [47] R. Ortiz Cabria, M. Adriazola Semino, M. A. Blanco Parra, E. Garcá Cobo, E. Tejada Báñez, and F. Romero Rodríguez, “Skin lesions of the penis. Prostatic adenocarcinoma metastasis. Report of a case,” *Actas Urológicas Españolas*, vol. 23, no. 2, pp. 153–155, 1999.
- [48] S. E. Cox and P. D. Cruz Jr., “A spectrum of inflammatory metastasis to skin via lymphatics: Three cases of carcinoma erysipeloides,” *Journal of the American Academy of Dermatology*, vol. 30, no. 2, pp. 304–307, 1994.
- [49] A. Delima, A. Mohamed, S. V. Yalla, and H. M. Burros, “Prostatic carcinoma metastasizing to skin and subcutaneous tissues,” *Urology*, vol. 2, no. 6, pp. 663–665, 1973.
- [50] F. Gallizia and G. Gallizia, “Solitary dermal metastasis of a prostatic carcinoma,” *J Urol Nephrol*, vol. 74, pp. 487–490, 1968.
- [51] J. Gary-Bobo, A. Pages, and M. Bousquet, “Cutaneous metastasis of prostatic epitheliomas. Bull Assoc Fr Etud Cancer,” in *Bousquet M. Cutaneous metastasis of prostatic epitheliomas. Bull Assoc Fr Etud Cancer*, pp. 49–74, 49, 74–83, 1962.
- [52] B. Peison, “Metastasis of Carcinoma of the Prostate to the Scalp: Simulation of a Large Sebaceous Cyst,” *JAMA Dermatology*, vol. 104, no. 3, pp. 301–303, 1971.
- [53] P. C. Pieslor and L. G. Hefter, “Umbilical metastasis from prostatic carcinoma-Sister Joseph nodule,” *Urology*, vol. 27, no. 6, pp. 558–559, 1986.
- [54] M. Razvi, R. Firfer, and B. Berkson, “Occult transitional cell carcinoma of the prostate presenting as skin metastasis,” *The Journal of Urology*, vol. 113, no. 5, pp. 734–735, 1975.
- [55] G. Rius Espina and C. Vargas Blasco, “Skin metastasis in prostatic adenocarcinoma,” *Actas Urológicas Españolas*, vol. 16, no. 8, pp. 648–649, 1992.
- [56] P. F. Schellhammer, “Prostatic carcinoma with diffuse cutaneous metastases,” *Urology*, vol. 12, no. 3, p. 377, 1978.
- [57] P. F. Schellhammer, R. Milsten, and R. C. Bunts, “Prostatic Carcinoma with Cutaneous Metastases,” *British Journal of Urology*, vol. 45, no. 2, pp. 169–172, 1973.
- [58] R. Segal, N. S. Penneys, and G. Nahass, “Metastatic prostatic carcinoma histologically mimicking malignant melanoma,” *Journal of Cutaneous Pathology*, vol. 21, no. 3, pp. 280–282, 1994.
- [59] A. Steg and L. Boccon-Gibod, “Cutaneous metastasis of prostatic cancer. 2 cases,” *Annales d’Urologie*, vol. 4, pp. 57–59, 1970.
- [60] J. Thivolet, C. Molinie, G. Moulin, and J. Proust, “Metastases of the penis during prostatic cancer. (apropos of a case of isolated cutaneous metastasis of the gland),” *Dermatologica Sinica*, vol. 130, pp. 221–230, 1965.
- [61] L. Telis, V. Wolf, O. Yaskiv et al., “Skin metastasis, an uncommon course of prostate carcinoma: A report of two cases,” *Malaysian Journal of Pathology*, vol. 38, no. 2, pp. 165–168, 2016.
- [62] T. Sheridan, M. Herawi, J. I. Epstein, and P. B. Illei, “The role of P501S and PSA in the diagnosis of metastatic adenocarcinoma of the prostate,” *The American Journal of Surgical Pathology*, vol. 31, no. 9, pp. 1351–1355, 2007.
- [63] M. A. Dall’Era, L. D. True, A. F. Siegel, M. P. Porter, T. M. Sherertz, and A. Y. Liu, “Differential expression of CD10 in prostate cancer and its clinical implication,” *BMC Urology*, vol. 7, article 3, 2007.
- [64] R. Li, K. Heydon, M. E. Hammond et al., “Ki-67 staining index predicts distant metastasis and survival in locally advanced prostate cancer treated with radiotherapy: an analysis of patients in Radiation Therapy Oncology Group Protocol 86-10,” *Clinical Cancer Research*, vol. 10, no. 12, part 1, pp. 4118–4124, 2004.
- [65] O. H. Yuksel, A. Urkmez, S. Akan, C. Yildirim, and A. Verit, “Predictive value of the platelet-to-lymphocyte ratio in diagnosis of prostate cancer,” *Asian Pacific Journal of Cancer Prevention*, vol. 16, no. 15, pp. 6407–6412, 2015.
- [66] O. V. Batson, “The function of the vertebral veins and their role in the spread of metastases,” *Annals of Surgery*, vol. 112, no. 1, pp. 138–149, 1940.
- [67] L. Mo, J. Zhang, J. Shi, Q. Xuan, X. Yang, M. Qin et al., “Human kallikrein 7 induces epithelial-mesenchymal transition-like

changes in prostate carcinoma cells: a role in prostate cancer invasion and progression," *Anticancer Research*, vol. 30, pp. 3413–3420, 2010.

- [68] E. Kawashita, Y. Osumi, K. Nakamura et al., "A case of prostatic carcinoma with skin metastases," *Urologia Internationalis*, vol. 40, no. 5, pp. 298–300, 1985.
- [69] M. Marcelli, M. Ittmann, S. Mariani, R. Sutherland, R. Nigam, L. Murthy et al., "Androgen receptor mutations in prostate cancer," *Cancer Research*, vol. 60, pp. 944–949, 2000.