

Prenatal Ultrasound Markers of Isolated Total Anomalous Pulmonary Venous Return and a Sequential Approach to Reach Diagnosis

Wan-Ling Chih^{1,2}, Hsuan Ko¹, Tung-Yao Chang^{1*}

¹Department of Fetal Medicine, Taiji Clinic, New Taipei, Taiwan, ²Department of Pediatrics, Mackay Memorial Hospital, Taipei, Taiwan

Abstract

This article comprehensively reviews the literature concerning prenatal ultrasound findings of isolated total anomalous pulmonary venous return (TAPVR) and the application of specific sonographic markers to differentiate among the TAPVR types. These markers can be categorized as direct and indirect, based on either morphological features or hemodynamic changes in TAPVR. Indirect markers include the ventricular disproportion, an increased distance between the left atrium (LA) and the descending aorta, as well as the dilatation of superior vena cava or coronary sinus for supracardiac or cardiac TAPVR, along with abnormal pulmonary venous spectral Doppler patterns. Direct markers predominantly focus on the absence of a connection between the pulmonary veins and the LA. Some direct markers are specific to certain TAPVR types, such as the vertical vein. Diagnosing isolated TAPVR can pose challenges, but following a sequential approach can improve detection rates and outcomes. In cases with equivocal findings, additional follow-ups are recommended. The sequential approach described in the current article provides a step-wise methodology and sonographic markers for prenatal diagnosis of TAPVR, which can be utilized by fetal-maternal medicine specialists, obstetricians, and radiological technicians to ensure timely interventions.

Keywords: Fetal heart, prenatal ultrasound, pulmonary veins, screening, total anomalous pulmonary venous return

INTRODUCTION

Total anomalous pulmonary venous return (TAPVR) is a critical congenital heart disease (CHD) requiring surgical repair soon after birth. In Taiwan, the prevalence rate is 1.1/10,000 at live births, accounting for 0.8% of all CHD cases.^[1,2] Clinical presentations of TAPVR in neonates and infants range from tachypnea and cyanosis to cardiorespiratory failure. Early neonatal or prenatal diagnosis, followed by timely postnatal intervention, is crucial for improving outcomes.^[3,4] However, despite recent advances in ultrasound evaluation of the fetal venous system, the prenatal diagnosis of isolated TAPVR remains challenging. An international retrospective cohort study reported that prenatal detection rates ranged between 0% and 50%.^[5] Even though various sonographic markers have been proposed, isolated TAPVR continues to evade prenatal diagnosis during routine screening.^[6,7] This article aims to review the current understanding of sonographic features

of fetal TAPVR and provides a sequential approach starting from obstetric screening views to identify possible cases and categorize the TAPVR types step by step.

SONOGRAPHIC MARKERS FOR SCREENING AND DIAGNOSIS OF FETAL TOTAL ANOMALOUS PULMONARY VENOUS RETURN

TAPVR defines the heart anomaly in which the pulmonary veins have no connection with the left atrium (LA). Instead, they connect directly to one or more systemic veins or drain directly into the right atrium (RA) [Figure 1]. Previous studies have identified several sonographic markers for screening and diagnosing fetal TAPVR cases.^[3,4,8,9] These sonographic

Address for correspondence: Dr. Tung-Yao Chang,
Department of Fetal Medicine, Taiji Clinic, 2F, No. 210, Section 3,
New Taipei Boulevard, Xinzhuang District, New Taipei 242, Taiwan.
E-mail: tychang@fetalmedicine.tw

Received: 11-01-2024 Accepted: 22-01-2024 Available Online: 26-04-2024

Access this article online

Quick Response Code:



Website:
<https://journals.lww.com/jmut>

DOI:
10.4103/jmu.jmu_4_24

This is an open access journal, and articles are distributed under the terms of the Creative Commons Attribution-NonCommercial-ShareAlike 4.0 License, which allows others to remix, tweak, and build upon the work non-commercially, as long as appropriate credit is given and the new creations are licensed under the identical terms.

For reprints contact: WKHLRPMedknow_reprints@wolterskluwer.com

How to cite this article: Chih WL, Ko H, Chang TY. Prenatal ultrasound markers of isolated total anomalous pulmonary venous return and a sequential approach to reach diagnosis. *J Med Ultrasound* 2024;32:104-9.

markers are categorized as either morphological features or hemodynamic changes in TAPVR and are commonly classified as direct or indirect markers.

INDIRECT SONOGRAPHIC MARKERS FOR FETAL TOTAL ANOMALOUS PULMONARY VENOUS RETURN

Directly visualizing the connection between the pulmonary veins and the LA could be technically difficult. Indirect markers can serve as the initial clue for detecting fetal TAPVR. These markers are primarily based on morphological features (e.g., increased post-LA space) or on hemodynamic changes (ventricular disproportion in later gestational age, dilated superior vena cava [SVC] or coronary sinus, and abnormal Doppler waveforms) in such cases.^[8,9] It is important to note that indirect markers may not lead to a straightforward TAPVR diagnosis but rather raise suspicion.

Ventricular disproportion

Asymmetric ventricular chamber dimensions result from extra-abnormal flow from the pulmonary veins to the right heart, providing a diagnostic clue for TAPVR.^[9] Right heart dominance is often observed in infants with TAPVR and can also be seen in fetal cases after the late second trimester [Figure 2a]. However, routine second-trimester fetal anatomical scans are typically conducted at the gestational age of 18–22 weeks, rendering this sonographic marker less useful for screening purposes.

A study found no significant differences in right/left ventricular dimension ratios between normal and TAPVR fetuses in the mid-trimester.^[10] Another study recommended not including this in routine screening criteria.^[3] A systematic review and meta-analysis reported that the gestational age at diagnosis of fetal TAPVR ranged from 16 to 30 weeks, while ventricular disproportion appeared mainly in the late second trimester or third trimester (range: 18–37 weeks).^[11] Nonetheless, ventricular disproportion was one of the most common findings in fetal TAPVR, with approximately 60% of isolated TAPVR

cases exhibiting this sonographic feature.^[11] In brief, the ventricular disproportion is a finding that warrants a detailed fetal cardiac evaluation at later gestation.

Increased distance between the left atrium and the descending aorta

The presence of a pulmonary venous confluence is a distinctive feature of TAPVR and leads to an increased distance between LA and the descending aorta (DAo) [Figure 2b]. Detecting this confluent chamber can be technically challenging, but a straightforward measurement with high sensitivity and specificity is more practical for screening purposes. Kawazu *et al.* proposed the “post-LA space index” as a potential marker, calculated as the ratio of the LA-DAo distance to the diameter of the DAo [Figure 2b].^[13] Other studies have confirmed its reliability in differentiating TAPVR from normal cases, showing low inter- and intraobserver variabilities.^[10,12] Notably, the post-LA space index was independent of the gestational age,^[13] the four-chamber view orientation (apical, basal, or lateral), and the TAPVR type.^[12] Studies have demonstrated that post-LA space index cutoff value of ≥ 1.27 or 1 exhibited

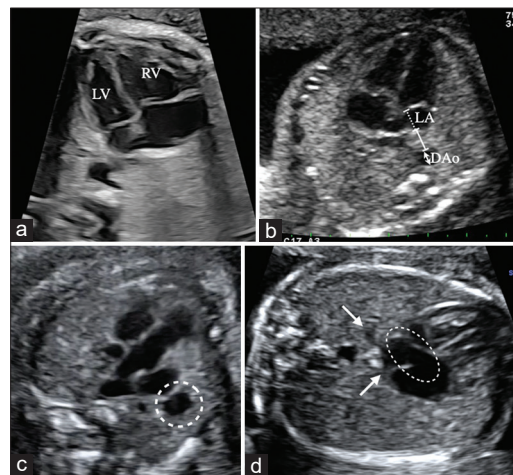


Figure 2: Two-dimensional ultrasonic images of indirect sonographic markers for fetal total anomalous pulmonary venous return (TAPVR) on B-mode. (a) Ventricular disproportion at 35 weeks of gestation: In this case, supracardiac TAPVR was diagnosed through the second-trimester screening; however, ventricular disproportion (right ventricle > left ventricle) was not apparent until 35 weeks of gestation, (b) Increased distance between the left atrium (LA) and the descending aorta (DAo) at 23 weeks of gestation: In the apical four-chamber view, the post-LA space index was calculated as the ratio of the distance from LA to DAo (solid line calipers) to the diameter of the DAo (arrow calipers). The left-atrial posterior-space-to-diagonal ratio was calculated by dividing the distance from LA to DAo (solid line calipers) by the diameter of the LA (dotted line calipers), (c) Dilated superior vena cava (SVC) (supracardiac type) at 26 weeks of gestation: Because of the excess blood flow from the vertical vein draining into the SVC, the SVC becomes as large as the aorta (dashed line circle), (d) dilated coronary sinus (coronary sinus type) at 23 weeks of gestation: The pulmonary veins (arrows) connect to the dilated coronary sinus (dashed line circle) instead of the LA. This plane is caudal to the true four-chamber view plane because the atrioventricular valves are not seen clearly. RV: Right ventricle, LV: Left ventricle, LA: Left atrium, DAo: Descending aorta

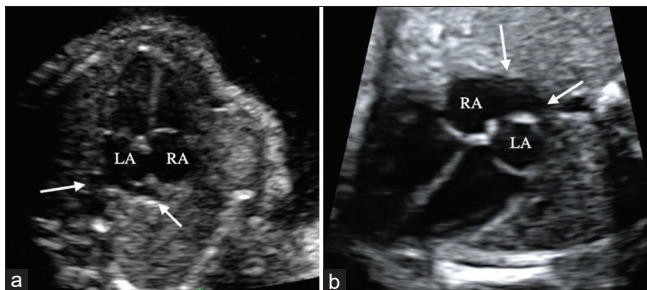


Figure 1: Two-dimensional gray-scale ultrasound of four-chamber view in a typical fetal heart versus right atrial-type total anomalous pulmonary venous return (right atrium [RA]-type total anomalous pulmonary venous return [TAPVR]). (a) Normal four-chamber view in a fetus at 23 weeks of gestation: Normal entry of the pulmonary veins to the left atrium (arrows), (b) In right atrial-type TAPVR at 24 weeks of gestation, the pulmonary veins connect to the RA (arrows). LA: Left atrium, RA: Right atrium

excellent diagnostic performance with a sensitivity of 100% and specificity of 99% and 95.1%, respectively.^[10,12]

An alternative marker with a similar diagnostic performance and independence of the gestational age was recently proposed by Anuwutnavin *et al.*^[12] The new method also focuses on the enlarged area behind the LA: the “left-atrial posterior-space-to-diagonal (LAPSD) ratio,” which is calculated by dividing the LA-DAo distance by the left atrial diameter [Figure 2b]. The authors hypothesized that a higher LAPSD ratio reflects the enlargement of the retroatrial space and smaller LA, which are considered typical changes for TAPVR. LAPSD ratio ≥ 0.35 was proposed as an optimal cutoff for detecting TAPVR.^[12] The authors underlined that in certain cases, it might be crucial to employ multiple indirect signs to ensure the correct diagnosis, for example, in patients with a small LA such as hypoplastic left heart syndrome.

Dilated superior vena cava (supracardiac type)

In a typical three-vessel-trachea (3VT) view, the SVC usually appears smaller than the aorta. However, in cases of supracardiac TAPVR, anomalous pulmonary venous drainage increases blood flow to the drainage site, which then returns to the RA through the SVC. Thus, the diameter of SVC can become enlarged due to excess blood flow. This enlargement can make the SVC appear as large as or even larger than the aorta in the 3VT view [Figure 2c].^[3,9] A prominent SVC has been reported in 67%–100% of supracardiac TAPVR cases.^[4,9] It is especially important to utilize supplementary views (e.g., 3VT view) in cases when the presence of connections to the LA is inconclusive.^[3]

Dilated coronary sinus (cardiac type)

When the pulmonary veins anomalously drain into the coronary sinus, its dilatation is expected due to excess blood flow. In the subcostal view of pediatric echocardiography, this subtype is characterized by the “whale’s tail sign,” where left and right pulmonary veins drain into the dilated coronary sinus. Unfortunately, the subcostal view is technically difficult in fetal echocardiography. The coronary sinus is located in the left atrioventricular groove and is not usually seen in the four-chamber view plane, making the detection of this subtype more challenging than the others. Moreover, the anomalous drainage route is quite short, and pulmonary venous obstruction is uncommon in this subtype. Consequently, the spectral Doppler waveforms of the individual pulmonary veins appear entirely normal. This explains why cardiac type accounts for around 38% of all TAPVR cases in postnatal cohorts^[14,15] but is seldom mentioned in prenatal series.^[16]

In clinical practice, visualizing the coronary sinus may be achieved by sweeping from the four-chamber view plane to the abdominal view plane instead of relying solely on static images. A normal coronary sinus looks slim and usually measures <3 mm in diameter during the second trimester.^[17] Nonetheless, a dilated coronary sinus signals the need for further evaluation [Figure 2d]. Differential diagnosis may

include cardiac TAPVR or, more commonly, a persistent left SVC (PLSVC).

Abnormal pulmonary venous spectral Doppler

The typical pulmonary venous waveform is characterized by a pulsatile flow, which is influenced by left atrial hemodynamics. In fetal TAPVR, the pulmonary venous waveform is a reflection of the length of the anomalous pulmonary venous drainage and the presence of pulmonary venous obstruction.^[18] Literature has reported that changes in pulmonary venous spectral waveforms were observed in 86%–96% of fetal TAPVR cases, with exceptions in cardiac type.^[3,4] Tongsong *et al.* reported that spectral Doppler waveforms were typically normal or biphasic in cardiac type, whereas in supracardiac and infracardiac types, the waveforms can be biphasic, monophasic, or continuous [Figure 3].^[3] Despite its high specificity, this marker is not commonly a primary reason for referral in clinical practice, likely because spectral Doppler is not yet routinely employed in fetal cardiac screening. According to a meta-analysis, the method that raised primary suspicion for fetal TAPVR was color/power Doppler (84.9% with 95% confidence interval = 67.3%–93.9%).^[11] On the other hand, pulsed-wave Doppler of the pulmonary veins has proven informative in cases with equivocal anatomy^[4] or for evaluating obstruction and drainage site.^[7]

In brief, an abnormal pulmonary venous waveform is currently seen as a confirmation marker of the morphological diagnosis of fetal TAPVR, as spectral Doppler is rarely used as a tool in first-line screening.

DIRECT SONOGRAPHIC MARKERS FOR FETAL TOTAL ANOMALOUS PULMONARY VENOUS RETURN

Direct markers are based on anatomical features in TAPVR, such as a lack of connection between the pulmonary veins and the LA or the presence of a confluent chamber. Their presence usually confirms the diagnosis. Certain direct markers are specific to particular types of TAPVR, for example, the ascending or descending vertical vein in the supracardiac or infracardiac type.

Lack of connection between the pulmonary veins and the left atrium

This marker is the most common in the cases of TAPVR and is considered a major diagnostic criterion for fetal cases.^[3,8] Guidelines for fetal cardiac screening recommended attempting to visualize at least one pulmonary vein entering LA in the four-chamber view on B-mode imaging.^[19] In the four-chamber view, a characteristic feature is the presence of a left and a right pulmonary vein entry at the posterior wall of the LA, forming a horn-like insertion [Figure 1a].^[9] In TAPVR, this horn-like insertion is absent, and the posterior wall of LA may look “smooth” [Figure 4a].

Color flow Doppler images can complement B-mode images for observing pulmonary venous entry.^[9] However, it is important not to rely solely on color Doppler images for this




Figure 3: Pulmonary venous spectral Doppler waveforms in different types of total anomalous pulmonary venous return (TAPVR). (a) Cardiac TAPVR at 34 weeks of gestation: Normal S, D, and A waves. (b) Infracardiac TAPVR at 23 weeks of gestation: Abnormal monophasic pulsatile pattern, (c) supracardiac TAPVR at 26 weeks of gestation: Abnormal continuous pattern. S: Systolic phase, D: Diastolic phase, A: Atrial contraction phase

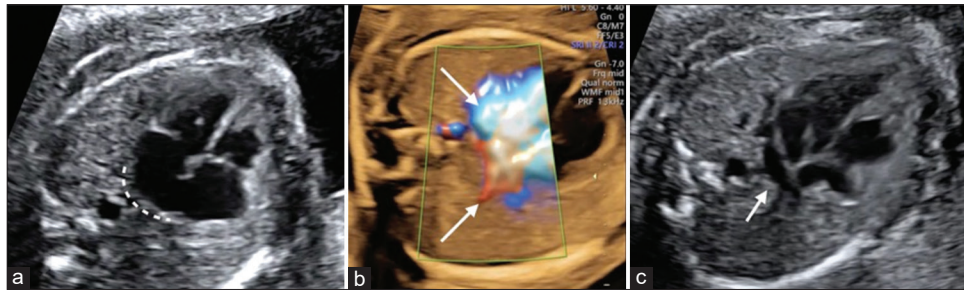


Figure 4: Direct sonographic markers for fetal total anomalous pulmonary venous return. (a) The smooth posterior wall of the left atrium at 24 weeks of gestation in the absence of pulmonary venous entry into the left atrium, (b) color Doppler imaging cannot be used in isolation to confirm pulmonary venous entry into the left atrium. For example, in the presented case at 26 weeks of gestation, when applying the color Doppler, the pulmonary veins seemed to enter the left atrium, but B-mode image, (c) a pulmonary venous confluent chamber (twig sign) (arrow) behind the left atrium

purpose. In the context of a low-velocity scale, distinguishing whether the pulmonary veins are entering LA itself or entering a confluence behind LA can be challenging [Figure 4b].

Pulmonary venous confluent chamber behind the left atrium (twig sign)

A previous study suggested that the visualization of a confluent chamber behind the LA and a vertical vein provided the most consistent echocardiographic clues.^[20] In TAPVR, it is common for the anomalous pulmonary veins to enter a confluent chamber behind the LA, with the exception in the cardiac type. The confluence appears like a twig extending behind the heart in the four-chamber view [Figure 4c]. It is easier to detect in the apical or basal four-chamber view than in the lateral four-chamber view, as it would provide a clearer visualization if the membrane dividing LA is perpendicular to the ultrasound beam. The presence of a confluent chamber increases the distance between the left atrial wall and the DAo, which aligns with one of the indirect markers for TAPVR mentioned above.

In the case of coronary sinus-type TAPVR, the pulmonary venous confluent chamber is located below the four-chamber view plane and does not form a twig sign, making it more difficult to detect.

Vertical vein

A vertical vein serves as a connection between the pulmonary venous confluence and the systemic vein. According to a systematic review and meta-analysis, approximately 60% of prenatally diagnosed TAPVR cases had a vertical vein.^[11]

Published case series had suggested that a vertical vein could be present in supracardiac, infracardiac, and mixed-type TAPVR cases, but not in the cardiac type.^[4,16,21]

By utilizing color Doppler mapping to trace the direction of vertical vein drainage, it becomes possible to diagnose supracardiac or infracardiac TAPVR.

Ascending vertical vein: An additional vessel in the three-vessel-trachea view (supracardiac type)

In supracardiac TAPVR [Figure 5], an ascending vertical vein drains upward to the innominate vein or SVC, or less commonly, into the azygos vein. This marker can be observed in the 3VT view as an additional vessel, usually located at the left of the main pulmonary artery. As the 3VT view is a part of the screening plane, this marker can be the first clue for prenatal detection during screening. The key to differentiation lies in observing the flow direction of the additional vessel, which helps distinguish between an ascending vertical vein and a PLSVC.

Descending vertical vein as an additional vessel in the abdominal plane (infracardiac type)

In the case of infracardiac TAPVR, a descending vertical vein drains downward through the diaphragm, connecting the pulmonary venous confluence to the inferior vena cava (IVC), hepatic veins, or the portal system. This descending vertical vein can be seen as an additional vein in the axial abdominal plane [Figure 6a]. In the sagittal view, an additional vein located between DAo and IVC can be identified, providing a clear depiction of the flow direction [Figure 6b].

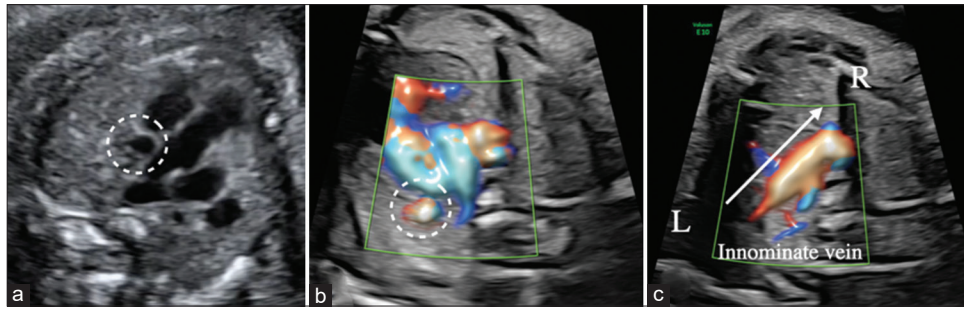


Figure 5: Prenatal ultrasound findings in a fetal heart at 26 weeks of gestation in a case of supracardiac total anomalous pulmonary venous return. (a) An additional vertical vein can be seen in the left side of the pulmonary artery (dashed line circle), (b) color Doppler mapping of a corresponding location (a) (dashed line circle), (c) prominent innominate vein due to excess flow (following the arrow direction) from the ascending vertical vein

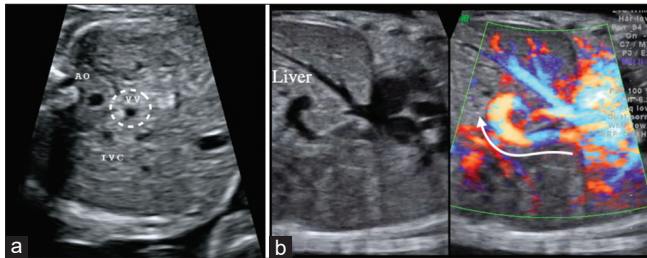


Figure 6: Prenatal ultrasound findings at 28 weeks of gestation in a case of infracardiac total anomalous pulmonary venous return. (a) Besides the left posterior descending aorta and right anterior inferior vena cava, an additional vertical vein (dashed line circle) can be found in the abdominal plane, (b) sagittal view of the vertical vein: The vessel goes downward through the diaphragm and drains into the liver (arrow). Ao: Aorta, IVC: Inferior vena cava, VV: Vertical vein

SEQUENTIAL APPROACH FOR DIAGNOSIS OF FETAL TOTAL ANOMALOUS PULMONARY VENOUS RETURN

Despite the many sonographic markers proposed for fetal TAPVR, prenatal diagnosis of isolated TAPVR remains a challenge. Most of these markers can be subtle during the second trimester. As a result, confirming the entry of the pulmonary veins into the LA is crucial to enhance prenatal diagnosis at the screening level. Therefore, we suggest a sequential approach, starting from obstetric screening views, to detect cases with suspected isolated TAPVR and differentiate among TAPVR types by identifying sonographic markers presented in Figure 7.

In fetal cardiac screening, the left and right pulmonary veins entering the LA are commonly observed in the four-chamber view. Their presence effectively rules out the possibility of TAPVR. However, when the connection between the pulmonary veins and the LA is not clear, the sonographer should raise suspicions of TAPVR and conduct a systematic search for other possible pulmonary venous drainage routes.

Staying at the level of a four-chamber view, one can focus on the area behind the LA to search for the presence of a pulmonary venous confluent chamber (or twig sign). If the pulmonary veins connect to the RA directly, the diagnosis of RA-type TAPVR can be made. However, if the connection of

the pulmonary veins to the fetal heart can only be observed at a level lower than the four-chamber view plane, they are likely draining into the dilated coronary sinus, which is inferior to the LA. In addition, a flow from the coronary sinus to the RA can be observed in the color Doppler image, aiding in the differentiation between cardiac TAPVR and primum atrial septal defect, as the latter shows a flow from RA to LA.

When a pulmonary venous confluent chamber is identified, the next step is to trace its drainage. Using color Doppler alongside the B-mode image, one can first move the probe cranially to the 3VT view to search for an ascending vertical vein and finally confirm its drainage. Common drainage sites of supracardiac-type TAPVR include the innominate vein and SVC. Increased blood flow and dilatation of the drainage vessel, recognized as indirect markers, can be expected. If the cephalic veins appear normal, one can move the probe caudally to the fetal abdomen at the level of the liver to search for a descending vertical vein. Possible drainage sites for a descending vertical vein in infracardiac-type TAPVR include IVC, hepatic veins, or the portal system. Pulsed Doppler waveforms of the individual pulmonary veins are usually abnormal, serving as indirect markers.

CONCLUSION

In the absence of a single sonographic sign for the diagnosis of fetal TAPVR, a systematic and sequential approach is crucial to improve the prenatal detection and diagnosis of TAPVR. The key to enhancing prenatal diagnosis is adherence to the fetal cardiac screening guidelines and evaluation of pulmonary venous entry into the LA in the four-chamber view. Other sonographic signs including direct and indirect markers, when used in conjunction with color and spectral Doppler, serve as adjuncts to precise prenatal diagnosis. Further follow-up at later gestation can be suggested in cases with equivocal findings.

Declaration of patient consent

The authors certify that they have obtained all appropriate patient consent forms. In the form, the patients have given their consent for their images and other clinical information

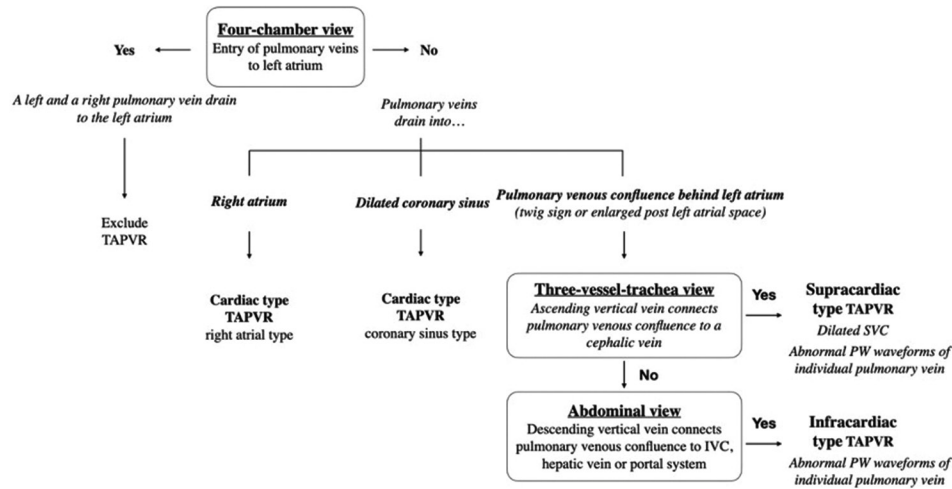


Figure 7: Flowchart for assessment of total anomalous pulmonary venous return by sequential approach. TAPVR: Total anomalous pulmonary venous return, SVC: Superior vena cava, IVC: Inferior vena cava

to be reported in the journal. The patients understand that their names and initials will not be published and due efforts will be made to conceal identity, but anonymity cannot be guaranteed.

Financial support and sponsorship

The study was funded by the Taiwan Institute of Fetal Medicine (Taiwan Registered Non-profit Organization 1080280906).

Conflicts of interest

Dr. Tung-Yao Chang, an editor at *Journal of Medical Ultrasound*, had no role in the peer review process or decision to publish this article. The other authors declared no conflicts of interest in writing this paper.

REFERENCES

1. Wu MH, Chen HC, Lu CW, Wang JK, Huang SC, Huang SK. Prevalence of congenital heart disease at live birth in Taiwan. *J Pediatr* 2010;156:782-5.
2. Yeh SJ, Chen HC, Lu CW, Wang JK, Huang LM, Huang SC, et al. Prevalence, mortality, and the disease burden of pediatric congenital heart disease in Taiwan. *Pediatr Neonatol* 2013;54:113-8.
3. Tongsong T, Luewan S, Jatavan P, Tongprasert F, Sukpan K. A simple rule for prenatal diagnosis of total anomalous pulmonary venous return. *J Ultrasound Med* 2016;35:1601-7.
4. Ganesan S, Brook MM, Silverman NH, Moon-Grady AJ. Prenatal findings in total anomalous pulmonary venous return: A diagnostic road map starts with obstetric screening views. *J Ultrasound Med* 2014;33:1193-207.
5. Bakker MK, Bergman JE, Krikov S, Amar E, Cocchi G, Cragan J, et al. Prenatal diagnosis and prevalence of critical congenital heart defects: An international retrospective cohort study. *BMJ Open* 2019;9:e028139.
6. Olsen R, Doyle Z, Levy D, Anton T, Molkara D, Tarsa M, et al. Anomalous pulmonary venous return: Insights into prenatal detection. *J Ultrasound Med* 2016;35:1193-206.
7. Bravo-Valenzuela NJ, Peixoto AB, Araujo Júnior E. Prenatal diagnosis of total anomalous pulmonary venous connection: 2D and 3D echocardiographic findings. *J Clin Ultrasound* 2021;49:240-7.
8. Heard J, Soni R, Nikel K, Day C, Pylypjuk C. Can prenatal diagnosis of total anomalous pulmonary venous return (TAPVR) using routine fetal ultrasound be improved? A case-control study. *Radiol Res Pract* 2022;2022:7141866.
9. Kao CC, Hsieh CC, Cheng PJ, Chiang CH, Huang SY. Total anomalous pulmonary venous connection: From embryology to a prenatal ultrasound diagnostic update. *J Med Ultrasound* 2017;25:130-7.
10. Akkurt MO, Yavuz A, Akkurt I, Karakoc G, Sezik M. Reliability of posterior-left atrium space index measurements during 20-24 weeks of gestation in structurally normal fetuses. *J Perinat Med* 2016;44:613-7.
11. Paladini D, Pistorio A, Wu LH, Meccariello G, Lei T, Tuo G, et al. Prenatal diagnosis of total and partial anomalous pulmonary venous connection: Multicenter cohort study and meta-analysis. *Ultrasound Obstet Gynecol* 2018;52:24-34.
12. Anuwutnavin S, Unalome V, Rekhawasin T, Tongprasert F, Thongkloung P. Fetal left-atrial posterior-space-to-diagonal ratio at 17-37 weeks' gestation for prediction of total anomalous pulmonary venous connection. *Ultrasound Obstet Gynecol* 2023;61:488-96.
13. Kawazu Y, Inamura N, Kayatani F, Taniguchi T. Evaluation of the post-LA space index in the normal fetus. *Prenat Diagn* 2019;39:195-9.
14. Hu SY, Chou HW, Chen YS, Huang SC. Total anomalous pulmonary venous connection: Surgical outcomes and risk factors for postoperative pulmonary vein obstruction. *Acta Cardiol Sin* 2023;39:254-65.
15. Fu CM, Wang JK, Lu CW, Chiu SN, Lin MT, Chen CA, et al. Total anomalous pulmonary venous connection: 15 years' experience of a tertiary care center in Taiwan. *Pediatr Neonatol* 2012;53:164-70.
16. Laux D, Fermont L, Bajolle F, Boudjemline Y, Stirnemann J, Bonnet D. Prenatal diagnosis of isolated total anomalous pulmonary venous connection: A series of 10 cases. *Ultrasound Obstet Gynecol* 2013;41:291-7.
17. Abello KC, Stewart PA, Baschat AA. Two-dimensional and M-mode echocardiography of the fetal coronary sinus. *Ultrasound Obstet Gynecol* 2002;20:137-41.
18. Valsangiaco ER, Hornberger LK, Barrea C, Smallhorn JF, Yoo SJ. Partial and total anomalous pulmonary venous connection in the fetus: Two-dimensional and Doppler echocardiographic findings. *Ultrasound Obstet Gynecol* 2003;22:257-63.
19. Carvalho JS, Axt-Flidner R, Chaoui R, Copel JA, Cuneo BF, Goff D, et al. ISUOG practice guidelines (updated): Fetal cardiac screening. *Ultrasound Obstet Gynecol Off J Int Soc Ultrasound Obstet Gynecol* 2023;61:788-803.
20. Konduri A, Aggarwal S. Partial and total anomalous pulmonary venous connection. In: *Statpearls*. Treasure Island (FL): StatPearls Publishing; 2023.
21. Seale AN, Carvalho JS, Gardiner HM, Mellander M, Roughton M, Simpson J, et al. Total anomalous pulmonary venous connection: Impact of prenatal diagnosis. *Ultrasound Obstet Gynecol* 2012;40:310-8.