




Contents lists available at ScienceDirect

## Epilepsy &amp; Behavior Reports

journal homepage: [www.elsevier.com/locate/ebcr](http://www.elsevier.com/locate/ebcr)

## Case Report

## Cognitive and behavioral outcome of stereotactic laser amygdalohippocampotomy in a pediatric setting



Kim E. Ono<sup>a,b</sup>, Donald J. Bearden<sup>a,b</sup>, Elizabeth Adams<sup>c</sup>, Jason Doescher<sup>c</sup>, Sookyong Koh<sup>a,b</sup>, Yaman Eksioglu<sup>a,b</sup>, Robert E. Gross<sup>d,e,f</sup>, Daniel L. Drane<sup>a,e,g,\*</sup>

<sup>a</sup> Department of Pediatrics, Emory University School of Medicine, Atlanta, GA, USA

<sup>b</sup> Children's Hospital of Atlanta, Atlanta, GA, USA

<sup>c</sup> Department of Neurology, Minnesota Epilepsy Group, Minneapolis, MN, USA

<sup>d</sup> Department of Neurosurgery, Emory University School of Medicine, Atlanta, GA, USA

<sup>e</sup> Department of Neurology, Emory University School of Medicine, Atlanta, GA, USA

<sup>f</sup> Coulter Department of Biomedical Engineering, Emory University, GA, USA

<sup>g</sup> Department of Neurology, University of Washington School of Medicine, Seattle, WA, USA

## ARTICLE INFO

## Article history:

Received 7 April 2020

Received in revised form 16 May 2020

Accepted 18 May 2020

Available online 02 June 2020

## Keywords:

Laser interstitial thermal therapy

Stereotactic laser ablation

Cognitive outcome

Socio-emotional deficits

Medial temporal lobe epilepsy

Pediatric

## ABSTRACT

We present neuropsychological and functional outcome data in a teenager undergoing stereotactic laser amygdalohippocampotomy (SLAH) who had drug-resistant mesial temporal lobe epilepsy due to left hippocampal sclerosis. Given strong baseline cognitive performance, there was concern for post-operative declines in language and verbal memory were this patient to undergo open resection. She was evaluated pre- and post-ablation with clinical and experimental neuropsychological measures including semantic memory, category-specific object/face recognition and naming, spatial learning, and socio-emotional processing. The patient became seizure-free following SLAH and experienced significant improvements in school performance and social engagement. She experienced improvement in recognition and naming of multiple object categories, memory functions, and verbal fluency. In contrast, the patient declined significantly in her ability to recognize emotional tone from facial expressions, a socio-emotional process that had been normal prior to surgery. We believe this decline was related to surgical disruption of the limbic system, an area highly involved in emotional processing, and suspect such deficits are an under-assessed and unrecognized risk for all surgeries involving the amygdalohippocampal complex and broader limbic system regions. We hope this positive SLAH outcome will serve as impetus for group level research to establish its safety and efficacy in the pediatric setting.

© 2020 The Authors. Published by Elsevier Inc. This is an open access article under the CC BY-NC-ND license (<http://creativecommons.org/licenses/by-nc-nd/4.0/>).

## 1. Introduction

### 1.1. Promise of stereotactic laser amygdalohippocampotomy for controlling seizures with minimal cognitive consequences

Minimally invasive procedures, such as stereotactic laser ablation (SLA) and focused ultrasound, are opening up new options for the surgical management of epilepsy [1–3]. For patients with medial temporal lobe epilepsy (MTLE), stereotactic laser amygdalohippocampotomy (SLAH) is a promising alternative treatment to open resection (OR) procedures [2]. SLAH utilizes advances in neuroimaging and surgical navigation that offer a minimally invasive and targeted neurosurgical treatment option, and the ability to ablate brain tissue more focally

than OR techniques. To date, extant research on SLAH has been almost entirely adult-focused and centered principally on feasibility and outcomes, especially changes in seizure frequency [4,5]. Research has examined neuropsychological consequences of SLAH only in adults thus far [6–8], and only a single study has directly compared neurocognitive outcome in SLAH with that in OR [9]. Thus, there is a strong need for investigations of neurocognitive outcomes in pediatric epilepsy patient groups undergoing SLAH.

An assumed benefit of SLAH's minimally invasive approach is that neurocognitive decline is minimized by reducing collateral damage to functional tissue when compared with traditional OR [10]. This hypothesis has been corroborated in adult studies of naming [6,9] and object/face recognition [9]. While episodic declarative memory findings have been mixed [6], the overall pattern reflects better preservation of memory in patients undergoing SLAH rather than OR although decline can occur [1,10]. Overall, the frequency and magnitude of memory decline following SLAH appears to be less than has been reported in published research following OR.

\* Corresponding author at: Neurology and Pediatrics, Emory University School of Medicine, 101 Woodruff Circle, Suite 6011, Atlanta, GA 30322, USA.  
E-mail address: [ddrane@emory.edu](mailto:ddrane@emory.edu) (D.L. Drane).

### 1.2. Potential benefit of stereotactic laser ablation in pediatric epilepsy

We assume that there will be similar sparing of select neurocognitive functions in pediatric patients undergoing SLAH when compared with adults, yet there are no reports in the research literature with this population. Based on published pediatric data with traditional OR procedures, we would expect that similar patterns of vulnerability will be observed [11,12]. For example, in a review by Sherman et al. [13], findings from OR procedures in children are reported to be similar to those seen in adults, including heightened risk of decline in verbal memory and naming skills. Decline in naming, but not verbal memory ability, was associated with increased size of resection area. Currently, research on neurocognitive outcomes of pediatric MTLE patients following SLAH is lacking, as are studies comparing neurocognitive outcomes between SLAH and OR methods.

Beyond the benefits of potential neurocognitive sparing with SLAH in adults, there appears to be only a minimal decrement in seizure freedom outcome as compared with OR procedures [1,14]. These findings suggest a tradeoff between decreased collateral damage of SLAH, which is frequently sufficient for a seizure-free outcome, and slight to moderate increased likelihood of seizure freedom with standard OR surgical methods. Moreover, in patients with persistent seizures following SLAH, repeat stereotactic laser ablation (SLA) and/or subsequent OR remain options. This would seemingly make SLAH a preferred first choice in patients at risk for cognitive decline, which is more often than not sufficient for a seizure-free outcome. Seizure outcome studies in pediatrics are restricted to two articles demonstrating that SLA can lead to successful surgical outcomes in children [15,16]. These publications lack direct comparison to OR procedures and provide no data regarding neurocognitive outcome.

A few of the earliest publications involving the SLA procedure pertained to its use in children and young adults with seizures related to hypothalamic hamartomas (HH) [15,17]. Results in this patient group suggested that SLA can be used to surgically ablate HH lesions, without many of the side effects that can occur with OR. Such side effects include diabetes insipidus and cognitive decline. Many of these patients had preexisting cognitive delays and no formal testing was reported beyond parent and physician subjective assessment of outcome.

### 1.3. Current case presentation objectives

Given the absence of studies examining pediatric outcomes from SLAH, including neurocognitive effects and seizure burden, we present results from a 15-year-old patient with MTLE with hippocampal sclerosis (HS) who underwent left SLAH. We evaluated the patient pre-operatively and at two post-operative time points (6 months and one year). Evaluations involved comprehensive neuropsychological assessments that assessed a wide range of cognitive and psychosocial domains, including several experimental domains not typically evaluated in clinical settings (semantic memory, spatial learning, category-specific naming and recognition, socio-emotional processing).

## 2. Methods

We reviewed the patient's presurgical evaluation and history, the left SLAH procedure, and her post-surgical outcome. We focused on cognitive and emotional change derived from repeated neuropsychological evaluation and seizure freedom outcome reported using Engel outcome classification scale [18]. For assessing cognitive change, we used reliable change indices when available and, otherwise, reported change in standard deviation (SD) of improvement or decline [19,20]. Consistent with clinical and research practice, we considered a 1–2 SD change in performance to reflect a mild to moderate change in performance, and a greater than 2 SD change in performance to reflect a large change.

## 3. Results — case presentation

### 3.1. Review of demographics and disease-specific case details

The current patient presented as a 15-year-old, right-handed, right-footed Caucasian female with MTLE who was first diagnosed with focal impaired-awareness seizures at age 10 years old. She recalls that she experienced “funny feelings” at times as early as the age of 4 to 5 years, but these sensations were not considered a cause for concern. Two seizure types were reported: 1) focal impaired-awareness seizures occurring eight to ten times per month and lasting 60–90 s that included right-hand posturing, slurred speech, and oral-motor distortions, after which the patient typically returned to baseline functioning and 2) episodes during which she experienced vivid “mental pictures” that occurred three to four times a week. Multiple antiseizure medications (ASMs) had been attempted without obtaining complete seizure control. The patient had experienced a reduction of seizures but was beginning to experience declines in cognitive function and performance in school and daily life. This led her treating physicians to consider surgical intervention for her care. Prior to her surgery, the patient was being treated with clobazam (20 mg QD), lacosamide (200 mg BID), felbamate (1500 mg TID), and levetiracetam (1500 mg BID). She was also being treated with methylphenidate (36 mg QD) both pre- and post-surgically to improve her attention. Medical history was otherwise noncontributory, with no family history of seizures and no personal history of head trauma, birth injury, developmental delay, or febrile seizures.

### 3.2. Presurgical functional status

At presurgical baseline, the patient was attending 9th grade. While she continued to make average grades with scores ranging from “A to C”, her family reported that she had to work exceptionally hard to keep up with her classmates. The patient's parents reported long-standing concerns about academic problems, especially in math. Ninth grade was difficult for her, and she was having trouble following information and organizing her school effort. Her parents described the patient as less alert than in the past and felt her performance was slower and less accurate due to her ASM regimen. They described her as emotionally blunted and less mature than her peers, including her personal interests. Socially, they reported that she was more withdrawn. In general, they believed that her quality of life was suffering due to ongoing seizure burden and a polytherapeutic medication regimen.

### 3.3. Presurgical epilepsy evaluation

Presurgical 3-tesla magnetic resonance imaging (3 T MRI) of the brain revealed the presence of left HS. Consistent with structural imaging findings, video-EEG evaluations revealed left anterior temporal lobe seizure onset. A magnetoencephalography (MEG) localized interictal epileptiform discharges to the left fronto-temporal region. Results of MEG and functional MRI suggested left hemisphere cerebral language dominance. An intracarotid amobarbital (Wada) procedure performed primarily to assess risk of memory dysfunction indicated predominantly left hemisphere language representation with no elevated risk for an amnesic outcome. The patient was considered to be at risk of verbal memory decline, as she obtained passing memory scores following injections ipsi- and contralateral to her seizure onset. She was initially considered for a traditional OR procedure involving the left temporal lobe but was eventually referred for a left SLAH due to concerns about cognitive consequences associated with OR.

### 3.4. Presurgical neuropsychological evaluation findings

As part of this patient's preoperative workup, a comprehensive neuropsychological evaluation was performed. For the purpose of our study, we focused on tasks for which post-surgical changes were

observed and on tasks that have frequently shown change following OR procedures in published research (e.g., episodic memory, confrontational naming, verbal generative fluency, object/face recognition) [21]. Neuropsychological assessment tools included both established and novel measures; novel measures are indicated within the tables, and included more extensive semantic memory, category-related naming and recognition, spatial learning, visual processing, and socio-emotional tasks.

The patient presented for the presurgical neuropsychological evaluation as pleasant and friendly. Socially, she was quiet and interactions were immature for age. Evaluation results indicated average overall intellectual functioning [22] and average working memory and psychomotor processing speed (Table 1). The patient's visual confrontation naming ability (Table 2) varied from the impaired (Emory Famous Faces Test (EFFT)-Adult Version) [23] to average range (EFFT-Children's Version; Iowa Landmark and Emory Animal Naming Tests) [24,25], depending upon the type of item to be named. Naming man-made objects was moderately impaired [26]. The patient's recognition of objects and faces also varied from the impaired (EFFT-Adult Version) to average (Iowa Landmark and Emory Animal Naming Tests) range. Response time across these tasks fell in the impaired range. Auditory naming was also impaired in accuracy and speed [27].

Semantic fluency skills (Table 3) on established measures ranged from borderline (D-KEFS Category Fluency) to average (Animal Fluency) [28]. Performance on novel fluency measures (Emory Semantic Fluency paradigm: ESFP) [29] was similarly variable, including skills in the impaired (ESFP – Animal, Famous Person, Famous Landmarks, Television Shows, & Places to Shop or Dine Fluency subtests), borderline (ESFP Household Object Fluency), and average (ESFP Musical Instrument & Supermarket Item Fluency tasks) ranges. Most generative verbal fluency skills on novel semantic measures improved when cues were provided.

Auditory-verbal learning and memory ability was in the average range for both rote (Rey Auditory Verbal Learning Test (RAVLT); word lists) [30,31] and contextual (4th edition of the Wechsler memory Scale (WMS-IV) Logical Memory; stories) [32] information, with the exception of weak recognition skill on both tasks. Visual-spatial learning and memory skills were variable. When required to recall, reproduce (draw), and recognize designs briefly shown to her (WMS-IV Visual Reproduction), the patient's performance was average. However, when required to learn visual-spatial information over repeated trials (Brown's Location Test) [33] her performance was variable, resulting in an overall learning score in the borderline range. Short-delay free recall ability was in the borderline range and declined to the impaired range following a longer delay. Recognition performance on this task was in the borderline range.

The patient's performance on measures of attention/executive function was variable. Her cognitive fluency when spontaneously providing words beginning with a specified letter and verb/action words ranged from borderline to impaired. Her cognitive flexibility was in the average range on both verbally and visually mediated tasks (D-KEFS Verbal Fluency, Category Switching & D-KEFS Design Fluency).

**Table 1**  
Intellectual function – pre-/post-surgical comparison.

Measure	Pre-SLAH SS/%	Measure	1-Year SS/%
Intellectual			
WISC-IV FSIQ	N/A	WAIS-IV FSIQ	93/32nd
WISC-IV WMI	94/34th	WAIS-IV WMI	100/50th
WISC-IV PSI	94/34th	WAIS-IV PSI	89/23rd

Note. SLAH = stereotactic laser amygdalohippocampotomy; SS = standard score; WISC-IV = Wechsler Intelligence Scale for Children (4th edition); FSIQ = Full-Scale Intellectual Quotient; WMI = Working Memory Index; PSI = Processing Speed Index.

Emotionally, no significant mood or anxiety problems were endorsed on standardized self-report measures (i.e., Beck Anxiety Inventory (BAI), 2nd edition of the Beck Depression Inventory (BDI-2)) (Table 6) [34–36]. On a measure of quality of life, the patient endorsed mildly elevated concern regarding seizures, and low energy/fatigue [37,38]. Socially (Table 6), the patient's ability to perceive others' emotional state from facial expression was in the average range (Reading the Mind Through the Eyes Test) [39].

### 3.5. Surgical procedure

The patient underwent an MRI-guided left SLAH at Emory University Hospital. This consisted of stereotactic trans-occipital to mesial temporal insertion of a saline-cooled cannula with fiber optic under general anesthesia, targeting the inferior amygdala and the associated uncus, and the hippocampus from the head to posterior body [2,4]. Laser-induced interstitial thermal energy was delivered during continuous MRI-based thermography (Visualase, Medtronic, Inc., Louisville, CO). Ablation extent was determined in real-time from thermal imaging and confirmed post procedure with FLAIR and contrast-enhanced T1 MPRAGE anatomic imaging. Post-surgical MRI, immediately and 2 years after the surgery (see Fig. 1), revealed an ablation zone involving the inferior amygdala, uncus and head and body of the hippocampus, extending posteriorly to the level of the lateral mesencephalic sulcus, which was considered a technical success. The procedure was performed without complication and the patient was discharged home the following day.

### 3.6. Post-surgical outcome

The patient was re-evaluated by her neurosurgeon (REG) and neuropsychologist (DLD) at Emory University at both six-month and one-year post-surgical follow-up. The patient remained seizure-free at both time points (Engel Class I outcome) and had no reported complications in any neurological or psychosocial domain. Parent report at follow-up evaluations indicated that she seemed brighter, less fatigued, and sharper cognitively, and that her performance in school had improved, although she continued to struggle with mathematics. The patient began running track and cross-country and intended to obtain a driver's license. These changes were seen as positive improvements in her engagement in school and with peers. The patient's medication regimen was reduced following her 6-month follow-up to include only felbamate (1200 mg TID) and levetiracetam (1500 mg BID). Behaviorally, the patient was described as more outgoing and alert by her examiners and reported improved self-confidence.

### 3.7. Postsurgical neuropsychological evaluation findings

Direct comparisons of the patient's intellectual function pre- and one-year post-SLAH could not be made due to age-related change in assessment tools; however, indirect comparisons suggest stable overall intellectual, working memory, and processing speed skills [40] (Table 1), with all scores remaining in the average range. Her visual confrontation naming ability (Table 2) improved significantly over post-SLAH time points on some naming tasks (BNT, EFFT-Children's & Adult Versions, Emory Landmark Naming Task, Columbia Auditory Naming Test), and remained stable on others (Emory Animal Naming Task). Postsurgical recognition of famous faces improved markedly, while all remaining object recognition performances remained stable. Rate of response significantly improved across all naming measures.

The patient's pattern of performance on some semantic fluency tasks (Table 3) was U-shaped, showing a decline from presurgical skill at the six-month follow-up evaluation that improved at the final evaluation (ESFP – Animal Fluency; Supermarket, Television Show, & Places to Shop or Dine Fluency). Performance improved at the initial follow-up evaluation on the Emory Household Item Fluency task, but declined at

**Table 2**  
Naming – pre-/post-surgical comparison.

Measure	Time 1	Time 2	Difference	Time 3	Difference	Meaningful change
	Raw/%	Raw/%		Raw/%		
<b>BNT</b>						
Raw score	44/60	N/A	N/A	50/60	+6	Yes
Semantic total	45/60	N/A	N/A	50/60	+5	Yes <sup>a</sup>
	Moderately impaired			Low average		
<b>Auditory Naming Test</b>						
Total score	41/50, <1st	44/50, 1st	+3	N/A	N/A	No
Tip of the tongue score	21, <1st	11, 3rd	+10	N/A	N/A	Yes <sup>b</sup>
Mean response time (seconds)	2.5, 1st	1.8, 5th	+0.7	N/A	N/A	Yes <sup>b</sup>
<b>Emory Naming Paradigms</b>						
<b>EFFT-Children's Version</b>						
Recognition (familiar items)	58/63, Average	N/A	N/A	61/61 High average	+3	No
Total Recognition (all items)	58/65, Average	N/A	N/A	61/65, Average	+3	No
Naming (recognized items)	51/58, Average	N/A	N/A	55/61, High average	+4	Yes <sup>b</sup>
Response Speed (seconds)	5.56, Moderately impaired	N/A	N/A	3.19, Low average	+2.37	Yes <sup>c</sup>
<b>EFFT-Adult Version</b>						
Recognition (familiar items)	29/53, Moderately impaired	N/A	N/A	32/59, Moderately impaired	+3	No
Total Recognition (all items)	29/105, Moderately impaired	N/A	N/A	32/105, Moderately impaired	+3	No
Naming (recognized items)	12/29, Impaired	N/A	N/A	20/32, Low average	+8	Yes <sup>c</sup>
Response Speed (seconds)	7.94, Low average	N/A	N/A	5.50, Average	+2.44	Yes <sup>b</sup>
<b>Landmarks</b>						
Recognition (familiar items)	24/48, Low average	N/A	N/A	22/47, Low average	-2	No
Total Recognition (all items)	24/65, Borderline	N/A	N/A	22/65, Borderline	-2	No
Naming (recognized items)	12/24, Moderately impaired	N/A	N/A	20/32, Low average	+8	Yes <sup>c</sup>
Response Speed (seconds)	6.20, Impaired	N/A	N/A	4.28, Average	+1.92	Yes <sup>b</sup>
<b>Animals</b>						
Recognition (familiar items)	72/80, Average	N/A	N/A	72/80, Average	0	No
Total Recognition (all items)	72/80, Average	N/A	N/A	72/80, Average	0	No
Naming (recognized items)	69/72, High average	N/A	N/A	71/72, High average	+2	No
Response Speed (seconds)	6.58, Impaired	N/A	N/A	2.17, High average	+4.41	Yes <sup>c</sup>

Note. BNT = Boston Naming Test; EFFT = Emory Famous Faces Test; SD = standard deviation.

<sup>a</sup> Significant change with reliable change indices.

<sup>b</sup> Significant change of 1–2 SD magnitude.

<sup>c</sup> Significant change of >2 SD magnitude.

one-year, whereas D-KEFS Verbal Fluency was consistent with presurgical performances at the six-month follow-up but improved at the final evaluation. Proper noun fluency performances remained stable and well below average across all time points.

In areas of learning and memory (Table 4), the patient's auditory-verbal memory for contextual information was stable pre-SLAH to the six-month follow-up evaluation. Recognition performance improved significantly. Rote auditory/verbal learning ability remained stable at the six-month postsurgical evaluation when compared with baseline and declined non-significantly at one-year follow-up. Immediate and delayed memory and recognition performances were generally consistent across all time points.

The patient's overall performance on visual-spatial learning and memory tasks (Table 4) ranged from stable to improved following SLAH. Her ability to reproduce and recognize designs from memory remained average across all evaluations. Her ability to learn visual-spatial information following repeated exposures improved significantly

after SLAH, whereas her retention of the information remained stable. Recognition performance significantly improved on this task.

On measures of attention/executive function (Table 5), the patient's verbally mediated cognitive fluency showed improvement at the final evaluation when compared with presurgical performance. Verbally mediated cognitive flexibility initially declined following SLAH, but significantly improved at the one-year time point. Visually mediated cognitive fluency significantly improved from presurgical levels, whereas cognitive flexibility remained stable.

Emotionally (Table 6), no significant changes were reported for mood or anxiety across time points. Quality of life improved incrementally, but significantly, across the three time points with the exception of medication effects and social functioning. The patient continued to report diminished functioning in the social sphere of life. Of note, the patient's ability to recognize emotion from facial expression declined significantly following the SLAH procedure, with her performance decreasing from the average to the impaired range.

**Table 3**  
Semantic fluency/pre-/post-surgical comparison.

Measure	Time 1	Time 2	Difference	Time 3	Difference	Meaningful change
	Raw/%	Raw/%		Raw/%		
<b>D-KEFS</b>						
Letter Fluency	15, 2nd	13, 1st	-2	28, 25th	+13	Yes <sup>c</sup>
Category Fluency	20, 2nd	21, 2nd	+1	40, 63rd	+20	Yes <sup>c</sup>
Category Switching	9, 25th	10, 35th	+1	17, 95th	+8	Yes <sup>c</sup>
<b>Animal Fluency</b>						
<b>Emory Semantic Fluency Paradigm<sup>b</sup></b>						
Animals, Standard	11, Mildly impaired	12, Mildly impaired	+1	21, Average	+10	Yes <sup>b</sup>
Animals, Cued	20, Low average	18, Borderline	-2	22 Low average	+2	No <sup>b</sup>
Famous Persons, Standard	4, Impaired	5, Impaired	+1	5, Impaired	+1	No
Famous Persons, Cued	9, Mildly impaired	7, Moderately impaired	-2	10, Borderline	+1	No
Famous Landmarks, Standard	4, Impaired	3, Impaired	-1	4, Impaired	0	No
Famous Landmarks, Cued	9, Mildly impaired	7, Mildly impaired	-2	8, Mildly impaired	-1	No
Household Objects, Standard	16, Borderline	20, Average	+4	17, Borderline	+1	No
Household Objects, Cued	26, Average	19, Low average	-7	19, Low average	-7	No
Musical Instruments, Standard	17, High average	17, High average	0	14, Average	-3	No
Musical Instruments, Cued	13, Low average	13, Low average	0	14, Low average	+1	No
Supermarket Items, Standard	17, Average	9, Moderately impaired	-8	17, Low average	0	Yes <sup>b</sup> (6 months)
Supermarket Items, Cued	15, Borderline	20, Low average	+5	22, Average	+7	Yes <sup>b</sup> (both time points)
Television Shows, Standard	9, Mildly impaired	5, Moderately impaired	-4	8, Mildly impaired	-1	No
Television Shows, Cued	8, Moderately impaired	7, Moderately impaired	-1	8, Moderately impaired	0	No
Places to Shop/Dine, Standard	8, Mildly impaired	6, Moderately impaired	-2	9, Mildly impaired	+1	No
Places to Shop/Dine, Cued	11, Mildly impaired	9, Moderately impaired	-2	11, Mildly impaired	0	No

Note. D-KEFS = Delis-Kaplan Executive Function System; SD = standard deviation.

<sup>a</sup> Significant change with reliable change indices.

<sup>b</sup> Significant change of 1–2 SD magnitude.

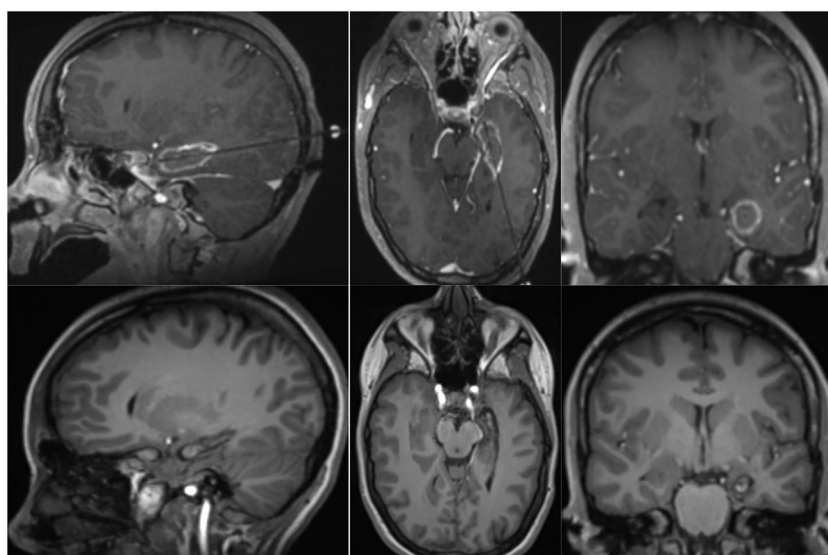
<sup>c</sup> Significant change of >2 SD magnitude.

#### 4. Discussion

We present outcome data for a teenager undergoing SLAH, demonstrating that this procedure can be safely tolerated and can be effective for achieving seizure control and favorable neuropsychological outcome. The patient remains seizure-free, achieving an Engel Class I outcome following SLAH at one-year follow-up. Although a single case limits broad conclusions, these results suggest that SLAH may be a promising alternative to OR in the treatment of MTL in a pediatric population. From a neuropsychological perspective, this patient improved across multiple cognitive domains including language, visual and verbal memory, executive control, and visual-spatial processing domains. It

had been perceived decline in cognitive function, which prompted her treating providers to consider a surgical option. Further, quality of life significantly improved from pre- to post-SLAH. We did find, however, that performance on a novel social-emotional task requiring the patient to recognize emotional content from facial expressions significantly declined, likely due to the involvement of limbic structures in this complex network underlying emotional processing [41].

Findings of language improvements are consistent with results from the existing adult literature with SLAH [9,10]. It has been suggested that better visual confrontation naming outcome results from sparing critical white matter pathways and temporal lobe brain regions that support naming ability, which include the temporal pole, basal temporal



**Fig. 1.** Ablation and post-ablation 3 T MRI scans of the brain demonstrating a completed left stereotactic laser amygdalohippocampotomy in a pediatric patient (images from left to right include sagittal, axial, and coronal presentations of the brain).

**Table 4**  
Memory/pre-/post-surgical comparison.

Measure	Time 1	Time 2	Difference	Time 3	Difference	Meaningful change
	Raw/%	Raw/%		Raw/%		
<b>Verbal Learning &amp; Memory</b>						
WMS-IV Logical Memory						
Story A	13	14	+1	N/A	N/A	N/A
Story B	13	13	0	N/A	N/A	N/A
Logical Memory I	26/50th	27/63rd	+1	N/A	N/A	No
Logical Memory II	18/25th	18/25th	0	N/A	N/A	No
Recognition	22/30	26/30	+4	N/A	N/A	Yes <sup>b</sup>
Rey Auditory Verbal Learning Test						
Total (Trials 1–5)	53/44th	56/62nd	+3	46/12th	–7	No
Immediate Recall	12/59th	14, 86th	+2	13/74th	+1	No
Delayed Recall	10/21st	12/55th	+2	10/21st	0	No
Recognition Discrimination	10/15/1st	14/15/43rd	+4	12/15/3rd	+2	Yes (6-month only) <sup>b</sup>
<b>Visual Learning &amp; Memory</b>						
WMS-IV Visual Reproduction						
Visual Reproduction I	39/50th	41/63rd	+2	N/A	N/A	No
Visual Reproduction II	23/25th	28/37th	+5	N/A	N/A	Yes <sup>b</sup>
Recognition	6/7, Average	5/7, Average	–1	N/A	N/A	No
Brown's Location Test						
Total (Trials 1–5)	27/5th	38/38th	+11	49/83rd	+22	Yes (6-month) <sup>b</sup> Yes (1-year) <sup>c</sup>
Short Delay Free Recall	6/8th	7/48th	+1	12/87th	+6	Yes (1-year only) <sup>c</sup>
Long Delay Free Recall	4/1st	8/28th	+4	10/61st	+6	Yes (6-month) <sup>b</sup> Yes (1-year) <sup>c</sup>
Recognition Total Correct	14/4th	18/32nd	+4	21/69th	+7	Yes (6-month) <sup>b</sup> Yes (1-year) <sup>c</sup>

Note. WMS-IV = Wechsler Memory Scale (4th edition); SD = standard deviation.

<sup>a</sup> Significant change with reliable change indices.

<sup>b</sup> Significant change of 1–2 SD magnitude.

<sup>c</sup> Significant change of >2 SD magnitude.

language area, inferior fronto-occipital fasciculus, and arcuate fasciculus [9,10,42]. Of note, the patient showed significant gains across multiple object categories and showed continued improvement over time. This is in stark contrast to naming outcome observed following open resections in adults, where deficits are much more likely to occur [43,44], and ultimately persist beyond an initial period of possible recovery [23,24]. Additionally, gains over time have not traditionally been seen on these tasks in adults following OR, although they are being reported in adult patients undergoing SLAH [10].

The patient experienced notable gains across multiple verbal generative fluency tasks. However, the latter improvement (verbal fluency) was only noticeable at one-year follow-up, likely owing to a modification in her ASM regimen that occurred prior to her one-year evaluation. It is possible that further improvement in cerebral network integrity has occurred over time, as such gains have been observed in pediatric and adult patients who become seizure-free following surgery [45,46]. The

patient had two of her four ASMs discontinued prior to her last assessment time point, and such medications have a known effect on verbal fluency [21,47], particularly when the number of ASMs used rises above two, or when therapeutic blood levels are exceeded [48]. Of note, ASMs have less influence on confrontation naming accuracy but can affect speed of response in this area. The patient exhibited impaired scores on many verbal generative fluency scores at baseline, but by one-year follow-up, many were within the average range. The patient continued to have much greater difficulty generating proper nouns, which is a function highly dependent on language-dominant anterior temporal lobe structures (i.e., temporal pole) [49,50]. Response rates, however, were much improved across all verbal tasks.

Based on recent studies in adult epilepsy surgery patients, it was feared that our patient would have experienced declines in naming ability following OR [9,51,52], particularly given the large number of object categories sampled. We have previously found that a high percentage of

**Table 5**  
Executive function/pre-/post-surgical comparison.

Measure	Time 1	Time 2	Difference	Time 3	Difference	Meaningful change
	Raw/%	Raw/%		Raw/%		
<b>D-KEFS</b>						
Verbal Fluency						
Letter Fluency	15/2nd	13/1st	–2	28/25th	+13	Yes (1-year only) <sup>c</sup>
Category Fluency	20/2nd	21/2nd	+1	40/63rd	+20	Yes (1-year only) <sup>c</sup>
Category Switching	9/25th	10/37th	+1	17/95th	+8	Yes (1-year only) <sup>c</sup>
Design Fluency						
Filled Dots	6/16th	N/A	N/A	11/63rd	+5	Yes (1-year only) <sup>b</sup>
Empty Dots	7/16th	N/A	N/A	11/50th	+4	Yes (1-year only) <sup>b</sup>
Switching	7/37th	N/A	N/A	7/37th	0	No <sup>b</sup>
Action/Verb Fluency	12/1st	12/1st	0	17, 16th	+4	No

Note. D-KEFS = Delis–Kaplan Executive Function System; SD = standard deviation.

<sup>a</sup> Significant change with reliable change indices.

<sup>b</sup> Significant change of 1–2 SD magnitude.

<sup>c</sup> Significant change of >2 SD magnitude.

**Table 6**

Psychosocial function/pre-/post-surgical comparison.

Measure	Time 1	Time 2	Difference	Time 3	Difference	Meaningful change
	T/%	T/%		T/%		
Quality of life						
Overall score	48	53	+5	60	+12	Yes (1 year only) <sup>b</sup>
Seizure worry	38	43	+5	54	+16	Yes (1 year only) <sup>b</sup>
Overall quality of life	53	52	-1	68	+15	Yes (1 year only) <sup>b</sup>
Emotional well-being	50	57	+7	57	+7	Yes (both) <sup>b</sup>
Energy/fatigue	38	55	+17	64	+26	Yes (6-month) <sup>b</sup> Yes (1-year) <sup>c</sup>
Cognitive functioning	47	50	+3	55	+8	Yes (1-year only) <sup>b</sup>
Medication effects	46	50	+4	55	+8	Yes (1-year only) <sup>b</sup>
Social functioning	58	43	-15	50		
Beck Depression Inventory, 2nd Ed.						
Total score	5, Normal	11, Mild depression	-6	1, Normal	+4	Yes <sup>b</sup>
Beck Anxiety Inventory						
Total score	8, Normal	0, Normal	+8	0, Normal	+8	Yes <sup>b</sup>
Reading the Mind Through the Eyes Test						
Total score	28/36, Average	21/36, Mildly impaired	-7	19/36, Moderately impaired	-9	Yes <sup>c</sup>

Note. T = T-score; SD = standard deviation.

<sup>a</sup> Significant change with reliable change indices.<sup>b</sup> Significant change of 1–2 SD magnitude.<sup>c</sup> Significant change of >2 SD magnitude.

language-dominant MTLE patients undergoing OR (including standard, tailored, and selective approaches) show decline if man-made objects and famous persons are sampled [9,23]. Busch et al. [51] found that more than 40% of such patients declined significantly on man-made objects alone. In the current study, the patient showed significant gains over time in her ability to generate both proper and common nouns to confrontation. Of note, while the patient had a limited baseline knowledge of famous individuals from politics, television/movies, sports, and popular culture (Emory Famous Faces Test), she exhibited a normal performance on a newly developed task designed to assess similar knowledge in children (Emory Famous Faces Test – Children's Version). The latter assesses the ability to name and recognize iconic adult figures (e.g., Abraham Lincoln), characters from movies and television directed toward children (e.g., Cinderella, Harry Potter), and cartoon characters with proper names (e.g., Mickey Mouse). This highlights that children and adolescents may need specialized tasks of naming ability that are geared toward information and individuals that they are likely to encounter. The patient exhibited gains in the recognition and naming of persons on both tasks. This newly created task should enable clinicians and researchers to assess proper noun naming in children as well as individuals who are developmentally delayed.

Significant visual memory improvements were observed following left SLAH in this teenage patient and auditory/verbal memory remained stable or slightly improved. The patient performed slightly better at six-month follow-up on verbal memory measures than she did at one-year. The reason for this pattern is unclear but may reflect chance fluctuation as her overall scores remained unimpaired across assessments. Even in MTLE patients with HS, memory decline frequently occurs following OR procedures in adults [53,54] and memory decline is often observed in pediatric cases following temporal lobe surgical procedures [13]. It would seem likely that ablating a portion of the amygdalohippocampal complex (AHC) rather than removing this region and broader temporal lobe structures would be advantageous for memory outcome, as long as the chosen AHC is not essential for effective declarative memory processing. These findings suggest that a unilateral AHC is not an absolute requirement for such processing, consistent with data observed in many adult cases. This is not to say that memory cannot be hurt by the SLAH procedure, only that it seems less likely to occur as compared with a broader OR option.

Otherwise, mild gains were observed across a variety of cognitive domains, including executive functions, recognition of objects, and visuo-perception. Stable performances were observed across processing speed, attention, visual-spatial processing, and constructional ability. Fine-motor speed and coordination was decreased bilaterally (right-hand more restricted than left-hand) at one-year follow-up. This latter finding may reflect the effects of medications, and could have been present presurgically, although it was not assessed at that time.

In contrast, one area of post-ablation decline involved a mild to moderate decline in recognizing emotion from facial expression. This is a function that can contribute to social interactions but that has not been routinely assessed in a clinical setting in adults or children with epilepsy. It is not surprising that elements of emotional processing can be affected by a medial temporal lobe procedure, given the known importance of the limbic system in emotional processing [55] and the emerging role of the anterior temporal lobe in social processing [56]. This is an area of study that needs to be explored in both children and adults, as little research exists.

In addition to the extremely positive cognitive outcome results in this teenager undergoing a left SLAH, the patient has remained seizure-free since undergoing the ablation. Initial results from the SLAH procedure in adults have been very promising with regard to seizure control, with only a slight relative decrement in proportion of patients rendered seizure-free [1,57] when compared with OR outcomes. The slightly worse seizure freedom outcome with SLAH is offset by the positive cognitive outcome. Moreover, further surgical procedures can be carried out if SLAH does not successfully render a patient seizure-free.

Future research is needed in pediatric patients undergoing SLA procedures, and should include not only those with MTLE undergoing SLAH but patients requiring focal ablations in other temporal and extra-temporal brain regions. MTLE is less common in pediatric than in adult populations, and there are going to be many more cases of focal ablations of non-medial temporal lobe regions due to the presence of developmental brain abnormalities in children (e.g., dysplasia, schizencephaly, tumors, gyral abnormalities). It is likely that deficits will occur if functional tissue is resected/ablated no matter where it is located in the brain, but it is also probable that restricting surgical interventions to the least destructive zone will minimize acquired dysfunction. Direct comparisons between OR and SLA procedures would be highly informative for ultimately assisting patients and their families to make treatment decisions.

## Ethical publications statement

All authors confirm that we have read the Journal's position on issues involved in ethical publication and affirm that this report is consistent with those guidelines (i.e., Declaration of Helsinki). Informed consent was received from the patient and her parents related to her participation in our clinical research.

## CRediT authorship contribution statement

**Kim E. Ono:** Writing - original draft, Conceptualization, Formal analysis. **Donald J. Bearden:** Conceptualization, Formal analysis, Visualization, Writing - review & editing. **Elizabeth Adams:** Conceptualization, Investigation, Writing - review & editing. **Jason Doescher:** Conceptualization, Writing - review & editing. **Sookyong Koh:** Conceptualization, Writing - review & editing. **Yaman Eksioglu:** Conceptualization, Writing - review & editing. **Robert E. Gross:** Investigation, Visualization, Writing - review & editing. **Daniel L. Drane:** Conceptualization, Methodology, Formal analysis, Supervision, Writing - original draft, Writing - review & editing.

## Declaration of competing interest

Dr. Robert Gross serves as a consultant to Medtronic, Inc. and receives compensation for these services. Medtronic, Inc. develops products related to the research described in this paper. The terms of this arrangement have been reviewed and approved by Emory University in accordance with its conflict of interest policies. Dr. Daniel Drane has received research support from Medtronic, Inc. related to other projects. Dr. Gross is co-primary investigator of the Stereotactic Laser Ablation in Temporal Lobe Epilepsy (SLATE) FDA trial being completed by Medtronic, Inc. Dr. Drane is the core lab director of the neuroimaging and neuropsychological procedures used in the SLATE trial. The remaining authors have nothing to disclose.

## Acknowledgments

We would like to thank Gloria Novak for her assistance with lab coordination. Dr. Daniel Drane's research efforts related to this project were supported by two grants from the NIH/NINDS (K02 NS070960 & R01NS088748) and a project grant from the Goizueta Business School and Children's Hospital of Atlanta. These grants provide salary support for Dr. Drane and his laboratory staff and covered the cost of all research related activities. Drs. Ono and Bearden have received partial salary support from the latter project grant.

## References

- [1] Gross RE, Stern MA, Willie JT, Fasano RE, Saindane AM, Soares BP, et al. One-year outcomes following stereotactic laser amygdalohippocampotomy for the treatment of mesial temporal lobe epilepsy: 5-year experience in 58 patients. *Ann Neurol*. 2018;83:575–87.
- [2] Gross RE, Willie JT, Drane DL. The role of stereotactic laser amygdalohippocampotomy in mesial temporal lobe epilepsy. *Neurosurg Clin N Am*. 2016;27(1):37–50.
- [3] Tovar-Spinoza Z, Carter D, Ferrone D, Eksioglu Y, Huckins S. The use of MRI-guided laser-induced thermal ablation for epilepsy. *Children's Nerv Syst*. 2013;29:2089–94.
- [4] Willie JT, Laxpati NG, Drane DL, Gowda A, Appin C, Hao C, et al. Real-time magnetic resonance-guided stereotactic laser amygdalohippocampotomy (SLAH) for mesial temporal lobe epilepsy. *Neurosurgery*. 2014;74(6):569–85.
- [5] Jermakowicz WJ, Kanner AM, Sur S, Bermudez C, D'Haese PF, Kolcun JPG, et al. Laser thermal ablation for mesiotemporal epilepsy: analysis of ablation volumes and trajectories. *Epilepsia*. 2017;58(5):801–10.
- [6] Dredla BK, Lucas JA, Wharen RE, Tatum WO. Neurocognitive outcome following stereotactic laser ablation in two patients with MR-/PET+ mTLE. *Epilepsy Behav*. 2016;56:44–7.
- [7] Kang JY, Wu C, Tracy J, Lorenzo M, Evans J, Nei M, et al. Laser interstitial thermal therapy for medically intractable mesial temporal lobe epilepsy. *Epilepsia*. 2016;57(2):325–34.
- [8] Waseem H, Osborn KE, Schoenberg MR, Kelley V, Bozong AM, Cabello D, et al. Laser ablation therapy: an alternative treatment for medically resistant mesial temporal lobe epilepsy after age 50. *Epilepsy Behav*. 2015;51:152–7.

- [9] Drane DL, Loring DW, Voets NL, Price M, Ojemann JG, Willie JT, et al. Better object recognition and naming outcome with MRI-guided stereotactic laser amygdalohippocampotomy for temporal lobe epilepsy. *Epilepsia*. 2015;56:101–13.
- [10] Drane DL. MRI-guided stereotactic laser ablation for epilepsy surgery: promising preliminary results for cognitive outcome. *Epilepsy Res*. 2018;142:170–5.
- [11] Gilliam F, Wyllie E, Kashden J, Faught E, Kotagal P, Bebin M, et al. Epilepsy surgery outcome: comprehensive assessment in children. *Neurology*. 1997;48(5):1368–74.
- [12] Dangueman AN, Smith ML. Verbal associative memory outcomes in pediatric surgical temporal lobe epilepsy: exploring the impact of mesial structures. *Epilepsy Behav*. 2019;101.
- [13] Sherman EMS, Wiebe S, Fay-McClymount TB, Tellez-Zenteno JF, Metcalfe A, Hernandez-Ronquillo L, et al. Neuropsychological outcomes after epilepsy surgery: systematic review and pooled estimates. *Epilepsia*. 2011;52(5):857–69.
- [14] Youngerman BE, Oh JY, Anbarasan D, Billakota S, Casadei CH, Corrigan EK, et al. Laser ablation is effective for temporal lobe epilepsy with and without mesial temporal sclerosis if hippocampal seizure onsets are localized by stereoelectroencephalography. *Epilepsia*. 2018;59(3):595–606.
- [15] Curry DJ, Gowda A, McNichols RJ, Wilfong AA. MR-guided stereotactic laser ablation of epileptogenic foci in children. *Epilepsy Behav*. 2012;24(4):408–14.
- [16] Lewis EC, Weil AG, Duchowny M, Bhatia S, Ragheb J, Miller IW. MR-guided laser interstitial thermal therapy for pediatric drug-resistant lesional epilepsy. *Epilepsia*. 2015;56:1590–8.
- [17] Wilfong AA, Curry DJ. Hypothalamic hamartomas: optimal approach to clinical evaluation and diagnosis. *Epilepsia*. 2013;54(Suppl. 9):109–14.
- [18] Engel Jr J, Van Ness PC, Rasmussen TB, Ojemann LM. Outcome with respect to epileptic seizures. In: J. Engel J, editor. *Surgical treatment of the epilepsies*. 2nd ed. New York: Raven Press; 1993. p. 609–21.
- [19] Schoenberg MR, Werz MA, Drane DL. Epilepsy and seizures. In: Scott MRSJ, editor. *Black book of neuropsychology*. New York: Springer; 2011. p. 423–519.
- [20] Hermann BP, Seidenberg M, Schoenfeld J, Peterson J, Leveroni C, Wyler AR. Empirical techniques for determining the reliability, magnitude, and pattern of neuropsychological change after epilepsy surgery. *Epilepsia*. 1996;37(10):942–50.
- [21] Drane DL. Neuropsychological evaluation of the epilepsy surgical candidate. In: Barr WB, Morrison C, editors. *Handbook on the neuropsychology or epilepsy*. NY: Springer; 2015. p. 87–121.
- [22] Wechsler D. *Wechsler Intelligence Scale for Children – fourth edition (WISC-IV)*; 2003.
- [23] Drane DL, Ojemann JG, Phatak V, Loring DW, Gross RE, Hebb AO, et al. Famous face identification in temporal lobe epilepsy: support for a multimodal integration model of semantic memory. *Cortex*. 2013;49:1648–67.
- [24] Drane DL, Ojemann GA, Aylward E, Ojemann JG, Johnson LC, Silbergeld DL, et al. Category-specific naming and recognition deficits in temporal lobe epilepsy. *Neuropsychologia*. 2008;46(5):1242–55.
- [25] Tranel D, Enekwachi N, Manzel K. A test for measuring recognition and naming of landmarks. *J Clin Exp Neuropsychol*. 2005;27(1):102–26.
- [26] Kaplan E, Goodglass H, Weintraub S. *Boston Naming Test*. Philadelphia: Lea and Febiger; 1983.
- [27] Hamberger MJ, Seidel WT. Auditory and visual naming tests: normative and patient data for accuracy, response time, and tip-of-the-tongue. *J Int Neuropsychol Soc*. 2003;9(3):479–89.
- [28] Delis DC, Kaplan E, Kramer JH. *Delis-Kaplan Executive Function System: examiner's manual*. San Antonio, Texas: The Psychological Corporation; 2001.
- [29] Drane DL, Lee P G, Cech H, Huthwaite JS, Ojemann GA, Ojemann JG, et al. Structured cueing on a semantic fluency task differentiates patients with temporal versus frontal lobe seizure onset. *Epilepsy Behav*. 2006;9(2):339–44.
- [30] Rey A. *L'Examen Clinique en Psychologie*. Paris: Press Universitaire de France; 1958.
- [31] Rey A. *L'examen psychologique dans les cas d'encephalopathie traumatique*. *Arch Psychol*. 1941;28:21.
- [32] Wechsler D. *Wechsler Memory Scale – 4th edition (WMS-IV) technical and interpretive manual*. San Antonio, TX: Pearson; 2009.
- [33] Brown FC, Roth RM, Saykin AJ, Beverly-Gibson G. A new measure of visual location learning and memory: development and psychometric properties for the Brown Location Test (BLT). *Clin Neuropsychol*. 2007;21:811–925.
- [34] Arnett PA, Rao SM, Grafman J, Bernardin L, Luchetta T, Binder JR, et al. Executive functions in multiple sclerosis: an analysis of temporal ordering, semantic encoding, and planning abilities. *Neuropsychology*. 1997;11(4):535–44.
- [35] Beck AT, Epstein N, Brown G, Steer RA. An inventory for measuring clinical anxiety: psychometric properties. *J Consult Clin Psychol*. 1988;56:893–7.
- [36] Beck AT, Steer RA, Brown GK. *Manual for the Beck Depression Inventory – II*. San Antonio, TX: The Psychological Corporation; 1996.
- [37] Meador KJ. Research use of the new Quality-of-Life in Epilepsy Inventory. *Epilepsia*. 1993;34(Suppl. 4):S34–8.
- [38] Cramer JA, Westbrook LE, Devinsky O, Perrine K, Glassman MB, Camfield C. Development of the Quality of Life in Epilepsy Inventory for adolescents: the QOLIE-AD-48. *Epilepsia*. 2005;46(8):1114–21.
- [39] Baron-Cohen S, Wheelwright S, Hill J, Raste Y, Plumb I. The "Reading the Mind in the Eyes" Test Revised Version: a study with normal adults, and adults with Asperger syndrome or high-functioning autism. *J Child Psychol Psychiatry Allied Discip*. 2001;42:241–51.
- [40] Wechsler D. *Wechsler Adult Intelligence Scale – fourth edition*. San Antonio, TX: Pearson; 2009.
- [41] Goossens L, Kukulja J, Onur OA, Fink GR, Maier W, Griez E, et al. Selective processing of social stimuli in the superficial amygdala. *Hum Brain Mapp*. 2009;30(10):3332–8.
- [42] Drane DL, Pedersen NP. Knowledge of language function and underlying neural networks gained from complex partial seizures and epilepsy surgery. *Brain Lang*. 2019;19:20–33.



- [43] Busch RM, Chapin JS, Haut JS, Dulay MF, Naugle RI, Najm I. Word-finding difficulties confound performance on verbal cognitive measures in adults with intractable left temporal lobe epilepsy. *Epilepsia*. 2013;54(3):37–40.
- [44] Hermann BP, Perrine K, Chelune GJ, Barr W, Loring DW, Strauss E, et al. Visual confrontation naming following left anterior temporal lobectomy: a comparison of surgical approaches. *Neuropsychology*. 1999;13(1):3–9.
- [45] Gleissner U, Sassen R, Schramm J, Elger CE, Helmstaedter C. Greater functional recovery after temporal lobe epilepsy surgery in children. *Epilepsia*. 2005;128(12):2822–9.
- [46] Takaya S, Mikuni N, Mitsueda T, Satow T, Taki J, Kinoshita M, et al. Improved cerebral function in mesial temporal lobe epilepsy after subtemporal amygdalohippocampectomy. *Brain*. 2009;132(1):185–94.
- [47] Ojemann LM, Ojemann GA, Dodrill CB, Crawford CA, Holmes MD, Dudley DL. Language disturbances as side effects of topiramate and zonisamide therapy. *Epilepsy Behav*. 2001;2:579–84.
- [48] Drane DL, Meador KJ, editors. *Cognitive toxicity of antiepileptic drugs*. Boston: Butterworth-Heinemann; 2002.
- [49] Grabowski T, Damasio H, Tranel D, Ponto LLB, Hichwa RD, Damasio AR. A role for left temporal pole in the retrieval of words for unique entries. *Hum Brain Mapp*. 2001;13:199–212.
- [50] Tranel D. The left temporal pole is important for retrieving words for unique concrete entities. *Aphasiology*. 2009;23:867–84.
- [51] Busch RM, Floden DP, Prayson B, Chapin JS, Kim KH, Ferguson L, et al. Estimating risk of word-finding problems in adults undergoing epilepsy surgery. *Neurology*. 2016;87:2363–9.
- [52] Busch RM, Hogue O, Kattan MW, Hamberger MJ, Drane DL, Hermann B, et al. Nomograms to predict naming decline after temporal lobe surgery in adults with epilepsy. *Neurology*. 2018;91:e2144–52.
- [53] Baxendale S. Long-term cognitive outcomes after epilepsy surgery in adults. In: Malmgren K, Baxendale S, editors. *Long-term outcomes of epilepsy surgery in adults and children*. Cham: Springer; 2015.
- [54] Baxendale S, Thompson PJ, Sander JW. Neuropsychological outcomes in epilepsy surgery patients with unilateral hippocampal sclerosis and good preoperative memory function. *Epilepsia*. 2013;54(9):131–4.
- [55] Rolls ET. Limbic systems for emotion and memory but no single limbic system. *Cortex*. 2015;62:119–57.
- [56] Olson IR, Plotzker A, Ezzyat Y. The enigmatic temporal pole: a review of findings on social and emotional processing. *Brain*. 2007;130:1718–31.
- [57] Wu C, Jermakowicz WJ, Chakravorti S, Cajigas I, Sharan AD, Jagid JR, et al. Effects of surgical targeting in laser interstitial thermal therapy for mesial temporal lobe epilepsy: a multicenter study of 234 patients. *Epilepsia*. 2019;60(6):1171–83.