

Pancreatic lymphoepithelial cyst with concurrent HIV infection: A case report and review of the literature

SAGE Open Medical Case Reports
Volume 10: 1–5
© The Author(s) 2022
Article reuse guidelines:
sagepub.com/journals-permissions
DOI: 10.1177/2050313X221131166
journals.sagepub.com/home/sco



Oluwayomi Oyedeji¹ , Shannon Rodgers¹, Allen Wrubel²,
Rupen Shah³ and Sanam Husain¹

Abstract

Pancreatic lymphoepithelial cysts are rare, benign, non-neoplastic unilocular or multilocular cystic lesions. These circumscribed pancreatic lesions are filled with keratinous material grossly and exhibit distinct microscopic features. Pancreatic lymphoepithelial cysts are like the more common lymphoepithelial cysts of the parotid glands, which have been associated with the diffuse infiltrative lymphocytosis syndrome often seen in patients with HIV infection. However, pancreatic lymphoepithelial cysts are rare and their association with HIV infection has not been established. The presence of secondary changes in non-neoplastic cysts such as goblet cell metaplasia that was present in our case is an important feature to be included in the differential diagnosis and not to be interpreted as a mucinous neoplasm, particularly on fine-needle aspiration specimen microscopic evaluation that would impact further management. Here we describe the diagnosis and treatment of lymphoepithelial cysts in a patient who was on highly active antiretroviral therapy for HIV infection and we provide a brief literature review. Defining the clinical characteristics of lymphoepithelial cysts in patients with HIV and determining accurate preoperative diagnostic procedures will be critical for establishing effective surgical and medical approaches to treating these cysts, which differ substantially from other more serious pancreatic cystic lesions.

Keywords

Pancreas, lymphoepithelial cyst, human immunodeficiency virus, keratinous debris, fine-needle aspiration, goblet cell metaplasia

Date received: 24 June 2022; accepted: 19 September 2022

Introduction

Pancreatic cystic lesion (PCL) comprises a broad group of lesions, both neoplastic and non-neoplastic, that are being increasingly detected by imaging studies. Most cystic pancreatic lesions are non-neoplastic and pseudocysts are the most commonly seen. Lymphoepithelial cysts (LEC) of the pancreas are rare, benign, non-neoplastic unilocular or multilocular circumscribed cystic lesions. They are lined with mature stratified squamous epithelium, surrounded by a dense band of mature lymphoid tissue with occasional prominent well-formed germinal centers, and filled with keratinous content.¹ Pancreatic LEC are morphologically similar to the LEC of the salivary gland that often occur in the parotid gland. These parotid LEC are strongly associated with a diffuse infiltrative lymphocytosis syndrome seen in patients with HIV infection.²

The first report of a patient with pancreatic LEC was described by Lühtrath and Schriefers in 1985.³ Pancreatic LEC constitute less than 0.5% of non-neoplastic lesions⁴ and are often difficult to differentiate from other pancreatic cystic neoplasms clinically, radiologically, and preoperatively. The etiopathogenesis of pancreatic LEC is not well understood

¹Department of Pathology and Laboratory Medicine, Henry Ford Hospital, Detroit, MI, USA

²Department of Diagnostic Radiology, Henry Ford Hospital, Detroit, MI, USA

³Division of Surgical Oncology, Department of Surgery, Henry Ford Hospital, Detroit, MI, USA

Corresponding Author:

Oluwayomi Oyedeji, Department of Pathology and Laboratory Medicine, Henry Ford Hospital, Detroit, MI 48202, USA.
Email: ooyedeji1@hfhs.org



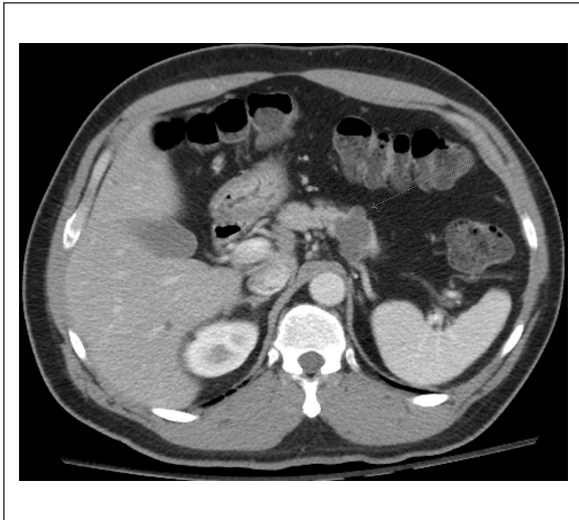


Figure 1. Contrast-enhanced abdomen and pelvis computed tomography scan (CT). Axial CT image—dotted arrow shows a septated and cystic lesion within the pancreatic body to the left of the midline.

and the association of pancreatic LEC with HIV infection is highly uncommon and has been regarded as mere a coincidental finding. Of approximately 100 previously reported cases of pancreatic LEC, only two included patients had concurrent HIV infection.⁵ Thus, the association of pancreatic LEC in patients with HIV infection has not been established because of limited historical reports and the non-specific features of some benign cyst that may mimic neoplastic lesions. These challenges could lead to delayed diagnosis and unnecessary medical interventions, and more information is needed to establish clear clinical procedures for accurately identifying and effectively treating pancreatic LEC in patients with HIV. Here, we report a case of pancreatic LEC within the setting of HIV infection and provide a brief literature review of cases reported within this clinical context.

Case report

A 53-year-old man who was receiving highly active antiretroviral therapy for HIV infection presented to the emergency department for recurrent rectal abscess. The patient had type 2 diabetes and did not have a history of acute or chronic pancreatitis. An abdominopelvic computed tomography scan revealed an incidental 2.8 cm cystic lobulated exophytic lesion without associated calcifications within the pancreatic body, which was suspected to be a neoplasm (Figure 1). Magnetic resonance imaging of the pancreatic lesion revealed a T2 hyperintense, T1 hypointense cystic mass with a few thin septations in the distal pancreatic body. There were no mural nodules or enhancement noted, and the mass had no obvious communication with the main pancreatic duct. The patient also had an elevated carbohydrate antigen 19-9 value (CA 19-9) of 59.1 U/mL (reference < 45.1 U/mL)

and an unremarkable pancreatic cyst fluid carcinoembryonic antigen (CEA) of 2.4 ng/mL. The patient underwent further workup, including endoscopic ultrasonography and a fine-needle aspiration (EUS-FNA) of the lesion. The fine-needle aspiration cytology showed bland epithelial cells with vacuolated intracytoplasmic mucin and scattered lymphocytes as well as benign squamous epithelium (Figure 2); therefore, the differential diagnosis included a mucinous cystic neoplasm, among others. Because of the working diagnosis of a mucinous cystic neoplasm as determined by the radiological and cytological evaluations, a distal pancreateosplenectomy was performed. Macroscopic examination of the surgical specimen revealed a 3.1 × 2.4 × 2.3 cm tan-yellow, well-circumscribed cystic mass filled with serous to caseous secretions. Microscopic examination of the specimen showed a cyst lined by mature stratified squamous epithelium with foci of goblet cell metaplasia, surrounded by dense lymphoid tissue (Figure 3). The cyst cavity was filled with keratinous debris and all pathological analyses were consistent with a benign pancreatic LEC.

Discussion

PCLs are common and recent technological advances in imaging modalities have increased our ability to detect them. As a result of improved imaging techniques developed over the last three decades, the clinical, radiological, and pathological features of many PCLs have been better characterized. Cystic pancreatic lesions are broadly categorized as non-neoplastic or neoplastic,⁶ and majority are non-neoplastic, with pseudocysts being the most seen non-neoplastic lesion. Since cystic pancreatic lesions are increasingly being detected by imaging techniques, we need defining clear, safe diagnostic procedures and exploring whether surgical or medical treatment approaches work best. EUS-FNA of pancreatic cysts with fluid characterization, including cytologic assessment as well as biochemical marker analysis (e.g. CEA, CA19-9 and amylase), do have diagnostic limitations. The diagnostic accuracy of CEA as a tumor marker is poor in assessing malignant pancreatic cysts with reported sensitivity and specificity of approximately 63%.⁷ The addition of DNA-based molecular testing of pancreatic cyst fluid using next-generation sequencing technique for detection of *KRAS*, *GNAS*, *RNF43*, *SMAD4*, and *TP53* mutations can further aid diagnostic accuracy preoperatively and risk stratification of PCL.⁸ Various meta-analysis studies have revealed overall high specificity and low sensitivity of EUS-FNA-based cytology in differentiating mucinous from non-mucinous pancreatic cysts,⁹ with a variable sensitivity of 35%–63% and specificity of 83%–99%.^{10–12} One of the recent innovations to improve diagnostic accuracy of PCL is the use of endoscopic ultrasonography-guided through-the-needle biopsy (EUS-TTNB). By inserting a micro-forceps device through a 19-gauge needle, this technique enhances tissue sampling of PCL and thus leads to a more definitive

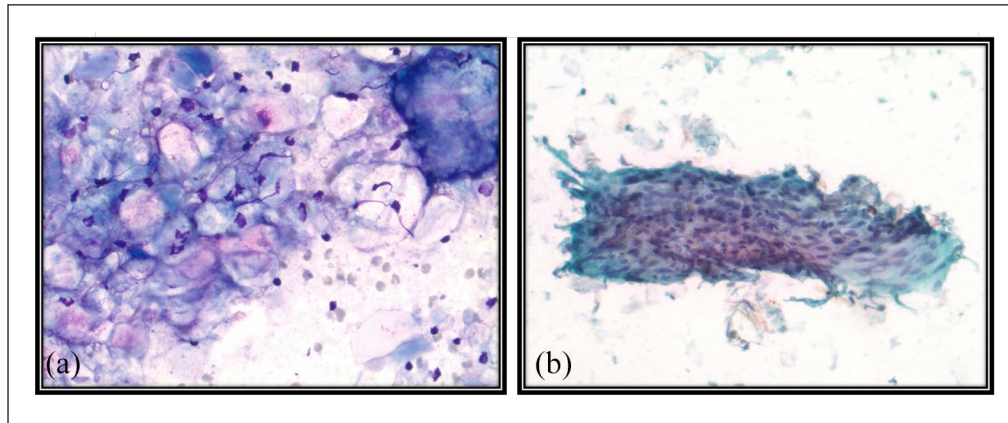


Figure 2. (a) Romanowsky stain $\times 200$ —bland epithelial cells with intracytoplasmic mucin and few scattered lymphocytes. (b) Papanicolaou stain $\times 100$ —benign squamous component.

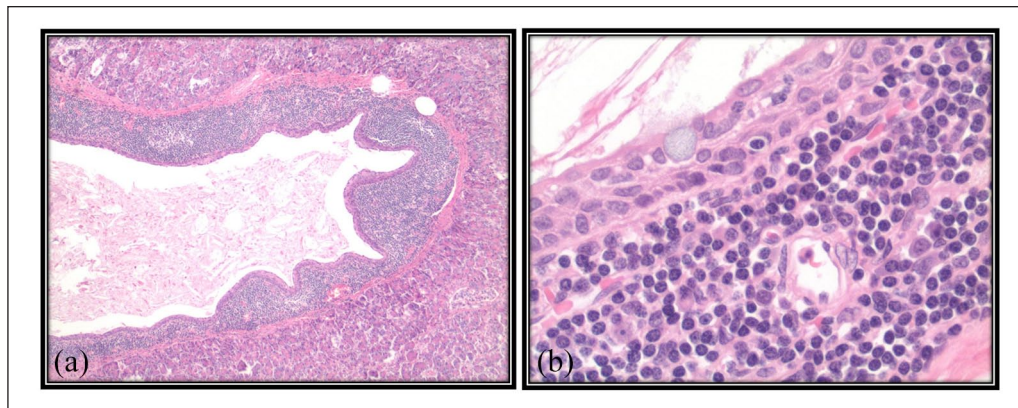


Figure 3. (a) Hematoxylin and eosin $\times 100$ —cyst wall lined by mature stratified squamous epithelium and a band of lymphocytes with foci of goblet cell metaplasia. (b) Hematoxylin and eosin $\times 400$ —focus of goblet cell metaplasia.

diagnosis and decrease in interobserver variability.^{13,14} A recent study showed that EUS-TTNB has a higher diagnostic yield in the preoperative assessment of PCL than the combination of EUS-FNA cytology and fluid CEA.¹⁵

Pancreatic neoplastic cysts can be subclassified into two categories: mucinous (intraductal papillary mucinous neoplasms, mucinous cystic neoplasms, and intraductal oncocytic papillary neoplasms) and non-mucinous (serous cystadenomas).^{6,16} Non-neoplastic pancreatic cysts are usually injury-related and/or inflammation-related, and these are seen in approximately 30%–40% of patients with chronic pancreatitis. Other non-neoplastic cysts include congenital cysts, LEC, and squamoid cysts of the pancreatic duct (SCOPD), among others. In general, mucinous pancreatic neoplasms have serious clinical implications, as they possess malignant potential representing the adenoma-adenocarcinoma sequence,¹⁶ whereas non-mucinous neoplastic cysts do not appear to harbor malignant potential. Also, in assessing PCL, the rare occurrence of degenerative or necrotic changes in non-mucinous solid malignant tumors such as cystic degeneration in ductal adenocarcinoma and neuroendocrine

tumors must be considered, since these are malignant, with variable degrees of aggressiveness.¹⁶ In addition, the presence of secondary changes in non-neoplastic cysts such as goblet cell metaplasia that was present in our case is an important feature to be included in the differential diagnosis and not to be interpreted as a mucinous neoplasm, particularly on fine-needle aspiration specimens that would impact further patient management. To our knowledge, this is the first case of pancreatic LEC that demonstrated such metaplastic features.

LEC have been described in various anatomic locations and within different human organs, including the parotid gland, thyroid, parathyroid, lung, thymus, and rarely in the pancreas.^{4,17,18} Pancreatic LEC are rare cystic lesions that have an undetermined pathogenesis and are predominant in men.^{3,4} A potential pitfall in the accurate diagnosis of benign pancreatic LEC is that the cyst fluid may harbor elevated levels of carbohydrate antigen 19-9, and rarely, elevated levels of CEA; however, cysts with these features have no malignant potential as shown in the previous case reports and literature review.¹⁸ Furthermore, a small biopsy sample

of the dense lymphoid stroma that contains limited tissue may falsely suggest the possibility of a lymphoproliferative disorder or as in our case, the rare finding of goblet cell metaplasia led to the diagnostic consideration of mucinous neoplasm on the EUS-FNA specimen.

Pancreatic LEC are rarer than parotid gland LEC, with less than 100 patient reports documented in the literature, including only two associated with an HIV infection.⁵ Exploration into a possible association of pancreatic LEC with HIV infection might be warranted since the parotid gland and the pancreas are similar in many ways: both being accessory organs of the human digestive system, and furthermore, they are both exocrine and endocrine organs with similar structure, physiologic function, and embryological development.^{19,20} In addition, the progenitor cells of the pancreas and parotid glands have similar roles in repair and regeneration.^{19–21} Bédât et al.⁵ emphasized the similarity and correlation between the pancreatic and the parotid gland LEC. However, the pathogenesis of pancreatic LEC remains largely unknown. Of the possible mechanisms proposed in the pathogenesis, one is that LEC may occur as a consequence of antigens or expression of mediators acting on the ductal epithelium, which has an affinity for lymphoid cells, resulting in massive lymphoid infiltration and growth induction from the factors that lymphoid cells mediate.⁴ Alternatively, development of a remnant of epithelium within the lymph nodes may occur, and this model was substantiated by Arai et al.²² in their identification of LEC precursors within peripancreatic lymph nodes.^{4,23} However, one factor arguing against this theory of pathogenesis is that LEC lack unique lymph node features, such as sinuses and a capsule.⁴ Finally, it has been suggested that pancreatic LEC may originate from displaced branchial cleft cysts fused with pancreatic tissues during embryogenesis.^{3,4,24}

Conclusion

Our patient's case and the other few reported cases suggest the possible association of benign pancreatic LEC with HIV infection, similar to what has been described for the parotid gland LEC. Our case also highlights that although rare, secondary changes, including goblet cell metaplasia, may occur in pancreatic LEC and therefore this entity should be included in the differential diagnosis of cystic lesions of the pancreas since the management can be non-surgical. Additional studies and follow-up are needed to establish potential association with HIV and goblet cell metaplasia in pancreatic LEC.

Author contributions

Oluwayomi Oyedeji was responsible for drafting the manuscript, proofreading, ensuring that the descriptions are accurate and agreed by all authors. Shannon Rodgers was responsible for assisting in drafting the manuscript, ensuring that the descriptions are accurate and agreed by all authors. Allen Wrubel was responsible for

providing CT and MRI scans finding and imaging report review. Rupen Shah contributed to the case report, discussion, and literature review of the manuscript and ensuring the accuracy and integrity of all aspects of research. Sanam Husain contributed to the case pathology report review, discussion and literature review of the manuscript, and responsibility for accuracy and integrity of all aspects of research.

Declaration of conflicting interests

The author(s) declared no potential conflicts of interest with respect to the research, authorship, and/or publication of this article.

Ethical approval

This is a case report and literature review. Ethics approval is not required in accordance with our institution's policies. Our institution does not require ethical approval for reporting individual cases or case series.

Funding

The author(s) received no financial support for the research, authorship, and/or publication of this article.

Informed consent

Written informed consent was obtained from the patient for his anonymized information to be published in this article.

ORCID iD

Oluwayomi Oyedeji  <https://orcid.org/0000-0001-7644-5338>

References

1. Hisaoka M, Haratake J, Horie A, et al. Lymphoepithelial cyst of the pancreas in a 65-year-old man. *Hum Pathol* 1991; 22(9): 924–926.
2. Sekikawa Y and Hongo I. HIV-associated benign lymphoepithelial cysts of the parotid glands confirmed by HIV-1 p24 antigen immunostaining. *BMJ Case Rep* 2017; 2017: bcr2017221869.
3. Lühtrath H and Schriefers KH. A pancreatic cyst with features of a so-called branchiogenic cyst. *Pathologe* 1985; 6(4): 217–219.
4. Adsay NV, Hasteh F, Cheng JD, et al. Lymphoepithelial cysts of the pancreas: a report of 12 cases and a review of the literature. *Mod Pathol* 2002; 15(5): 492–501.
5. Bédât B, Genevay M, Dumonceau JM, et al. Association between lymphoepithelial cysts of the pancreas and HIV infection. *Pancreatol* 2012; 12(1): 61–64.
6. Karoumpalis I and Christodoulou DK. Cystic lesions of the pancreas. *Ann Gastroenterol* 2016; 29: 155–161.
7. Ngamruengphong S, Bartel MJ and Raimondo M. Cyst carcinoembryonic antigen in differentiating pancreatic cysts: a meta-analysis. *Dig Liver Dis* 2013; 45: 920–926.
8. Theisen BK, Wald AI and Singhi AD. Molecular diagnostics in the evaluation of pancreatic cysts. *Surg Pathol Clin* 2016; 9(3): 441–456.
9. Thosani N, Thosani S, Qiao W, et al. Role of EUS-FNA-based cytology in the diagnosis of mucinous pancreatic cystic

- lesions: a systematic review and meta-analysis. *Dig Dis Sci* 2010; 55(10): 2756–2766.
10. Gillis A, Cipollone I, Cousins G, et al. Does EUS-FNA molecular analysis carry additional value when compared to cytology in the diagnosis of pancreatic cystic neoplasm? A systematic review. *HPB* 2015; 17(5): 377–386.
 11. Stigliano S, Covotta F and Di Matteo FM. A new micro-forceps for endoscopic ultrasound-guided through-the-needle biopsy in the diagnosis of pancreatic cystic lesions: single center experience. *JGH Open* 2021; 5(9): 1004–1008.
 12. Bhutani MS, Gupta V, Guha S, et al. Pancreatic cyst fluid analysis—a review. *J Gastrointest Liver Dis* 2011; 20(2): 175–180.
 13. Canakis A and Lee LS. State-of-the-art update of pancreatic cysts. *Dig Dis Sci* 2022; 67(5): 1573–1587.
 14. Larghi A, Manfrin E, Fabbri C, et al. Interobserver agreement among expert pathologists on through-the-needle micro-forceps biopsy samples for evaluation of pancreatic cystic lesions. *Gastrointest Endosc* 2019; 90(5): 784–792.
 15. Hashimoto R, Lee JG, Chang KJ, et al. Endoscopic ultrasound-through-the-needle biopsy in pancreatic cystic lesions: a large single center experience. *World J Gastrointest Endosc* 2019; 11: 531–540.
 16. Basturk O, Coban I and Adsay NV. Pancreatic cysts: pathologic classification, differential diagnosis, and clinical implications. *Arch Pathol Lab Med* 2009; 133(3): 423–438.
 17. Wu L, Cheng J, Maruyama S, et al. Lymphoepithelial cyst of the parotid gland: its possible histopathogenesis based on clinicopathologic analysis of 64 cases. *Hum Pathol* 2009; 40(5): 683–692.
 18. Rockacy M and Khalid A. Update on pancreatic cyst fluid analysis. *Ann Gastroenterol* 2013; 26(2): 122–127.
 19. Tiffon C. Defining parallels between the salivary glands and pancreas to better understand pancreatic carcinogenesis. *Biomedicines* 2020; 8: 178.
 20. Lee MG, Ohana E, Park HW, et al. Molecular mechanism of pancreatic and salivary gland fluid and HCO₃ secretion. *Physiol Rev* 2012; 92(1): 39–74.
 21. Gittes GK. Developmental biology of the pancreas: a comprehensive review. *Dev Biol* 2009; 326: 4–35.
 22. Arai T, Kino I, Nakamura S, et al. Epidermal inclusions in abdominal lymph nodes. *Acta Pathol Jpn* 1992; 42(2): 126–129.
 23. Sako S, Isozaki H, Hara H, et al. Cystic lymphoepithelial lesions of the pancreas and peripancreatic region: report of two cases. *Surg Today* 1999; 29(5): 467–471.
 24. Truong LD, Rangdaeng S, Jordan PH, et al. Lymphoepithelial cyst of the pancreas. *Am J Surg Pathol* 1987; 11: 899–903.