



Active postoperative acromegaly: sustained remission after discontinuation of somatostatin analogues

Cristina Alvarez-Escola and Jersy Cardenas-Salas

Department of Endocrinology and Nutrition, Hospital Universitario La Paz, Madrid, Spain

Correspondence
should be addressed
to C Alvarez-Escola
Email
escola.cristina@gmail.com

Summary

In patients with active acromegaly after pituitary surgery, somatostatin analogues are effective in controlling the disease and can even be curative in some cases. After treatment discontinuation, the likelihood of disease recurrence is high. However, a small subset of patients remains symptom-free after discontinuation, with normalized growth hormone (GH) and insulin-like growth factor (IGF1) levels. The characteristics of patients most likely to achieve sustained remission after treatment discontinuation are not well understood, although limited evidence suggests that sustained remission is more likely in patients with lower GH and IGF1 levels before treatment withdrawal, in those who respond well to low-dose treatment, in those without evidence of adenoma on an MRI scan and/or in patients who receive long-term treatment. In this report, we describe the case of a 56-year-old female patient treated with lanreotide Autogel for 11 years. Treatment was successfully discontinued, and the patient is currently disease-free on all relevant parameters (clinical, biochemical and tumour status). The successful outcome in this case adds to the small body of literature suggesting that some well-selected patients who receive long-term treatment with somatostatin analogues may achieve sustained remission.

Learning points:

- The probability of disease recurrence is high after discontinuation of treatment with somatostatin analogues.
- Current data indicate that remission after treatment discontinuation may be more likely in patients with low GH and IGF1 levels before treatment withdrawal, in those who respond well to low-dose treatment, in those without evidence of adenoma on MRI, and/or in patients receiving prolonged treatment.
- This case report suggests that prolonged treatment with somatostatin analogues can be curative in carefully selected patients.

Background

Acromegaly is a rare, severe systemic disease caused by a growth hormone (GH)-secreting pituitary adenoma, which leads to the excessive production of both GH and insulin-like growth factor 1 (IGF1). The mainstay of treatment is transsphenoidal neurosurgery, which achieves remission rate in up to 76% of noninvasive adenomas, but only 24% of invasive tumours (1). In patients who are ineligible for surgery or in those in which the surgery is unsuccessful, medical treatment

and/or radiotherapy are necessary to remove or shrink the tumour to normalize GH and IGF1 levels.

A variety of medications can be used to treat acromegaly, including Pegvisomant (a GH receptor blocker) and, more commonly, somatostatin analogues (2). Long-acting somatostatin analogues (octreotide or lanreotide) are the cornerstone of medical treatment for this disease, and these can play either a primary or adjunct role in treatment. These drugs are effective





in inducing biochemical remission and shrinking the tumour, thereby reducing the clinical influence of the disease (3). In rare cases, complete disappearance of the pituitary tumour has been reported (4, 5, 6, 7). Despite the well-documented effectiveness of somatostatin analogue therapy, discontinuation—when feasible—is desirable to eliminate the possible treatment-related adverse effects (cholelithiasis, blood glucose alterations, injection site pain, gastrointestinal cramps, among others) (3). Data on the effects of discontinuation in this patient population are limited; however, some reports suggest that the remission pattern in these patients may be similar to that observed after withdrawal of dopamine agonists in patients with prolactinomas (8). Most studies have found that the disease is likely to recur soon after discontinuation, although some studies have found that GH and IGF1 levels remain at safe levels in a small subset of patients even after treatment discontinuation (4, 9, 10, 11). Based on the limited data currently available (mostly case reports/series), it appears that remission after discontinuation of medical treatment may be more likely in patients with low GH and IGF1 levels before treatment withdrawal, in those who respond well to low-dose treatment, in patients without adenoma on magnetic resonance imaging (MRI) and/or in patients receiving prolonged treatment (3, 12, 13, 14). Nonetheless, the characteristics of patients likely to achieve sustained remission after treatment discontinuation are still not well understood.

The present report describes the case of a woman with active postoperative acromegaly who achieved sustained disease remission on all relevant parameters (clinical, biochemical and tumour status) after discontinuation of prolonged treatment with lanreotide Autogel.

Case presentation

In October 2000, a 56-year-old female was referred to the Endocrinology Department with suspicion of acromegaly. Relevant medical history included well-controlled hypertension, carpal tunnel syndrome treated surgically, hysterectomy and oophorectomy due to postmenopausal bleeding and uterine myoma and severe myopia. The patient did not report any headaches, hyperhidrosis or visual field defects; her only complaint was wrist pain. Remarkable findings on the physical examination included a large jaw, protruding brow, prominent cheekbones, enlarged lips, macroglossia and enlargement of the hands and feet. Her only treatments at that moment were Captopril 25 mg b.i.d. and oral calcium.

Investigation

Blood tests revealed abnormal random GH levels (56 ng/mL), and MRI indicated the presence of a right pituitary macroadenoma. Visual field testing revealed a diffuse generalized defect in the right eye and a minimal temporal defect in the left eye. The patient was diagnosed with acromegaly associated with a pituitary tumour and underwent transsphenoidal neurosurgery in February 2001. Pathological findings revealed an eosinophilic, sparsely-granulated (chromophobic) adenoma. IGF1 levels were assessed with the Immulite assay (Euro/DPC Ltd.; Gwynedd, Wales, UK). Postoperatively, both GH and IGF1 levels remained elevated (38.5 and 947 ng/mL respectively) vs the reference values (<8 and between 81 and 225 ng/mL respectively) for females in this age range. A subsequent MRI revealed the presence of an expansive intrasellar process with leftwards displacement of the pituitary stem and disease extension above the cavernous sinus indicative of invasion. Consequently, the patient was diagnosed with active postoperative acromegaly. The patient was not considered a candidate for pituitary radiotherapy.

Treatment

In September 2001, treatment with somatostatin analogues (slow-release (SR) lanreotide (30 mg)) was started (one injection every 14 days) to reduce symptomatology. However, due to insufficient disease control, the dosing frequency was increased in February 2002 to one injection every 10 days. Jointly, the Departments of Neurosurgery and Endocrinology decided to perform a second transsphenoidal neurosurgery (September, 2002). Pathological findings showed an eosinophilic, sparsely granulated adenoma, with a low Ki67 index. A postoperative MRI revealed tumour remnants mainly located in the right lobe, with invasion of the right cavernous sinus. After surgery, a 75 g oral glucose tolerance test (OGTT) was performed. The baseline GH was 8 ng/mL and GH nadir was 12 ng/dL. Based on these OGTT results, the patient was diagnosed with active postoperative acromegaly. In March 2003, treatment with subcutaneous injection lanreotide (Somatuline Autogel) was started (120 mg every 56 days). Doses were adjusted in accordance with changes in the GH and IGF-1 levels, which steadily decreased over time until both had normalized by January 2005 (random GH <1 ng/mL and normal IGF-1 levels) (see Table 1 for detailed measurements). The patient did not receive oestrogen replacement therapy during treatment.



Table 1 Details of GH and IGF1 measurements in relation to treatment with somatostatin analogue.

Date	GH (ng/mL)	IGF1 (ng/mL)	Normal range of IGF1 (ng/mL)	Treatment
01/02/2003	8	1113	81–225	Previous to treatment
01/09/2003	1.8	411	81–225	Lanreotide Autogel 120 mg/56 days
01/12/2003	1.3	316	81–225	Lanreotide Autogel 120 mg/56 days
01/03/2004	1.4	590	81–225	Lanreotide Autogel 120 mg/56 days
01/06/2004	1.2	258	81–225	Lanreotide Autogel 120 mg/42 days
01/01/2005	0.5	178	75–212	Lanreotide Autogel 120 mg/42 days
01/06/2005	0.5	145	75–212	Lanreotide Autogel 120 mg/42 days
01/03/2006	1.1	138	75–212	Lanreotide Autogel 120 mg/42 days
01/09/2006		90	75–212	Lanreotide Autogel 120 mg/42 days
01/03/2007		133	75–212	Lanreotide Autogel 120 mg/42 days
01/07/2007		142	75–212	Lanreotide Autogel 120 mg/42 days
08/02/2008	0.47	113	75–212	Lanreotide Autogel 120 mg/42 days
03/09/2008	0.73	112	75–212	Lanreotide Autogel 120 mg/56 days
04/03/2009	0.61	114	75–212	Lanreotide Autogel 120 mg/56 days
05/10/2010	2.89	98	69–200	Lanreotide Autogel 90 mg/56 days
30/06/2011	0.27	90	69–200	Lanreotide Autogel 90 mg/56 days
15/12/2011	0.45	101	69–200	Lanreotide Autogel 60 mg/56 days
27/06/2012	0.27	118	69–200	Lanreotide Autogel 60 mg/63 days
Lanreotide treatment: discontinued September 2012				
11/03/2013	1.16	146	69–200	No treatment
04/07/2013	0.67	131	69–200	No treatment
17/03/2014	1.07	129	69–200	No treatment
10/10/2014	0.59	102	69–200	No treatment
20/05/2015	0.66	118	64–188	No treatment
14/09/2015		151	64–188	No treatment
13/11/2015		130	64–188	No treatment
14/03/2016	0.72	146	64–188	No treatment

A pituitary MRI performed in June 2012 showed postsurgical changes, including only minimal remains of the gland, retraction of the optic chiasm (Figs 1 and 2) and no evidence of any remaining residual tumour.

Outcome and follow-up

In September 2012, lanreotide treatment was discontinued to assess the patient's disease status. Since discontinuation, the patient has not required any further medical treatment. Moreover, no evidence of disease recurrence has been observed, and the patient is considered cured (Table 1). Importantly, pituitary function has been conserved. An OGTT (75 g glucose) performed 9 months after treatment discontinuation (July 2013) showed a basal GH 0.67 ng/mL with a GH nadir of 0.54 ng/mL. In March 2014, a new OGTT was performed, with a baseline GH of 1.07 and a GH nadir of 0.55 ng/mL. A pituitary MRI performed 18 months after discontinuation of medical treatment (April 2014) showed changes in the floor of the sella turcica with minimal glandular remains, with the pituitary stalk retracted to the left. No alterations were observed at the level of the cavernous sinuses (Figs 3 and 4). At her most recent follow-up evaluation

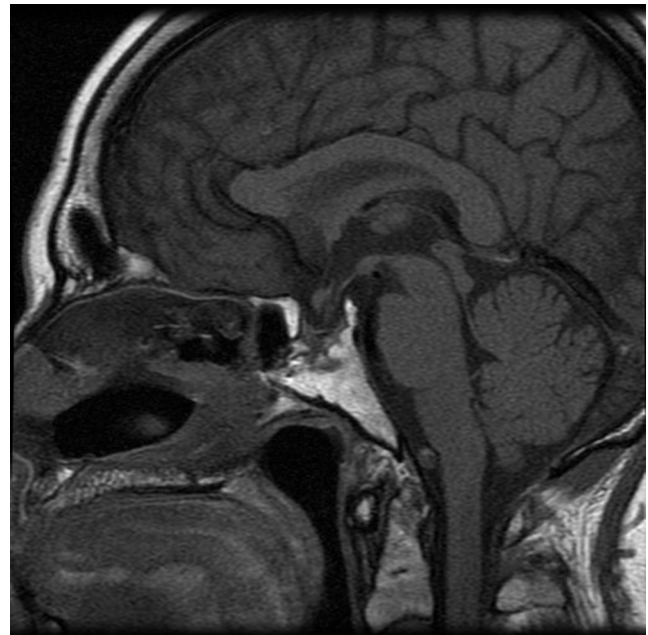


Figure 1
MRI, June 22, 2010. Sagittal cut.

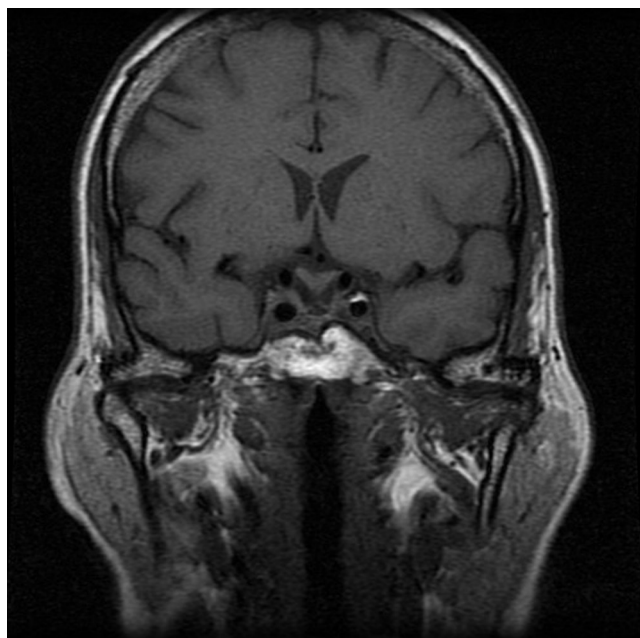


Figure 2
MRI, June 22, 2010. Coronal cut.

(March 2016), random GH levels and IGF1 values were 0.72 and 146 ng/mL respectively (normal values for IGF1 range from 64 to 188 ng/mL). The patient (with a previous diagnosis of diabetes mellitus and HbA1c levels of 6.5%) currently presents abnormal basal glucose levels, with the 120-min OGTT glucose value showing abnormal

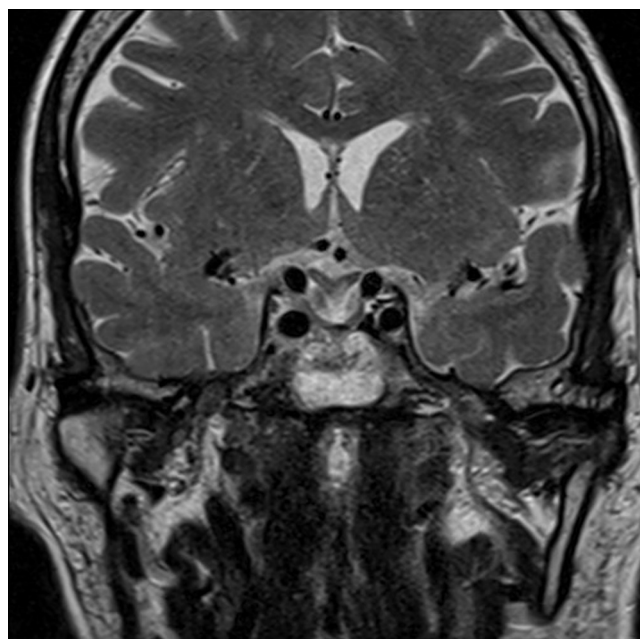


Figure 3
MRI, April 24, 2014. Coronal cut.

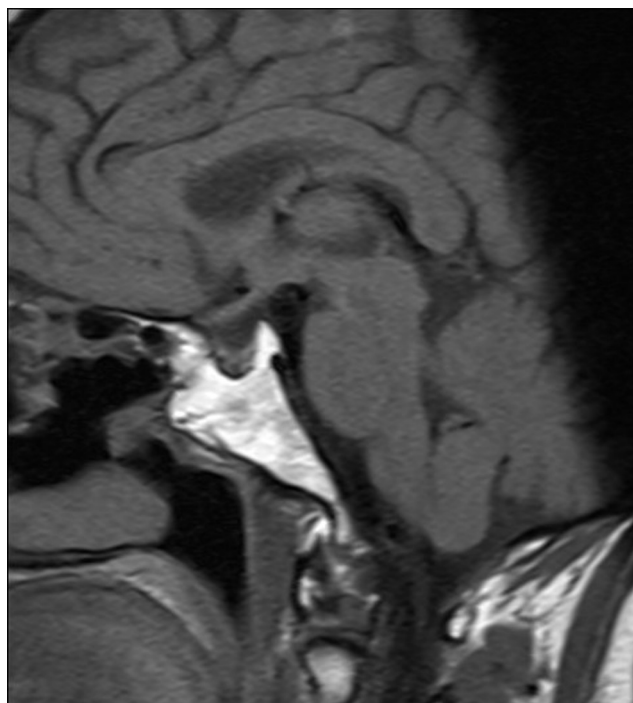


Figure 4
MRI, April 24, 2014. Sagittal cut.

tolerance to carbohydrates. HbA1c values after treatment discontinuation have ranged from 5.8% to 6.0%.

Discussion

In this report, we describe the case of a woman who presented active postoperative acromegaly (without radiotherapy) and whose disease has remained in complete remission (post-glucose GH nadir ≤ 1 ng/mL and IGF1 levels in the normal range) after discontinuation of long-term treatment (11 years) with lanreotide Autogel. This case demonstrates the potential of somatostatin analogues to achieve sustained disease remission in some well-selected acromegalic patients and suggests that the length of treatment may play an important role. This case is especially remarkable because the patient had a very high IGF-1 level before treatment and it is unusual for such patients to achieve remission with medical treatment. Treatment with somatostatin analogues has been proven to improve the clinical symptoms of acromegaly by normalizing GH and IGF1 levels and by decreasing the size of the tumour. In the PRIMARYS trial, a reduction of $>20\%$ tumour volume was achieved in 56% of treatment-naïve acromegalic patients after 6 months of treatment with lanreotide Autogel, and nearly one in four (23.9%) patients achieved a GH level ≤ 1.0 ng/mL



with IGF1 normalization (15). In most cases, recurrence is common after discontinuation of somatostatin analogue treatment (12, 14), although numerous cases of prolonged remission and even complete tumour disappearance and/or biochemical control of the acromegaly have been reported (5, 6, 7, 13, 16, 17).

Recurrence rates after discontinuation of prolonged somatostatin analogue treatment can vary highly, ranging from 15% to 84% (mean, 62%) (4, 9, 10, 11) during the first 3–4 months after treatment discontinuation. Similarly, the percentage of patients who achieve prolonged remission (>12 months) after treatment withdrawal is also highly variable (18.5–41.7%), although this variability can probably be explained by differences in inclusion criteria among these studies. Stewart *et al.* (10) assessed 12 acromegalic patients who received \geq one year of lanreotide SR followed by treatment discontinuation. Three months after treatment discontinuation, only 2 patients (both of whom had undergone radiotherapy more than 5 years previously) remained recurrence-free. Notably, no tumour regrowth was observed in any of the patients. Caron *et al.* (9) prospectively evaluated 51 patients with active acromegaly (31 with incomplete tumour resection and 18 treated with radiotherapy) who received 30 mg of lanreotide SR every 10–14 days. Eight weeks after treatment discontinuation, 84% of patients (43 cases) had relapsed. Of the 8 patients (16%) who remained in remission, four had undergone prior radiotherapy. Ronchi *et al.* (4) evaluated 27 acromegalic patients (12 in primary treatment and 15 with active postoperative acromegaly) treated with somatostatin analogues for \geq 12 months (median, 48 months) and with good disease control. Within 4 months of treatment discontinuation, 15 patients (56%) had relapsed. However, nine patients (33%) remained in remission at the 6-month assessment and five patients (19%) remained in remission for more than 12 months.

Numerous authors have attempted to identify the characteristics associated with sustained remission. In the study carried out by Ronchi *et al.* (4), IGF1 was the only variable significantly associated with sustained remission, although lower levels of IGF1 were associated with lower relapse rates at 6 months but not at 12 months. In addition, those same authors observed significant reductions in fasting glucose and HbA1C levels after discontinuation, as occurred in our case. Ramírez *et al.* (18), in a series of 12 acromegalic patients (five of whom remained in remission for >12 months after treatment discontinuation), found that patients who received prolonged treatment with somatostatin

analogues (>12 weeks) were more likely to achieve sustained remission. The absence of adenoma on MRI is also recognized as a predictor of sustained remission (8). In our patient, we believe that the pathophysiology of remission could be due to a direct effect of the drug via its antiproliferative (cytostatic and apoptotic), antiangiogenic and antisecretory mechanisms. We do not believe that tumour apoplexy played a role in our patient given the lack of compatible signs or symptoms.

The data from the studies described here, together with our case report, suggest that although sustained remission in acromegalic patients is rare, some patients do appear to respond to prolonged treatment with somatostatin analogues. However, this can only be verified after discontinuing treatment. In fact, a recent consensus statement on medical treatment of acromegaly recommends periodically suspending treatment to assess patient response (3). Periodic treatment discontinuation is necessary given that at least some patients will achieve disease remission and those that do will benefit from an improved quality of life through elimination of treatment-related adverse effects. In addition, treatment-related costs are also reduced by withdrawing unnecessary chronic treatment in that subset of patients.

Conclusions

The available evidence suggests that the possibility of achieving sustained disease remission after discontinuation of somatostatin analogues may be higher in patients (a) with lower GH and IGF-1 levels before treatment withdrawal, (b) who respond well to low-dose treatment, (c) without adenomas on MRI and/or (d) who receive long-term treatment with these medications. However, many important questions remain unresolved, including the optimal duration of medical therapy. Although the available evidence provides some guidance with regards to the characteristics of patients likely to achieve sustained disease remission after treatment discontinuation, more research is needed to better identify the best candidates for treatment withdrawal.

Declaration of interest

Dr C A-E declares receiving payments for lectures paid for by Ipsen Pharma S.A.

Funding

The translation and editing of this manuscript was funded by Ipsen Pharma S.A. who also paid for the article processing charges related to publication.



Patient consent

Written patient consent has been obtained from the patient.

Author contribution statement and acknowledgements

C A and J C collected data and performed the review of the literature and discussion. All authors have read and approved the final manuscript.

References

- 1 Buchfelder M & Feulner J 2016 Neurosurgical treatment of acromegaly. *Progress in Molecular Biology and Translational Science* **138** 115–139. (doi:10.1016/bs.pmbts.2015.11.002)
- 2 Lim DST & Fleseriu M 2016 The role of combination medical therapy in the treatment of acromegaly. *Pituitary*. In press. (doi:10.1007/s11102-016-0737-y)
- 3 Giustina A, Chanson P, Kleinberg D, Bronstein MD, Clemmons DR, Klibanski A, van der Lely AJ, Strasburger CJ, Lamberts SW, Ho KKY, et al. 2014 Expert consensus document: a consensus on the medical treatment of acromegaly. *Nature Reviews Endocrinology* **10** 243–248. (doi:10.1038/nrendo.2014.21)
- 4 Ronchi CL, Rizzo E, Lania AG, Pivonello R, Grottoli S, Colao A, Ghigo E, Spada A, Arosio M & Beck-Peccoz P 2007 Preliminary data on biochemical remission of acromegaly after somatostatin analogs withdrawal. *European Journal of Endocrinology* **158** 19–25. (doi:10.1530/EJE-07-0488)
- 5 Auriemma RS, Galdiero M, Grasso LFS, Vitale P, Cozzolino A, Lombardi G, Colao A & Pivonello R 2010 Complete disappearance of a GH-secreting pituitary macroadenoma in a patient with acromegaly: effect of treatment with lanreotide autogel and consequence of treatment withdrawal. *European Journal of Endocrinology* **162** 993–999. (doi:10.1530/EJE-09-0769)
- 6 Resmini E, Murialdo G, Giusti M, Boschetti M, Minuto F & Ferone D 2005 Pituitary tumor disappearance in a patient with newly diagnosed acromegaly primarily treated with octreotide LAR. *Journal of Endocrinological Investigation* **28** 166–169. (doi:10.1007/BF03345361)
- 7 Livadas S, Hadjidakis D, Argyropoulou M, Stamatelatos M, Kelekis D & Raptis S 2006 Disappearance of a growth hormone secreting macro adenoma during long-term somatostatin analogue administration and recurrence following somatostatin withdrawal. *Hormones* **5** 57–63. (doi:10.14310/horm.2002.11169)
- 8 Mehta GU & Lonser RR 2016 Management of hormone-secreting pituitary adenomas. *Neuro Oncology*. In press. (doi:10.1093/neuonc/nw130)
- 9 Caron P, Tabarin A, Cogne M, Chanson P & Jaquet P 2000 Variable growth hormone profiles following withdrawal of long-term 30 mg slow-release lanreotide treatment in acromegalic patients: clinical implications. *European Journal of Endocrinology* **142** 565–571. (doi:10.1530/eje.0.1420565)
- 10 Stewart PM, Stewart SE, Clark PMS & Sheppard MC 1999 Clinical and biochemical response following withdrawal of a long-acting, depot injection form of octreotide (Sandostatin-LAR). *Clinical Endocrinology* **50** 295–299. (doi:10.1046/j.1365-2265.1999.00660.x)
- 11 Lorcy Y, Dejager S & Chanson P 2000 Time course of GH and IGF-1 levels following withdrawal of long-acting octreotide in acromegaly. *Pituitary* **3** 193–197. (doi:10.1023/A:1011416112730)
- 12 Hatipoglu E, Bozcan S & Kadioglu P 2015 Discontinuation of somatostatin analogs while acromegaly is in long-term remission. *Pituitary* **18** 554–560. (doi:10.1007/s11102-014-0608-3)
- 13 Vilar L, Fleseriu M, Naves LA, Albuquerque JL, Gadelha PS, dos Santos Faria M, Nascimento GC, Montenegro RM & Montenegro RM 2014 Can we predict long-term remission after somatostatin analog withdrawal in patients with acromegaly? results from a multicenter prospective trial. *Endocrine* **46** 577–584.
- 14 Casagrande A, Bronstein MD, Jallad RS, Moraes AB, Elias PCL, Castro M, Czepielewski MA, Boschi A, Ribeiro-Oliveira A, Schweizer JROL, et al. 2016 Long-term remission of acromegaly after octreotide withdrawal is an uncommon and frequently unsustainable event. *Neuroendocrinology*. In press. (doi:10.1159/000446542)
- 15 Caron PJ, Bevan JS, Petersenn S, Flanagan D, Tabarin A, Prévost G, Maisonobe P & Clermont A 2014 Tumor shrinkage with lanreotide autogel 120 mg as primary therapy in acromegaly: results of a prospective multicenter clinical trial. *Journal of Clinical Endocrinology and Metabolism* **99** 1282–1290. (doi:10.1210/jc.2013-3318)
- 16 Avramidis A, Polyzos SA, Efstathiadou Z & Kita M 2008 Sustained clinical inactivity and stabilization of GH/IGF-1 levels in an acromegalic patient after discontinuation of somatostatin analogue treatment. *Endocrine Journal* **55** 351–357. (doi:10.1507/endocrj.K07E-055)
- 17 Ronchi CL, Rizzo E, Lania AG, Pivonello R, Grottoli S, Colao A, Ghigo E, Spada A, Arosio M & Beck-Peccoz P 2008 Preliminary data on biochemical remission of acromegaly after somatostatin analogs withdrawal. *European Journal of Endocrinology* **158** 19–25. (doi:10.1530/EJE-07-0488)
- 18 Ramírez C, Vargas G, González B, Grossman A, Rabago J, Sosa E, Espinosa-de-Los-Monteros AL & Mercado M 2012 Discontinuation of octreotide LAR after long term, successful treatment of patients with acromegaly: is it worth trying? *European Journal of Endocrinology* **166** 21–26. (doi:10.1530/EJE-11-0738)

Received in final form 26 September 2016

Accepted 10 October 2016