



Case Report

Humeral plate failure following trauma – A case report

M. Wilson*, E. Stirling

Department of Trauma & Orthopaedics, Wexham Park Hospital, Frimley Health NHS, United Kingdom of Great Britain and Northern Ireland

Introduction

Stress-risers are a location in an object where stress is concentrated. This term is used in orthopaedics to describe how a mechanical defect, for example an implanted prosthesis, can concentrate stress in an area. This most commonly occurs at the interface between the end of the plate and the bone and may lead to a peri-implant fracture [1]. Plates are designed to be uniformly stiff. This not only facilitates contouring to the bone, but also reduces stress concentrations. However, the potential problem of a peri-implant fracture following orthopaedic internal fixation still remains. Further surgical management, can be more complex due to scar formation, bony overgrowth, or extensive soft tissue injuries secondary to high impact trauma [2]. Some orthopaedic practitioners will advocate removal of fixation after bony union to reduce this risk, particularly in the skeletally immature.

We present a rare case of titanium plate failure, in a trauma setting.

Case presentation

A 20-year-old, left hand dominant, male groundsman was brought to our Emergency Department following a motor vehicle accident. The patient lost control of his vehicle after swerving to avoid an obstacle whilst driving at between 50 and 70 miles per hour on a local A-road. A seat belt was not used. His vehicle was rolled several times and was in a non-repairable condition following the accident. The patient suffered no head injury or loss of consciousness, and was able to self-extricate from the vehicle. The emergency services were contacted and the patient brought to our institution, a level 2 trauma unit, by ambulance. He was assessed by the trauma team on arrival, and found to be haemodynamically stable with no immediately life-threatening injury identified. He reported pain in his left upper limb with dorsal angulation of approximately 25 degrees visible (Fig. A). There was no neurovascular deficit to the limb. No other long bone injury was clinically evident. A CT trauma series was performed in view of the mechanism of injury and plain radiographs of his left humerus obtained (Fig. B). The CT imaging revealed no head, spinal, thoracic, abdominal or pelvic injury. Radiographs confirmed a periprosthetic fracture of his left humerus.

Almost eight years prior to this injury and before skeletal maturity, the patient had sustained a fracture to the left distal humerus, following a fall off a bicycle. Open reduction internal fixation was performed using a single interfragmentary compression screw and a nine-hole titanium Synthes plate (Fig. C). Post-operative recovery was uneventful, bony union was confirmed on follow-up imaging and the patient regained full function allowing discharge from follow up.

His radiographs demonstrated a short oblique fracture of his humeral diaphysis proximal to the previous site of fracture (Figs. B and C). Apex anterior angulation of 31.7 degrees was noted with the fracture sited between the two most proximal screws. The imaging suggested that all metalwork remained intact but the plate had undergone plastic deformation.

Following review of the presentation and imaging in the departmental trauma meeting the patient underwent surgical fixation two days after the injury. A posterior approach to the fracture was performed, all initial fixation except for the interfragmentary compression screw was removed and found to be intact. The fracture was reduced and fixation achieved with a Synthes Titanium 9-hole LC-DCP. Satisfactory fixation was achieved and the fracture well aligned on image intensifier (Fig. D). There were no *peri* or

* Corresponding author at: 26 Cathcart Road, London SW10 9NN, United Kingdom of Great Britain and Northern Ireland.
E-mail address: michael.wilson18@nhs.net (M. Wilson).

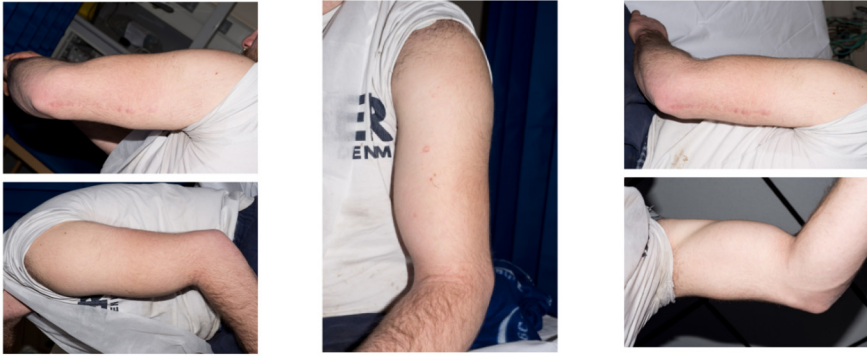

Fig. A. Medical Photography: injury to left upper limb.

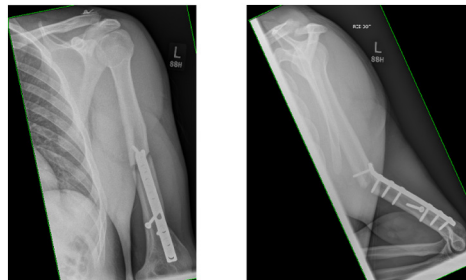


Fig. B. Radiographs: peri-prosthetic fracture of Left humerus shaft, plastic deformation of plate.

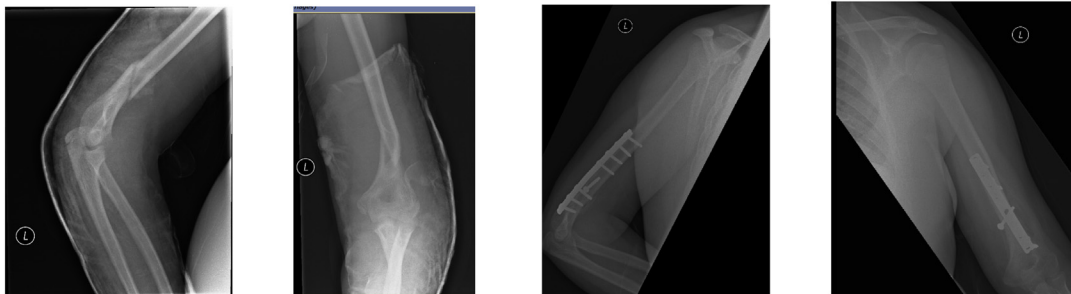


Fig. C. Radiographs: Humeral shaft fracture, pre and post open reduction and internal fixation.

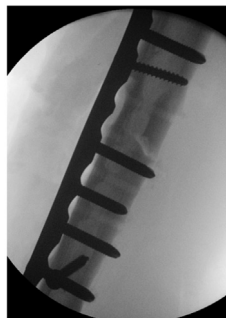

Fig. D. Radiograph: image intensifier - ORIF.

immediate post-operative complications and the patient was discharged home day one post-operatively.

Discussion

Over the last 20 years implant design for fracture fixation has moved towards the use of titanium, rather than stainless steel, as orthopaedic researchers have tried to improve fracture healing and reduce complication rates [3]. Titanium combines both excellent mechanical performance with corrosion resistance and high biocompatibility [4]. However, titanium has a brittle structure (lower modulus of elasticity) that has been implicated in an increased rate of implant fracture in some studies.

A number of cases of postoperative implant failures have been reported in the literature and various failure mechanisms have been described [5–8]. However, a plate undergoing plastic deformation traumatically, rather than a fracture occurring above the plate secondary to stress risers does not appear to be reported – warranting presentation of this unusual case.

In a large retrospective series reporting on postoperative implant failures, there was a failure rate of 13% in the titanium implant group compared to 1% of stainless steel implants [3]. Implant failure is most commonly a multi-factorial process related to the implant, the procedure and the patient, as well as mechanism of injury: e.g. road traffic accident.

Conclusion

This is an extremely unusual case of titanium implant failure in a young male secondary to a high speed road traffic accident. Given the mechanism of injury and original fixation, it would be expected that the fracture would occur proximal to the previous fixation with no deformity of the metalwork. Plastic deformation of the plate itself with an associated fracture is a previously undescribed, unusual injury.

Conflict of interests

The authors declare no potential conflict of interests.

References

- [1] A. Kawoosa, S.A. Dhar, M.F. Butt, G.N. Dar, M.R. Mir, The role of composite technique in managing peri implant re-fractures in a case with supracondylar fracture of the femur: a case report, *Cases J.* 2 (6) (2009) 8174.
- [2] A. Barquet, A. Fernandez, J. Luvizio, R. Masliah, A combine therapeutic protocol for aseptic nonunion of the humeral shaft: a report of 25 cases, *J. Trauma* 29 (1989) 95–98.
- [3] J.M. Banovetz, R. Sharp, R.A. Probe, et al., Titanium plate fixation: a review of implant failures, *J. Orthop. Trauma* 10 (1996) 389–394.
- [4] M.G. Manda, P.P. Psyllaki, D.N. Tsipas, et al., Observations on an in-vivo failure of a titanium dental implant/abutment screw system: a case report, *J Biomed Mater Res B Appl Biomater* 89 (2009) 264–273.
- [5] T.A. Chiodo, V.B. Ziccardi, M. Janal, et al., Failure strength of 2.0 locking versus 2.0 conventional syntheses mandibular plates: a laboratory model, *J. Oral Maxillofac. Surg.* 64 (2006) 1475–1479.
- [6] A. Katakura, T. Shibahara, H. Noma, et al., Material analysis of AO plate fracture cases, *J. Oral Maxillofac. Surg.* 62 (2004) 348–352.
- [7] M. Martola, C. Lindqvist, H. Hanninen, et al., Fracture of titanium plates used for mandibular reconstruction following ablative tumor surgery, *J Biomed Mater Res B Appl Biomater* 80 (2007) 345–352.
- [8] C. Sommer, R. Babst, M. Muller, et al., Locking compression plate loosening and plate breakage: a report of four cases, *J. Orthop. Trauma* 18 (2004) 571–577.