

Comparison of Six-strand and Four-strand Techniques on the Repair of Injured Deep Flexor Tendons of Zone II of the Hand: A Randomized Controlled Clinical Trial

Mohammad Bagher Heydari¹, Yusef Porhesam¹, Arian Karimi Rouzbahani^{2,3},
Golnaz Mahmoudvand³, Hormoz Mahmoudvand^{4*}

1. Department of Surgery, Faculty of Medicine, Kermanshah University of Medical Sciences, Kermanshah, Iran
2. Student Research Committee, Lorestan University of Medical Sciences, Khorramabad, Iran
3. USERN Office, Lorestan University of Medical Sciences, Khorramabad, Iran
4. Department of Surgery, Faculty of Medicine, Lorestan University of Medical Sciences, Khorramabad, Iran

ABSTRACT

Background: Hand zone II flexor tendon repair had been associated with many complications thereby it was previously called no man's land. Although there is some agreement on the primary repair of flexor tendons in this area, it is challenging due to certain complications.

We compared the six and four-strand techniques in the repair of flexor digitorum profundus (FDP) tendons of zone II.

Methods: This randomized controlled clinical trial was registered with the Iranian Registry of Clinical Trials (IRCT20130812014333N139). Fifty patients with damaged FDP in zone II of the hand who were referred to Taleghani Hospital, Kermanshah, Iran in 2020 were included and divided into two groups (n=25). In group 1, the damaged tendons were repaired using the four-strand technique and prolene suture while in group 2, the six-strand technique was used. Postoperatively, the patients were examined every week for the first three weeks. In the second and third weeks, sutures were removed. At the end of 3rd month, the outcomes of surgery were compared in the groups.

Results: Fifty patients (74% male) with 85 damaged fingers were investigated. Based on Buck-Gramcko criteria, the outcomes of surgery were excellent in 78%, good in 16%, fair in 4%, and bad in 2%. Complications after surgery were adhesion (8%) and 2 cases of rupture. There was no significant difference between 4 and 6-strand sutures regarding tendon adhesion and range of motion.

Conclusion: Both 4 and 6-strand sutures were associated with favorable outcomes in patients with damaged FDP in zone II of the hand.

KEYWORDS: Hand Injury; Tendon; Tendon Injury; Plastic Surgery Procedure

Please cite this paper as:

Heydari MB., Porhesam Y., Karimi Rouzbahani A., Mahmoudvand G., Mahmoudvand H. Comparison of Six-strand and Four-strand Techniques on the Repair of Injured Deep Flexor Tendons of Zone II of the Hand: A Randomized Controlled Clinical Trial. *World J Plast Surg.* 2023;12(2):34-40. doi: 10.52547/wjps.12.2.34

*Corresponding Author:

Hormoz Mahmoudvand, MD.

Department of Surgery, Lorestan University of Medical Sciences, Khorramabad, Iran.

Tel.: +989166616195

Email: dr.mahmoudvand@gmail.com

Received: 2023/04/10

Accepted: 2023/08/02

INTRODUCTION

The hand has been divided into five anatomic zones in order to diversify the therapeutic approach based on the site of flexor tendon injury^{1,2}. Among these 5 zones, zone II has particular importance as it contains both flexor digitorum superficialis and flexor digitorum profundus (FDP)³. Zone II is located between the middle part of the middle phalanx and the distal palmar fold. This zone has been historically named "no man's

land” by Bunnell⁴ as the surgical intervention in this area is associated with a high risk of complications including tendon rupture, because of an insufficient vascular supply, and adhesion formation due to the tightness of the tunnel that encompasses the two tendons⁵.

Recovering sufficient digital function following flexor tendon injury is among the most challenging topics in hand surgery. Although many techniques have been introduced to optimize the outcomes of surgical intervention, numerous controversies still remain in this field³. The strength of the repair is the most crucial factor that preserves the physiological function of tendons. More strands in sutures cause more strength but bulking the area like six-strand sutures. Four strand sutures maintain the balance between strength and bulking^{6,7}. Overall, the existing evidence suggests the use of a four-strand repair using braided nonabsorbable sutures⁸. To reduce the risk of tendon adhesion, the surgical procedure should be performed within the first 6 to 12 hours after damage. If the diagnosis is delayed

for only a week, the tendon repair may become impossible⁹.

Due to the inconsistency of the results of previous studies and the lack of agreement on the methods used to repair flexor tendons in zone II and also the importance of these tendons in hand function, we conducted the present study to evaluate the results of FDP repair with four-strand proline suture compared with the six-strand technique.

METHODS

Study design and participants

This randomized controlled clinical trial was conducted at Taleghani Hospital, Kermanshah, Iran in 2020. The inclusion criteria were damaged FDP in zone II of the hand. Patients who did not consent to participate in the study, had severe bone or finger damage, and crushed injury were excluded. Randomization was done with random allocation software. A total of 50 patients were included in the study and randomly divided into two groups of 25.

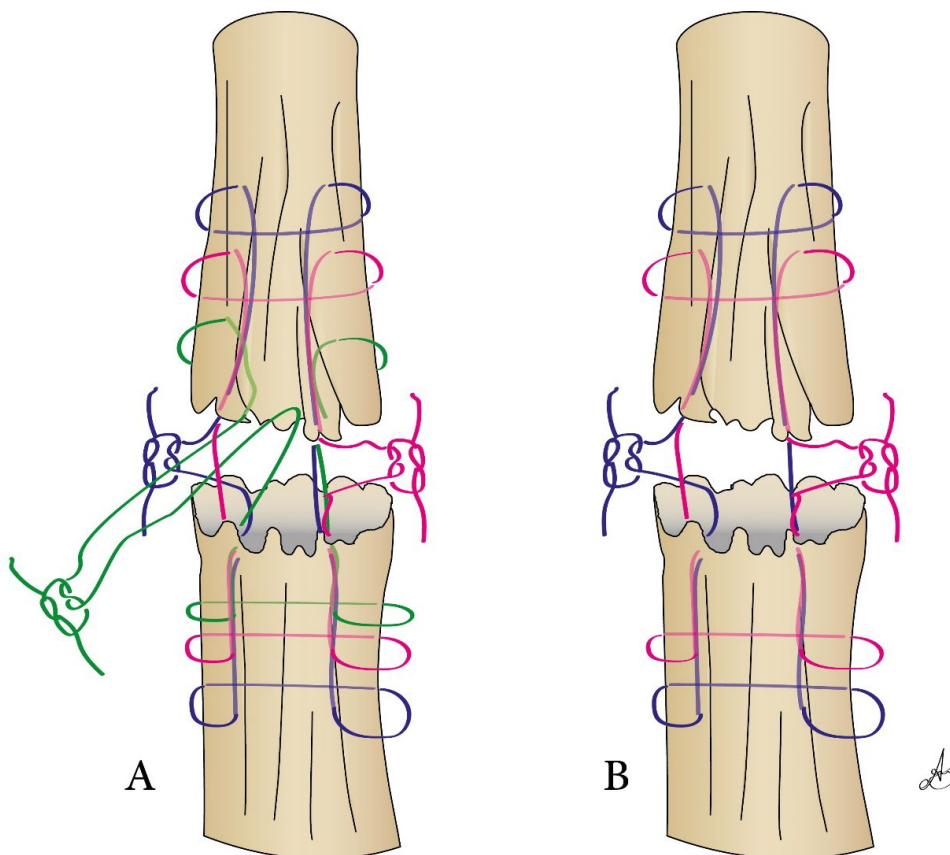


Figure 1: Surgical techniques used in this study: A= modified Kessler six-strand suture, B= modified Kessler four-strand suture

Data collection

Demographic information and subjective data related to the injury were collected by interviewing with patients. The severity of damage was assessed by exploring by the surgeon. Patients in the two groups underwent surgical procedure by the same surgeon. The procedure was performed under local anesthesia and within the first 24 hours after injury if possible. Various core suture techniques have been described in the literature. Modified Kessler is a popular technique chosen by 65% of surgeons¹⁰. In the present study, in group 1, the damaged tendons were repaired using modified Kessler four-strand suture while in group 2, modified Kessler six-strand suture were used. After surgery, the limb's immobility was achieved by casting in dorsal of the limb with 40 to 45-degree flexion of the wrist, 50 to 60-degree flexion of the metacarpophalangeal joint, and interdigital joints extension. Finger mobility started on the second day after surgery based on the modified Kleinert technique. All patients were examined every week for the first three weeks. The first examination of the fingers was performed by measuring the total range of motion of the JAMAR fingers and Total Active Motion¹¹ was compared recorded with the healthy finger of the opposite hand. In the second and third weeks, sutures were removed. After removing sutures and casting, patients were referred for physiotherapy. At the of the third month, all the limitations in the motility were eliminated. 3 months after the surgery, the

results were compared in two groups based on the Buck-Gramcko criteria¹². The healing process, digital range of motion, and complications such as adhesion and rupture of tendons were investigated. Primary repair (within the first 24 hours) and delayed repair (24 hours to 10 days) were also compared.

Statistical analysis

SPSS software version 16 (Chicago, IL, USA) was used for statistical analysis. Kolmogorov-Smirnov test was used to determine the normality of quantitative variables. For comparison of quantitative variables in two groups, independent *t*-test or Mann Whitney U test were used. The chi-square test or Fisher's exact test were used to analyze the qualitative variables. The statistical significance was set at 0.05 for all tests.

Ethical considerations

This randomized controlled clinical trial was registered with the Iranian Registry of Clinical Trials (IRCT20130812014333N139). The study was also approved by the Research Ethics Committee of Kermanshah University of Medical Sciences (IR. KUMS.REC.1398.942). Written informed consent was obtained from all of the participants in this study. The patients were assured that they could withdraw from the study at any time. The principles of ethics Medicine, The Helsinki Declaration, was observed.

Table 1: Assessment of FDP recovery according to Buck-Gramcko criteria

Variable	Degrees	Points
Flexion of interphalangeal joint	50-90	6
	30-49	4
	10-29	2
	<10	0
	0-10	3
Extension deficit	11-20	2
	21-30	1
	30<	0
	40<	6
Total active movement	30-39	4
	20-29	2
	<20	0
Evaluation	Excellent	14-15
	Good	11-13
	Fair	7-10
	Poor	0-6

RESULTS

Baseline characteristics of the participants

Overall, 25 patients (20 men and 5 women) were in the four-strand suture group and 25 patients (17 men and 8 women) were in the six-strand suture group. The mean age was 27.08 in four-strand group and 34.4 in six-strand suture group. In the four-strand group, the minimum age was 2 years and the maximum was 57 years, and in the six-strand suture group, it was 8 and 50 years, respectively. In the four-strand group, 18 were married and 7 were single while in the six-strand suture group, 11 were married and 14 married single (Table 2).

Surgical outcomes

Postoperatively, digital range of motion was excellent in 39 patients (78%), good in 8 patients (16%), fair in 2 patients (4%), and bad in 1 patient (2 %). In the four-strand group, there were 20

patients with excellent range of motion, 3 with good range of motion, 2 with fair range of motion, and 0 with bad range of motion. In the six-strand suture group, there were 19, 5, 0, and 1 patient/patients with excellent, good, fair, and bad range of motion, respectively. In each group one case had rupture. Two cases of adhesion occurred in in each group (8%). There was no significant difference between the two groups in terms of range of motion (0.317), and tendon adhesion. There was no significant difference between men and women in terms number of damaged digits, range of motion, and adhesion (Table 3). However, there was a remarkable association between gender and involved side.

There was no significant association between involved side and range of motion, or tendon adhesion (Table 4).

There was a significant association between number of damaged digits with range of motion and tendon adhesion (Table 5).

Table 2: Baseline characteristics of the participants in the two groups

Variable	Six-strand group Number (%)	Four-strand group Number (%)
Age group (years)	1-10	1 (4)
	11-20	5 (20)
	21-30	13 (52)
	31-40	2 (8)
	41-50	3 (12)
	51-60	1 (4)
Number of damaged digits	One	13 (52)
	Two	10 (40)
	Three	2 (8)
Involved side	Dominant	18 (72)
	Non-dominant	7 (28)

Table 3: Clinical characteristics of the study population by gender.

Variable	Gender		P-value
	Male	Female	
Digital range of motion	Excellent	29	.657
	Good	5	
	Fair	2	
	Poor	1	
Tendon adhesion	Yes	2	.253
	No	35	
Number of damaged digits	One	13	.265
	Two	19	
	Three	5	
Involved side	Dominant	21	.01
	Non-dominant	16	

DISCUSSION

Superficial position of flexor tendons, vessels, and nerves of the hand and forearm dispose them to rupture and damage. Despite the development of novel techniques, repairing the zone II flexor tendons is still a challenging field in hand surgery due to the high risk of rupture and adhesion¹³.

Demographic characteristics

The number of damaged digits was 1.7 in males and 1.4 in females. In other studies, this ranged from 1.2 to 2^{14,15}. Similar to our findings, Güntürk et al. observed no difference between men and women in terms of surgical outcomes¹⁶. In this study, the prevalence of injury was higher in the age group of 21-30, which is consistent with a previous study, where an average age of 28.9 was reported¹⁶. Behdaneh et al., in contrast to the present study, showed that excellent and good results were more in non-dominant hands¹⁴.

Functional outcomes

In the present study, the application of four-strand and six-strand suture techniques was associated with good or excellent postoperative results in 94% of the cases with damaged FDP in zone II of the hand. Previous studies have shown different surgical outcomes. Zhou et al. reported a 83%

chance of excellent and good healing after surgery of ruptured tendons¹⁷. In a study performed by Moriya et al., a good or excellent outcome was observed in 82% of the cases¹⁸. Another study also demonstrated 87% of good and excellent range of motion achievement after surgery¹⁹. These results are mainly consistent with the outcomes of our study, however, some discrepancy is noted in results of different studies that could be because of non-referral to physiotherapist, early removing of cast, and damage to the nerve and vessels. Some patients are scared of secondary rupture due to physiotherapy and avoid referring because of pain and hardness of joint while physiotherapy is recommended^{20,21}.

Surgical complications

In this study, the risk of complications was similar in both groups (12%). We observed a 4% risk of rupture which is lower than the 5.4% risk reported by Moriya et al.¹⁸. Venting the pulley has been suggested as the major strategy in reducing the risk of rupture¹⁹. Four strand and six-strand sutures were not different in the present study regarding digital motions and adhesion. Previous studies noted that 4 strand suture was associated with higher strength and lower risk of rupture, as well as reduced need for a second surgery^{11,22}.

Table 4: Surgical outcomes of the study population by involved side.

Variable		Involved side		P-value
		Dominant	Non-dominant	
Digital range of motion	Excellent	25	14	.778
	Good	6	2	
	Fair	1	1	
	Poor	1	0	
Tendon adhesion	Yes	3	1	.692
	No	30	16	

Table 5: Surgical outcomes of the study population by number of damaged digits.

Variable		Number of damaged digits			P-value
		One	Two	Three	
Digital range of motion	Excellent	20	17	2	.03
	Good	0	6	2	
	Fair	0	1	1	
	Poor	0	1	0	
Tendon adhesion	Yes	0	2	2	.01
	No	20	23	3	

Postoperative care

Tendon repair happens in three-stage of inflammation, fibroblasts proliferation, and remodeling. Tendon strength increases 21 days after repair and inserted stresses, and movement is so important in the reorganization of collagen²³. These facts prove the importance of early movements in strength increase and adhesion reduction after surgery. So, after surgery, rehabilitation is necessary for achieving social and occupational activities. Immobility for a period, and then physiotherapy is suitable for this purpose^{24, 25}. In the present study, limb immobilization was performed after surgery by placing a plaster splint on the dorsal surface of the limb. The modified Kleinert method trained and performed starting movements from the second day after surgery. In this study, immobility after surgery casting on the dorsal surface was done. Moreover, on the second day after surgery, the movement by the modified Kleinert method was started.

The results of flexor tendon repair procedures are strongly influenced by a wide range of factors, including the patient's age and motivation, preoperative condition, surgical technique, and postoperative management²⁶. Tendon repair, when accompanied by full observance of technical principles such as minimal damage to the tendon sheath during dissection to find the two ends of tendons, tendon sheath repair after tendon repair, avoiding lumps at the repair site, and maintaining proper rotation of tendons power, leads to excellent results²⁷. Overall, multi-stranded repair is undoubtedly stronger, but regarding the time of surgery and tissue damage, which may have biological consequences for tendon healing. It is also essential to maintain friction between the tendon and the sheath. As the extra suture fibers are repaired, the repair volume must be increased to elevate the resistance to further shear of the tendon. After each repair, a slight increase in friction resistance is observed. However, there is no significant difference between the techniques, which may lead to controversies on the selection of repair techniques²⁸⁻³⁰. The limitation of this study was the relatively short length of follow-up. A long-term follow-up might affect the results of the surgical techniques evaluated in this study.

CONCLUSION

Despite significant advances in hand zone II flexor tendon surgical repair, adhesion between the

tendon and its sheath is still problematic. This study compared the results of four-strand suture and six-strand suture in patients with damaged FDP in zone II of the hand. Overall, surgical intervention showed favorable outcomes in patients and no significant difference was found between the two techniques in terms of range of motion and tendon adhesion. Zone II flexor tendon rehabilitation protocols are evolving toward the use of early active movement, and the search for stronger repair techniques continues.

ACKNOWLEDGMENTS

Not applicable.

FUNDING

This study was supported by Kermanshah University of Medical Sciences.

CONFLICT OF INTEREST

The authors declare that there is no conflict of interests.

REFERENCES

1. Lee YJ, Ryoo HJ, Shim H-S. Prevention of postoperative adhesions after flexor tendon repair with acellular dermal matrix in Zones III, IV, and V of the hand: A randomized controlled (CONSORT-compliant) trial. *Medicine* 2022;**101**(3).
2. Klifto CS, Bookman J, Paksima N. Postsurgical rehabilitation of flexor tendon injuries. *J Hand Surg Am* 2019;**44**(8):680-6.
3. Venkatramani H, Varadharajan V, Bhardwaj P, Vallurupalli A, Sabapathy SR. Flexor tendon injuries. *J Clin Orthop Trauma* 2019;**10**(5):853-61.
4. Bunnell S. Repair of tendons in the fingers and description of two new instruments. *Surg Gynecol Obstet* 1918;**26**:103-10.
5. Fulchignoni C, Bonetti MA, Rovere G, Ziranu A, Maccauro G, Pataia E. Wide awake surgery for flexor tendon primary repair: A literature review. *Orthop Rev (Pavia)* 2020 Jun 29;**12**(Suppl 1):8668.
6. Ishak A, Rajangam A, Khajuria A. The evidence-base for the management of flexor tendon injuries of the hand: Review. *Ann Med Surg (Lond)* 2019 Dec;**48**:1-6.
7. Lutsky KF, Giang EL, Matzon JL. Flexor tendon injury, repair and rehabilitation. *Orthop Clin North Am* 2015;**46**(1):67-76.
8. Gibson PD, Sobol GL, Ahmed IH. Zone II Flexor Tendon Repairs in the United States: Trends in

- Current Management. *J Hand Surg Am* 2017 2017/02/01/;42(2):e99-e108.
9. Hess GP, Cappiello WL, Poole RM, Hunter SC. Prevention and treatment of overuse tendon injuries. *Sports Med* 1989 Dec;8(6):371-84.
 10. Unsal SS, Yildirim T, Armangil M. Comparison of surgical trends in zone 2 flexor tendon repair between Turkish and international surgeons. *Acta Orthop Traumatol Turc* 2019 2019/11/01/;53(6):474-7.
 11. Osada D, Fujita S, Tamai K, Yamaguchi T, Iwamoto A, Saotome K. Flexor tendon repair in zone II with 6-strand techniques and early active mobilization. *J Hand Surg Am* 2006 Jul-Aug;31(6):987-92.
 12. Buck-Gramcko D, Dietrich F, Gogge S. Evaluation criteria in follow-up studies of flexor tendon therapy. *Handchirurgie* 1976;8(2):65-9.
 13. Çetin A, Dinçer F, Keçik A, Cetin M. Rehabilitation of flexor tendon injuries by use of a combined regimen of modified Kleinert and modified Duran techniques. *Am J Phys Med Rehabil* 2001;80(10):721-8.
 14. Behdaneh R, Boozari-Poorboeini B, Ansari-Poor M. The investigation of the repair of acute trauma to flexor tendons of Zone II. *Zahedan Journal of Research in Medical Sciences* 2005;7(3).
 15. Tang JB, Xu Y, Chen F. Impact of flexor digitorum superficialis on gliding function of the flexor digitorum profundus according to regions in zone II. *J Hand Surg Am* 2003 Sep;28(5):838-44.
 16. Güntürk ÖB, Kayalar M, Kaplan İ, Uludağ A, Özaksar K, Keleşoğlu B. Results of 4-strand modified Kessler core suture and epitendinous interlocking suture followed by modified Kleinert protocol for flexor tendon repairs in Zone 2. *Acta Orthop Traumatol Turc* 2018 2018/09/01/;52(5):382-6.
 17. Stefanich RJ, Putnam MD, Peimer CA, Sherwin FS. Flexor tendon lacerations in zone V. *J Hand Surg Am* 1992 Mar;17(2):284-91.
 18. Moriya K, Yoshizu T, Maki Y, Tsubokawa N, Narisawa H, Endo N. Clinical outcomes of early active mobilization following flexor tendon repair using the six-strand technique: short- and long-term evaluations. *J Hand Surg Eur Vol* 2014 2015/03/01/;40(3):250-8.
 19. Pan ZJ, Qin J, Zhou X, Chen J. Robust thumb flexor tendon repairs with a six-strand M-Tang method, pulley venting, and early active motion. *J Hand Surg Eur Vol* 2017 2017/11/01/;42(9):909-14.
 20. Quadlbauer S, Pezzeri C, Jurkowitsch J, Reb P, Beer T, Leixnering M. Early Passive Movement in flexor tendon injuries of the hand. *Arch Orthop Trauma Surg* 2016;136(2):285-93.
 21. Svingen J, Rosengren J, Turesson C, Arner M. A smartphone application to facilitate adherence to home-based exercise after flexor tendon repair: A randomised controlled trial. *Clin Rehabil* 2021;35(2):266-75.
 22. Dy CJ, Hernandez-Soria A, Ma Y, Roberts TR, Daluiski A. Complications after flexor tendon repair: a systematic review and meta-analysis. *J Hand Surg Am* 2012 Mar;37(3):543-51.e1.
 23. Vaysman M, Alben M, Todd M, Ruotolo C. Pharmacologic Enhancement of Rotator Cuff Repair: A Narrative Review. *Orthop Rev (Pavia)* 2022;14(3):37782.
 24. Khor WS, Langer MF, Wong R, Zhou R, Peck F, Wong JK. Improving outcomes in tendon repair: a critical look at the evidence for flexor tendon repair and rehabilitation. *Plast Reconstr Surg* 2016;138(6):1045e-58e.
 25. Edsfeldt S, Eklund M, Wiig M. Prognostic factors for digital range of motion after intrasynovial flexor tendon injury and repair: long-term follow-up on 273 patients treated with active extension-passive flexion with rubber bands. *J Hand Ther* 2019;32(3):328-33.
 26. Moriya K, Maki Y, Tsubokawa N. Effect of age on the outcome of reconstruction for flexor tendon rupture following distal radial fracture. *J Hand Surg Eur Vol* 2021;46(5):549-52.
 27. Rigo I, Røkkum M. Predictors of outcome after primary flexor tendon repair in zone 1, 2 and 3. *J Hand Surg Eur Vol* 2016;41(8):793-801.
 28. Thurman RT, Trumble TE, Hanel DP, Tencer AF, Kiser PK. Two-, four-, and six-strand zone II flexor tendon repairs: an in situ biomechanical comparison using a cadaver model. *J Hand Surg Am* 1998 Mar;23(2):261-5.
 29. Gil JA, Skjong C, Katarincic JA, Got C. Flexor tendon repair with looped suture: 1 versus 2 knots. *J Hand Surg Am* 2016;41(3):422-6.
 30. Torres Fuentes CE, Carvajal Flechas FS, Hernández JA, et al. Helical 6-strand cruciate tenorrhaphy: description of a new technique and biomechanical comparative analysis with 2 standard techniques. *HAND* 2022;17(1):98-105.