

The first report of two cases of cystic echinococcosis in the lung by *Echinococcus ortleppi* infection, in Vietnam

Nguyen Van De¹
Duyet Le Van²

¹Department of Parasitology, Hanoi Medical University of Vietnam,

²Clinical Laboratories, National Hospital of Tropical Diseases, Hanoi, Vietnam

Abstract: In 2013, two cases of infection by *Echinococcus* that caused cystic echinococcosis in the lungs were reported. In the first case, there was a cyst of 6 × 7 cm in diameter, and in the second case, there were four cysts of 5 × 6 cm, 4 × 4 cm, 3.5 × 3 cm and 2.5 × 2 cm in diameter, respectively. In both cases, *Echinococcus* larvae were collected from the cysts. The larvae were identified as *Echinococcus ortleppi* by morphology and a molecular method (using reduced nicotinamide adenine dinucleotide hydrogenase [NADH] with 99%–100% homology compared with *E. ortleppi* in GenBank). This is the first time that this species has been found in humans in Vietnam.

Keywords: *E. ortleppi*, hydatid, Vietnam

Introduction

Human echinococcosis is a zoonotic infection caused by larval forms (metacestodes) of tapeworms of the genus *Echinococcus*. The adult stage develops in the small intestine of canids, and the larval stage develops in the viscera of a variety of mammalian species, including humans.¹ At present, nine valid species of the genus *Echinococcus* have been identified in the world, including *E. granulosus* sensu stricto (G1 [sheep strain], G2 [Tasmanian sheep strain], G3 [buffalo strain]), *E. equinus* (G4), *E. ortleppi* (G5), *E. canadensis* (G6–G10), *E. multilocularis*, *E. vogeli*, *E. oligarthrus*, *E. felidis*, and *E. shiquicus*.^{2–5} Two of these species are of special medical importance. These are *E. granulosus* and *E. multilocularis*, causing cystic echinococcosis and alveolar echinococcosis in humans, respectively.⁶ The first report of *E. ortleppi* (genotype G5) was in Italy.⁷ The adult worm is 3–6 mm in length, including three to four proglottids, and is a common parasite in the intestine of the canine family. Humans are considered aberrant intermediate hosts that acquire the infection through accidental ingestion of parasite eggs that may develop into the larval stage of the parasite (metacestode) in suitable internal organs, mainly the liver and lungs. Growing cysts may also damage surrounding tissues and blood vessels. Any associated clinical problems will be dependent on the number of cysts, their size, location, and rate of growth. The organs most frequently affected are the liver and the lungs in approximately 65% and 25% of cases, respectively.⁸ The kidneys, spleen, brain, heart, skeletal system, and musculature tissues can also be affected.⁶ In Italy, the chest X-rays and lung images in 24/28 (85.7%) patients found a total of 149 cysts, mostly with hepatic localization (96%).⁹ The lifespan of hydatid cysts of *E. granulosus* can be as long as 16 years in horses¹⁰ and 53 years in humans.¹³

Correspondence: Nguyen Van De
Department of Parasitology, Hanoi Medical University of Vietnam, No. 1 Ton That Tung Street, Hanoi 100000–150000, Vietnam
Tel +84 9 1237 7281
Email ngvdeyh@gmail.com

Reports of echinococcosis in humans have been reviewed by Alvarez Rojas et al,¹² in livestock by Cardona and Carmena,¹³ and in domestic dogs and wild carnivores by Carmena and Cardona.^{14,15}

Echinococcosis is distributed almost worldwide and is especially common in such areas as Australia, Tasmania, New Zealand, Southern and Northern Africa, and South America.⁶ In Asia, echinococcosis has been reported in Japan, China, Korea, Mongolia, Thailand, Indonesia, Bangladesh, and India,¹⁶ but not in Vietnam.

In 2013, two patients were detected with cystic echinococcosis at the National Hospital of Tuberculosis and Lung Diseases in Hanoi, Vietnam. The main clinical and para-clinical symptoms of the patients were described. In the first patient, samples were collected during surgery for removal of the cyst from the lung, and in the second patient, samples were collected by extracting fluids from the cyst in the lung. *Echinococcus* antigen in an enzyme-linked immunosorbent assay (ELISA) kit was used for detection of *Echinococcus*-specific antibodies with cutoff OD <0.3. The ELISA test and morphological identification of species were carried out in the Department of Parasitology, Hanoi Medical University, and the molecular methods were performed in the Molecular Diagnostic Laboratory of the National Hospital of Tropical Diseases. The two patients were followed-up for 2 years after their treatments. These

patients are the first reported cases of echinococcosis in Vietnam. Both patients provided written consent to have their data and images published.

Case report

Description of the first case

The first patient was a 42-year old male residing in the Thach Dong commune, Thach Thanh District, Thanh Hoa Province, in the mountainous region of northern Vietnam. He is a farmer and had never left the country. He felt chest pains on his right side in January 2013, and this symptom increased for 2 months; at the end of February 2013, he visited the Provincial Hospital and then the National Hospital of Lung Diseases (Hanoi, Vietnam). The main clinical symptom was pain in the right chest, absence of fever, and no cough or other symptoms. Paraclinical symptoms were a big nodular shadow circle form of equal density in the right lobe of the lungs, detected by chest X-ray examination, of 6 × 7 cm size (Figure 1). The leukocyte count was 9,600,000, including neutrophils 57.4%, lymphocytes 20.6%, eosinophils 12.8%, monocytes 8.3%, and basophils 0.9%; positive serodiagnosis was obtained by ELISA test with *Echinococcus* antigen. This patient was treated by surgery combined with use of albendazole 800 mg/day for 30 days (three dosages), and he was free of symptoms during the follow-up period of 3 months.

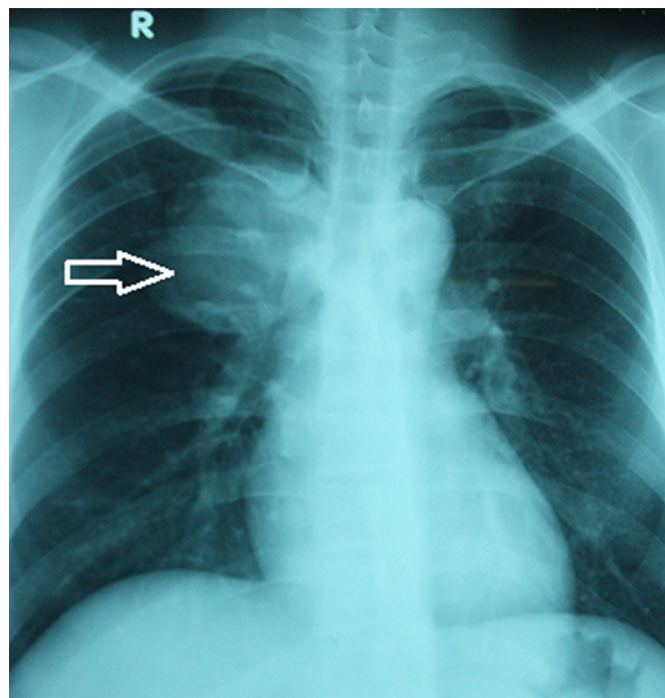


Figure 1 A hydatid cyst (6 × 7 cm in diameter, arrow) in the lung of the first patient, detected by X-ray.

Description of the second case

The second patient was a 48-year old female residing in Phu Yen town of the Phu Yen District, Son La Province, also in the mountainous north region of Vietnam. She is a medical technician and had also never left the country. She felt chest pains, along with cough and bloody sputum in June 2013; these symptoms increased for 2 months, and in the middle of August 2013, she visited the Provincial Hospital and then the National Hospital of Lung Diseases (Hanoi, Vietnam). The main clinical symptoms were pain in the chest, dyspnea, and cough with blood, in addition to absence of fever. Paraclinical symptoms were four big nodular shadow circles formed of equal density in both lobes of the lungs, detected by chest X-ray examination, with sizes of 5×6 cm, 4×4 cm, 3.5×3 cm, and 2.5×2 cm (Figure 2). The leukocyte count was 8,520,000, including neutrophils 72.0%, lymphocytes 12.9%, eosinophils 8.3%, monocytes 6.7%, and basophils 0.1%; positive serodiagnosis was obtained by ELISA test with

Echinococcus antigen. A microscopic examination of the fluid, extracted from the biggest cyst using a disposable syringe, was performed. The results showed the presence of a large number of *Echinococcus* larvae. Surgery was not done on this patient because the cysts were found in both lungs. However, she was treated with albendazole 800 mg/day for 30 days (six dosages). She was free of chest pain during the follow-up period of 3 months and free of cough after 12 months; however, the cysts had decreased in size (the remaining two cysts only: 3.5×2 cm and 2.5×1.5 cm in the lungs).

Description of the parasite

In the cysts (cystic echinococcosis) of both patients were many protoscoleces, each of which had many hooks (Figure 3).

The protoscolex is a spherical body of approximately 0.15×0.14 mm in diameter, in which an invaginated scolex with 30 hooks and four suckers is contained, and each hook is 22 μ m in diameter length (Figure 3).

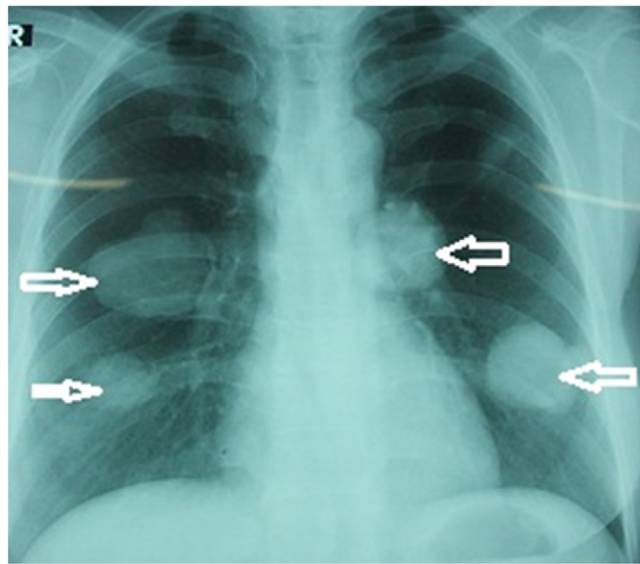


Figure 2 The hydatid cysts (four cysts: 5×6 cm, 4×4 cm, 3.5×3 cm, and 2.5×2 cm in diameter, arrows) in the lungs of the second patient, detected by X-ray.

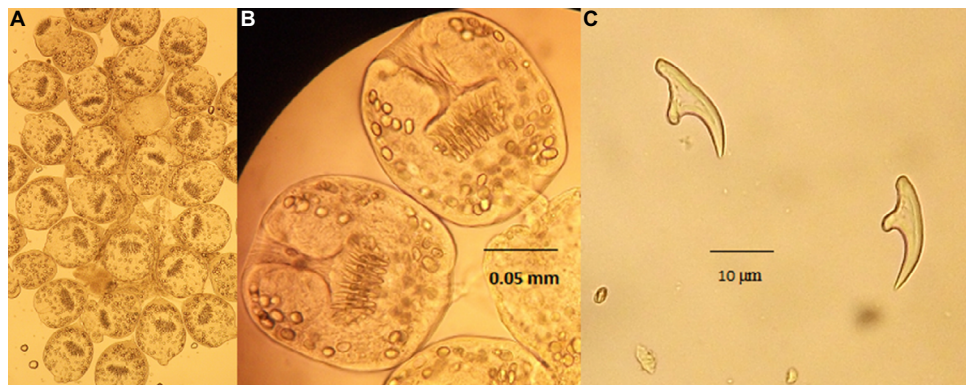


Figure 3 The protoscoleces and the hooklets of Vietnamese *Echinococcus*.

Notes: (A) The larvae observed by microscopy (10 \times); (B) the larvae observed at 40 \times ; (C) the hooks of the larvae observed at 90 \times .

Table 1 Sequencing of NADH dehydrogenase I gene of different *Echinococcus* spp. from GenBank compared with *E. ortleppi** in Vietnam

Notation	Origin	Host	Length	Species	GenBank number	Authors
Eorvn1	Vietnam	Human	438 bp	<i>E. ortleppi</i> *	–	This study
Eorvn2	Vietnam	Human	438 bp	<i>E. ortleppi</i> *	–	This study
Eor1	Sudan	Camel	438 bp	<i>E. ortleppi</i>	JN637177.1	Ahmed et al ²²
Eor2	Unknown	Cattle	438 bp	<i>E. ortleppi</i>	AB235846.1	Nakao et al ²³
Eor3	The Netherlands	Cattle	438 bp	<i>E. ortleppi</i>	DQ402037.1	Lavikainen et al ²⁴
Eor4	The Netherlands	Cattle	438 bp	<i>E. ortleppi</i>	AJ237636.1	Bowles et al ²⁵
Eeq5	Namibia	Zebra	420 bp	<i>E. equinus</i>	AJ508085.1	Obwaller et al ²⁶
Eca6	Finland	Reindeer	438 bp	<i>E. canadensis</i>	AF525297.1	Lavikainen et al ²⁶
Eca7	Sudan	Camel	438 bp	<i>E. canadensis</i>	JN637176.1	Ahmed et al ²²
Egr8	Iran	Camel	438 bp	<i>E. granulosus</i>	HM749618.1	Rostami et al, unpublished data, 2010
Egr9	Iran	Camel	438 bp	<i>E. granulosus</i>	HM749617.1	Rostami et al, unpublished data, 2010
Egr10	Iran	Human	438 bp	<i>E. granulosus</i>	HM563037.1	Fasihi et al, unpublished data, 2010
Egr11	Poland	Human	438 bp	<i>E. granulosus</i>	JX266822.1	Dybicz et al ²⁷
Egr12	Poland	Human	438 bp	<i>E. granulosus</i>	JX266818.1	Dybicz et al ²⁷

Notes: *Result after this study. Eorvn1 and Eorvn2 are Vietnamese *Echinococcus* spp. (collected from Patient 1 and Patient 2); Eor1 is Sudanese *E. ortleppi* (GenBank number: JN637177.1), Eor2 is from an unknown country (GenBank number: AB235846.1), Eor3 and Eor4 are *E. ortleppi* from the Netherlands (GenBank numbers: DQ402037.1 and AJ237636.1); Eeq5 is *E. equinus* from Namibia (GenBank number: AJ508085.1); Eca6 and Eca7 are *E. canadensis* from Finland and Sudan (GenBank numbers: AF525297.1 and JN637176.1), Egr8, Egr9, and Egr10 are Iranian *E. granulosus* specimens (GenBank numbers: HM749618.1, HM749617.1, and HM563037.1), and Egr11 and Egr12 are *E. granulosus* specimens from Poland (GenBank numbers: JX266822.1 and JX266818.1).

Abbreviations: bp, base pairs; NADH, reduced nicotinamide adenine dinucleotide.

Table 2 Percentage of identity of nucleotides of NADH dehydrogenase I gene sequences of Vietnamese *Echinococcus ortleppi* and other *Echinococcus* spp. in GenBank

	Eorvn1	Eorvn2	Eor1	Eor2	Eor3	Eor4	Eeq5	Eca6	Eca7	Egr8	Egr9	Egr10	Egr11	Egr12
Eorvn1		99	99	99	99	99	96	94	94	94	94	93	93	93
Eorvn2	99		99	99	100	99	96	93	93	93	93	93	93	93
Eor1	99	99		100	100	99	96	93	93	93	93	93	93	93
Eor2	99	100	100		100	99	96	93	93	93	93	93	93	93
Eor3	99	100	100	100		99	96	93	93	93	93	93	93	93
Eor4	99	99	99	99	99		96	93	93	93	93	93	93	93
Eeq5	96	96	96	96	96	96		93	97	97	97	97	97	97
Eca6	94	93	93	93	93	93	97		97	97	100	99	99	99
Eca7	94	93	93	93	93	93	97	100		100	100	99	99	99
Egr8	94	93	93	93	93	93	97	100	100		100	99	99	99
Egr9	94	93	93	93	93	93	97	100	100	99		99	99	99
Egr10	93	93	93	93	93	93	97	99	99	99	99		99	100
Egr11	93	93	93	93	93	93	97	99	99	99	99	100		100
Egr12	93	93	93	93	93	93	97	99	99	99	99	100	100	

Notes: Eorvn1 and Eorvn2 are Vietnamese *Echinococcus* spp. (collected from Patient 1 and Patient 2); Eor1 is Sudanese *E. ortleppi* (GenBank number: JN637177.1), Eor2 is from an unknown country (GenBank number: AB235846.1), Eor3 and Eor4 are *E. ortleppi* from the Netherlands (GenBank numbers: DQ402037.1 and AJ237636.1); Eeq5 is *E. equinus* from Namibia (GenBank number: AJ508085.1); Eca6 and Eca7 are *E. canadensis* from Finland and Sudan (GenBank numbers: AF525297.1 and JN637176.1), Egr8, Egr9, and Egr10 are Iranian *E. granulosus* specimens (GenBank numbers: HM749618.1, HM749617.1, and HM563037.1), and Egr11 and Egr12 are *E. granulosus* specimens from Poland (GenBank numbers: JX266822.1 and JX266818.1).

Abbreviation: NADH, reduced nicotinamide adenine dinucleotide.

These protoscoleces were analyzed by a molecular method using the gene of NADH hydrogenase. The result identified them as *E. ortleppi* with 99–100% homology compared with *E. ortleppi* in GenBank, but only homology with *E. granulosus* was 93–94% (Tables 1 and 2). The phylogenetic tree of *E. ortleppi* Vietnam and other strains derived from part of the NADH dehydrogenase nucleotide sequence and the COX1 gene, determined by neighbor-joining (NJ) method

using MEGA5.1,⁶ showed that the strain of Vietnamese *E. ortleppi* belongs to the same group as strains of *E. ortleppi* in GenBank (Figures 4 and 5).

Discussion

The two cases of echinococcosis in Vietnam were clearly diagnosed because larvae were detected in the cysts from both patients. X-ray diagnosis clearly showed one cyst of 6 × 7 cm

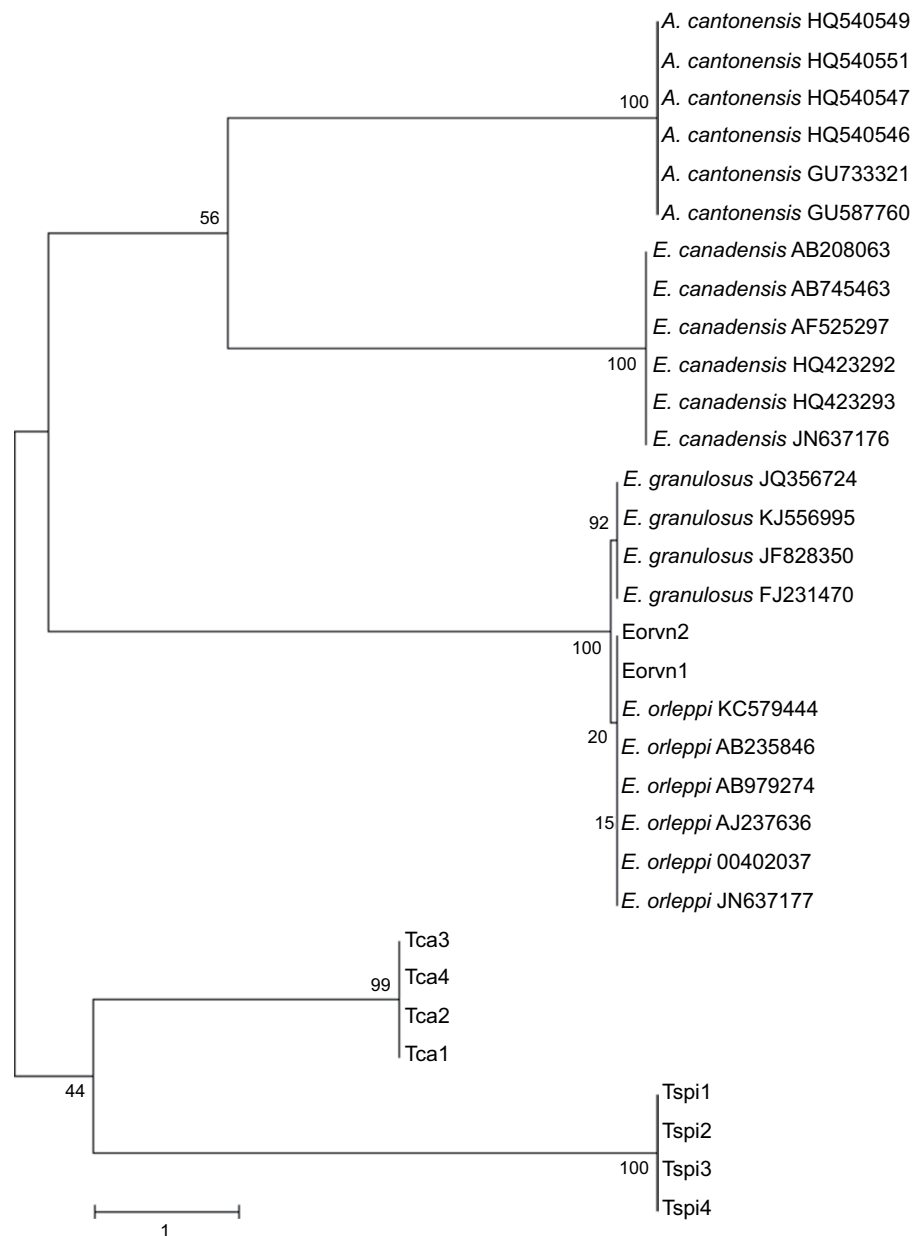


Figure 4 Phylogenetic tree of *Echinococcus ortleppi* Vietnam and other strains derived from part of NADH dehydrogenase nucleotide sequence estimated by neighbor-joining (NJ) method using MEGA5.1.

Notes: Eorvn1, Eorvn2 = Vietnamese *Echinococcus*; Tspi1, Tspi2, Tspi3, Tspi4 = Chinese *Trichinella spiralis* (GenBank numbers: GU339148.1, GU339147.1, GU339146.1, and GU339145.1, respectively). Tca1, Tca2, Tca3, and Tca4 are *Toxocara canis* species (GenBank numbers: JF837170.1, JF837169.1, JN617989.1, and FJ418788.1, respectively). *E. ortleppi* are from Argentina (GenBank number: KC579444.1), Japan (GenBank numbers: AB235846.1 and AB979274.1), the Netherlands (GenBank numbers: AJ237636.1 and DQ402037.1), and Sudan (GenBank number: JN637177.1). *E. granulosus* samples are from France (GenBank number: JQ356724.1), China (GenBank number: KJ556995.1), Brazil (GenBank number: JF828350.1), and Estonia (GenBank number: FJ231470.1). *Echinococcus canadensis* is from Kazakhstan (GenBank number: AB208063.1), Finland (GenBank numbers: AB745463.1 and AF525297.1), Canada (GenBank numbers: HQ423292.1 and HQ423293.1), and Sudan (GenBank number: JN637176.1). *Angiostrongylus cantonensis* is from China (GenBank numbers: HQ540551.1, HQ540547.1, and HQ540546, respectively), Brazil (GenBank number: GU733321.1), and the USA (GenBank number: GU587760.1).

Abbreviation: NADH, reduced nicotinamide adenine dinucleotide.

in the first patient and four cysts with 2×3 cm, 3.5×4 cm, 5×6.5 cm, and 6×6.5 cm in the second patient. In Vietnam, in 2009, De and Khue reported a case, in which a 3×3.5 cm cyst in the lung was suspected as echinococcosis and which yielded a positive ELISA test with *Echinococcus* antigen.¹⁸ However, no larvae were collected from the cyst. In recent years, some suspected cases of water cysts in the liver were diagnosed as

echinococcosis by ultrasonography, but again no larvae or hooks were collected in the fluid from the cysts. In 1967, Le-Van-Hoa and Vu-Ngoc-Tan¹⁹ reported on dogs that were infected with *E. granulosus* in southern Vietnam and that served as definitive hosts, which could transmit the disease to humans.

Echinococcus ortleppi is a cattle strain (genotype G5) of *E. granulosus* occurring in Europe,^{4,28} which is infective

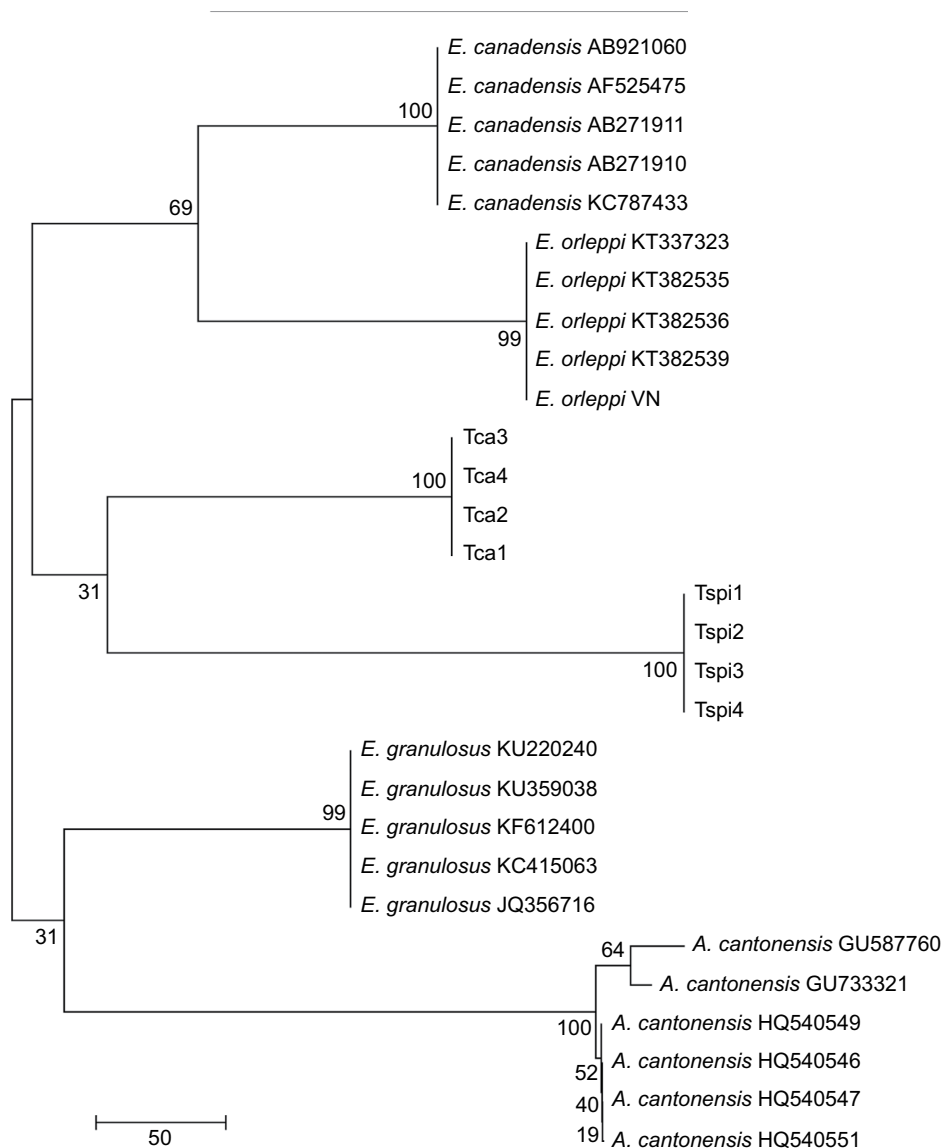


Figure 5 Phylogenetic tree of *Echinococcus orteppi* Vietnam and other strains derived from part of cytochrome C oxidase subunit I nucleotide sequence, estimated by neighbor-joining (NJ) method using MEGA5.1.

Notes: *E. orteppi* VN = Vietnamese *Echinococcus*; Tspi1, Tspi2, Tspi3, and Tspi4 = Chinese *Trichinella spiralis* (GenBank numbers: GU339148.1, GU339147.1, GU339146.1, and GU339145.1, respectively). Tca1, Tca2, Tca3, and Tca4 are *Toxocara canis* species (GenBank numbers: JF837170.1, JF837169.1, JN617989.1, and FJ418788.1, respectively). *E. orteppi* samples are from Brazil (GenBank numbers: KT337323.1, KT382536.1, KT382535.1, and KT382539.1, respectively). *Echinococcus canadensis* is from Egypt (GenBank number: AB921060.1), Finland (GenBank number: AF525475.1), Sudan (GenBank numbers: AB271911.1 and AB271910.1), and Brazil (GenBank number: KC787433.1). *E. granulosus* samples are from Iran (GenBank numbers: KU220240.1, KU359038.1, and KF612400.1), India (GenBank number: KC415063.1), and France (GenBank number: JQ356716.1). *Angiostrongylus cantonensis* samples are from China (GenBank numbers: HQ540551.1, HQ540547.1, and HQ540546, respectively), Brazil (GenBank number: GU733321.1), and the USA (GenBank number: GU587760.1).

to humans. Genotype G5 of *E. orteppi* was detected for the first time in Italy in 2008 by Casulli et al,⁷ and cystic echinococcosis caused by its larval stage was found to be endemic in southern Brazil by Balbinotti et al in 2012.³ In 2011 and 2012, liver infections caused by *E. orteppi* tapeworms were diagnosed in two humans in France, and in 2012, a nationwide slaughterhouse survey identified *E. orteppi* infections in cattle.²⁰ Echinococcosis in livestock caused by *E. orteppi* was described in Kenya, Sudan, India, Italy, Argentina, and Brazil.^{13,14} More recent studies have reported the presence of this *Echinococcus* spp. in Ethiopia,³⁰ Egypt,³¹ and France.⁷

Conclusion

In 2013, two cases of infection by *E. orteppi* that caused cystic echinococcosis in the lungs were reported in Vietnam. This was the first time that this species was detected in humans in Vietnam.

Acknowledgments

This research was funded by the Vietnam National Foundation for Science and Technology Development (NAFOSTED) under grant number 106-YS.05-2014.08, in collaboration with the National Hospital of Tuberculosis and Lung Diseases, Hanoi, Vietnam.

Disclosure

The authors report no conflicts of interest in this work.

References

- De NV, Khue PV. *Zoonotic Parasites*. Scientific Book. Vietnam: Education Published House; 2009:116–117.
- De NV, Le TH. *Taeniasis/Cysticercosis and Molecular Amplification*. Scientific Book Medical Published House; 2010:163–165.
- Balbinotti H, Santos GB, Badaraco J, et al. Echinococcus ortleppi (G5) and echinococcus granulosus sensu stricto (G1) loads in cattle from Southern Brazil. *Vet Parasitol*. 2012;188(3–4):255–260.
- Nakao M, Lavikainen A, Yanagida T, Ito A. Phylogenetic systematics of the genus Echinococcus (Cestoda: Taeniidae). *Int J Parasitol*. 2013;43(12–13):1017–1029.
- Saarma U, Jõgisalu I, Moks E, et al. A novel phylogeny for the genus Echinococcus, based on nuclear data, challenges relationships based on mitochondrial evidence. *Parasitology*. 2009;136(3):317–328.
- Tamura K, Nei M, Kumar S. Prospects for inferring very large phylogenies by using the neighbor-joining method. *Proc Natl Acad Sci USA*. 2004;101(30):11030–11035.
- Miyazaki I. Helminthic zoonoses. *International Medical Foundation of Japan*. Tokyo; 1991:247–258.
- Casulli A, Manfredi MT, La Rosa G, Cerbo AR, Genchi C, Pozio E. Echinococcus ortleppi and E. granulosus G1, G2 and G3 genotypes in Italian bovines. *Vet Parasitol*. 2008;155(1–2):168–172.
- de la Rue ML, Takano K, Brochado JF, et al. Infection of humans and animals with Echinococcus granulosus (G1 and G3 strains) and E. ortleppi in Southern Brazil. *Vet Parasitol*. 2011;177(1–2):97–103.
- Schwabe CW. Current status of hydatid disease: a zoonosis of increasing importance. In: Thompson RCA, editors. *The Biology of Echinococcus and Hydatid Disease*, London: George Allen & Unwin; 1986: 81–113.
- Linda P, Gilda C, Lidia C, et al. Cystic echinococcosis in a single tertiary care center in Rome, Italy. *Bio Med Res Int*. 2013; Article ID 978146, 9 pages.
- Roneus O, Christensson D, Nilsson NG. The longevity of hydatid cysts in horses. *Vet. Parasitol*. 1982;11(2–3):149–154.
- Spruance SL. Latent period of 53 years in a case of hydatid cyst disease. *Arch Intern Med*. 1974;134(4):741–742.
- Alvarez Rojas CA, Romig T, Lightowlers MW. Echinococcus granulosus sensu lato genotypes infecting humans—review of current knowledge. *Int J Parasitol*. 2014;44(1):9–18.
- Cardona GA, Carmena D. A review of the global prevalence, molecular epidemiology and economics of cystic echinococcosis in production animals. *Vet Parasitol*. 2013;192(1–3):10–32.
- Carmena D, Cardona GA. Canine echinococcosis: global epidemiology and genotypic diversity. *Acta Trop*. 2013;128(3):441–460.
- Carmena D, Cardona GA. Echinococcosis in wild carnivorous species: epidemiology, genotypic diversity, and implications for veterinary public health. *Vet Parasitol*. 2014;202(3–4):69–94.
- Ito A, Wen H, Yamazaki H. Taeniasis/cysticercosis and echinococcosis in Asia. *Asian Parasitology*. 2005;2:155–234.
- Ahmed ME, Eltom KH, Musa NO, et al. First report on cerculation of echinococcus ortleppi in the one humped camel (camelus dromedaries), Sudan. *BMC Vet Res*. 2013;9:127.
- Bowles J, McManus DP. NADH dehydrogenase 1 gene sequences compared for species and strains of the genus Echinococcus. *Int J Parasitol*. 1993;23(7):969–972.
- Dybiez M, Gierczak A, Dabrowska J, Rdzancki I, Michalowicz B. Molecular diagnosis of cystic echinococcosis in human from central Poland. *Parasitol Int*. 2013;62(4):364–367.
- Fasihi MH, Budke CM, Rostami S. The monetary burden of cystic echinococcosis in Iran. *PLoS Negl Trop Dis*. 2012;6(11):e1915.
- Nakao M, McManus PD, Schantz PM, Craig PS, Ito A. A molecular phylogeny of the genus Echinococcus inferred from complete mitochondrial genom. *Parasitology*. 2007;134(Pt 5):713–722.
- Lavikainen A, Lehtinen MJ, Laaksonen S, Agren E, Oksanen A, Meri S. Molecular characterization of Echinococcus isolates of cervid origin from Finland and Sweden. *Parasitology*. 2006;133(Pt 5):713–722.
- Lavikainen A, Lehtinen MJ, Meri T, Hirvenla-Koski V, Meri S. Molecular genetic characterization of Fennoscandian cervid strain, a new genotypic group(G10) of Echinococcus granulosus. *Parasitology*. 2003;127(Pt 5):207–215.
- Obwaller A, Schneider R, Walochnik J, et al. Echinococcus granulosus strain differentiation based on sequence heterogeneity in mitochondrial genes of cytochrome c oxidase I and NADH dehydrogenase I. *Parasitology*. 2004;128(Pt 5):569–575.
- Hoa LV, Tan VN. Concerning the presence of cestodes, Echinococcus granulosus (Batsch, 1786), in a wild dog, Cyon primaerus (Hodgk) in South Vietnam. *Bull Soc Pathol Exot Filiales*. 1967;60(1):64–71. French.
- Thompson RCA. The taxonomy, phylogeny and transmission of Echinococcus. *Exp Parasitol*. 2008;119(4):439–446.
- Grenouillet F, Umhang G, Arbez-Gindre F, et al. Echinococcus ortleppi infections in humans and cattle, France. *Emerg Infect Dis*. 2014;20(12):2100–2102.
- Tigre W, Deresa B, Haile A, et al. Molecular characterization of Echinococcus granulosus s.l. cysts from cattle, camels, goats and pigs in Ethiopia. *Vet Parasitol*. 2016;215:17–21.
- Amer S, Helal IB, Kamau E, Xiao L. Molecular characterization of Echinococcus sensu lato from farm animals in Egypt. *PLoS One*. 2015;10(3):e0118509.

Research and Reports in Tropical Medicine

Publish your work in this journal

Research and Reports in Tropical Medicine is an international, peer-reviewed, open access journal publishing original research, case reports, editorials, reviews and commentaries on all areas of tropical medicine, including: Diseases and medicine in tropical regions; Entomology; Epidemiology; Health economics issues; Infectious disease; Laboratory

science and new technology in tropical medicine; Parasitology; Public health medicine/health care policy in tropical regions; and Microbiology. The manuscript management system is completely online and includes a very quick and fair peer-review system. Visit <http://www.dovepress.com/testimonials.php> to read real quotes from published authors.

Submit your manuscript here: <https://www.dovepress.com/research-and-reports-in-tropical-medicine-journal>